Index Copernicus ID 5385

ISSN No. 0972-396X

KDJ

Kerala Dental Journal

Vol 42 | No. 1
January 2019

Quarterly Publication of Indian Dental Association, Kerala State Branch

kdj.idakerala.com

SIS Index ID 833

Lips can't Lie:- An original study on Role of lip prints in individual identification

Antimicrobial properties of titanium dioxide nanoparticles and chitosan reinforced polymethyl methacrylate resin: an in vitro study

An in vitro evaluation of effects of packaged fruit juices on various tooth coloured restorative materials and dental enamel

Versatile ways for orthodontic intrusion of anterior teeth

Redefining the role of Rugae in Supporting/Stabilizing Complete Dentures – A Review

Some Unrenowned Bacteria -Associated With Periodontitis

Minimally invasive procedure for the removal of an Aberrant Frenum

Creation of an esthetic smile

Treatment of lateral periodontal cyst

Race with braces; A novel Orthodontic approach

Non-metric dental traits in forensic odontology: brief review

Customization and precision in orthodontics: current and future perspectives

editorkdj2018@gmail.com

www.idakerala.com

Kerala Dental Journal
Vol. 42 | No. 1 | January 2019

OFFICE BEARERS OF IDA KERALA STATE

PRESIDENT
Dr Abhilash G S

IMM. PAST PRESIDENT
Dr Ciju A Paulose

PRESIDENT ELECT
Dr C C Joseph

VICE PRESIDENTS
Dr.Jinu Mathew Vaidyan
Dr.Anil Thunoli
Dr. George Abraham

HON. SECRETARY
Dr Suresh Kumar G

JOINT SECRETARY
Dr Binoy Stanly

ASST. SECRETARY
Dr. Krisshna Kumar K S

TREASURER
Dr. Arun R.

EDITOR
Dr Anjana G

CDE CHAIRMAN
Dr. Jose Paul

CDH CHAIRMAN
Dr Subash K. Madhavan

EDITOR
Dr Anjana G

ASST. EDITOR
Dr Sangeeth K Cherian
Dr Joseph Edward

BUSINESS MANAGER
Dr V I Paul

EDITORIAL CONSULTANTS
Dr K Nandakumar
Dr Santhosh Sreedhar
Dr K George Varghese
Dr Chandrashekharan Nair
Dr C V Pradeep
Dr P G Francis
Dr Oommen Aju Jacob
Dr Thomas Manjooran
Dr Sobha Kuriakose
Dr N O Varghese

EX-OFFICIO MEMBERS
Dr Abhilash G S
Dr Suresh Kumar G
Dr Ciju A Paulose
Dr C C Joseph

EDITORIAL BOARD
Dr Dibyendu Mazumdar
Dr Ashok Dhoble
Dr M K Mangalam
Dr Jolly Mary Varghese
Dr Sheela Sreedhar
Dr Retnakumari
Dr E Anuradha Sunil
Dr Gilsa K Vasunni
Dr Anitha Balan
Dr Ajay Haridas
Dr V T Beena
Dr Shobhana C R
Dr Manjunath Rai
Dr Shaju Chemmanam
Dr Anupam Kumar T V
Dr Harish Kumar V V
Dr Vibha Shetty
Dr George P John
Dr Kavitha Kulkarni
Dr Jose Paul
Dr Vinod Kumar R B
Dr Radhakrishnan
Dr Civy V Pulayath

EDITORIAL OFFICE
Amritha Multi-specialty and Pediatric Dental Clinic
Opposite Akshaya Hospital,
Kaloor Kadavanthra Road
Kadavanthra, Kochi- 682 020
Kerala
Phone: 9447115816
e-mail: editorkdj2018@gmail.com
web: www.idakerala.com

Aesthetic Crowns for little Angels

Un esthetic primary teeth can produce negative self-perceptions in preschool-aged children. While restoring badly broken-down primary incisors and molars, Pediatric dentists had very few aesthetic options for full coverage restorations. Full coverage restoration techniques for primary teeth include, polycarbonate crowns, acid etched crown, stainless steel crown (SSC), open–faced SSC with veneer placed on chair side and commercially veneered SSC. Each of these techniques presents technical, functional or esthetic compromises that complicate their efficient and effective usage.

Zirconia has only been used for pediatric crowns since 2010. Pediatric zirconia crowns, like stainless steel crowns, come premade in six or seven different sizes for each tooth and are supplied in kits.

To place the crowns, the caries is removed and the tooth prepared with occlusal and circumferential reduction to a gingival featheredge. An appropriately sized crown is then tried onto the preparation. If the crown does not fit, either another size is tried or more tooth reduction is done until a crown is passively seated onto the preparation. No modification of the crown is possible, therefore, extended preparation and fitting times are necessary.

A one to two mm sub-gingival feather margin also is required for proper crown placement. But the advantages are very good aesthetics and no chipping or discoloration.

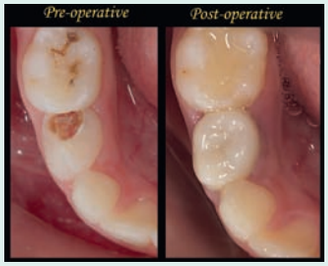

Edited by: **Dr. Anjana G,** Hon. Editor • Published By: **Dr. Suresh Kumar G.** Hon Secretary • **For IDA, Kerala State Branch** • Design and concept: **Suman Graphics,** sumangfx@gmail.com • Printed at: **Printout Villa,** Mukkom

Kerala Dental Journal
Vol. 42 | No. 1 | January 2019

Contents

Contents

Editorial 6

President's Message 7

Secretary's Report 8

Lips can't Lie:- An original study on Role of lip prints in individual identification 9
Sajith S Raj, Vinod Kumar RB, Jubin Thomas, Ajish M Saji, Akhil S, Amal K Iype

Antimicrobial properties of titanium dioxide nanoparticles and chitosan reinforced polymethyl methacrylate resin: an in vitro study 14
Yehsana N., Prabu P.S., Shinto Thomas, Meenu Merry C Paul, Laju.S, Justin Ninan

An in vitro evaluation of effects of packaged fruit juices on various tooth coloured restorative materials and dental enamel 17
Twinkle M. Alex, A. Devadathan, Baby James, Jose Jacob, Manuja Nair

Versatile ways for orthodontic intrusion of anterior teeth 22
Mohamed Nayaz VP. P.G. Francis, Vincy Antony Margaret

Redefining the role of Rugae in Supporting/Stabilizing Complete Dentures – A Review 26
Anjana Rajagopalan, Prasanth Viswambharan

Some Unrenowned Bacteria -Associated With Periodontitis 29
Varun M., Mahesh Raj V.V., Anil Melath, Subair K., Jilu Jessy Abraham

Minimally invasive procedure for the removal of an Aberrant Frenum 32
Suresh A., Nandakumar K., Prasad A, Madhu M, Midhulaj Azeez

Creation of an esthetic smile 36
Mekha Madhu, T P Padmakumar, Aneen Suresh, Anagha Prasad, Harikrishnan B. Pillai

Treatment of lateral periodontal cyst 39
Anagha Prasad, Devisree Naveen, Mekha Madhu, Aneen Suresh, Aswathy Sheela Sudhakar

Race with braces; A novel Orthodontic approach 42
Shabeer Babu, P.G. Francis, Vincy Antony Margaret

Non-metric dental traits in forensic odontology: brief review 47
Asha S D, Nripan T, R. Rathy, Harish R.K, Ameena M.

Customization and precision in orthodontics: current and future perspectives 52
Asni Shebad A.

Association News 56

Editorial

Dr. Anjana G.

Continuing Dental Education: a mandate

Continuing Dental Education programs have picked up and is booming, where everyday one gets a soft copy of the brochure of some program or the other since the credit point system has been reinstated. Dentists are in confusion as to attend which program and where. While the vendors of the program tries to market the program by increasing the registrations to huge numbers to claim them as mega CDEs, many a times the information and skills that one takes back home is diluted and minimal. The freebies promised turns out to be outdated at times too.

IDA branches being one of the most important providers of CDE programs, has the responsibility of making sure that the program actually benefits its members as the Dental Practitioners come to attend this spending their valuable time and money. Though the speaker might be a renowned person, the matter he/she presents should be tailor made to the audience as to make the participants utilize the information and skills in their clinical practice as well as benefit their patients. Certain topics are mandatory updates, but a variety of other topics can be chosen and a CDE calendar can be made as to the need of the practitioners in each branch. This gives the practitioners a choice as to which CDE to attend according to their need. Hands-on programs should be conducted so as to benefit each registrant in acquiring necessary skills, even if the number is limited to few for whom the necessary facilities and individual attention can be provided. Ultimately it is not the quantity, but the quality that matters and let us work wisely to provide our members with useful information and skills that benefits their practice as well as their patients.

Dr Anjana G.
Editor, KDJ

Message from the President

Dr Abhilash G S

Dear Members of IDA,

Greetings from IDA Kerala state.

It gives me immense pleasure to pen down my words for the first issue of KDJ for the year 2019. First of all I would like to congratulate our Editor Dr. Anjana G. for bagging the Best Journal award at the National level. Kudos to her untiring efforts and dedication for achieving the honor. Kerala Dental Journal keeps its high standard always with informative contents and excellent quality.

As this new association year unfolds with newer hopes and goals, I am looking forward to work for our profession with the vibrant team of new office bearers. I am sure that, we can achieve better results with the help of this sincere team and with the cooperation of our members.

As all of us know, our profession is facing a lot many new challenges like Implementation of C E bill, New Consumer protection acts etc. IDA Kerala state is keen to tackle these issues. We have already formed District committees all over Kerala to deal the major issues District wise. The first state level meeting of District committees was held on 6th of March at Trivandrum and we had useful discussions and deliberations there.

Another important agenda of this year is about the hike in our membership strength and student membership. IDA Kerala state is charting out a master plan to work it out. We need whole hearted support from all local branches to fulfill this aim. At this juncture I sincerely request maximum support from every member in every activities and projects of our association. Without your cooperation we cannot move forward with strong and confident steps.

I am sure that this year also our Editor Dr. Anjana and her team can do the best for our journal. Every issue of our journal should be better than the previous one and on behalf of IDA Kerala state; I wholeheartedly wish all the very best to our Editor and Journal to achieve new milestones.

Thanking you

JAI IDA

JAI HIND

Dr. G S Abhilash
President, IDA Kerala state

Message from the Secretary

Dr. Suresh Kumar G.

Dear Members,

Greetings to you.

As the new organisational year unfolds it brings with it a sense of optimism to the association in helping the members to face up to the challenges of the present.

A year that is undoubtedly going to be very important as new regulations are being enforced in the form of CE Act, CDE Regulations and amendments to the Dentist Act. This will surely have a significant effect on the way we practice dentistry in future.

We at the office fully understand this responsibility and will strive to work towards providing an environment that is conducive to the practice of the profession in a hassle free manner in the years to come.

The importance of channelising the collective strength of the profession is greater than ever before. It should be our endeavour to garner the support and trust of all organisations be it in the Government sector or Speciality organisations in our efforts.

IDA Kerala with its flagship schemes like IDA HOPE, IDA MARK, IDA CAN, HOPEMEDI, HOPE ASSURE is surely on the right track and has always been a role model for other states to follow.

I take this as an opportunity to thank the numerous individual Members, Branches, Alumni Associations and Groups who have come forward to donate generously towards the IDA Disaster Relief Fund in a sizeable manner. The fact that we were able to help more than 60 Dental Surgeons who have suffered losses to their clinic or residence in the floods is a testimony in itself to the commitment that IDA and its members have towards the well being of each other.

The successful conduct of 'Milan 2019' gives us much hope and confidence in the preparations for the much awaited National Conference (IDC 2020) to be held at Thiruvananthapuram during January 2020. We request the sincere participation of each and every member to make this event a memorable one.

The enthusiasm shown by the new group of office bearers of all local branches is the welcome sign and definitely augurs well for the association and the profession as a whole.

Looking forward to a great year ahead.

Thank you

Dr. Suresh Kumar G.
Secretary, IDA Kerala State

ORIGINAL RESEARCH

Lips can't Lie:- An original study on Role of lip prints in individual identification

*Sajith S Raj, **Vinod Kumar RB, ***Jubin Thomas, ****Ajish M Saji, ***Akhil S, ****Amal K Iype,

Abstract

Background & Objectives: Cheiloscopy is the study of lines and grooves on the red portion of lips, the imprints of which are called lip prints. Like finger prints, lip prints can be a source of evidence left at a crime scene. For personal identification, the theory of uniqueness is the strong point used in finger print analysis. But many authorities had frowned over the reliability of lip print uniqueness as a forensic aid in the identification of individuals. So, the aim of the present study was to assess the uniqueness of lip prints as a reliable and potential tool for the identification of its creator.

Method: A total of 175 individuals (included 94 males and 81 females) and aged between 18-55 years were included in the study. The lips of the individuals were cleaned and matted lipstick was evenly applied. The lip prints were recorded on white bond paper. Each of thelip prints were divided into six compartments. The number of lines present on the middle one centimetre compartment of the lower lip, their length, branching and combination were considered for classification. The classification as proposed by Suzuki and Tsuchihashi was followed. The legible lines in each compartment were coded as per their pattern. The sum of these codes were noted in each compartment. The combination of these scores represented an individual lip and were compared with other combinations, for similarity if any.

Results & Discussion: In the studied cases, the lip scores in a particular compartment/ a few compartments were the same but their scores in other compartments differed. It was observed that no two lip prints had exactly matching scores in all the six compartments. Through the study it was demonstrated that none of the lips had a single type of lip print pattern and the combination of patterns on each lip print varied widely.

Conclusion: From the present study, it could be established that lip prints show variation from person to person. During the study it was demonstrated that none of the lips had a single type of lip print pattern and the combination of patterns on each lip print varied widely. Further it was noted that no two individuals had identical lip prints.

Keywords: cheiloscopy; lip print; patterns; lip stick;classification; scoring;uniqueness; identification.

KDJ 2019 | Vol. 42 | No. 1 | Pg 9-13

► Introduction

Human identification is the establishment of a person's individuality and is an ultimate necessity for personal, social and legal reasons. Legally, identification is necessary in criminal cases like persons accused of assault, murder, rape and impersonation, etc. and in civil cases like marriage, inheritance, passport, insurance claims, missing persons, etc.[1]

In Forensic Science, a means of personal identification used is to scientifically analyse physical features present on the body.[1] Apart from physical examination, there are advanced laboratory tests and special techniques for personal identification.[2]

Advanced laboratory methods for identification include DNA profiling, videograph, voice identification, superimposition technique, facial reconstruction and retina & iris scan. But at times, available evidences will not be sufficient to go for such advanced routes. Then, there are some special identification techniques which include Dactyloscopy (finger prints), Poroscopy (study of pores), Podogram (foot-marks), Rugoscopy (palatal rugae prints) and Cheiloscopy (lip prints).[1]

The imprint of normal lines and furrows in the form of wrinkles and grooves in the human lip, between the inner labial mucosa and outer skin, having certain individual characteristics like finger prints are called Lip prints.[3] The examination of lip prints is known as Cheiloscopy.[2]

The grooves and lines on the lips are heritable and individualistic. Therefore, like finger prints, lip prints can be

*Postgraduate Student, **Professor & Head, ***Reader, ****Senior Lecturer, Department of Oral Pathology, Malabar Dental College and Research Centre, Mudur P.O., Edappal, Kerala - 679 578. • Corresponding Author: Dr Akhil S., E-mail: aksmvpa@gmail.com

a source of evidence left at a crime scene.[1, 2] Latent lip prints would be available as the vermilion zone of lips are continually wet by saliva and the outer border skin of lips is moistened by sebaceous glands and sweat glands.[4] These lip prints can be obtained up to 30 days after being produced, using special techniques which are employed to develop the finger prints.[5] Lip prints are unaltered from six weeks of intrauterine life till death.[4]

Lip print identification methodology is very similar to finger print analysis. To establish the identity between evidence and the comparing entity, the common properties are to be compared and proved.[37] For personal identification, the theory of uniqueness is the strong point used in finger print analysis. But many authorities had frowned over the reliability of lip print uniqueness as a forensic aid in the identification of individuals.[2,5,18] So here we tried to assess the uniqueness of lip prints as a reliable and potential tool for the identification of its creator.

Fig. 1: Armamentarium

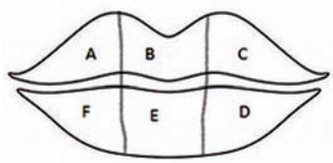

Fig. 3: Lip print divided into six compartments

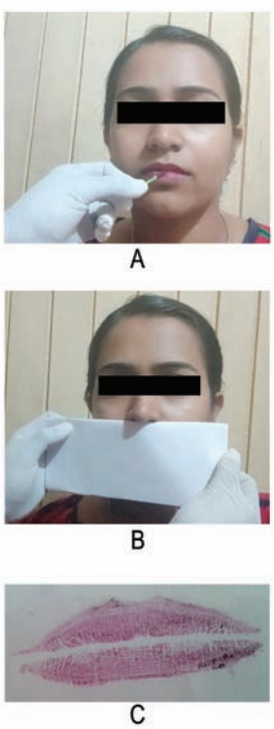

Fig. 2: Procedure
(A) Application of lipstick with an applicator
(B) Transfer of lip print to white paper
(C) Lip print protected with cellophane tape

► Materials & Methodology:

A total of 175 individuals (included 94 males and 81 females) aged between 18-55 years who visited Malabar Dental College, Manoor, Kerala and had normal lips free from any pathology, were included in the study. Individuals with known hypersensitivity to lipsticks or who had, inflamed /malformed lips, congenital abnormality to lips, trauma /scar, loss of front teeth were excluded. Prior ethical clearance had been obtained from the Institutional Ethical Committee (Ref. No: IEC/06// OPATH-B/MDC/2016).

Procedure for extraction of lip prints:

Informed written consent was taken from each of the individuals in the study. The lips of the individuals were cleaned using cotton and matted lipstick was evenly applied with a lipstick applicator in a single stroke. The subjects were asked to rub both the lips to evenly spread the applied lipstick and made to wait for two minutes for lip stick to dry. The lip prints were recorded on the white bond paper by placing it over the closed lips. The central part of lips were dabbed first and then uniform pressure was given to the corners of each lips. A piece of transparent cellophane tape was stuck over each lip print on bond paper to avoid distortion. The subject's serial number was written on the back of the paper. A photograph of the lip print was taken with a digital camera for record purpose. The lip prints were studied carefully using a magnifying lens with light. (Figs 1-2)

For the study purpose, the lip prints were divided into six

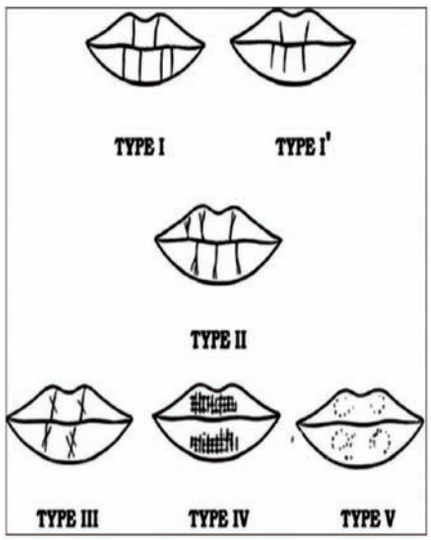

Fig 4: Schematic representation of Suzuki and Tsuchihashi classification

Fig 5: Lip prints with the Suzuki & Tsuchihashi patterns in the lower middle portion

compartments, in such a way that two compartments on either sides of middle one centimeter compartment on each upper and lower lips were considered (Fig. 3).

The middle one centimetre (10 mm) compartment of the lower lip was considered for classification as this part is usually visible in any trace, least distorted and most frequently found at the crime scene.[8] The number of lines and furrows present were noted. The lip groove pattern which had numerical superiority in this segment was recorded. The classification of the patterns of grooves on lips as proposed by Suzuki and Tsuchihashi was followed:[9] (Fig. 4)

Type I – A clear-cut groove running vertically across the lip.

Type I'– Partial-length groove of type I.

Type II – A branched groove.

Type III – An intersected groove.

Type IV – A reticular pattern.

Type V – Undetermined /Grooves do not fall into any of the above categories.

To know whether lip prints differed from one another and whether it is unique to its owner, the following method was applied, in the lip prints which were already segregated according to this classification.

Scoring of lip prints:

By visual comparison, ten similar appearing lip prints from each six types were selected for further analysis. Since the lip prints which had similar pattern in the lower middle one centimeter were already segregated under each type, to find identical lip prints, their similarity in all other compartments of the complete lip were verified.

The legible lines in each compartment were coded as per their pattern as 1 (type I), 2 (type I'), 3(type II), 4 (type III), 5(type IV) and 6 (type V). These lines were marked from left to right in each compartments. The sum of these codes were noted in each compartment.

The sums (lip scores) were recorded in six columns representing the six compartments, from upper right compartment to lower right compartment in clockwise order (A, B, C, D, E and F). The total lip score, counting all the compartment scores on a lip was also noted (Table 1).

The combination of these seven scores represented an individual lip and were compared with other combinations, for similarity if any. If matching or similar combinations were found, the total number and sequence of individual codes (patterns) in each compartments were compared.

Table 1: Lip print score table

Subject's serial No.	Pattern	Compartment scores						Total lip score
		A	B	C	D	E	F	

Results:

In our study, we found that all the six types of lip print patterns described according to Suzuki and Tsuchihashi's classification were present in the study population (Fig. 5) (Table 2).

When ten lip prints which appeared similar, from each of the six lip print types were selected and further analyzed, the score table showed that some cases within each lip print group matched in the total lip score but differed in the individual compartment scores (2 cases in type I lip prints). In some other cases, the lip scores in a particular compartment/ a few compartments were the same but their scores in other compartments differed. This was observed in the following cases (Table 3):

It was observed that no two lip prints had exactly matching scores in all the six compartments.

The compartments B and E recorded the maximum number of similarities in lip scores (10 cases in each). Compartment B represented the upper middle portion and compartment E represented the lower middle portion. Thus both the upper and lower middle portions of lips showed maximum similarity

Table 2: Lip print pattern distribution in study population

Total subjects = 175	Types					
	I	I'	II	III	IV	V
% within subjects	26 14.9%	14 8.0%	20 11.4%	29 16.6%	59 33.7%	27 15.4%

Table 3: Lip prints with similarity in compartment scores

	Lip print Type					
	I	I'	II	III	IV	V
No. of cases which showed similarity	4	7	9	4	2	7
No. of similar compartments	2	2	2	2	3	2

among individuals.

Thus through the study it was demonstrated that none of the lips had a single type of lip print pattern and the combination of patterns on each lip print varied widely. Further it was noted that no two individuals had identical lip prints.

► Discussion:

In physical appearance humans are diverse in nature. This diversity has resulted from genetic influences and environmental factors including climate and geographic location. Thus, the world population look different. This diversity is present in oral morphology as well. As a result, it may be possible to identify an individual and that individual's population of origin based on this biological and anthropological variation in oral features.[2] Forensic odontology utilizes such individual specific variations in and around oral cavity for personal identification. Thus, cheiloscopy which deals with the study of system of characteristic furrows on the red part of human lips can be a vital tool in forensic science.[1]

Identification is the determination of exact individuality of a person. The traditional methods for personal identification in Forensic science include visual identification, anthropometry, medical records, finger prints analysis, sex determination, age estimation, measurement of height, differentiation by blood groups, DNA analysis, craniofacial techniques and odontology. Lip print analysis or cheiloscopy is a special method of identification that can help the investigator when other evidences are not available or in conclusive.[1, 3]

The development or extraction of lip prints is a matter of providing colour contrast between the print and its background, so that it can be photographed or otherwise preserved for later comparison.[10, 11] A number of chemicals and dyes, like Sudan black, indigo, lysochromes, carbonate powder, aluminium powder and Nile red are used to highlight these imprints so that they can be easily visualized and identified.[12]

Lipsticks are complex substances, which have in their constitution, in a solid base of waxes, oils, dissolved dyes or colouring agents, hydrocarbons and sometimes perfumes.[3] There are lipsticks that do not leave visible marks, called "permanent or long-lasting lipsticks".[13] Conventional lip sticks can be easily applied and removed from the lips. Because of the harmless nature, easiness in usage and reproducibility numerous researchers had used conventional lip sticks to produce lip prints with colour contrast, in their studies.

In the present study, the use of a matted dark-coloured lip stick gave a good contrast from the background white paper, so that the lines in the lip print are easily noticed and legible. It was important to maintain hygiene without causing cross contamination among study subjects and was effectively achieved using separate sterile applicator tips for each individuals. Lip stick application and transfer of lip prints to white paper was a simple, less time consuming, inexpensive and easy to remove technique that was well accepted by the subjects in the study.

In our study, the middle one centimetre of lower lip was considered for classification which was proposed by Sivapathasundaram et al., as this part is usually visible in any trace, least distorted and most frequently found at the crime scene.[8] In all the lip impressions we recorded, inevitably the most legible area was the lower middle portion.

The classification of the lip-prints is valuable in reducing the number of items to be compared, and helps in identification of the individual, as in the case of fingerprints by finding characteristic points to establish the diagnosis.[2]

We used the classification by Suzuki and Tsuchihashi because it is the most commonly used classification system in the literature due to its simplicity to learn, accuracy, easiness in usage and interpretation.[14]

In our study, we tried to analyze the uniqueness of lip prints, which is the key factor in personal identification. A combination of different patterns was seen in every lip print. The possible combination of the six types of grooves is, theoretically[6] 6x6 if they are entered in the six compartments on each lip print.[14] We used this characteristic feature to demonstrate that each lip print differed from one another, thus differentiating their owners. This was done by scoring these patterns on lips compartment-wise.

The number of patterns or lines present in each compartment can also vary. The cases which were matching in the total lip score, they differed in the individual compartment scores. The lip score in a particular compartment of lip could be the same among some lip prints but their lip scores in other compartments differed. If matching or similar combinations were seen, the total number and position of individual codes (patterns) in each of these six compartments were compared and found to be different.

Those similar appeared lip prints differed either in the width and length of the lips, the number of grooves present, the length of lines, the level of branching and intersections or the spacing between grooves or the pattern combinations in the individual lip prints, thus establishing the uniqueness and individuality of lip prints.

In finger print analysis the coincidence of nine individual properties is necessary to establish the identity between evidence

and comparing entity, worldwide. A catalogue of 23 types of individual cheiloscopic properties had been prepared by Kasprzak J. He stated that an average of 1145.5 individual properties could be established for one lip print whereas in one finger print only 100 individual properties could be differentiated.[15] This could make the combinations of these properties on lips be varied in mind-blowing number of ways.

Our study finding was in accordance with various studies which all had demonstrated lip print uniqueness either manually by visual comparison, [8, 10, 16] or digital method of comparison[14,17] or by superimposition of digital photographs of the lip prints and could reveal no two identical lip prints.[9] Our study results differed from Randhawa K et al.[7], Saraswathi TR et al.[5] who had raised questions over the reliability of uniqueness of lip prints in forensic identification. The present study was in line with the studies by Prabhu RV et al.[14], Prasad P et al.[18] who had demonstrated lip print uniqueness.

Setbacks we faced during the present study were as follows: In our study, around 8% of our lip prints were smudged and were repeated. Extra care was given to maintain an even thickness for lipstick application. The middle part of each lips were recorded well, but towards the corners the impressions were less legible. We encountered difficulty in getting lip impressions of males who had prominent facial hairs.

Limitations of cheiloscopy: Tsuchihashi had pointed out that the anatomic position of lip prints on the transition zone close to vermillion border is a highly mobile area. Even closed mouth and open mouth lip impressions may differ.[8] There is no bony support to this area, thus lip prints produced can differ in appearance when pressure and its direction of application change. This makes cheiloscopy a highly technique sensitive method. Surgical treatments, scarring and trauma may alter the morphology of lip grooves. So there is a need to develop standard protocols for collecting and analyzing lip prints to establish its validity in the court of law.[2]

Over the years just as for fingerprint detection equipment and databases have been developed efficiently, similar effort and investment in methodologies, research and databases would help in expanding the utilization of lip prints in forensic science for either partial or complete identification of an individual.[16] Lip prints bring an adjuvant evidence from a crime scene that can be valuable, especially in cases lacking other evidence, like fingerprints.[3]

► Conclusion:

From the present study, it could be established that lip prints show variation from person to person. During the study it was demonstrated that none of the lips had a single type of lip print pattern and the combination of patterns on each lip print varied widely. Further it was noted that no two individuals had identical lip prints.

This validates that lip prints can serve as a part of identification data of any individual, along with the finger prints.

► References:

1. Mahanta P. Forensic Odontology. In:Modern textbook of forensic medicine & toxicology. Jaypee Brothers; 2014.p.142-168.
2. Acharya AB, Sivapathasundharam B. Forensic Odontology. In: Sivapathasundharam B, editor. Shafer's textbook of Oral Pathology. 8th ed. Elsevier India: New Delhi; 2016. p. 716-40.
3. Venkatesh R, David MP. Cheiloscopy: An aid for personal identification. J Forensic Dent Sci. 2011; 3(2):67-70.
4. Nagpal B, Hegde U, Sreeshyla HS, Arun M. Comparative evaluation of lip prints among Indian and Malaysian students. J IndianAcad Forensic Med 2015; 37(2):131-4.
5. Saraswathi TR, Mishra G, Ranganathan K. Study of lip prints. Forensic Dent Sci 2009; 1(1):28-31.
6. Sandhu SV, Bansal H, Monga P, Bhandari R. Study of lip print pattern in a Punjabi population. J Forensic Dent Sci 2012; 4:24-8.
7. Randhawa K, Narang RS, Arora PC. Study of the effect of age changes on lip print pattern and its reliability in sex determination. J Forensic Odontostomatol. 2011 Dec; 29(2):45-51.
8. Sivapathasundharam B, Prakash PA, Sivakumar G. Lip prints (cheiloscopy). Indian J Dent Res 2001; 12:234-7.
9. Suzuki K, Tsuchihashi Y. Personal identification by means of lip print. J Forensic Med 1970; 17:52-7.
10. Chatra L, Peter T, Ahsan A. Cheiloscopy. Int J Forensic Odontol 2016; 1:48-52.
11. Dineshshankar J, Ganapathi N, Yoithapprabhunath TR, Maheswaran T, Kumar MS, Aravindhan R. Lip prints: Role in forensic odontology. J Pharm Bioallied Sci. 2013; 5 (Suppl 1):S95-7.
12. Ranjan V, Sunil MK, Kumar R. Study of lip prints: A forensic study. J Indian Acad Oral Med Radiol 2014; 26:50-4.
13. Herrera LM, Fernandes CM, Serra MD. Human identification by means of conventional and digital Cheiloscopy: a study of the literature. RGO. RevistaGaúcha de Odontologia. 2013; 61(1):113-20.
14. Prabhu RV, Dinkar A, Prabhu V. Digital method for lip print analysis: A New approach. J Forensic Dent Sci. 2013; 5(2):96-105.
15. Devi A, Astekar M, Kumar V, Kaur P, Singh N, Sidhu GK. The study of inheritance analysis and evaluation of lip prints in individuals. J Forensic Dent Sci. 2015 Jan; 7(1):49-53.
16. Alzapur A, Nagothu RS, Nalluri HB. Lip prints-A study of its uniqueness among students of MediCiti Medical College. Indian J ClinAnat Physiol.2017 Jan; 4(1):68-70.
17. Jatti D, Rastogi P. Digital analysis of lip prints for personal identification: a cross sectional study in south Indian population. J Indian Acad Forensic Med.2015; 37(3):289-93.
18. Prasad P, V. A comparison of lip prints between Aryans-Dravidians and Mongols. Indian J Dent Res 2011; 22:664-8.

Antimicrobial properties of titanium dioxide nanoparticles and chitosan reinforced polymethyl methacrylate resin: an in vitro study

*Yehsana N., **Prabu P.S., ***Shinto Thomas, ****Meenu Merry C Paul, *****Laju.S, ******Justin Ninan

Abstract

Aim: To evaluate and compare the antimicrobial adhesion property of titanium dioxide nanoparticles and chitosan reinforced in polymethyl methcrylate resin.

Materials and method: Acrylic resin samples in the form of thin discs of 10×2mm were fabricated. Out of the 50 samples 10 was kept as control,10 each were surface coated with 2 wt% titanium dioxide and chitosan respectively and 10 samples each were reinforced with chitosan and titanium dioxide in 2 wt%. All the samples were subjected to UV light treatment. The antimicrobial adhesion assay of all the samples was done and the number of colony forming units (CFU) was counted.

Results: Titanium dioxide surface coated samples showed the highest antimicrobial adhesion property (2.2×10^2 CFU) followed by titanium dioxide reinforced samples (8.5×10^2 CFU). Chitosan reinforced samples showed 1.85×10^3 CFU and chitosan coated samples 4.5×10^3 CFU, which was better than the control (7.2×10^3 CFU). The statistical analysis was done using one way ANOVA and chi quare test and the value calculated was $P<0.05$.

Conclusion: The surface coating of PMMA resin with titanium dioxide nanoparticles is a reliable method to develop antimicrobial properties in dentures.

Key words: Titanium dioxide nanoparticles, Candida albicans species, Chitosan

KDJ 2019 | Vol. 42 | No. 1 | Pg 14-16

Introduction

The improvement in life expectancy has led to an increase in the ageing population with a hike in the demand for removable dentures. Since its introduction by Dr. Walter Wright, Poly methyl methacrylate (PMMA) resin has been the ideal material of choice for the fabrication of removable dentures. PMMA continues to be used because of its favorable properties. However it is not gifted with antibacterial properties, because of which long term use of dentures is often associated with denture stomatitis, an infection of the oral cavity. Candida albicans is a symbiotic organism inhabiting the oral mucosa of healthy individuals with a prevalence of 3 to 48% with a higher preponderance for children and young adults.[1, 2, 3,5]

The microbial adhesion of Candida species to dentures often befouls the oral cavity and can lead to serious systemic infections like pneumonia, especially in the geriatric and immuno compromised patients.[3]

Though there are several chemical and mechanical methods to remove the bio film, efficiency in complete removal is a challenge for geriatric patient especially the debilitated and patients with poor neuromuscular co-ordination. Specific antimycotic drugs such as Nystatin, amphotericin B, antifungal antibiotics on a long term use often leads to resistance and recurrences.[1,13]

The process of activation of catalysts by UV light is termed photocatalysis. One such naturally occurring material that could be exploited as a photocatalyst is titanium dioxide with the added advantage of being antimicrobial, nontoxic and biocompatible. The incorporation of titanium dioxide into acrylic denture base resins to improve its mechanical and antimicrobial properties have already been proved in the literature.[3, 4, 5, 13]

Chitosan is a naturally occurring biopolymer derived from chitin by N-deacetylation, and it is found to be nontoxic, biocompatible, biodegradable, antimicrobial and hemostatic. Recently chitosan has also been used in the researches with acrylic resins as an antimicrobial agent. Chitosan has been proved to have an inhibitory effect on candida albicans in a dose dependent manner.[6, 16, 18]

Though there are previous studies related to antimicrobial properties of chitosan and titanium dioxide, a comparative study has not been done yet. This study was done to compare the antimicrobial adhesion properties of titanium dioxide nanoparticles and chitosan, and also to compare the differences on surface coating and reinforcing them in PMMA resin.

Materials and method

The materials used for the study were Heat cure acrylic resin (acrylan –H), Titanium dioxide nanoparticles procured from KMML (Kerala Minerals and Metals Ltd, Kollam, Kerala),

* Final year postgraduate student, **Professor and Head, ***Final year postgraduate student, ****Professor, *****Reader, ******Senior Lecturer, Department of Prosthodontics, Malabar Dental College and Research Centre, Mudur, Edappal, Malappuram, Kerala - 679 578 • Correspondence Author: Dr Yehsana N., E-mail: drsanafarees@gmail.com

chitosan nanoparticles (Matsyafed, Neendakara, Kollam), Silane coupling agent: 3-glycidoxypropyl trimethoxy silane (alfa aesar), absolute ethanol (97%), glacial acetic acid (1%).

For the purpose of study about 50 samples in the form of thin discs of size 10 x 2 mm were fabricated from heat cure polymerizing acrylic resin (acrylan H). The acrylic samples were mixed according to manufacture recommendations of 2:1 by weight.

The samples were divided into five groups

Group A: Control group (plain PMMA), Group B: PMMA resin coated with titanium dioxide nanoparticles, Group C: PMMA resin coated with chitosan, Group D: PMMA resin reinforced with titanium dioxide nanoparticles, Group E: PMMA resin reinforced with chitosan. Both titanium dioxide nanoparticles and chitosan were reinforced and coated in a concentration of 2 wt%.

For Group B, Titanium dioxide nanoparticles (2 wt%) were coated on acrylic resin samples using the spin coating method.[15] For the purpose, titanium dioxide nanoparticles (2 wt%) was sonicated in a 10:1 solution of ethanol and silane coupling agent (alfa aesar) for 30 minutes.[7] 10 PMMA resin samples (10x2mm discs) were fabricated and was finished and polished. The spin coating was done per sample at the rate of 1000 rpm for 60 seconds. The samples were air dried.

For Group C, chitosan (2 wt%) was deacetylated by mixing in a solution of 1% of 50 ml acetic acid by magnetic stirring for 24 hours.[19] The acrylic discs (n=10) were coated with chitosan from the mixture using the spin coating technique similar to titanium dioxide.

The PMMA resin samples for Group D was fabricated by mixing Titanium dioxide 2 wt% with the polymer monomer mixture in the dough stage and was packed into the mold spaces created. The samples retrieved after acrylisation were finished and polished.

Similarly Group E, chitosan reinforced specimens were fabricated by mixing the deacetylated solution in 2 wt% with the acrylan–H monomer prior to mixing with the polymer. The samples were packed in the dough stage, acrylised, finished and polished.[19]

Antibacterial activity.

All the samples were subjected to UV light (365nm) from UV lamp (Philips, Made in Holland) for 60 minutes prior to inoculating the microbial culture. The sterile test specimens were placed in SDA (Sabouraud Dextrose Agar) plates inoculated with candida albicans strain (MTCC 227) and was incubated for 24 hours at 37°C. Each sample was then removed from the culture medium and was washed with distilled water three times to remove any Candida species clinging to the samples. The samples were then vortexed vigourously with 1 ml of sterile deionised water. A serial dilution was performed and 1 ml of the sample was plated on to PDA (Potato Dextrose Agar). After 24 hours of incubation the colony forming unit (CFU) was counted.[5]

► Results

Group A samples with plain PMMA showed 7.2 ×10^3 CFU/ml. Group B samples coated with 2 wt% titanium dioxide showed 2.2× 10^2 CFU/ml, Group C with chitosan coated samples 4.5× 10^3 CFU/ml, Group D with titanium reinforced PMMA was 8.5× 10^2 CFU/ml and Group E with chitosan reinforced PMMA showed 1.85×10^2 CFU/ml.

Statistical analysis

The statistical analysis for the study was done using the SPSS 19.0 soft ware. P values were calculated using one way ANOVA. Chi square test was used to determine the differences between the groups. P value was calculated to be P<0.05

GROUP	Antimicrobial adhesion in CFU/ml (Candida albicans species)
A-Control group	7.2 ×103
B- Titanium coated	2.2× 102
C-Chitosan coated	4.5× 103
D-titanium reinforced	8.5× 102
E-chitosan reinforced	1.85×102

► Discussion

Candidiasis continues to be one of the prevalent infections for the denture wearers, the leading causative agent being candida albicans species.[6] Continuous use of antifungal agents can lead to toxicity issues and development of resistance as majority of the infections are caused by the formation of biofilms.[1, 2, 6]

The antimicrobial properties of titanium coated PMMA resins have already been proved in literature through previous studies and it is attributed to the photocatalytic activity of titanium dioxide in the presence of sunlight or other UV light sources. Titanium dioxide on exposure to light in the presence of water vapor gets activated into reactive oxygen species like hydroxyl ion and superoxide which have a high oxidative power to decompose bacteria and organic matter into CO_2 and water, making it biocidal or antiproliferative. The coating of titanium dioxide on PMMA samples in small weight percentage helps to maintain the antimicrobial properties without compromising the mechanical properties.[11,12,15,17]

An increase in the CFU with titanium dioxide reinforced specimens may be explained by the fact that when reinforced within the specimen titanium dioxide need to be in higher concentrations (greater than 3%) for predictable antimicrobial properties.[3] The incorporation of higher percentage of titanium dioxide in turn compromises the mechanical properties of PMMA resins which has already been proved in the literature.

The antifungal effect of chitosan to inhibit the growth and adhesion of candida species have been proved in the literature. Chitosan is also a promising biocompatible base to coat or reinforce acrylic resins for antimicrobial activity. The antifungal activity of chitosan is dependant on the molecular weight, the amount of deacetylation obtained and the PH of the medium. High molecular weight chitosan has less antifungal activity compared to low molecular weight chitosan. The best results are

obtained when there is a high degree of chitosan deacetylisation and low media PH.[8,10]

The formation of the candida albicans biofilm proceeds through three phases on the polymethyl methacrylate strips- Early, intermediate and maturation phases. Chitosan is more effective on candida species in the early and intermediate phases and less effective in the matured phase.[6]

The antifungal activity of chitosan is attributed to its polycationic nature. The mode of action of chitosan on fungi happens through three mechanisms. One is by increasing the membrane permeability leading to leakage of cellular contents and eventually cell death, the second mechanism by chelating with the trace elements causing a shortage of nutrients available for the fungi and the third through the penetration of the cell wall and interfering with the synthesis of proteins and enzymes.[10] In this study the activity of chitosan in preventing the antimicrobial adhesion was more when compared to the control but less when compared to the titanium dioxide coated and reinforced groups. When comparison was made between the chitosan coated and chitosan reinforced groups, the chitosan reinforced groups showed more antifungal adhesion capability. This could be partly due to the chelation of surface coated chitosan with the fungi and also depends on the amount of coating that was obtained using the technique used in the present study. Also the incubation for 24 hours leads to the formation of more mature biofilms which is more resistant to the action of chitosan.[8]

► Conclusion

The present study was done to evaluate and compare the antimicrobial adhesion of titanium dioxide nanoparticles and chitosan upon surface coating and reinforcement in PMMA. The study led to the following conclusions:

(a) The surface coating of PMMA resins with titanium dioxide nanoparticles had the highest antimicrobial adhesion property (2.2×102 CFU)

(b) There were significant differences in inhibiting the microbial adhesion on PMMA resin between the surface coating of chitosan and titanium dioxide nanoparticles ($P< 0.05$)

(c) Titanium dioxide nanoparticle surface coating is more efficient than titanium dioxide reinforcement of PMMA resin for inhibiting microbial adhesion.

(d) Chitosan reinforced samples had lesser microbial adhesion compared to chitosan coated samples

(e) All the reinforced and surface coated groups had antimicrobial adhesion properties when compared to the control group ($P<0.05$)

Acknowledgement

Special thanks to Dept of Nanoscience, NIT Calicut for allowing a part of the study to be done there. We also extend our gratitude to Matsyafed, Neendakara, Kollam.

► References

1 Farah CS, Lynch N, McCullough MJ. Oral fungal infections: an update for the general practitioner. Australian Dental Journal 2010; 55:(1 Suppl): 48–54

2 Gleiznys A, Zdanaviciene E, Zilinskas J. Candida albicans importance to denture wearers. A literature review . Stomatologija, Baltic Dental and Maxillofacial Journal, 17: 54-66, 2015.

3 Tsuji M, Ueda T, Sawaki K, Kawaguchi M, Sakurai K. Biocompatibility of a titanium dioxide-coating method for denture base acrylic resin. Gerodontology 2015; doi:10.1111/ger.12204

4 Anehosur GV, Kulkarni DR, Naik MG, Nadiger RK. Synthesis and Determination of Antimicrobial Activity of Visible Light Activated TiO2 Nanoparticles with Polymethyl Methacrylate Denture Base Resin Against Staphylococcus Aureus. J Gerontol Geriat Res 2012, 1:1

5 Alrahlah A, Fouah H, Hashem M, Niazy AA, AlBadah A. Titanium Oxide (TiO2)/Polymethylmethacrylate (PMMA) Denture Base Nanocomposites: Mechanical, Viscoelastic and Antibacterial Behavior

6 Pu Y, Liu A, Zheng Y, Ye B. In vitro damage of Candida albicans biofilms by chitosan. Exp Ther Med. 2014 Sep; 8(3): 929–934. doi: [10.3892/etm.2014.1839]

7 Wang H, Xian G, Li H.Grafting of titanium dioxide to flax fibers and the enhancement of mechanical properties of the flax fiber/epoxy composite. Composites: Part A 76 (2015).

8 Torr MK, Chittenden C, Franich AR, Kreber B. Advances in understanding bioactivity of chitosan and chitosan oligomers against selected wood-inhabiting fungi. Holzforschung, Vol. 59, pp. 559–567, 2005.

9 Anehosur GV, Naik MG, Kulkarni R, Nadiger RK, K Lekha. Antifungal effect on Denture base resins using visible light activated titanium oxide synthesized by two different techniques. Journal of Advanced Oral Research / Jan-Apr 2016 /Vol. 7No. 1.

10 Ing LY, Zin MN, Sarwar A, Kataf H. Antifungal activity of Chitosan Nanoparticles and Correlation with their Physical Properties. International Journal of Biomaterials Volume 2012, Article ID 632698, 9 pages.http://dx.doi.org/10.1155/2012/632698

11 Sato W, Yoshida Y, Komasa S, Hasegawa Y, Okazaki J. Antimicrobial effect of Titanium Hydroxyapetite In Denture Base Resin. Appl. Sci. 2018, 8, 963; doi:10.3390/app8060963

12 Gad M M, Abualsaud R. Behavior of PMMA Denture Base Materials Containing Titanium Dioxide Nanoparticles:A Literature Review. International Journal of BiomaterialsVolume 2019, Article ID 6190610,14 pages. https://doi.org/10.1155/2019/6190610

13 Almeida DM, Attik N, Amalric J, Brunon C, Renaud F, Abouelleil H etal. Chitosan coating as an antibacterial surface for biomedical applications. PLoS One v.12(12); 2017. doi: [10.1371/journal.pone.0189537]

14 Jorgensen EB. Clinical aspects of Candida infection in denture wearers. JADA, Vol. 96, March 1978.

15 Kuroiwa A, Nomura Y, Ochiai T, Sudo T, Nomoto R, Hayakawa T etal. Antibacterial, Hydrophilic Effect and Mechanical Properties of Orthodontic Resin Coated with UV-Responsive Photocatalyst. Materials 2018, 11, 889; doi:10.3390/ma11060889. www.mdpi.com/journal/materials

16 Wieckiewicz M, Wolf E, Richter G, Meissner H, Boening K. New Concept of Polymethyl Methacrylate (PMMA) and Polyethylene Terephthalate (PET) Surface Coating by Chitosan. Polymers 2016, 8, 132; doi:10.3390/polym8040132. www.mdpi.com/journal/polymers

17 Bahador A, Khalil S, Pourakbari B, Ghorbanzadeh R, Kassae ZM, Moghadam OS etal. Photocatalytic Effects of Acrylic Resins Incorporated with Nano-titanium Dioxide on Planktonic and Biofilm Growth of Four Cariogenic Bacteria. Annual Research & Review in Biology 4(17): 2695-2708, 2014.

18 Walczak K, Thiele J, Geisler D, Boening K, Wieckiewicz M. Effect of Chemical Disinfection on Chitosan Coated PMMA and PETG Surfaces—An In Vitro Study. Polymers 2018, 10, 536; doi:10.3390/polym10050536. www.mdpi.com/journal/polymers

19 Zaharia A, Ghisman VP, Corina LS, Musat V. Thermal, Morphological and Structural Characterization of Chitosan-Modified Hybrid Materials for Prosthodontics. REV.CHIM.(Bucharest) 67, No. 10, 2016

An in vitro evaluation of effects of packaged fruit juices on various tooth coloured restorative materials and dental enamel

*Twinkle M. Alex, **A. Devadathan, *** Baby James, **** Jose Jacob, *****Manuja Nair

Abstract

As lifestyles have changed through the decades, the total amount and frequency of consumption of acidic juices have also increased. Acidic drinks and food are major exogenous source for dental erosion, affecting not only the teeth but also reducing the clinical performance and durability of dental restorations. When a dietary acidic challenge acts for long enough, a clinically visible erosive defect occurs.

Aim: To analyze alterations of surface topography of tooth and tooth coloured restorations by packaged fruit juices.

Materials and methods: 30 extracted non-carious premolars were selected, cleaned and stored in normal saline at room temperature. Buccal and lingual halves were obtained and embedded in acrylic blocks. The specimens were divided into 3 groups. Group 1 the control group of dental enamel and groups 2 and 3 cavities prepared of size 3x5mm and restored with composite and RMGIC respectively. Each group was further subdivided based on the type of packaged fruit juice (Frooti and Real Grape Juice) in which they were immersed for 14 days. The baseline and post immersion changes of the surface topography were measured using surface profilometer.

Results: The change in average surface roughness showed statistically significant difference for RMGIC ($p<0.05$), followed by tooth enamel and composite($p>0.05$).

Conclusion: The change in average surface roughness was highest in RMGIC followed by tooth enamel and then composite. Frooti showed the highest erosive potential when compared with Real Grape juice.

Key words: Composite, Dental erosion, Enamel, RMGIC, surface roughness.

KDJ 2019 | Vol. 42 | No. 1 | Pg 17-21

Introduction

Dental erosion has been increasingly seen as the most common cause of tooth surface loss[1,2]. Early reports of erosion were made by Darby in 1892 and Miller in 1907[3]. According to Pindborg, 1970 *dental erosion* is defined as the loss of tooth tissue by a chemical process not involving bacteria[4]. As lifestyles have changed through the decades, the total amount and frequency of consumption of packaged juices have risen sevenfold[4]. When a dietary acidic challenge acts long enough, a clinically visible erosive defect occurs. Under acidic conditions, not only the teeth but all dental restorative materials have shown degradation over time[5] thus reducing the clinical performance and durability of dental restorations[6].

Aim

To analyze alterations of surface topography of tooth and tooth coloured restorations by packaged fruit juices.

Materials and methods

30 extracted non-carious premolars were selected, cleaned and stored in normal saline at room temperature. Crowns were separated from root. Buccal and lingual halves were obtained and embedded in acrylic blocks of size 20x20x15mm.

The specimens were divided into 3 groups (n= 60). Group 1 the control group of dental enamel. In group 2 and 3 cavities prepared of size 3x5mm and restored with composite (Tetric N-Ceram T2 shade) and RMGIC (GC Light Cured Universal Restorative A3) respectively. Each group was further subdivided (n=10) based on the type of packaged fruit juice (Mango Frooti and Real Grape juice) in which they were immersed. pH of each experimental drink was measured using Digital pH meter.

*PG student, **Professor and Head, *** Professor, ****Associate Professor, *****Reader, Department of Conservative Dentistry and Endodontics, Pushpagiri College of Dental Sciences, Thiruvalla • Corresponding Author: Dr. Twinkle M. Alex, E-mail: drtwinklemaryalex@gmail.com

GROUPS	SUB-GROUPS	
(n= 20)	a. Rèal Grape Juice	b. Frooti
Group 1- Enamel	10	10
Group 2- Composite	10	10
Group 3- RMGIC	10	10

Baseline surface roughness i.e., Ra (Average surface roughness) was measured for specimens in each group using Handysurf (Carl Zeiss) surface profilometer. The reading was obtained by moving the tip of stylus transversely on the exposed surface of specimen. 10 samples of each sub group were placed in 6 separate airtight plastic containers carefully labeled with each drink. Each plastic container was filled with 100ml of respective drink. The containers with specimen and drinks were stored at 37°C for a total period of 14 days. The drinks were changed daily for 14 days. At the end of 14 days, the average surface roughness (Ra) of each sample was evaluated again.

► Results

The data were analyzed and presented as Mean and SD for baseline and 14 days after storage in packaged juices. Independent sample t-test and paired sample t-test were done to compare the surface topography of the samples at baseline and post immersion. All hypotheses were tested at 0.05 level of significance. The mean average surface roughness of pre- and post immersion samples at baseline and after 14 days was statistically significant between the groups and within the groups.

When comparison was done between the groups after 14 days of immersion, group 3 (RMGIC) immersed in Frooti with mean value of 0.58 µm showed the highest surface roughness when compared to group 2 (composite) immersed in Frooti with a mean value of 0.41 µm that was statistically significant ($p<0.05$). When comparing group 3 (RMGIC) immersed in Real grape juice with mean value of 0.51 µm showed the highest surface roughness when compared to group 2 (composite) immersed in Real grape juice with a mean value of 0.36 µm that was statistically significant ($p<0.05$).

When comparison was done within the group, mango frooti showed greater surface roughness than Real grape juice for all 3 groups at baseline (group1- 0.02 µm, group2- 0.13 µm and group3- 0.40 µm) and also after 14 days (group1- 0.66 µm, group2- 0.41 µm and group3- 0.58 µm) of immersion.

Table 1: Comparison of surface roughness (Ra) at Baseline and Final (after 14 days of immersion).

		group	Mean (µm)	Std. Deviation	P value	Sig
Group 1 (Enamel)	Base line	Grape	.2080	.01483	.874	p>0.05
		Mango	.2060	.02302		
	Final	Grape	.4640	.05899	.000	P<0.01
		Mango	.6660	.04219		
Group 2 (Composite)	Base line	Grape	.1200	.01581	.753	p>0.05
		Mango	.1340	.03847		
	Final	Grape	.3680	.02950	1.26	p>0.05
		Mango	.4160	.07925		
Group 3 (RM GIC)	Base line	Grape	.4100	.01732	.489	p>0.05
		Mango	.4000	.02550		
	Final	Grape	.5160	.03847	.04	P<0.05
		Mango	.5860	.05459		

Enamel in Frooti after 14 days of immersion showed highest (0.66 µm) change in average surface roughness. Composite in Real Grape juice showed the least (0.36 µm) change in surface roughness.

Discussion

Erosion was derived from Latin verb 'Erodere erosi, Erosum (to gnaw to corrode) described as the gradual destruction of surface of something, usually by electrolytic or chemical process[7]. Dental erosion is a multifactorial disease that is highly influenced by habits and lifestyles. One among the factor that determines the durability of dental restorative materials in the oral cavity is its resistance to dissolution or disintegration.

Beverages with lower pH has more erosive effect, however, additional factors such as type, concentration, calcium chelating properties, amount of acid, exposure time and temperature, buffering capacity of saliva contribute to enamel dissolution

Table 2: Comparison of Baseline and Final in the Real Grape juice sub-group

		Mean(µm)	Std. Deviation	P value	Sig
Group 1 (Enamel)	Base line	.2080	.01483	.001	P<0.05
	Final	.4640	.05899		
Group 2 (Composite)	Base line	.1200	.01581	.000	P<0.05
	Final	.3680	.02950		
Group 3 (RM GIC)	Base line	.4100	.01732	.004	P<0.05
	Final	.5160	.03847		

Table 3: Comparison of Baseline and Final in the Frooti sub-group

		Mean (µm)	Std. Deviation	P value	Sig
Enamel	Base line	.2060	.02302	.000	P<0.01
	Final	.6660	.04219		
Composite2	Base line	.1340	.03847	.000	P<0.01
	Final	.4160	.07925		
RM GIC3	Base line	.4000	.02550	.001	P<0.05
	Final	.5860	.05459		

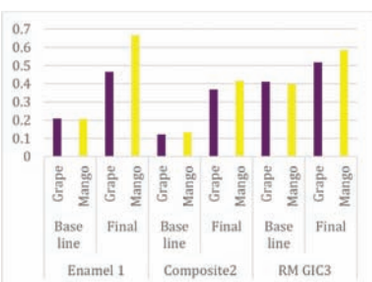

Graph 1: Comparison of surface roughness (Ra) at Baseline and Final (after 14 days of immersion).

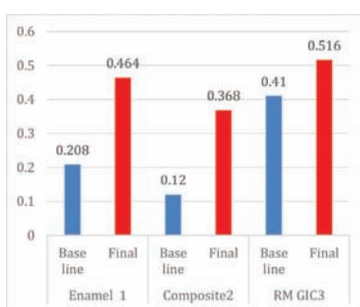

Graph 2: Comparison of Baseline and Final in the Real Grape juice sub-group

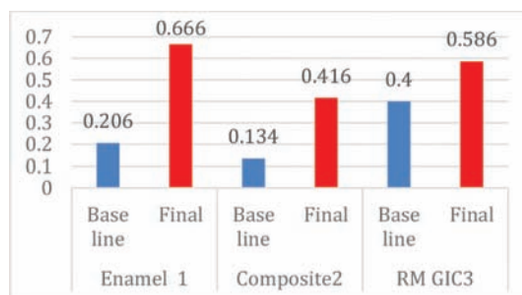

Graph 3: Comparison of Baseline and Final in the Frooti sub-group

in the oral cavity[4].

In our study we used two commonly used packaged fruit juices, i.e. Frooti and Réal Grape juice. As the pH of most beverages are below 3.5 and enamel dissolution occur below 4.24 pH value[8,9]. pH of Frooti (3.51) and Réal Grape juice (2.76) which was well below the critical pH at which enamel dissolution occurs. In this study we used 2 restorative materials, i.e. RMGIC and composite to evaluate the surface roughness after immersing for 14 days in Frooti and Réal Grape juice.

Immersion protocol of 14 days taken in the study was derived based on daily consumption of 25 ounces of soft drinks with residence time of 20 seconds in mouth before salivary clearance, thus making an annual soft drink exposure to enamel approximately 90,000 seconds i.e., 25 hours per year. Thus testing period of 14 days (350 hours) is comparable to 14 years of soft drink consumption[8].

Profilometer is chosen as the method to assess the surface roughness of eroded specimens as it has sufficient sensitivity to investigate early tooth tissue loss produced by limited exposure to acid[10]. Average surface roughness for RM GIC was highest followed by tooth enamel and lowest for composite. According to the study by Attin et al. in 2005, it's stated that dissolution of GIC in low pH drinks could be result from dissolution of the siliceous hydrogel layer[11].

After 14 days of immersion RMGIC in Frooti have showed the highest Ra value (0.58µm) and composite in Real grape juice had shown the least Ra value (0.36µm).

The significant surface roughness of the RM GIC could be due to the glass ionomer consisting of glass particles in a hydrogel matrix. In acidic solutions, H+ ions of citric acid diffuse into the glass ionomer component and replace metal cations in the matrix. These free cations then diffuse outward and are released from the surface causing surface roughness. As the metal cations in the matrix decreases, more ions would be extracted from the surrounding glass particles, causing them to dissolve thus continuously increase surface roughness[12,13].

Consequently the material would present a rough surface with voids and undissolved glass particles. Prolonged exposure of the glass ionomer materials to low pH drinks would result in higher surface roughness[12]. The pH value, buffering capacity, type of acid, calcium and phosphate content of a beverage determines its driving force for tooth mineral dissolution[14]

The surface roughness of composite is due to the presence of the resin matrix, which softens with exposure to citric acid, lactic acid, heptanes and 50% ethanol-water solution. Also the filler content has been correlated with the depth of polymerization, color stability, hardness, compressive strength, and stiffness. Less filler content counts to more surface degradation[12]. When exposed to lower pH, fillers tend to fall out from resin materials and the matrix component decomposes[15,16]. Han et al. in 2008 observed a relationship between filler volume and the surface degradation of resin and also distribution density of fillers on resin surface was related to the surface degradation. This means that the higher is the filler loading, the less is the surface degradation[17]. Therefore the lowest change in surface roughness of composite is due to more filler content and the presence of silane coupling agent, which bond the filler chemically to resin matrix, which may account for their hydrolytic stability[18].

According to the studies by Yap et al 2000[18], Han et al 2008[17], Karda et al 2016[8] composite showed the least surface roughness in comparison to other restorative materials,.

The initial pH value alone could not give the correct indication about the erosive potential of the drink as it was also influenced by the underlying buffering capacity[19]. Exposures to these drinks for long periods erode the tooth enamel and the resin material as well. Hence slightly greater erosive potential of Frooti over Réal Grape juice that has a lower pH suggests the influence of other factors as well.

► Conclusion

Within the limits of the study and from the results obtained, it can be concluded that frooti showed the highest erosive potential when compared to Real Grape juice. It was also concluded that RM GIC showed highest surface roughness when compared to composite.

► Bibliography:

1. Hengtrakool C, Kukiattrakoon B, Kedjarune-Leggat U. Effect of Naturally Acidic Agents on Microhardness and Surface Micromorphology of Restorative Materials. European Journal of Dentistry. 2011;12.
2. Gonçalves GKM, Guglielmi C de AB, Corrêa FNP, Raggio DP, Corrêa MSNP. Erosive potential of different types of grape juices. Brazilian Oral Research. 2012 Jul 19;26(5):457–63.
3. West NX, Maxwell A, Hughes JA, Parker DM, Newcombe RG, Addy M. A method to measure clinical erosion: the effect of orange juice consumption on erosion of enamel. Journal of Dentistry. 1998 May;26(4):329–35.
4. Edwards M, Creanor SL, Foye RH, Gilmour WH. Buffering capacities of soft drinks: the potential influence on dental erosion. Journal of Oral Rehabilitation. 1999 Dec;26(12):923–7.
5. Rios D, Honório HM, Francisconi LF, Magalhães AC, Machado MA de AM, Buzalaf MAR. In situ effect of an erosive challenge on different restorative materials and on enamel adjacent to these materials. Journal of Dentistry. 2008 Feb;36(2):152–7.
6. Fatima N, Abidi SYA, Qazi F-U-R, Jat SA. Effect of different tetra pack juices on microhardness of direct tooth colored-restorative materials. The Saudi Dental Journal. 2013 Jan;25(1):29–32.
7. Imfeld T. Dental erosion. Definition, classification and links. European Journal of Oral Sciences. 1996 Apr;104(2):151–5.

8. Karda B. To Analyse the Erosive Potential of Commercially Available Drinks on Dental Enamel and Various Tooth Coloured Restorative Materials – An In-vitro Study. Journal Of Clinical And Diagnostic Research [Internet]. 2016[cited 2018 Dec 26]
9. Rytömaa I, Meurman JH, Koskinen J, Laakso T, Gharazi L, Turunen R. In vitro erosion of bovine enamel caused by acidic drinks and other foodstuffs. European Journal of Oral Sciences. 1988 Aug;96(4):324–33.
10. Grenby TH. Methods of assessing erosion and erosive potential. European Journal of Oral Sciences. 1996;104(2):207–14.
11. Attin T, Weiss K, Becker K, Buchalla W, Wiegand A. Impact of modified acidic soft drinks on enamel erosion. Oral Diseases. 2005 Jan;11(1):7–12.
12. C Maganur P, R Prabhakar A, Satish V, Namineni S, Kurthukoti A. Erosive Effect of Soft Drink and Fresh Fruit Juice on Restorative Materials. Patil S, editor. World Journal of Dentistry. 2013 Jan 15;4:32–40.
13. Maganur P, Satish V, Prabhakar A, Namineni S. Effect of Soft Drinks and Fresh Fruit Juice on Surface Roughness of Commonly used Restorative Materials. Marwah N, editor. International Journal of Clinical Pediatric Dentistry. 2015;8:1–5.
14. Shelke S, Masih S, Singh N, Thomas AM. The Impact Of Modified Fruit Juice On Enamel Microhardness: An In-Vitro Analysis. :8.
15. Abu-Bakr NH, Han L, Okamoto A, Iwaku M. Effect of Alcoholic and Low-pH Soft Drinks on Fluoride Release from Compomer. Journal of Esthetic and Restorative Dentistry. 2000 Mar;12(2):97–104.
16. Poggio C, Dagna A, Chiesa M, Colombo M, Scribante A. Surface roughness of flowable resin composites eroded by acidic and alcoholic drinks. Journal of conservative dentistry: JCD. 2012;15(2):137.
17. Han L, Okamoto A, Fukushima M, Okiji T. Evaluation of Flowable Resin Composite Surfaces Eroded by Acidic and Alcoholic Drinks. Dental Materials Journal. 2008;27(3):455–65.
18. Yap AU, Low JS, Ong LF. Effect of food-simulating liquids on surface characteristics of composite and polyacid-modified composite restoratives. Operative Dentistry. 2000;25(3):170–176.
19. Grenby TH, Phillips A, Desai T, Mistry M. Laboratory studies of the dental properties of soft drinks. British Journal of Nutrition. 1989 Sep;62(02):451.

Versatile ways for orthodontic intrusion of anterior teeth

* Mohamed Nayaz VP. **P.G. Francis, *** Vincy Antony Margaret

Abstract

Dental intrusion often constitutes an integral part of comprehensive orthodontic treatment. The ability of a fixed orthodontic appliance to intrude maxillary anterior teeth is limited when compared to moving teeth in the sagittal plane. However in recent years, successful orthodontic intrusion has been achieved with Utility arch, 3-piece intrusion arch, Connecticut intrusion arch, K-SIR arch (Kalra-Simultaneous Intrusion and Retraction) and Reverse curved Nitinol arch wires. The advent of skeletal anchorage has revolutionized the concept of stationary anchorage, and has made complex tooth movements easier. With implant assisted orthodontics, some tooth movements that were considered difficult previously can now be carried out easily. Intrusion of maxillary anteriors is one such example.

Keywords: Dental intrusion, Intrusion arch, Skeletal anchorage

KDJ 2019 | Vol. 42 | No. 1 | Pg 22-25

► Introduction

Deep bite is one of the more frequently seen malocclusions next to crowding. It can occur along with other associated malocclusions and is said to be one of the most damaging malocclusions. Untreated deep bite can cause increased anterior crowding, maxillary dental flaring, periodontal problems and temporomandibular joint problems. The management of this problem demands a careful diagnostic analysis, treatment plan, and selection of appropriate treatment therapy. Deep bite can be treated orthodontically by intrusion or flaring of the incisors, extrusion or passive eruption of the buccal segments, or a combination of these.

Intrusion of anterior teeth often constitutes an integral part of orthodontic treatment in order to improve sagittal and vertical incisor relationships, to correct interincisal angle and consequently, the gingival line and restore the esthetics of smiling.[1] For many years, dental intrusion was considered impossible or problematic and was associated with numerous side-effects on the periodontium and cementum (root resorption)[1]. However, in recent years successful orthodontic intrusion has been clinically documented and is considered a safe procedure, provided that the magnitude and direction of forces are carefully monitored.

► Types of intrusion

Relative intrusion

It is achieved by preventing eruption of the incisors while growth provides vertical space into which the posterior teeth erupt. It can be achieved with continuous archwires by placing a reverse curve of Spee in the mandibular arch wire, and an exaggerated curve of Spee in the maxillary arch wire. Relative intrusion of the incisors is accomplished by labial tipping of the incisors and extrusion of other teeth in the arch, without any actual intrusion (Fig. 1).[2]

Absolute intrusion

Here there is pure intrusion of the incisors without extrusion of the posterior teeth. Light continuous force directed toward the tooth apex is the key to successful intrusion. The diagram shows incisors being intruded, using the molars as anchorage (Fig. 2). Pure absolute intrusion is preferably accomplished with the use of mini-implants.[2]

► Classification of appliances

Relative intrusion	Absolute intrusion
Anterior bite plane Reverse curve of Spee Utility arches Three-piece intrusion arch Connecticut intrusion arch K-SIR arch	J-Hook headgear Temporary skeletal anchorage

* P.G. Student, ** Professor and HOD, ***Professor, Dept. of Orthodontics and Dentofacial Orthopedics, MES Dental College, Perinthalmanna
`• Corresponding Author: Dr. Mohamed Nayaz VP, E-mail: mhmdnayazvp@gmail.com

Utility arch

The utility arch was introduced by Mc Namara[3] in the year 1986 and has been recommended for the resolution of a variety of clinical conditions. The most frequent application has been for leveling the curve of Spee and reduction of overbite through incisor intrusion.[3] The utility arch is usually fabricated from a continuous arch wire inserted into the edgewise brackets on the incisors and the maxillary or mandibular molars. For convenience and comfort, it is stepped in a gingival direction between the incisors and molars to bypass the buccal occlusion. Avoiding engagement of the premolars and canines results in improved load deflection properties because of the length of free wire existing between the segments at each end of the appliance.[3] The utility arch is activated for incisor intrusion by placing tip-back bends mesial to the molar tubes.[3] After activation, a light continuous force is delivered by the long lever arm from the molars to the incisors.

Biomechanics

Engaging the utility arch will produce approximately 25g of force on each of the lower incisors – a force level considered ideal for lower incisor intrusion.[3] The overall effect is an intrusion and possible torquing of the lower incisors, as well as a tipping back of the lower molars (Fig. 3).[3]

With an .018" appliance, the recommended wire for the mandibular arch is .016" x .016" or .016" x .022" Blue Elgiloy (not heat-treated).[3] For most maxillary arches, .016" x .022" Blue Elgiloy is recommended. With an .022" appliance, .019" x .019" Blue Elgiloy can be used in either arch.[3] When using utility arches in combination with full arch appliances, it is necessary to have auxiliary tubes in a gingival position on the first molar bands. In a pre-orthopedic phase of treatment when the buccal segments are not banded, the main buccal tube or bracket on the first molar can be used to anchor the utility arch posteriorly.[3]

Here there is a 5mm space between the anterior border of the auxiliary tube and the posterior vertical step of the utility arch (Fig. 4). This allows a slight retrusive activation of the arch to be made by pulling the wire posteriorly and then twisting the end of the arch gingivally.[3] Any type of utility arch can be activated for an intrusive movement by placing an occlusally directed gable bend in the vestibular segment.[3]

Three piece intrusion arch

This was introduced by Bhavna Shroff in the year 1995.[4] She used the principles of the segmented arch technique as described by Burstone in the year 1988.[5] Segmented arch mechanics uses different wire cross sections rather than continuous wires.[6] The advantage of using such an approach is that it is possible to develop a precise and predictable force system between an anterior segment (incisors) and a posterior segment (premolar and molars) enabling pure intrusion of the anterior teeth and control of their axial inclinations. Movement of the posterior segment is also well controlled.[7] Consequently, constant levels of force can be maintained, and the moment to force ratio (M/F) at the centers of resistance can be easily regulated to produce the desired tooth movements (Fig. 5).

After satisfactory alignment of the premolars and molars, passive segmented wires (0.017" x 0.025" stainless steel) are placed in the right and the left posterior teeth for stabilization. A precision stainless steel transpalatal arch (0.032" × 0.032") placed passively between the first maxillary molars consolidates the posterior unit consisting of right and left posterior teeth.[8] Canines may be retracted separately and incorporated into the buccal segments or left at their initial positions.[9,10] The next stage of treatment will involve the simultaneous intrusion and retraction of the incisor segment. To design the appliance optimally to obtain the desired force system, the position of the

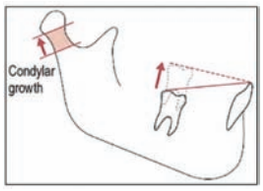

Fig. 1 Relative intrusion

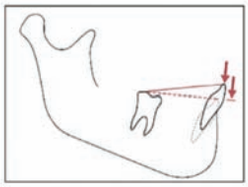

Fig. 2: Absolute intrusion

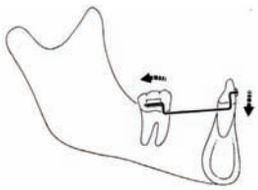

Fig. 3 Effect of intrusive force on mandibular incisors: incisors are intruded and torqued while molar is tipped posteriorly.

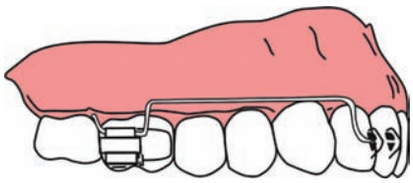

Fig. 4 Intrusion utility arch with posterior vertical step 5-8 mm anterior to auxiliary tube.

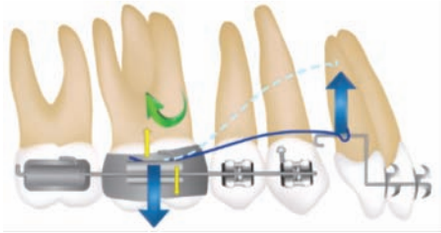

Fig. 5 Mechanics of three piece intrusion arch.

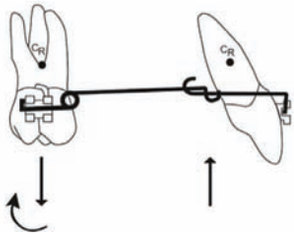

Fig. 6 Diagramatic representation of three-piece base arch. The anterior segment extends 2 to 3 mm distal to the center of resistance (CR) of the anterior teeth. Force acts through center of resistance.

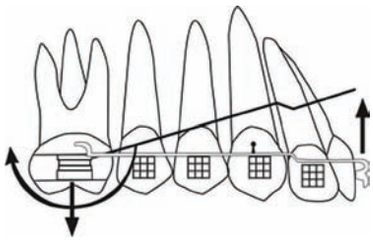

Fig. 7 Intrusion force system consists of anterior intrusive force, posterior extrusive force, and posterior tipback moment.

center of resistance of the anterior teeth should be estimated on a lateral cephalometric x-ray film.[4]

Biomechanics

In clinical situations where incisors are proclined, the center of resistance of the anterior segment lies further lingual to the incisor crowns. A three-piece base arch is used to intrude the anterior segment (Fig 6). A heavy stainless steel segment (0.017" x 0.025" or larger) with distal extensions below the center of resistance of the anterior teeth is placed passively in the anterior brackets. The distal extension ends 2 to 3 mm distal to the center of resistance of the anterior segment. The intrusive force is applied with a 0.017" × 0.025" TMA tip-back spring.[5]

The overall force system obtained is an intrusive force anteriorly and an extrusive force posteriorly associated with the tip back moment. The design of this appliance enables low friction sliding to occur along the distal extension of the anterior segment during space closure. The application of a light, distal force delivered by a Class I elastic to the anterior segment is used to alter the direction of the intrusive force on the anterior segment. This appliance design allows the application of the intrusive force to get true intrusion of the incisors along their long axes.[4]

Connecticut Intrusion Arch (CIA)

This was introduced by Nanda[11] in the year 1998. The CIA is fabricated from a nickel titanium alloy to provide the advantages of shape memory, spring back and light continuous force distribution. It incorporates the characteristics of the utility arch as well as those of the conventional intrusion arch.[12] The CIA is preformed with the appropriate bends necessary for easy insertion and use.

The intrusion arches are available in two wire sizes: .016" x .022" and .017" x .022". The maxillary and mandibular versions have anterior dimensions of 34mm and 28mm, respectively.[12] The bypass, located distal to the lateral incisors, is available in two different lengths to accommodate for extraction, non-extraction, and mixed dentition cases.[12] It is recommended to use triple tubes on the maxillary molars and double tubes on the mandibular molars.[12] An .018" x .022" auxiliary tube allows the CIA to be used in conjunction with other wires. Piggyback wires and posterior segments may be used where necessary. Transpalatal bars may be added to maintain buccal width or for anchorage purposes.

Biomechanics

The CIA's basic mechanism for force delivery is a V-bend calibrated to deliver approximately 40-60g of force. Upon insertion, the V-bend lies just anterior to the molar brackets.[12] When the arch is activated, a simple force system results, consisting of a vertical force in the anterior region and a moment in the posterior region (Fig. 7).

Incisor intrusion requires about 50g of force directed apically along the center of resistance. Although the CIA is calibrated for this purpose, slight differences in placement may alter the force system during activation. The moment created at the molar will also vary, according to the amount of force at the incisors multiplied by the distance to the molars.[12]

K-SIR Arch (Kalra Simultaneous Intrusion and Retraction)

The K-SIR (Kalra Simultaneous Intrusion and Retraction) archwire is a modification of the segmented loop mechanics of Burstone and Nanda[7,13] and was introduced by Varun Kalra[13] in the year 1998. It is a continuous .019" × .025" TMA archwire with closed 7mm × 2mm U-loop at the extraction sites (Fig. 8).[14]

Biomechanics

To obtain bodily movement and prevent tipping of the teeth into the extraction spaces, a 90° V-bend is placed in the archwire at the level of each U-loop (Fig. 9 A).[14] The V-bend when centered between the first molar and canine during the space closure, creates two equal and opposite moments to counter the moments caused by the activation forces of the closing loops (Fig. 9 B).[14]

A 60° V-bend located posterior to the center of the interbracket distance produces an increased clockwise moment on the first molar (Fig. 10 A) which augments molar anchorage

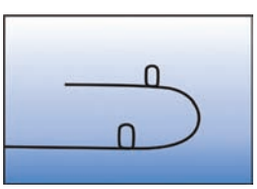

Fig. 8 K-SIR arch wire: .019" × .025" TMA archwire with closed U-loops 7 mm long and 2 mm wide.

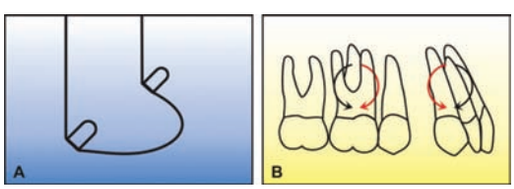

Fig. 9 (A) 90° bend placed in archwire at the level of U-loops. **(B)** Centered 90° V-bend creates two equal and opposite moments (red) that counter tipping moments (green) produced by activation forces.

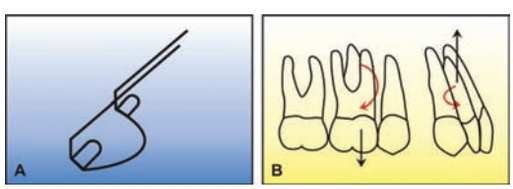

Fig. 10 (A) Archwire with off-center 60° V-bend placed about 2 mm distal to U-loop. **(B)** Off-center V-bend creates greater moment on molar, increasing molar anchorage and intrusion of anteriors.

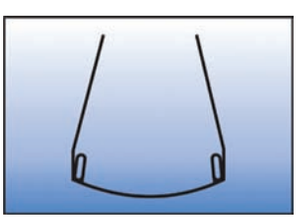

Fig. 11 20° antirotation bend placed in archwire just distal to U-loop.

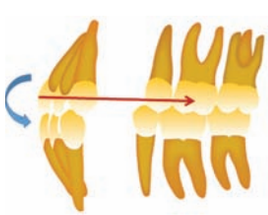

Fig. 12 Force vectors seen during routine fixed orthodontic treatment

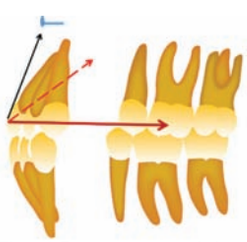

Fig. 13 Force vectors seen during intrusion with midline implant

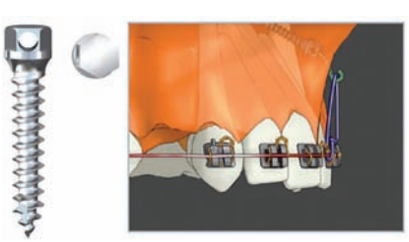

Fig. 14 Midline mini implant

as well as the intrusion of anterior teeth (Fig. 10 B).[14]

To prevent the buccal segment from rolling mesiolingually due to the forces produced by the loop activation, a 20° antirotation bend is placed in the archwire just distal to each U-loop (Fig. 11).[14]

A trial activation is performed outside the mouth. The trial activation releases the stress built up from bending the wire and thus reduces the sensitivity of V-bends. The archwire is activated about 3mm, so that the mesial and distal legs of loop are barely apart.[14]

Mini implant

In patients with dentoalveolar protrusion and increased incisor visiblity at rest, simultaneous intrusion and retraction of anteriors is indicated. Conventional methods of orthodontic retraction usually produces slight extrusion of anteriors there by worsening the preexisting increased incisor visiblity. This is because of the moment which is created by force acting away from the center of resistance (Fig. 12).

Biomechanics

Placement of miniscrew beneath the ANS to apply an intrusive force along with the conventional retraction force will redirect the resultant force closer to the center of resistance of anterior segment there by obviating the undesirable extrusion and providing true intrusion of anterior segment (Fig. 13).[15]

Creekmore and Eklund[16] were the first to report intrusion of incisors using metal implant. They placed a surgical vitallium bone screw just below the anterior nasal spine and used elastic thread to elevate the maxillary central incisors (Fig. 14). Recently several reports have documented the use of mini screw to correct gummy smile through intrusion of upper incisors.

Kim et al[17] applied a segmental intrusive force between the maxillary central incisors by using mini implants with segmental wires. Lin et al[18] reported the use of TADs in combination with periodontal surgery for correcting a gummy smile. In our Department, studies comparing mini implant assisted intrusion and K-SIR arch have revealed significant anterior intrusion with mini implants.

► Conclusion

The correction of deep overbite requires careful differential diagnosis and the determination of which teeth must be intruded or extruded for proper correction. Therefore, the mechanics for treatment can differ radically from one patient to another. The key to successful correction is not only the proper treatment plan, but precise mechanics to achieve the predetermined treatment plan goals. Not all patients with deep overbite should be treated with the same mechanics. For bite opening, both mini implants and conventional methods of intrusion have been found to be effective. The conventional methods can result in extrusion of molars which prevents its use in high angle cases with deep bite and increased incisal exposure. Deep bite correction with mini implants results in effective bite opening through true intrusion of incisors with minimal or no changes in molars and also patient compliance was not required. Hence, mini implants are an ideal choice for bite opening in such cases. The most important drawback of intrusion mechanics is root resorption.[19,20] Familial studies show that a person's genotype accounts for about two-thirds of the variation in the extent of periapical resorption. The other causes for root resorption are due to heavy force, occlusal trauma and this could be also due to abnormal tongue and lip functions. Greg Costopolis et al[19] also stated that with low force levels good amount of overbite reduction can be achieved with negligible root resorption.

► Reference

1. Al-Zubair NM. Orthodontic intrusion. A contemporary review. J Orthod Res 2014;2(3):118-124.
2. Ng J, Major PW, Heo G, Flores-Mir C. True incisor intrusion attained during orthodontic treatment: A systematic review and meta-analysis. Am J Orthod Dentofacial Orthop 2005;128:212-9.
3. McNamara JA Jr. Utility arches. J Clin Orthod 1986;20:452–456.
4. Burstone CJ. Variable modulus orthodontics. Am J Orthod 1981;80(1):1-16.
5. Burstone CJ, Koenig HA. Optimizing anterior and canine retraction. Am J Orthod 1976;70:1-20.
6. Burstone CJ, Manhartsberger C. Precision lingual arches-passive applications. J Clin Orthod 1988;22(7):444-51.
7. Manhartsberger C, Morton J, Burstone CJ. Space closure in adult patients using the segmented arch technique. Angle Orthod 1989;59:205-10.
8. Burstone CJ. The segmented arch approach to space closure. Am J Orthod 1982;82(5):361-78.
9. Aras I, Tuncer AV. Comparison of anterior and posterior mini-implant-assisted maxillary incisor intrusion: Root resorption and treatment efficiency. Angle Orthod 2016;86:746-752.
10. Shroff B, Lindauer SJ, Burstone CJ, Leiss JB. Segmented approach to simultaneous intrusion and space closure: Biomechanics of the three-piece base arch appliance. Am J Orthod Dentofacial Orthop 1995;107:136-43.
11. Nanda R, Marzban R, Kuhlberg A. The Connecticut Intrusion Arch. J Clin Orthod 1998;32(12):708-15.
12. Burstone CJ. Rationale of the segmented arch. Am J Orthod 1962;48:805-22.
13. Nanda R. Biomechanics in Clinical Orthodontics. Philadelphia; W.R. Saunders company; 1996.
14. Kalra V. Simultaneous intrusion and retraction of anterior teeth. J Clin Orthod 1998;35:535-40.
15. Nishimura M, Sannohe M, Nagasaka H, et al. Nonextraction treatment with temporary skeletal anchorage devices to correct a Class II division 2 malocclusion with excessive gingival display. Am J Orthod Dentofacial Orthop. 2014;145(1):85–94.
16. Creekmore TD, Eklund MK. The possibility of skeletal anchorage. J Clin Orthod. 1983;17:266–269.
17. Kim TW, Kim H, Lee SJ. Correction of deep overbite and gummy smile by using a mini implant with a segmented wire in a growing Class II division 2 patient. Am J Orthod Dentofacial Orthop. 2006;130:676–685.
18. Lin JC, Liou EJ, Bowman SJ. Simultaneous reduction in vertical dimension and gummy smile using miniscrew anchorage. J Clin Orthod. 2010;44:157–170.
19. Costopoulos G, Nanda R. An evaluation of root resorption incident to orthodontic intrusion. Am J Orthod Dentofac Orthop. 1996;109:543–548.
20. Harris EF. Root resorption during orthodontic therapy. Semin Orthod. 2000;6:183-194.

Redefining the role of Rugae in Supporting/Stabilizing Complete Dentures – A Review

*Anjana Rajagopalan, **Prasanth Viswambharan

Abstract

Removable Prosthesis in general and Complete Dentures in particular are regarded as the most challenging treatment modality undertaken in routine dental practice. Rehabilitation of a completely edentulous patient doesn't end with the insertion of the prosthesis. Periodic recalls and continued follow ups are mandatory for ensuring long term success of the treatment. A thorough understanding of the basic anatomy of relevant oro-facial structures makes the treatment outcome more predictable. Role of rugae in providing support and/or stability for complete dentures is subjected to controversy mainly because of the contradictory statements found in various text books. This article is aimed at clearly defining the role of rugae in providing support / stability for a complete denture.

Keywords: Rugae, Denture Support, Denture Stability, Selective Pressure Theory

KDJ 2019 | Vol. 42 | No. 1 | Pg 26-28

► Introduction

Role of rugae in providing support and/or stability for complete dentures is subjected to controversy mainly because of the contradictory statements found in various text books and scientific writings. Some authors describe Rugae as a secondary stress bearing area (Fig. 1). At the same time proponents of 'selective pressure impression theory', the most accepted impression philosophy for complete dentures, advocate placing 'relief wax' over the rugae along with relief areas like incisive papilla and median palatine raphae (Fig. 2). This raises a logical and scientific question as to how a 'relieved area' can act as a 'stress bearing' zone for the prosthesis.

► Discussion

Applied Gross and Microscopic Anatomy

In broader sense the term 'Rugae' can be used to refer to a series of ridges produced by the foldings on the wall of any organ. 'Palatine rugae' or 'transverse palatine ridges', irregular and often asymmetric in humans, are ridges of mucous membrane extending laterally from the incisive papilla and the anterior part of the 'median palatine raphae'. Its core is made up of dense connective tissue layer with fine interwoven fibres[1].

Microscopically lamina propria of anterior palate presents with long papillae and thick & dense collagenous tissue. Moderate vascular supply is noted with short capillary loops. Submucosa shows dense collagenous connective tissue that attaches mucosa to periosteum forming the mucoperiosteal complex. Fat cells are packed in the antero lateral areas of hard palate. Orthokeratinized (parakeratinized in parts) stratified squamous epithelium throws into transverse palatine rugae[2]. Rugae shows long and thin rete ridges when compared to rest of the hard palate.

Intra and inter population comparisons suggest that development of rugae is coordinated with that of the palate as a whole. An association of ridge development with size of palate is suggested, which reflects local differences in rate of cell division in early embryonic life[3]. Some studies showed a

* Intern, Govt. Dental College, Trivandrum, **Associate Professor of Prosthodontics, Govt. Dental College, Alappuzha • Corresponding Author: Dr Anjana Rajagopalan, E-mail: anj26795@gmail.com

statistically significant association between rugae forms and ethnicity. The length of rugae increased significantly with age but the total number of rugae remained constant[4,5]. Palatal rugae are unique for every individual[16]. Palatal rugae shape revealed significant differences even between Indian population[7]. Curved rugae were more common in Madhya Pradesh population, but Keralites showed a wavier pattern[8]. Rugae need not be bilaterally symmetric, but can be fragmented with posterior most one being usually divided[9].

Role in Denture stability/Support

Histologically rugae do not differ much from rest of the hard palate. But connective tissue thickness is more in rugae which makes it too compressible and displaceable (Fig. 3). Relief is mandatory in rugae area to prevent its compression while impression is being made. If compressed during impression, rugae will rebound resulting in displacement of denture once the seating force is removed. This adversely affects the stability of the denture. This is similar to the effect of flabby tissues on complete denture stability, even though histologically both are different.

Keratinized epithelium, thick submucosa, firmly adhered periosteum and compact supporting bone which is perpendicular to the direction of occlusal load are considered ideal for a perfect stress bearing area. Less keratinized areas, areas with loosely attached periosteum (buccal shelf) and areas of spongy underlying bone (residual alveolar ridge) are often selected for stress bearing even though they are not theoretically ideal. Areas where submucosa is absent/thin (median palatine raphae) and areas where submucosa is too thick (rugae) are not suitable for stress bearing.

Over compressible tissues will always be displaceable, irrespective of their histology. This factor is overlooked most of the times and more emphasis is given to histology alone. Compressibility of rugae should be assessed during the intra oral examination phase of diagnosis and treatment planning procedure. Compressible tissues can never be suited for stress bearing[10] and they require relief[11]. Round end of a 'T Burnisher' can be utilized for this purpose. Long term denture wearers sometimes present with less prominent and minimally compressive rugae. Such patients do not require relief in rugae area and for them rugae can be treated as stress bearing area similar to rest of the hard palate.

Only bone can act as a stress bearing area. Since rugae with thick connective tissue rolls don't contain any core of bone inside, they can never take load transmitted by dentures. Rugae can prevent antero-posterior displacement of maxillary denture by acting like a mechanical obstacle. Stability is the only quality of maxillary denture which is marginally improved in presence of prominent rugae. This enhancement in stability will become significant only in patients with severely resorbed maxillary residual alveolar ridges. Residual alveolar ridge, otherwise, is sufficient enough to provide antero-posterior stabilization of maxillary dentures.

These observations in no way neglect the importance of rugae in complete denture construction. Restoring patients' speech is an important goal in complete denture fabrication. For those complete denture wearers, who have difficulty with phonation, incorporating rugae texture in the palatal region may prove helpful[12]. Customized rugae dentures show better results than arbitrary rugae dentures[13].

Rugae pattern may be an additional method of differentiation between the Indian males and females in forensic sciences. This may help narrow the field for identification and give results in conjunction with the other methods such as visual, fingerprints, and dental characteristics[14]. Palatal rugae is of prime importance, and can be used as a reliable guide in forensic identification. Among the proofs taken from edentulous victims, palatal rugae pattern is one of the unique and available morphological features and the patterns can be taken not only directly from the hard palate but also from the mucosal surface of the dentures[15,16]. Palatine rugae are permanent and unique stable landmarks to each person, and clinicians and scientists can use them to establish identity through discrimination[17]. It can offer near perfect identification[18]. Palatoscopy is very reliable in this regard along with Cheiloscopy[19]. Rugae identification can be very useful in identification of victims during mass disasters

Fig 1 Rugae

Fig 2 Relief in rugae area

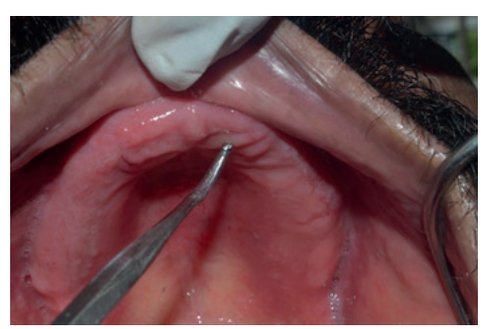

Fig 3 Checking compressibility of rugae

where charred human remains or heavily decomposed or fragmented bodies are confronted with[10].

Merkel cells (tactile epithelial cells) may become apoptotic under continuous pressure and that the sensory system may change as a response to denture wearing[21]. Mechanical compression on the palatal mucosa of rats using experimental palatal bases suggested mechanical compression of the palatal producing ischemia, and that cells in the underlying denture-supporting tissue, which includes the periosteum, synthesize HSP70 and VEGF to maintain homeostasis under these conditions[22]. This may not happen in complete denture patients because of the protection offered by the 'selective pressure impression technique', but clearly suggests that pressure on rugae can be harmful. Some authors even suggested small-opening type of palatal coverage for improved oral perception and dentures demonstrated sufficient retention[23]. All the relief wax patterns (Neil, Boucher, Murrow/Rudd/Rhoads, J J sharry, Bernad Levin and Sanath Shetty et al.), other than the one suggested by Roy Mc Gregor advocates relief in rugae area[24]. Surprisingly some authors were of the view that biological significance of palatal rugae, transverse ridges situated in the anterior part of the palate, is little understood[25].

► Conclusion

Any area if relieved, can never act as a stress bearing area. It is incorrect to consider any displaceable and compressible tissue as a stress bearing area. That is why it's logically and scientifically incorrect to consider rugae as a stress bearing area. Optimum thickness of connective tissue seems the most important of all the requirements for an ideal stress bearing area. Contribution of rugae in gaining stability for maxillary denture is negligible. Rugae, thus should routinely be treated as a relief area just like median palatal raphae and incisive papilla. Incorporating customised rugae in complete dentures play an important role in enhancing the quality of phonation. In forensic science too, customised rugae on dentures has a significant role to play in subject identification.

► References

1. G S Kumar(ed.), Orban's Oral Histology and Embryology, 13th edition, Elsevier Publishing
2. Antonio Nanci(ed.), Ten Cates Oral Histology, 8th Edition, Elsevier Publishing
3. G. Hauser, A. Daponte, M. J. Roberts, Palatal rugae, J Anat. 1989 ; 165: p 237–249
4. Sunita Kapali, Grant Townsend, Lindsay Richards, Tracey Parish, Palatal rugae patterns in Australian Aborigines and Caucasians, Australian Dental Journal 1997;42:(2):129-33
5. Shwetha K Shetty, Shalini Kalia, K Patil, Mahima VG, Palatal Rugae Pattern in Mysorean and Tibetal Populations, 2005, 16(2): p 51-55
6. English W, Robison S, Summitt J, Oesterle L, Brannon, and Morlang W, Individuality of Human Palatal Rugae, Journal of Forensic Sciences, 1988, 33(3): p 718-726
7. PreethiNayak, Ashith B.Acharya, A.T.Padmini, H.Kaveri, Differences in the palatal rugae shape in two populations of India, Archives of Oral Biology, 2007, 52(10), p 977-982
8. Aparna P, Sangeetha W, Rajkumar P, Palatal Rugoscopy : Establishing Identity, 2010, 2(1): p 27-31
9. Frans PG, van der Linden, Changes in the Position of Posterior Teeth in Relation to Ruga Points,AJO-DO, 1978, 72(2): p142-161
10. Alan B Carr, David T Brown, Mc Cracken's Removable Partial Prosthodontics, 12th Edition, Elsevier Publishing, 2013
11. JF McCord, AA Grant, Impression Making, British Dental Journal, 2000, 188, p 484-492
12. Christina A. Gitto, Salvatore J. Esposito, Julius M. Draper, A simple method of adding palatal rugae to a complete denture, JPD, 1999, 81(2): p 237–239
13. Raghavendra Adaki, Suresh Meshram, Shridevi Adaki, Acoustic Analysis and Speech Intelligibility in Patients Wearing Conventional Dentures and Rugae Incorporated Dentures, The Journal of Indian Prosthodontic Society, 2013, 13(4): p 413–420
14. A. Saraf, a S. Bedia, b A. Indurkar, c S. Degwekar, c R. Bhowate. C, Rugae Patterns as an Adjunct to Sex Differentiation in Forensic Identification, J Forensic Odontostomatol 2011;29(1):P 14-19
15. R. Poojya, C. S. Shruthi, Vaishali Mysore Rajashekar, and Aswathy Kaimal. Palatal Rugae Patterns in Edentulous Cases Are They A Reliable Forensic Marker? Int J Biomed Sci. 2015 Sep; 11(3): p 109–112
16. Goyal, Sandeep & Goyal, Sonia, Study of Palatal Rugae Pattern of Rwandan Patients Attending the Dental Department at King Faisal Hospital, Rwanda: A Preliminary Study, Rwanda Medical Journal, 70(1), 2013: 19-25
17. Manashvini S.Patil, Sanjayagouda B.Patil, Ashith B.Acharya, Palatine Rugae and Their Significance in Clinical Dentistry: A Review of the Literature, The Journal of the American Dental Association, 2008, 139(11): p 1471-147
18. Maki Ohtani et al., Indication and limitations of using palatal rugae for personal identification in edentulous cases, Forensic Science International, 2008, 176(2-3): p 178-182
19. Ines Morais Caldas, Teresa Magalhaes, Americo Afonso, Establishing identity using cheiloscopy and palatoscopy, Forensic Science International, 2007, 165(1): p 1-9
20. M.Muthusubramanian, K.S.Limson, R.Julian, Analysis of Rugae in Burn Victims and Cadavers to Simulate Rugae Identification in Cases of Incineration and Decomposition, The Journal of Forensic Odonto-Stomatology, 2005, 23(1): p 26-29
21. Ken Ishizaki et al., An Experimental Study on the Behavior of Merkel Cells under a Denture Base, Prosthodontic Research and Practice, 2003, 2(1): p 59-63
22. M Tsuruoka et al., Morphological and molecular changes in denture-supporting tissues under persistent mechanical stress in rats, Journal of Oral Rehabilitation, 2008, 35(12): p 889-897
23. Takashi Koike et al., Influence of anterior palatal coverage on perception and retention in complete dentures, The Journal of Prosthetic Dentistry, 2011, 105(4), p 272-279
24. Sanath Shetty, P. Venkat Ratna Nag, Kamalakanth K. Shenoy, The selective pressure maxillary impression: A review of the techniques and presentation of an alternate custom tray design, The Journal of Indian Prosthodontic Society, 2007, 7(1): p 8-11
25. G Hauser, A Daponte, MJ Roberts, Palatal Rugae, Journal of Anatomy, 1989, 165: p 237-249.

REVIEW

Some Unrenowned Bacteria - Associated With Periodontitis

*Varun M., **Subair K., ***Anil Melath, ****Mohammed Feroz T.P., *****Mahesh Raj V.V., *****Jilu Jessy Abraham

Introduction

Periodontitis is defined as an inflammatory disease of supporting tissues of the teeth caused by specific microorganism or group of specific microorganisms resulting in progressive destruction of periodontal ligament and alveolar bone with increased probing depth formation, recession, or both [Carranza – 12th edition]. It is estimated that more than 700 different species are capable of colonizing the adult mouth and that any individual typically harbors 150 or more different species (Moore WE, 1994). The immune-inflammatory response that develops in the gingival and periodontal tissues in response to the chronic presence of plaque bacteria results in destruction of structural components of the periodontium leading, ultimately, to clinical signs of periodontitis.

Mainly three bacterial species considered to be the etiological agents in periodontal diseases according to 1996 world workshop classification. Actinobacillus actinomycetemcomitans was considered to be a pathogen of various forms of aggressive periodontitis, while Porphyromonas gingivalis and Tannerella forsythia were considered to be important etiological agents of chronic periodontitis. Various studies proved that the oral microbiota as an ecological niche involving not only a selected few species but considering plaque as a whole and no longer individually defined but viewed as a team effort with recognition of their individual strengths and contributions in causing periodontitis[13]. Thus the periodontal pathogenesis is not pointing a specific pathogen as etiological factor, rather than pointing a group of pathogens with various structural and biochemical dissimilarities.

Current analysis of periodontal microbiology

Over the past few decades research in microbial aspect of periodontal disease mostly related to some specific pathogens. Unfortunately due to many technical difficulties research in this field is considerably decreased. The use of immunologic and molecular diagnostic tests for the identification of microorganisms independent on cultivation—such as DNA probes, polymerase chain reaction, and immunoassays—began in the 1990s made a great progress in the research field of microbiota[3]. The current concept of the periodontal pathogenesis is that periodontitis is contributed by a synergistic and dysbiotic microbial community rather than by certain specific pathogens.[2]

The following are essentially associated with periodontitis: P. gingivalis, T. forsythia, Aggregatibacter actinomycetemcomitans, Prevotella intermedia, Prevotella melaninogenica, Fusobacterium nucleatum, Parvimonas micra, Eikenella corrodens, Prevotella nigrescens, Capnocytophaga gingivalis, Treponema denticola, Treponema socranskii, Eubacterium nodatum and Campylobacter rectus.[12]

The following organisms have also been implicated as periodontal pathogens: Porphyromonas endodontalis, Prevotella denticola, Filifactor alocis, Cryptobacterium curtum, Eubacterium saphenum, Mogibacterium timidum, Prevotella corporis, Prevotella disiens, Peptostreptococcus magnus, Slackia exigua, Treponema maltophilum, Treponema sp. Smibert-3, Treponema lecithinolyticum, Treponema putidum sp. nov., Enterococcus faecalis, Escherichia coli and Bartonella sp[12]

* Post Graduate student ** Professor, *** Principal, **** Professor, ***** Post Graduate student, Dept. of Periodontics, Mahe Institute of Dental sciences and Hospital, Chalakara, Mahe. • Corresponding Author: Dr. Varun M., E-mail: ajuvarun09@gmail.com

Eubacterium nodatum

Eubacterium nodatum are obligatory anaeorbic gram positive rods with a branching often filamentous and beaded appearance occurring in clumps. Some of eubacterium species like eubacterium nodatum, eubacterium timidum and eubacterium brachy was isolated from subgingival samples taken from patients with moderate and severe periodontitis. Even though there is difficulty in their laboratory cultivation, because of the slow growing nature of the organism eubacterium considered to be the promising candidate in causing periodontitis.

Eubacteium nodatum resembles Actinomycetes species in most of its microscopic appearance. In most of the clinical specimens, Actinomycetes species the gram-positive rods, later identified as E. nodatum were approximately equal in number to the other species[1]. Nodatum, E. brachy, and E. timidum are thought to be periodontal pathogens. E. nodatum was found to be in the top two to 14 species enumerated in chronic periodontal disease. One of the characteristic features of eubacterium nodatum is its typical branching shape which helps to identify the nodatum from other species of the anaerobic gram positive rods which share certain biochemical characteristics and assachrolytic properties with nodatum[1]. There is a strong association of E. Nodatum and T. denticola with periodontitis whether in the presence or absence of high levels of the consensus pathogens[6].

Moore and Moore (1994) examined the proportions of bacterial species in subgingival plaque samples from patients with various forms of periodontitis and gingivitis, and in healthy subjects by using a roll tube cultural technique. And they found that E. nodatum was absent or low proportions in periodontal health and various forms of gingivitis, but was present in higher proportions in moderate periodontitis (2%), generalized early onset periodontitis (8%), localized juvenile periodontitis (6%), early onset periodontitis (5%) and adult periodontitis (2%).[5]

► Peptostreptococcus micros

Peptostreptococcus micros is a gram positive anaerobic coccid, even though it is considered to be normal commensally of oral cavity, it usually causes periodontal, endodontic, peritonsillar infections. It is, however, interesting to note that Gram-positive anaerobic bacteria including Peptostreptococcus were the predominant bacteria in the subgingival plaque of an adult patient with periodontal disease. Peptostreptococcus were isolated with high rates in both supragingival plaque (10/19; 52.6%) and subgingival plaque (9/19; 47.4%) (p=0.7456)4. One of the most rapid and reliable alternative method for identification of Peptostreptococcus micros in clinical samples is PCR assay, which confirm the role of Peptostreptococcus micros in the etiology of acute alveolar abscesses and adult periodontitis.[7]

Filifactor alocis

Filifactor alocis is a gram positive, fastidious anaerobic rod having trypsin like enzymatic activity as same as that of P.gingivalis and T.denticola. They show common virulence properties similar to fusobacterium. Filifactor alocis has the ability to survive in periodontal pocket. When compared with periodontally healthy individuals filifactor alocis found in elevated numbers in Aggressive periodontitis (77.8%) and chronic periodontitis (76.7%) because of its potential to withstand oxidative stress and inflammatory microenvironment provided by periodontal pocket.[2]

Filifactor alocis shows positive correlation with other seven putative pathogens forming a co-occurrence group with potential synergistic ecological pattern that was remarkably enriched in all three habitats of periodontitis patients.[8]

Solobacterium moorie

Solobacterium moorie earlier known as “Bulleidia moorei” Gram-positive, non-spore forming, obligatory anaerobic bacillus originally isolated from human feces[9] named in honor of contemporary American microbiologist W.E.C Moore. A new genus Solo bacterium is proposed for three strains, with one species, Solobacterium moorei, based on a 16S rDNA sequence divergence of greater than 12% with H. Filiformis and E Rhusiopathiae[9]. Solobacterium moorie shows much higher occurrence in dorsal surfaces of the tongue in halitosis subjects as compared to subject without halitosis together with H2S and beta galactosidase production confirms its association with halitosis.[10]

Treponema. lecithinolyticum

Treponema lecithinolyticum is a small saccharolytic spirochaete with phospholipase A and C activities associated with periodontitis and recently they were detected in infected root canals in apical periodontitis. In periodontitis and endodontic infections, the major surface protein of Treponema lecithinolyticum (MspTL) induce the production of proinflammatory mediators like interleukin (IL)-1b, IL-6 and IL-8 and intercellular adhesion molecule (ICAM)-1.[11]

► Conclusion

We attempt to describe some unframed bacteria in the pathogenesis of periodontitis. Many unrecognized periodontal pathogen remain to be identified. This paper focused on some lesser known bacteria. With the recent advancement in the cultural techniques and various other molecular techniques, many new pathogens were discovered. Researches to be continued to know structural and biochemical characteristics of the bacteria and their role in causing periodontitis. Focusing more on these unrenowned bacteria will definitely contribute more to the etiogenesis of periodontitis and there by improving

the treatment modalities in the field of periodontitis. By increasing the knowledge about the variations in microbial communities that reside within the host has contribute not only to dental sciences but also in the branch of immunology and microbiology.

► References

1. Hugoson A, Norderyd O. Has the prevalence of periodontitis changed during the last 30 years? J Clin Periodontol 2008;35 Suppl 8:338-45.
2. Kumar PS, Griffen AL, Barton JA, Paster BJ, Moeschberger ML, Leys EJ. New bacterial species associated with chronic periodontitis. J Dent Res 2003;82:338-44.
3. Paster BJ, Boches SK, Galvin JL, Ericson RE, Lau CN, Levanos VA, et al. Bacterial diversity in human subgingival plaque. J Bacteriol 2001;183:3770-83.
4. Socransky SS, Haffajee AD, Cugini MA, Smith C, Kent RL Jr. Microbial complexes in subgingival plaque. J Clin Periodontol 1998;25:134-44.
5. Haffajee AD, Socransky SS, Patel MR, Song X. Microbial complexes in supragingival plaque. Oral Microbiol Immunol 2008;23:196-205.
6. Hajishengallis G, Lamont RJ. Beyond the red complex and into more complexity: The polymicrobial synergy and dysbiosis (PSD) model of periodontal disease etiology. Mol Oral Microbiol 2012;27:409-19.
7. Ximénez-Fyvie LA, Haffajee AD, Socransky SS. Comparison of the microbiota of supra- and subgingival plaque in health and periodontitis. J Clin Periodontol 2000;27:648-57.
8. Aas JA, Paster BJ, Stokes LN, Olsen I, Dewhirst FE. Defining the normal bacterial flora of the oral cavity. J Clin Microbiol 2005;43:5721-32.
9. Kumar PS, Griffen AL, Moeschberger ML, Leys EJ. Identification of candidate periodontal pathogens and beneficial species by quantitative 16S clonal analysis. J Clin Microbiol 2005;43:3944-55.
10. Teles R, Teles F, Frias-Lopez J, Paster B, Haffajee A. Lessons learned and unlearned in periodontal microbiology. Periodontol 2000 2013;62:95-162.
11. Haffajee AD, Teles RP, Socransky SS. Association of Eubacterium nodatum and Treponema denticola with human periodontitis lesions. Oral Microbiol Immunol 2006;21:269-82.
12. Ghayoumi N, Chen C, Slots J. Dialister pneumosintes, a new putative periodontal pathogen. J Periodontal Res 2002;37:75-8.
13. Colombo AP, Boches SK, Cotton SL, Goodson JM, Kent R, Haffajee AD, et al. Comparisons of subgingival microbial profiles of refractory periodontitis, severe periodontitis, and periodontal health using the human oral microbe identification microarray. J Periodontol 2009;80:1421-32.
14. Silva-Boghossian CM, Neves AB, Resende FA, Colombo AP. Suppuration associated bacteria in subjects with chronic and aggressive periodontitis. J Periodontol 2013;84:e9-16.
15. Gomes SC, Piccinin FB, Oppermann RV, Susin C, Nonnenmacher CI, Mutters R, et al. Periodontal status in smokers and never-smokers: Clinical findings and real-time polymerase chain reaction quantification of putative periodontal pathogens. J Periodontol 2006;77:1483-90.
16. Nonnenmacher C, Dalpke A, Rochon J, Flores-de-Jacoby L, Mutters R, Heeg K. Real-time polymerase chain reaction for detection and quantification of bacteria in periodontal patients. J Periodontol 2005;76:1542-9.
17. Schlafer S, Riep B, Griffen AL, Petrich A, Hübner J, Berning M, et al. Filifactor alocis - Involvement in periodontal biofilms. BMC Microbiol 2010;10:66.
18. Dahlén G, Leonhardt A. A new checkerboard panel for testing bacterial markers in periodontal disease. Oral Microbiol Immunol 2006;21:6-11.
19. Park KK, Heuner K, Göbel UB, Yoo YJ, Kim CK, Choi BK. Cloning and characterization of a major surface protein (MspTL) of Treponema lecithinolyticum associated with rapidly progressive periodontitis. FEMS Microbiol Lett 2002;207:185-92.

Minimally invasive procedure for the removal of an Aberrant Frenum

*Aneen Suresh, **Nandakumar K., ***Anagha Prasad, *** Mekha Madhu, ****Midhulaj Azeez

Abstract

The frenum is a mucous membrane fold that attaches the lip and the cheek to the alveolar mucosa, the gingiva, and the underlying periosteum. It can jeopardize the gingival health when attached too closely to the gingival margin, either due to an interference in the plaque control or due to a muscle pull. The maxillary frenum may lead to aesthetic problems or compromise the orthodontic result in the midline diastema cases, which may lead to a recurrence. The management of such an aberrant frenum is accomplished by performing a frenectomy.

The case report is of a 42 year old female patient reported to the Department of Periodontology, Azeezia College of Dental Science and Research, complaining of irritation of tissues under her upper lip. On observation, a Placek Class III frenum was noted.

The frenectomy was done using the Minimally Invasive Frenectomy technique. The Minimally Invasive Frenectomy technique is a methodical and efficient way to preserve the integrity of the periodontium, and provides a simple and effective method of treating the aberrancy, without utilisation of the complex methods available today.

Key Words: Frenum, Minimally Invasive Frenectomy, Frenotomy, Mucogingival Surgery

KDJ 2019 | Vol. 42 | No. 1 | Pg 32-35

Introduction

The frenum is one of the more important, yet often misunderstood structures present in the oral cavity. One of the leading causes for people seeking dental interventions is for aesthetic concerns. The presence of a "spacing" or "gap" between the central incisors, leading to a concern about aesthetics is one of the most common complaint a dental surgeon faces. The presence of an aberrant frenum is one of the etiological factors for the persistence of this midline diastema, and because of this, the frenum has become the crux upon which satisfactory aesthetics hinges, for most patients.

The frenum is also one of the main culprits in affecting the gingival health of an individual. It leads to the causation of a gingival recession when they are attached close to the margins of the gingiva. This can lead to improper placement of the toothbrush, which could lead to poor oral hygiene maintenance. A possibility of the muscle pull affecting the opening of the gingival crevice can also be considered as a reason for the inability to maintain good oral hygiene

The muscular anatomy of the frenum

A frenum is a mucous membrane fold which contains muscle and connective tissue fibres that attach the lip and the cheek to the alveolar mucosa, the gingiva and the underlying periosteum[2].

In a histologic study conducted by Knox and Young on the frenum, it was reported to contain both elastic and muscle fibres (Orbicularis oris - horizontal bands and oblique fibres). However, Henry, Levin and Tsaknis have found considerably dense collagenous tissue and elastic fibres but no muscle fibres in the frenulum[2].

Etiology

The maxillary labial frenum occurs as a post-eruptive remnant of the ectolabial bands which connect the tubercle of the upper lip to the palatine papilla. When the 2 central incisors erupt widely separated, no bone is deposited inferior to the frenum. A V-shaped bony cleft between the two central incisors and an abnormal frenum attachment results. The mandibular frenum is considered as aberrant when it is associated with a decreased vestibular depth and an inadequate width of the attached gingiva[1,2].

*PG Student, **Dean, Azeezia College of Dental Science and Research, ***PG Student, ***Reader, Department of Periodontology and Oral Implantology, Azeezia College of Dental Science and Research, Meyyannoor, Kollam. • Corresponding Author: Dr. Suresh A., E-mail: dr.aneensuresh@gmail.com

Diagnosis

The abnormal frena are detected visually by applying tension over the frenum to see the movement of the papillary tip or the blanch which is produced due to ischaemia in the region. The frenum is characterized as pathogenic when it is unusually wide or when there is no apparent zone of the attached gingiva along the midline or the interdental papilla shifts when the frenum is extended.

Abnormal or aberrant frena are detected visually, by applying tension over it to see the movement of papillary tip or blanching produced. This is called the Tension test

Classification (Placek et al 1986)

1. Mucosal – when the frenal fibers are attached up to mucogingival junction
2. Gingival – when fibers are inserted within attached gingiva
3. Papillary – when fibers are extending into interdental papilla
4. Papilla penetrating – when the frenal fibers cross the alveolar process and extend up to palatine papilla

Clinically, papillary and papilla penetrating frena are considered as pathological. Effects can range from loss of papilla, recession, diastema, difficulty in brushing and malalignment of teeth. They can also prejudice the denture fit or retention, leading to psychological disturbances to the individual

A frenum can be considered as a problem, due to tension from lip movement. Frenal attachment that encroach on the marginal gingiva distend the gingival sulcus, fosters plaque accumulation, which leads to an increasing the rate of progression of periodontal recession, thereby leading to recurrence after treatment.

Indications

The frenum is characterized as pathogenic and is indicated for removal when

- An aberrant frenal attachment is present, which causes a midline diastema.
- A flattened papilla with the frenum closely attached to the gingival margin is present, which causes a gingival recession and a hindrance in maintaining the oral hygiene.
- An aberrant frenum with an inadequately attached gingiva and a shallow vestibule is seen.

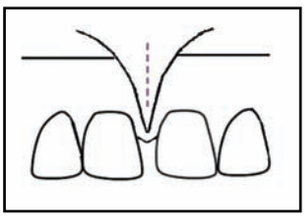

Fig 1.0 Identifying the Frenum

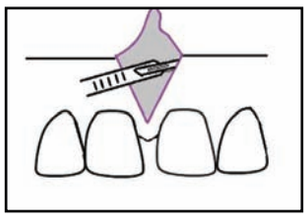

Fig 1.1 Single Incision Placed

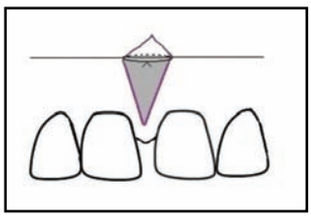

Fig 1.2 Split Thickness Dissection Completed

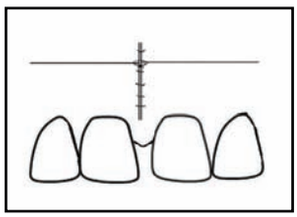

Fig 1.3 Suturing Completed

Fig 2.0 Armamentarium

Fig 2.1 Placek Type III Frenum with midline diastema

Fig 2.2 Midline incision carried out with #15 BP blade

Fig 2.3 Split Thickness Dissection carried out apicocoronally

Fig 2.4 Split Thickness Dissection carried out apicocoronally

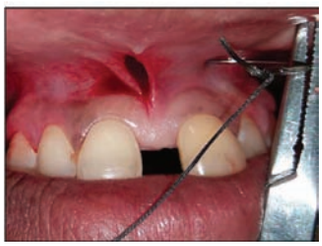

Fig 2.5 Single Anchoring Suture placed

Fig 2.6 Single Anchoring Suture placed

Fig 2.7 1 month post op

Treatment

The aberrant frena can be treated by *frenectomy* or by *frenotomy procedures*. Frenectomy is the complete removal of the frenum, including its attachment to the underlying bone, while *frenotomy* is the incision and the relocation of the frenal attachment[3].

Frenectomy can be accomplished either by the routine scalpel technique, electrosurgery or by using lasers. The conventional technique involves excision of the frenum by using a scalpel. However, it carries the routine risks of surgery like bleeding and patient compliance.

The use of electro surgery and lasers has also been proposed for frenectomy[4-9]. Researchers have advocated the use of an electrocautery probe due to its efficacy and due to the safety of the procedure, the mild bleeding and the absence of postoperative complications. However, it is associated with certain complications which include burns, the risk of an explosion if combustible gases are used, interference with pacemakers and the production of surgical smoke. These complications have not been reported with the new improvement in the electro surgical techniques, like the Argon Beam Coagulation (ABC)[4, 5].

Recently, the use of a CO2 laser in lingual frenectomies has been reported as a safe and effective procedure with the advantages of a shorter duration of the surgery, simplicity of the procedure, the absence of postoperative infections, lesser pain, swelling and the presence of a small or no scar [4]. A delayed healing as compared to that in the conventional scalpel techniques, a reduced surgical precision which results in an inadvertent laser-induced thermal necrosis and/or a photo acoustic injury, are some of the complications which are associated with lasers. The application of diode and Er: YAG lasers[6] in labial frenectomies in infants and Er, Cr: YSGG lasers[7] in labial frenectomies in the adolescent and the pre-pubescent populations have also been reported. Since the conventional procedure of frenectomy was first proposed, a number of modifications[10-12] of the various surgical techniques like the Miller's technique, V-Y plasty and Z-plasty have been developed to solve the problems which are caused by an abnormal labial frenum.

The present article is a case report, conducted in the Department of Periodontology and Oral Implantology at Azeezia College of Dental Science and Research that enumerates the minimally invasive technique for treatment of aberrant frena.

Techniques for frenal removal

- *Archer* and *Kruger* -Classical frenectomy
- *Edward* -"conservative surgical procedure".
- *Coleton* and *Lawrence* - free gingival graft combined with frenectomy
- *Miller* combined the frenectomy with a laterally positioned pedicle graft.
- *Schuchard* - Z Plasty

Of all the above techniques, we have decided to employ Minimally Invasive Frenectomy as our treatment of choice

Procedure

1. Identify the type of frenum according to the classification as provided by Placek et al (1986) (Fig 1.0)
2. A #15 BP blade is used to create the primary incision along the midline of the frenum (Fig 1.1)
3. Split - thickness dissection through the incision is carried in an apico-coronal direction on both sides. This helps to detach the underlying connective tissue attachment, so that free mucosal tissue flaps were obtained. (Fig 1.2)
4. Anchoring sutures (4-0 resorbable) was given at the vestibular region to stabilize the tissue (Fig 1.3)

Case

A 42 year old female patient reported to the Department of Periodontology, Azeezia College of Dental Science and Research, complaining of irritation of tissues under her upper lip.

The patient was in good physical health with no co-morbidities. On oral examination, it was noted that the patient had erythema in relation to the mandibular teeth, and a moderate gingival enlargement in relation to the maxillary teeth. A Placek Type III gingival frenal attachment was also observed, along with a midline diastema. (Fig 2.1)

The treatment plan involved the first line procedures including a Full mouth Oral Prophylaxis, followed by a thorough Scaling and Root Planing procedure. The patient was advised to follow proper oral hygiene instructions, and the use of mouthwash and dental floss. As the patient was quite receptive to the treatment, a repositioning of the frenum, to a much more viable position, to achieve proper periodontal health, was considered.

We decided to employ the minimally invasive frenectomy was decided as the treatment of choice. The armamentarium is represented in (Fig 2.0)

A #15 BP blade is used to create the primary incision along the midline of the frenum. (Fig 2.2). A Split - thickness dissection through the incision was carried out in an apico-coronal direction on both sides (Fig 2.3) and (Fig 2.4). This helps to detach the underlying connective tissue attachment, so that free mucosal tissue flaps were obtained.

A single anchoring suture (4-0 Black Silk) was given at the vestibular region to stabilize the tissue. (Fig 2.5 and Fig. 2.6).

The patient was reviewed at 1 month post surgery (Fig 2.7). Post-operative healing is good, and the patient was quite satisfied with the procedure.

Discussion

An aberrant frenum can be associated with various syndromes such as Ehlers-Danlos syndrome, Infantile hypertrophic pyloric stenosis, Holoprosencephaly, Ellis-van Creveld syndrome, and Oro-facial-digital syndrome. Each of them exhibit relatively specific frenal abnormalities, ranging from multiple, hyper plastic, hypoplastic, or an absence of frena.

Various non syndromic conditions include ankylosis of superior labial frena. These may show a familiar pattern of occurrence. Aberrant frenal attachments may be seen after orthognathic surgeries. Problems are probably caused by errors in the surgical technique. The design of the soft tissue incisions is critical, vertical incisions in the area of osteotomy may predictably create periodontal problems.

Most of the conventional frenectomy techniques impair the normal function of the frenum, since they completely remove it. In complete elimination of frena by frenectomy, even the deepest frenal attachments are cut. For this reason, the surgical site is often extensive and usually results in an extensive scar.

In contrast, the technique described in the current case report aims to preserve the papilla with minimal postsurgical scarring. This approach also allows preservation of interdental papilla in patients with a diastema. The frenum is positioned more apically. Only the attachments entering the bone are cut. In this way, attachments of the lip to the alveolar bone and gingiva maintain the natural function of the frenum. Because excision of tissue is limited, the modified frenectomy technique does not cause excess trauma to the buccal surface and does not compromise the interdental papilla.

This minimally frenectomy technique results in no scar at the buccal surface and preserves the interdental papilla. It has an added advantage that, it requires no extra incision to preserve the papilla. In addition, this report presents the results of this approach in only a single patient. The outcomes of clinical application of the technique in more patients must be assessed in order to allow evidence-based decision making.

Advantages of minimally invasive procedure

- Decreased post-operative discomfort
- Well accepted by the patient
- Almost universally applicable
- Minimal removal of tissue
- Minimal scarring
- Healing by Primary intention
- Good teaching tool as a suture exercise

Conclusion

Frenum may not regularly draw close scrutiny on routine dental examination. However, the detection of abnormal frenum may represent a highly useful indicator in the diagnosis of a wide array of syndromic and non-syndromic conditions. The presence of any abnormal frenal attachments can be corrected with a wide variety of surgical techniques available, of which, we would recommend utilising the minimally invasive technique

References

1. Periodontal Surgery: A Clinical Atlas – Natoshi Sato
2. Plastic-Esthetic Periodontal and Implant Surgery, Volume 9 - Otto Zuhr, Marc Hürzeler
3. A Review with the Reports of Surgical Techniques, Journal of Clinical and Diagnostic Research. 2012 November, Vol-6(9): 1587-1592
4. Wickham J. Minimally invasive therapy. Health Trends. 1991;23:6–9.
5. Christensen GJ. The advantages of minimally invasive dentistry. J Am Dent Assoc. 2005; 136:1563–5.
6. Beauchamp J, Caufield PW, Crall JJ, Donly K, Feigal R, Gooch B, et al. Evidence-based clinical recommendations for the use of pit-and-fissure sealants: A report of the American Dental Association Council on Scientific Affairs. J Am Dent Assoc. 2008; 139:257–68.
7. Gottlow J, Nyman S, Lindhe J, Karring T, Wennstrom J. New attachment formation in the human periodontium by guided tissue regeneration: Case reports. J ClinPeriodontol. 1986; 13:604–16.
8. Nyman S, Lindhe J, Karring T, Rylander H. New attachment following surgical treatment of human periodontal disease. J ClinPeriodontol. 1982; 9:290–6.
9. Bowers GM, Chadroff B, Carnevale R, Mellonig J, Corio R, Emerson J, et al. Histologic evaluation of new attachment apparatus formation in humans: Part II. J Periodontol. 1989; 60:675–82.
10. Camelo M, Nevins ML, Schenk RK, Simion M, Rasperini G, Lynch SE, et al. Clinical, radiographic, and histologic evaluation of human periodontal defects treated with Bio-Oss and Bio-Gide. Int J Periodontics Restorative Dent. 1998;18:321–31.
11. Cortellini P, Tonetti MS. Clinical performance of a regenerative strategy for intrabony defects: Scientific evidence and clinical experience. J Periodontol 2005;76: 341–350.
12. Wachtel H, Schenk G, Böhm S, Weng D, Zuhr O, Hürzeler MB. Microsurgical access flap and enamel matrix derivative for the treatment of periodontal intrabony defects: A controlled clinical study. J ClinPeriodontol 2003;30:496–504.

Creation of an esthetic smile

* Mekha Madhu, ** T P Padmakumar, *** Aneen Suresh, *** Anagha Prasad, ****Harikrishnan B. Pillai

Abstract

The esthetic demands in smile are continually rising. Several factors that can influence smile esthetics include tooth form, lip position and gingival tissue levels. The aim of this case report is to describe the improvement of smile esthetics in a patient that after orthodontic therapy, presented short clinical crowns and excessive gingival display. The present clinical case required combined treatment process including crown lengthening followed by lip repositioning technique to create an esthetic smile. Thus reduction of excessive gingival display, with a high level of patient satisfaction is obtained.

Key Words: Esthetics, Smile, Crown Lengthening, Lip Repositioning

KDJ 2019 | Vol. 42 | No. 1 | Pg 36-38

► Introduction

A basic and universal facial expression for communication and facial attractiveness is the smile. The demand for esthetics now a days increasing. The esthetics of smiling basically depends on the relation between three components: - Gingiva, Teeth, and Lips.

There are 3 main types of smile line.

According to Miller et al[1], a low smile line – exposing less than 75% of anterior maxillary coronary height and interproximal gingiva. A medium smile line – exposing 75 -100 % of anterior maxillary coronary height and interproximal gingiva. A high smile line – exposing entire crown height, a continuous band of gingiva. This is so called "gummy smile"

Gummy smile is also known as excess gingival display that showing more than 2 – 3 mm of gingiva on smiling[2]. Excess gingival display (EGD) during smiling has been a case of esthetically displeasing and embarrassment for some patients.

EGD is a multifactorial condition that may result from a single discrepancy or interplay of several discrepancies. Etiologic factors may be broadly defined as dento-alveolar and nondento-alveolar. Dento-alveolar discrepancies include those that affect dentition in the form of short clinical crowns, gingival hypertrophy or hyperplasia, altered passive eruption, and extrusion. Nondento-alveolar discrepancies involve vertical maxillary excess[3] and hyperactive, incompetent, or shortlip[2].

When altered passive eruption is present, crown lengthening such as gingivectomy and periodontal flap surgeries must be performed. Thus improving the esthetic smile by reducing excessive gingival display, exposing anatomic crown and re-establishing the appropriate biologic width to facilitate restorative procedures[4].

In some cases, smile esthetics problem will not solve by esthetic crown lengthening itself, Therefore a comprehensive treatment must be delivered for improving tooth shape, lip position and color[5].

The present case report describes a patient who undergoing orthodontic treatment, still requested improvement of her smile and esthetics. With proper diagnosis and communication, a combined treatment plan was employed to manage excessive gingival display, asymmetrical gingival margins and unpleasing tooth form.

► Case report

A 21 – year old systemically healthy female undergoing orthodontic treatment presented with the chief complaint of "a gummy smile ".

She wanted a procedure that would reduce the gingival display when she smiled. Her teeth had smaller dimension in height compared to normal and an excessive display of gingiva.

Since the patient had a short clinical crown, crown

*PG Student, **Head of the Department (HOD), ***PG Student, ****Senior Lecturer, Department of Periodontology and Oral Implantology, Azeezia College of Dental Science and Research, Meeyannoor, Kollam • Corresponding Author: Dr. Mekha Madhu, E-mail: mekhamdh@gmail.com

lengthening procedure using diode laser is done to expose the normal clinical crown. As the crown lengthening procedure had reduced the excessive gingival display, but the patient was not satisfied with her smile. So lip repositioning procedure also planned to correct the excessive gingival display.

Clinically it was observed that under developed clinical crowns on upper right and left anteriors and overall asymmetry of the gingival margin with excessive gingival display. [Figs. 1 and 2]

The dental history included orthodontic treatment, extraction of all 1st premolars.

► Procedure

Esthetic Crown lengthening procedure

- The surgical site is anaesthetized, by infiltration technique.
- Crown lengthening done using Diode laser (830 nm) on upper anteriors (canine to canine) to expose the clinical crown [Fig. 3].
- Post - operative esthetic crown lengthening after one week [Fig. 4] and after four weeks [Fig. 5].

Lip repositioning procedure

- One month after laser crown lengthening. Proper healing was obtained.
- The surgical site anaesthetized by infiltration (2% lidocaine with 1: 2000,000 epinephrine) into the buccal vestibule.
- A partial thickness incision is made along the mucogingival junction.
- A second parallel incision is made at the labial mucosa approximately 10-12 mm distance from the first incision.
- Two incision on either sides are made up to distal aspect of first premolar avoiding the frenum. [Fig. 6]
- A 5-6 mm of tissue excision done on both sides.[Fig. 7]
- Two incision lines are approximated with continuous interlocking suture using 5-0 absorbable suture.[Fig. 8] Pressure is applied until the haemostasis is obtained.
- Nonsteroidal anti-inflammatory medication prescribed post – operatively. Patient is instructed to use ice compress for several hours.
- Postoperative symptoms usually include some mild discomfort for several days and a feeling of tension when the patient smiles.
- Suture removal done after 2 weeks.
- Two weeks uneventful healing pattern is shown in [Fig.9].
- Follow up examination reveals reduced gingival display [Fig. 10].

The procedure is safe and has minimal side effects[6].

Variations in surgical lip repositioning have been reported in the medical literature. The smile muscle attachment is severed to prevent relapse of the smile muscle into its original position[7], thus minimizing the flap tension during suturing

► Discussion

This case report describes the successful management of

Fig. 1 Excess Gingival Display.

Fig. 2 Short Clinical Crowns

Fig. 3 Esthetic Crown Lengthening Using Diode Laser

Fig 4 One Week after Crown Lengthening.

Fig. 5 One month after Crown Lengthening, Clinical Crown Exposed

Fig. 6 Lip Repositioning Incision Placed on both sides.

altered passive eruption after orthodontic treatment via crown lengthening and modified lip repositioning procedure, resulting in an esthetically pleasing smile. Teeth shape and position and gingival tissue levels are several parameters that are important to achieve a pleasant smile[3].

An ideal zenith position of gingival contour in maxillary anterior teeth, the canines might be at a similar level or slightly apical than at central incisors, whereas a more coronal gingival contour is suggested for lateral incisors[8]. In our case, the proposed treatment that solved the asymmetry in gingival margin and lip position, lead to the patient's satisfaction with an enhanced smile.

Laser is a viable alternate to conventional therapies[9]. In this report crown lengthening procedure done initially using diode laser to expose the short clinical crowns. As in this case crown lengthening procedure alone does not cause reduction of excessive gingival display. Modified lip repositioning procedure also done.

Lip repositioning was introduced by Rubinstein and Kostianovsky as a simple conservative and permanent solution for the treatment of this esthetic discrepancy and although lip repositioning was first introduced in the 1970s[10].

Modified surgical lip repositioning technique also done as a second procedure, in this case followed by crown lengthening after 1 month is an effective method to reduce gingival display by positioning lip in a more coronal location.

Conclusion

The present case report described an approach to improve smile esthetics combining Diode laser crown lengthening and Modified lip repositioning technique. Thus the treatment result showed an esthetically created smile.

References

1) Tjan AH, Miller GD, TheJG. Some esthetic factors in a smile. J Prosthet Dent 1984; 51:24-8. Back to cited text no. 8 [PUBMED]
2) Robbins JW. Differential diagnosis and treatment of excess gingival display. Pract Periodontics Aesthet Dent. 1999; 11:265–272.
3) Garber DA, Salama MA. The aesthetic smile: Diagnosis and treatment. Periodontol 2000 1996; 11:18-28.
4) Ganji KK, Patil VA, John J. A comparative evaluation for biologic width following surgical crown lengthening using gingivectomy and ostectomy procedure. Int J Dent 2012; 2012:479241.
5) Hempton TJ, Dominici JT. Contemporary crown-lengthening therapy: A review. J Am Dent Assoc 2010; 141:647-55.
6) Kamer F. 'How do I do it' practical surgery practical suggestion on facial plastic surgery, smile surgery. Largyoscope 89: 1528 – 1532, 1979.
7) Miskinyar SAC. A new method for correcting a gummy smile, Plast. Reconstr surg 72: 397-400, 1983.
8) Magne P, Belser UC. Natural oral esthetics. In: Magne P, Belser UC, editors. Bonded Porcelain Restorations in the Anterior Dentition. A Biomimetic Approach. 1st ed. Chicago: Quintessence Books; 2002.p. 57-96.
9) Goldman L, Chromophore in tissue for laser medicine and laser surgery. Lasers Med Sci, 1990, 5(3) 289 – 292.
10) Rubinstein A, Kostianovsky A. Cosmetic surgery for the malformation of the laugh: original technique. Prensa Med Argent. 1973; 60:952–954.

Fig. 7 5 – 6 mm tissue excision done on both sides.

Fig. 8 Continuous Interlocking Sutures Placed.

Fig. 9 Healing After two Months.

Fig. 10 Reduced Gingival Display.

Pre – Operative View.

Post-Operative View

CASE REPORT

Treatment of lateral periodontal cyst

*Anagha Prasad, ** Devisree Naveen, *** Mekha Madhu, *** Aneen Suresh,
**** Aswathy Sheela Sudhakar

Abstract

Lateral periodontal cyst is a non-inflammatory developmental odontogenic cyst that arise from the cell rest of Malassez, reduced enamel epithelium or remnants of dental lamina. It is generally asymptomatic and diagnosed during routine radiographic examination. In this paper we have reported a case of Lateral periodontal cyst located in the mandibular premolar region and its treatment using GTR technique. The paper also reviews relevant literature describing the clinical, radiographic and histopathologic features of the cyst.

Key Words: Lateral Periodontal Cyst, Odontogenic cyst, Guided Tissue Regeneration

KDJ 2019 | Vol. 42 | No. 1 | Pg 39-41

► Introduction

Lateral periodontal cyst is a non-inflammatory developmental cyst that arise from the cell rest of Malassez, reduced enamel epithelium or remnants of dental lamina.[1, 2]

It is generally asymptomatic and seen on the lateral surface of the root of a vital tooth. It is commonly seen in the middle aged individuals with no racial predilection[3] and a slight male predilection[4]. The site of presentation is more often mandible especially the premolar- canine region.[5]

The patients with LPC are usually asymptomatic and are encountered during routine radiographic examination. Radiographically it appears as a well-defined, round or oval radiolucency less than 1 cm diameter[4] resembling an Odontogenic keratocyst or Lateral radicular cyst.[6]

Histologically, the lining epithelium is thin and non-keratinized, usually one to five layers thick and resembles the reduced enamel epithelium. Many of the lining cells have a clear, vacuolated, glycogen rich clear cells. The connective tissue subjacent to the epithelium exhibits a zone of hyalinization. Papillary infoldings of the cyst wall may be seen and inflammatory cells may be present but this is a secondary reaction.[7, 4]

When left untreated, it can result in root resorption, displacement of tooth, expansion and pain.[2] Treatment of LPC includes surgical enucleation of the cyst and regular follow up to monitor recurrence. Regenerative procedures including Guided tissue regeneration can also be used.

► Case report

A 52 year old male patient was referred to the Department of Periodontology from Prosthodontics department, Azeezia College of Dental Sciences and Research for evaluating the prognosis of 44 for crown placement, as they encountered a radiolucent lesion lateral to 44 while evaluating IOPA.

The patient was systemically healthy and was not under any medication which would affect the periodontal treatment. Clinical examination revealed deep cervical abrasion in relation

*P.G. Student, **Reader, ***PG Student, ****Senior Lecturer, Department of Periodontology and Oral Implantology, Azeezia College of Dental Science and Research, Meeyannoor, Kollam • Corresponding Author: Dr. Anagha Prasad, E-mail: anaghaprasad4@gmail.com

to 44 and multiple cervical abrasions in the adjacent teeth, generalized attrition was also noticed. Gingiva appeared to be normal, no swelling or enlargement were present. The tooth 44 had no mobility and no response to horizontal and vertical percussion. The patient had undergone RCT on the same tooth due to the presence of this radiolucent lesion lateral to it.

Radiographic examination revealed a well-defined round radiolucency with corticated borders less than 1 cm in diameter located in the distal aspect of middle third of the root of 44. (Fig. 1)

The provisional diagnosis on the basis of clinical and radiographic findings was Lateral Periodontal Cyst.

Surgical procedure

After initial therapy, Periodontal Access Flap surgery was planned in relation to 44, to gain access to the region. After ensuring adequate anaesthesia, Crevicular incisions in relation to 46, 45, 44 and 43 were placed followed by vertical releasing incision in relation to the line angles of 43. A triangular mucoperiosteal flap was elevated to expose the lesion. The granulation tissue was curetted completely from the lesion and an oval bone cavity was exposed. The defect after curettage was grafted with SybografTM (Sterile Synthetic Nanocrystalline Hydroxyapatite) followed by placement of Healiguide (Bioresorbable GTR membrane) to stabilize the graft material. Flaps were sutured with 4-0 Centisorb suture (4-0 absorbable Polyglactin 910 sutures) and periodontal dressing was placed. Analgesics and antibiotics were prescribed to avoid any post-operative pain or complications and patient was recalled after 7 days for review. (Figs. 2-10)

The tissue excised from the cystic lesion was fixed in 10% formalin, sectioned and stained with Haematoxylin and Eosin.

Histopathologic features

H & E stained soft tissue section shows a cystic lumen lined by non-keratinized squamous epithelium, 2-4 cell layer thick. The lining epithelium shows focal plaque like thickening into the connective tissue capsule. The connective tissue subjacent to the epithelial lining shows slight hyalinization and is devoid of any inflammation (Fig. 11)

► Discussion

Lateral periodontal cyst is a developmental odontogenic cyst usually diagnosed as a radiographic finding, presented as a well circumscribed round or oval radiolucency with corticated

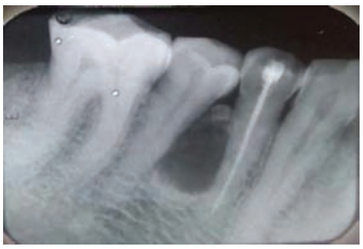

Fig. 1 Pre- operative IOPA

Fig. 2 Crevicular, Interdental and Vertical Incisions

Fig. 3 Excision of granulation tissue

Fig. 4 Cystic bone cavity after excision of granulation tissue

Fig. 5 Graft placed in the bony cavity

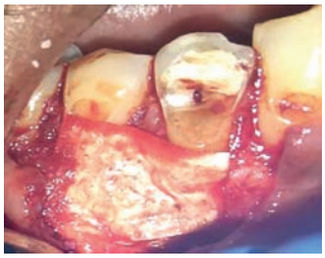

Fig. 6 Membrane placed.

Fig. 7 Flaps approximated and sutured

Fig. 8 Periodontal pack placed

Fig. 9 Review- week after suture removal

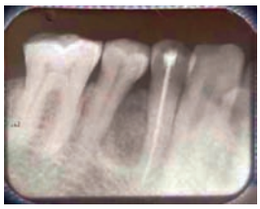

Fig. 10 Post- operative IOPA at the time of suture removal

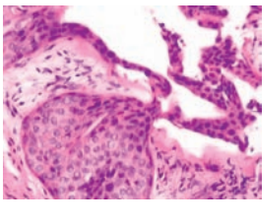

Fig. 11 Histopathologic picture of LPC (H& E Stain, 40X)

Fig. 12 Post- operative photo-graph – at 6 months

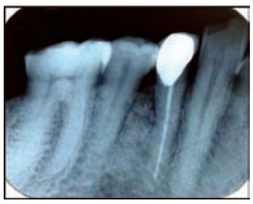

Fig. 13 Post- operative IOPA – at 6 months

borders. It represents 0.8% to 2% of all odontogenic cysts.[9]

The literature states that LPC is more common in adults of 5th-7th decades with a slight male predilection and no racial predilection. The site of occurrence was reported to be mandibular premolar area followed by maxillary anterior region.[10, 11, 12]

LPC does not present with clinical symptoms and the tooth associated is vital unless infected. Hence it is diagnosed with radiographic and histopathologic findings.

There is a multicystic variant of LPC called the Odontogenic botryoid cyst due to its macroscopic and microscopic findings resembling bunch of grapes.[3, 13, 14]

The differential diagnosis of LPC are radicular cyst (due to their high frequency), Follicular or Dentigerous cyst (always associated with an impacted tooth), Adult gingival cyst (same histologic and clinical features but no radiographic findings)[15] and Keratocystic odontogenic tumour (aggressive nature, fast growth and high recurrence rate).

The treatment for LPC is surgical enucleation of the cyst. Any endodontic treatment of the affected tooth was unnecessary[12]. In this case the patient had already undergone RCT before reporting to us due to the presence of this radiolucency. Surgical enucleation along with GTR was done. The bone cavity was grafted and covered by resorbable collagen membrane. The bone graft have osteoconductive properties that provide a scaffold for regenerative cells to differentiate and multiply. Collagen membrane acts as a barrier to prevent migration of epithelial cells.

Nart et al.[16] indicated the bone fill of the defect in LPC by re-entry after the treatment using GTR, along with bone grafts, 7 months postoperatively.

Subramaniam et al.[17] treated an intraosseous cystic cavity using PRP without bone graft. Although this study showed promising results in the treatment of intraosseous cystic cavities, PRP alone still lacks consistent clinical outcome in periodontal regeneration.[15, 16]

The patients are advised to report for regular recall and review to check for any recurrence.[18]

In this case, healing was acceptable with radiographic bone fill and no recurrence was noted in 6 months follow up. (Figs. 12, 13)

► Conclusion

Lateral periodontal cyst is a developmental, uncommon and non-inflammatory cyst which can be treated successfully with GTR technique to yield good clinical and radiographic outcome.

► References

1. Wood K, Goaz P. 5th ed. St. Louis: Mosby; 1997. Differential Diagnosis of Oral and Maxillofacial Lesions; pp. 305–6.
2. Demirkol M, Ege B, Yanik S, Aras MH, Ay S. Clinicopathological study of jaw cysts in southeast region of Turkey. Eur J Dent. 2014; 8:107–11
3. Cohen DA, Neville BW, Damm DD, White DK. The lateral periodontal cyst. A report of 37 cases. J Periodontol. 1984; 55:230–4.
4. Altini M, Shear M. The lateral periodontal cyst: An update. J Oral Pathol Med. 1992; 21:245–50.
5. Soares de Lima AA, Naval Machado MÂ, Braga AM, De Souza MH. Lateral periodontal cyst: Aetiology, diagnosis and clinical significance. A review and report of case. Rev de Clín Pesqui Odontol. 2005; 1:55–9.
6. Kramer IR, Pindborg JJ, Shear M. 2nd ed. Geneva: Springer-Verlag; 1992. WHO Histological Typing of Odontogenic Tumours; pp. 34–118.
7. Shafer's Textbook of Oral Pathology,6th edition.
9. Shear M. Developmental odontogenic cysts. An update. J Oral Pathol Med. 1994 Jan; 23(1):1-11. Review.
10. Krier PW. Lateral periodontal cyst. Oral Surg Oral Med Oral Pathol. 1980 May; 49(5):475.
11. Ortega A, Fariña V, Gallardo A, Espinoza I, Acosta S. Nonendodontic periapical lesions: a retrospective study in Chile. Int Endod J. 2007 May; 40(5):386-90. Epub 2007 Mar 21. Erratum in: Int Endod J. 2007 Aug; 40(8):661
12. Formoso Senande MF, Figueiredo R, Berini Aytés L, Gay Escoda C. Lateral periodontal cysts: a retrospective study of 11 cases. Med Oral Patol Oral Cir Bucal. 2008 May 1; 13(5):E313-7.
13. Rasmusson LG, Magnusson BC, Borrman H. The lateral periodontal cyst. A histopathological and radiographic study of 32 cases. Br J Oral Maxillofac Surg. 1991 Feb; 29(1):54-7.
14. Eliasson S, Isacsson G, Köndell PA. Lateral periodontal cysts. Clinical, radiographical and histopathological findings. Int J Oral Maxillofac Surg. 1989 Aug; 18(4):191-3.
15. Tolson GE, Czuszak CA, Billman MA, Lewis DM. Report of a lateral periodontal cyst and gingival cyst occurring in the same patient. J Periodontol. 1996 May; 67(5):541-4.
16. Nart J, Gagari E, Kahn MA, Griffin TJ. Use of guided tissue regeneration in the treatment of a lateral periodontal cyst with a 7-month reentry. J Periodontol. 2007; 78:1360–4.
17. Subramaniam P, Kumar K, Ramakrishna T, Bhadranna A. Bone regeneration with plasma-rich-protein following enucleation of traumatic bone cyst. Eur J Dent. 2013; 7:377–81.
18. Valério GM, Cury PR. Diagnosis and treatment of lateral periodontal cyst: Report of three clinical cases. Rev Odontol Cinc. 2009; 24:213–7.

Race with braces; A novel Orthodontic approach

* Shabeer Babu, **P.G. Francis, *** Vincy Antony Margaret

Introduction

Orthodontics, being the oldest specialty of dentistry, continues to amaze the field of science with its brilliance and enormously increasing research and development, in the form of newer materials, methods of diagnostic aids and superior treatment mechanics. However, one aspect, which has not come under the control, is the rather delayed treatment duration. Currently, fixed orthodontic treatment requires a long duration of about 2–3 years, which is of great concern and poses high risk of caries, external root resorption and decreased patient compliance. Lengthy orthodontic treatment prompts many patients, especially adults, to either avoid treatment or to seek shorter alternative solutions with compromised results. Therefore the treatment modality that decreases treatment time without compromising the treatment outcome is an active area of research in Orthodontics today. To date, several novel modalities have been reported to accelerate orthodontic tooth movement, including low-level laser therapy, pulsed electromagnetic fields, electrical currents, corticotomy, distraction osteogenesis and mechanical vibration;and now, the interest in using nanorobots to hasten orthodontic tooth movement is slowly taking shape.

Methods to accelerate orthodontic tooth movement (Table.1) can be broadly studied under the following categories:

Drugs	Device-assisted approach	Surgical Methods
Vitamin D	Cyclical force device	Interseptal alveolar surgery
Prostaglandin	Photobiomodulation	Corticotomy
Interleukins	Direct electric current effect	Micro-osteoperforations
Parathyroid hormone	Low-level laser therapy	Piezocision technique
Misoprostol		

Table 1: Methods to accelerate orthodontic tooth movement

Drugs

Various drugs have been tested to accelerate orthodontic tooth movement, and have achieved successful results[1-3]. These include vitamin D, prostaglandin, interleukins, parathyroid hormone, misoprostol, etc. Experiments have been done using these molecules exogenously to enhance tooth movement in humans. But, all of these drugs have some or the other unwanted adverse effect. For example, vitamin D when injected in the periodontal ligament increases the levels of LDH and CPK enzymes; prostaglandin causes a generalized increase in the inflammatory state and causes root resorption. Hence, as of today, no drug exists that can safely accelerate orthodontic tooth movement.

High concentration of cytokines such as interleukins IL-1, IL-2, IL-3, IL-6, IL-8, and tumor necrosis factor alpha (TNF) were found to play a major role in bone remodeling; moreover, interleukin-1 (IL-1) stimulates osteoclast function through its receptor on osteoclasts.[4] It was also found that mechanical stress due to orthodontic treatment increased the production of prostaglandin PGE and IL-1 beta in the periodontal ligament. These immunohistochemistry and micro photometry experiments were done on cats and the intensity of PGE and IL-1 beta was found to be highest on the tension side.[5]

Prostaglandins (PGs) are inflammatory mediators and a paracrine hormone that acts on nearby cells; it stimulates bone resorption by increasing directly the number of osteoclasts. Yamasaki[6,7] was among the first to investigate the effect of local administration of prostaglandin on rats and monkeys. In addition, experiments have shown that injections of exogenous PGE2 over an extended period of time caused acceleration of tooth movements in rats.[8]

Vitamin D3 has also attracted the attention of some

*Post Graduate Student, ** Professor and HOD, ***Professor, Dept. of Orthodontics and Dentofacial Orthopedics, MES Dental College, Perinthalmanna
• Corresponding Author: Dr Shabeer Babu E-mail: shabeerullatil@gmail.com

scientists to its role in the acceleration of tooth movement; 1,25 dihydroxycholecalciferol is a hormonal form of vitamin D and plays an important role in calcium homeostasis with calcitonin and parathyroid hormone (PTH). Another set of investigators[9] did an experiment where they have injected vitamin D metabolite on the periodontal ligament of cats for several weeks; the histologic picture revealed that vitamin D had accelerated tooth movement at 60% more than the control group due to the increase of osteoclasts on the pressure side.

Some studies have shown that locally injected Parathyroid hormone (PTH) induces local bone resorption, and it is more advantageous to give PTH locally rather than systemically.[10] The development of a slow-release application that keeps the local concentration of PTH for a long time was very efficient, where the daily injection of PTH dissolved in gel medium allowed a slow release which caused 1.6-fold faster acceleration of teeth compared to daily injection of PTH dissolved in saline solution which did not cause any acceleration.

Relaxin is a hormone that helps during childbirth by widening of the pubic ligaments in females and is suggested to be present in cranial sutures and periodontal ligament.[11] The role of relaxin is known in the remodeling of soft tissue rather than remodeling of bone. It has been shown that it increases collagen in the tension site and decreases it in compression site during orthodontic movement.[12,13]

Device-assisted approach

Another approach in accelerating tooth movement is by using device-assisted therapy. Surgical methods, regardless of technique, are still invasive to some degree, and hence have their associated complications. Hence, non-invasive methods like direct electric currents, pulsed electromagnetic field, static magnetic field, resonance vibration, and low level laser have been investigated and have given promising results.

Cyclical force device

Kauet al[14] used a cyclical force device, using the soft pulse technology in patients, and achieved a tooth movement of 2 to 3 mm/month. The vibration rate was 20 to 30 Hz and was used for 20 min/day. Recently, a product by the name Acceledent (Fig.1) has arrived at the market, which makes use of this technology. This device consists of an activator, which is the active part of the appliance that delivers the vibration impulses with a USB interface through which it can be connected to a computer to review the patient usage of the appliance and a mouthpiece that contacts the teeth. It is a portable device that can be charged similar to any other electronic device, and has to be worn for 20 minutes a day. Various case studies using this device have shown the treatment times to be reduced by up to 30-40%.[14]

Photobiomodulation

Light-accelerated orthodontics (LAO) is a technique within the scope of photobiomodulation or Low level light therapy. The terms photobiomodulation and LAO can be interchangeably

Fig. 1: Cyclical force device

Fig. 2: Extra-oral OrthoPulse LED, Biolux Research

Fig. 3: Fixed type electric appliance

Fig. 4: Lasers used in Orthodontics to accelerate tooth movement

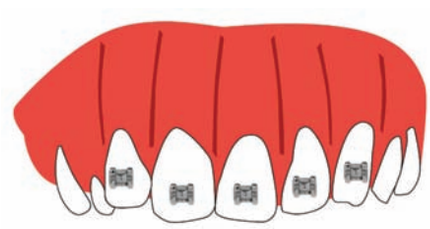

Fig. 5: Corticotomy

Fig. 6: The device Propel

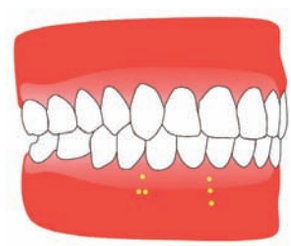

Fig. 7: Micro-osteoperforations

used to define the specific wavelength range, intensity, and light penetration and to differentiate from other methods utilizing light for treatment elsewhere in dentistry.

Device description[15]

It is an extra-oral device (Extra-oral OrthoPulse LED, Biolux Research, Vancouver, Canada) (Fig.2) which produces near infrared light with a continuous 850-nm wavelength. The surface of the cheek is irradiated with a power density of 60mW/cm2 for 20 or 30 min/day or 60 min/week to achieve total energy densities of 72, 108, or 216 J/cm2, respectively. Industry-standard light emitting diodes (LEDs) are used to produce the light, with arrays of emitters arranged in a series of treatment arrays to cover the target area of the alveolus of both the maxilla and mandible.

The device consists of three main components:

1) A small handheld controller which houses the microprocessor, the menu-driven software, and the LCD screen. The controller is programmable by the investigator for the number of treatment sessions and the session duration.
2) A set of four extra-oral treatment arrays, each with a flexible printed circuit board and a set of LEDs mounted on a contoured heat sink and infrared transmissible plastic lens, with conductive cables to the controller.
3) A headset similar to an eyeglass support structure to be worn by the patient on a daily or weekly basis, with attachment and adjustment mechanisms to position the treatment arrays in the appropriate location for the given patient.

Direct electric current effect on tooth movement[16] (Fig 3)

The application of an exogenous electric current to the alveolar bone surrounding a tooth being orthodontically treated can enhance orthodontic tooth movement. The appliance consists of a button cell and wire components embedded in acrylic which is attached with the bracket. The electric appliance is set in the maxilla to provide a direct electric current of 20µA. The tooth is provided with orthodontic force and electric current. Electrical current is to be applied to canines for 5 hours a day. The application of an exogenous electric current from the miniature electric device was found to accelerate orthodontic tooth movement by 2.42mm/4 weeks and thereby reduced orthodontic treatment duration.

Low-level laser therapy

Low level laser therapy (LLLT) is one of the most promising approaches today. Laser has a biostimulatory effect on bone regeneration, which has been shown in the midpalatal suture during rapid palatal expansion,[17] and also stimulates bone regeneration after bone fractures and in extraction sites[18,19] (Fig 4). It has been found that laser light stimulates the proliferation of osteoclasts, osteoblasts and fibroblasts, and thereby affects bone remodeling and accelerates tooth movement. The low-energy laser irradiation enhanced the velocity of tooth movement via RANK/RANKL and the macrophage colony-stimulating factor and its receptor expression.[20]

In 2004, Cruz et al[21]. was the first to carry out a human study on the effect of low-intensity laser therapy on orthodontic tooth movement. They showed that the irradiated canines were retracted at a rate 34% greater than the control canines over 60 days.

Surgical Methods

Surgical approaches have been documented in many case reports to accelerate orthodontic tooth movement. The surgical methods included interseptal alveolar surgery, osteotomy, corticotomy and Piezocision technique.

Interseptal alveolar surgery

The concept of distraction osteogenesis came from the early studies of limb lengthening and surgical treatment of craniofacial skeletal dysplasia; this concept was later adapted in relation to accelerated tooth movement.[22] Interseptal alveolar surgery or distraction osteogenesis is divided into distraction of periodontal ligament and distraction of the dentoalveolar bone; example of both is the rapid canine distraction. In the rapid canine distraction of periodontal ligament, the surgical procedure involved undermining the interseptal bone 1 to 1.5 mm in thickness distal to the canine after extraction of the first premolar, and the socket is deepened by a round bur to the length of the canine. The compact bone is replaced by the woven bone, and tooth movement is easier and quicker due to reduced resistance of the bone. The retraction of the canine is done by the activation of an intraoral device directly after the surgery. It has been shown that it took 3 weeks to achieve 6 to 7 mm of full retraction of the canine to the socket of the extracted first premolars.[23]

Corticotomy

Corticotomy is one of the surgical procedures that is commonly used in which only the cortical bone is cut and perforated but not the medullary bone, suggesting that this will reduce the resistance of the cortical bone and accelerate tooth movement (Fig 5). It was first tried in Orthodontics by Kole,[24] and he observed that orthodontic tooth retraction following extraction was achieved between 6 and 12 months. In 2001, Wilcko[25] reported that the acceleration of tooth movement was not due to the bony block movement as postulated by Kole; it was rather a process of bone remodeling at the surgical site, which was called regional acceleratory phenomenon (RAP). He developed patent techniques which were called Accelerated Osteogenic Orthodontics (AOO) and Periodontal Accelerated Osteogenic Orthodontics. He also reported that a

surface-computed tomographic evaluation of corticotomized patients clearly showed a transient localized demineralization-remineralization process consistent with the accelerated wound healing pattern of the regional acceleratory phenomenon. Also, modification of RAP was done by adding bioabsorbable grafting material over the injured bone to enhance healing.

The conventional corticotomy procedure involves elevation of full thickness mucoperiosteal flaps, buccally and/or lingually, followed by placing the corticotomy cuts using either micromotor under irrigation, or piezosurgical instruments. This can be followed by placement of a graft material, wherever required, to augment thickness of bone.

Advantages

1. It has been proven successful by many authors, to accelerate tooth movement.
2. Bone can be augmented, thereby preventing periodontal defects, which might arise, as a result of thin alveolar bone.

Disadvantages

1. High morbidity associated with the procedure.
2. Invasive procedure.
3. Chances of damage to adjacent vital structures.
4. Post-operative pain, swelling, chances of infection, avascular necrosis.
5. Low acceptance by the patient.

Micro-osteoperforations (MOP)

A device called Propel (Fig. 6), was introduced by Propel Orthodontics to further reduce the invasive nature of surgical irritation of bone; they called this process as Alveocentesis, which literally translates to puncturing bone.

This device comes as ready-to-use sterile disposable device with an adjustable depth dial and indicating arrow on the driver body. The adjustable depth dial can be positioned to 0 mm, 3 mm, 5 mm, and 7 mm of tip depth, depending on the area of operation. Mani Alikhani et al[26], performed a single center single-blinded study to investigate this procedure and concluded that MOPs (Fig.7) increased the rate of canine retraction 2.3-fold and reduced orthodontic treatment time by 62%. MOPs significantly increased the expression of cytokines and chemokines and were found to be effective, comfortable and a safe procedure to accelerate tooth movement during orthodontic treatment.

Piezocision technique

One of the latest techniques in accelerating tooth movement is the Piezocision technique. To reduce the morbidity associated with conventional corticotomy, Dibart et al in 2009,[27] introduced a flapless method of corticotomy, using piezosurgery.

In the technique described by them, the surgery was performed 1 week after placement of orthodontic appliance, under local anaesthesia. Gingival vertical incisions, only buccally, were made below the interdental papilla, as far as possible, in the attached gingiva using a No.15 scalpel. These incisions needed to be deep enough so as to pass through the periosteum, and contact the cortical bone. Next, ultrasonic instrumentation was done to perform the corticotomy cuts to a depth of 3 mm through the previously made incisions. At the areas requiring bone augmentation, tunnelling was performed using an elevator inserted between the incisions, to create sufficient space to accept a graft material. No suturing is required, except for the areas, where the graft material needed to be stabilized.

Hassan[28] has reported that Piezocision technique did not cause any periodontal damage. Another benefit of this technique is that it can be used with Invisalign, which lead to a better aesthetic appearance and less treatment time as reported by Keser[29]. Piezocision is a promising tooth acceleration technique because of its various advantages on the periodontal, aesthetic and orthodontic aspects.

Advantages

1) Minimally invasive.
2) Better patient acceptance.

Disadvantages

Risk of root damage, as incisions and corticotomies are "blindly" done.

► Conclusion

Since long, orthodontic patients have been asking for shorter treatment time, and today, we do have methods that can accelerate orthodontic tooth movement safely. The current methods such as piezocision, microosteoperforations, lasers and vibration have reduced or eliminated the invasive nature of previous procedures used to achieve the Regional Acceleratory Phenomenon. Also, they come with additional advantages such as reduced rates of relapse, reduced orthodontic pain and reduced root resorption. In general, all these techniques had drawbacks and uncertainties that made them not commonly used clinically. However, there has been a rapid increase in the interest levels of product companies to enhance the effects of biology in Orthodontics. These new approaches have the potential to be the next frontier for Orthodontics and its resources.

► References

1. Sekhavat A R, Mousavizadeh K, Pakshir H R., Aslani F S. Effect of misoprostol, a prostaglandin E1 analog, on orthodontic tooth movement in rats. Am.J.OrthodDentofacialOrthop. 2002;122(5): 542-547.
2. Collins M K, & Sinclair P M. The local use of vitamin D to increase the

rate of orthodontic tooth movement. Am JOrthodDentofacialOrthop. 1988; 94(4):278-284.

3. Bartzela T, TürpJ C, Motschall E, Maltha, J C. Medication effects on the rate of orthodontic tooth movement: a systematic literature review. Am.JOrthodDentofacialOrthop. 2009;135(1):16-26.
4. Davidovitch Z, Nicolay OF, Ngan PW, Shanfeld JL. Neurotransmitters, cytokines, and the control of alveolar bone remodeling in orthodontics. Dent Clin North Am. 1988; 32(3):411–35.
5. Saito M, Saito S, Ngan PW, Shanfeld J, Davidovitch Z. Interleukin 1 beta and prostaglandin E are involved in the response of periodontal cells to mechanical stress in vivo and in vitro. Am J OrthodDentofacialOrthop. 1991; 99(3):226–40.
6. Yamasaki K, Miura F, Suda T. Prostaglandin as a mediator of bone resorption induced by experimental tooth movement in rats. J Dent Res. 1980; 59(10):1635–42.
7. Yamasaki K, Shibata Y, Fukuhara T. The effect of prostaglandins on experimental tooth movement in monkeys (Macacafuscata). J Dent Res. 1982; 61(12):1444–6.
8. Leiker BJ, Nanda RS, Currier GF, Howes RI, Sinha PK. The effects of exogenous prostaglandins on orthodontic tooth movement in rats. Am J OrthodDentofacialOrthop. 1995; 108(4):380–8.
9. Collins MK, Sinclair PM. The local use of vitamin D to increase the rate of orthodontic tooth movement. Am J OrthodDentofacialOrthop. 1988; 94(4):278–84.
10. Takano-Yamamoto T, Rodan GA. A model for investigating the local action of bone-acting agents in vivo: effects of hPTH(1–34) on the secondary spongiosa in the rat. Calcif Tissue Int. 1990; 47(3):158–63.
11. Nicozisis JL, Nah-Cederquist HD, Tuncay OC. Relaxin affects the dentofacialsutural tissues. ClinOrthod Res. 2000; 3(4):192–201.
12. Han GL, He H, Hua XM, Wang SZ, Zeng XL. Expression of cathepsin K and IL-6 mRNA in root-resorbing tissue during tooth movement in rats. Zhonghua Kou Qiang Yi XueZaZhi. 2004; 39(4):320–3.
13. Bumann A, Carvalho RS, Schwarzer CL, Yen EH. Collagen synthesis from human PDL cells following orthodontic tooth movement. Eur J Orthod. 1997; 19(1):29–37.
14. Kau CH. A radiographic analysis of tooth morphology following the use of a novel cyclical force device in orthodontics. Head Face Med. 2011; 7:14.
15. Kau et al. Photobiomodulation accelerates orthodontic alignment in the early phase of treatment. ProgOrthod. 2013 14:30.
16. Kim et al. The effects of electrical current from a micro-electrical device on tooth movement Korean J Orthod 2008;38(5): 337-346.
17. Saito S, Shimizu N. Stimulatory effects of low-power laser irradiation on bone regeneration in midpalatal suture during expansion in the rat. Am J OrthodDentofacialOrthop. 1997; 111(5):525–32.
18. Trelles MA, Mayayo E. Bone fracture consolidates faster with low-power laser. Lasers Surg Med. 1987; 7(1):36–45.
19. Takeda Y. Irradiation effect of low-energy laser on alveolar bone after tooth extraction. Experimental study in rats. Int J Oral Maxillofac Surg. 1988; 17(6):388–91.
20. Fujita S, Yamaguchi M, Utsunomiya T, Yamamoto H, Kasai K. Low-energy laser stimulates tooth movement velocity via expression of RANK and RANKL. OrthodCraniofac Res. 2008; 11(3):143–55.
21. Cruz DR, Kohara EK, Ribeiro MS, Wetter NU. Effects of low- intensity laser therapy on the orthodontic movement velocity of human teeth: A preliminary study. Lasers in Surgery and Medicine: The Official Journal of the American Society for Laser Medicine and Surgery. 2004;35(2):117-20
22. Ilizarov GA. The possibilities offered by our method for lengthening various segments in upper and lower limbs. Basic Life Sci. 1988; 48:323–4.
23. Liou EJ, Huang CS. Rapid canine retraction through distraction of the periodontal ligament. Am J OrthodDentofacialOrthop. 1998;114:372–382.
24. Köle H. Surgical operations of the alveolar ridge to correct occlusal abnormalities. Oral Surg Oral Med Oral Pathol 12:515, 1959.
25. Wilcko WM, Wilcko MT, Bouquot JE, et al: Rapid orthodontics with alveolar reshaping: Two case reports of decrowding. Int J Periodontics Restorative Dent.2001; 21:9.
26. Alikhani M, Raptis M, Zoldan B, Sangsuwon C, Lee YB, Alyami B, Corpodian C, Barrera LM, Alansari S, Khoo E, Teixeira C. Effect of micro-osteoperforations on the rate of tooth movement. Am. J OrthodDentofacialOrthop.. 2013 Nov 1;144(5):639-48.
27. Dibart S, Surmenian J, DavidSebaoun J, Montesani L. Rapid treatment of Class II malocclusion with piezocision: two case reports. The International journal of periodontics & restorative dentistry. 2010 Oct;30(5):487.
28. Hassan N, Sa IT. The effect of using piezocision technique in orthodontic tooth movement on the periodontal condition. Egypt Dent J. 2011;57:3047.
29. Keser EI, Dibart S. Piezocision-assisted Invisalign treatment. CompendContinEduc Dent. 2011;32(2):46–8.

REVIEW

Non-metric dental traits in forensic odontology: brief review

* Asha S D, *Nripan T, ** R. Rathy, ***Harish R.K, **** Ameena M.

Abstract

The term non-metric implies the structural variations of individual crown and root forms that are visually scored as present or absent basis. Non-metric dental studies have been used in modern contexts mainly for forensic racial identification. The fundamental of forensic odontology is that, teeth are the hardest substances of human body which are well protected structures resistant to decomposition and temperature to a significant extend, so the last structure to disintegrate. Tooth can provide many details regarding shape of a tooth crown, shape or number of roots, and on the number of teeth present. The phenotypic traits found on teeth are the best source of information that helps to identify biological relationships between populations or subgroups. This review explains about commonly identified nonmetric dental traits in forensic odontology.

Keywords: Non metric dental traits, odontology, identification, forensic.

KDJ 2019 | Vol. 42 | No. 1 | Pg 51-55

► Introduction

Forensic odontology is a branch of dentistry which deals with the proper handling and examination of dental evidence and the proper evaluation and presentation of dental findings in the interest of justice (Goldman AD 1982). The fundamental of forensic odontology is that, teeth are the hardest substances of human body which are well protected structures resistant to decomposition and temperature to a significant extend, so the last structure to disintegrate.[1]

The advantage of using teeth in forensic odontology is because of their preservability, observability, variability and heritability. Because of their preservability it can be used as fossils, archeological studies and forensic records. Observability can be utilized in living, skeleton as well as fossils. Teeth may show great variability like dozens of measurements and discrete attributes of the crowns and roots that vary within and between populations. They also show heritability such as strong genetic basis underlying tooth development and trait expression.[2]

A nonmetric trait means morphological features that can occur in any anatomical tissue. They are called non metric because they cannot be measured in incremental units. Nonmetric traits can be either asymptomatic or pathological, these traits have a good role in forensic odontology studies.[3] In 1920 A. Hrdlicka gave the first description about nonmetric tooth traits.[4] In humans, dentition always show variations and they will not be same always. These variations can be used as a key for the researchers in identifying variation between individuals. This review provides a brief overview of various non metric dental traits used in the forensic odontology.

► Discussion

Non metric dental traits (NMDTs) are utilized commonly in forensic odontology and anthropology. Dental anthropology is the study of teeth to garner information on social and historical backgrounds of individuals and their groups. These non metric traits can be simply recorded on a present or absent basis. They can also be graded on a scale with absence and to different grades of positive expression from minimal to maximum. Non-metric traits are passed between the members of different groups, indicating their genetic origin, so a dedicated attention can reveal more information both within and between the different groups. A systematic approach is required to record all the traits without fail, and otherwise the observer may overlook many of the features.[4,5]

Theories of non metric traits:

Different theories exist explaining the expression of traits among different populations.

Field theory suggests that environmental factors induce and influence the dental traits. Nutrients, fluoride intake and the size of the jaws are few among them.

*Post graduate student, **Professor and Head, ***Reader, ****Senior Lecturer, Dept. of Oral Pathology and Microbiology, Azeezia College of Dental Sciences and Research, Meeyannoor, Kollam. • Corresponding Author: Dr. Asha SD E-mail: ashasanoop1@gmail.com

The clonal model theory put forth that, traits are intrinsic and the extrinsic factors play little or no role in their development.[4]

The formation of non metric dental traits are independent from uterine influence, their evolution is slow and probably independent from natural selection. The development of anatomic traits of teeth is seemingly uncorrelated and presents low sexual dimorphism[6]. It relies on a small and stable portion of the genome.

History of non metric dental trait analysis

Ales Hrdlicka (1920) published his work on incisor shovelling. Other than the dichotomy presence or absence, he proposed a gradation for the trait. The work of Hrdlicka was revolutionary in this field. He noted that when present, these traits take different variations ranging from minimal to maximal expression. He also published descriptions and photographs of each grades for others to make same sort of observations.[7]

Albert A Dahlberg was another pioneer researcher in NMDTs. In 1956 he developed grading standards and also released a series of standardized plaques from the Zoller clinic in Chicago. The standardized plaster plaques could be distributed with other researchers of the field provided, visual aid in grading NMDTs. Shovelling, double shovelling, hypocone, Carabelli's trait and the protostylid were included in his plaster plaques.[2]

Kazuro Hanihara in 1968 published morphological pattern of deciduous dentition in the Japanese-American hybrids.[8] Hanihara et al. in 1970 also quantified size of the hypocone through the use of photographs, but this method is time consuming, expensive, and does not address shape concerns, especially for low grades of expression. This method works well for maxillary first molars, which consistently expresses a hypocone, but is less useful for the more variable maxillary second and third molars, where the hypocone is often reduced or lost altogether. Of course, this method requires teeth that show very little wear. Because of these limitations, no workers have adopted this method for scoring variation in hypocone size.[9]

A.A Zubov (1968, 1977) developed a method called odontoglyphics for using "tooth shape" for anthropological and forensic purpose. This approach focuses on complex pattern of furrows in multicusped tooth. In Zubov's method negative relief on the wax bite impressions were studied for the NMDTS. This method does not gain much popularity except in Russia, because positive replica of traits were widely used for studies in other countries.[2]

In 1991 Turner et al developed a new system of grading of NMDTs in the Arizona University known as Arizona State University Dental Anthropology System (ASUDAS). ASUDA system was developed based on the principle of Dahlberg's plaster plaques. More traits were added and plaques were distributed all over the world for studies in different fields.[2]

Table I Maxillary Incisors

Trait	Description
Winging	Unlike most of the other traits, it is not dictated in crown or root but by the orientation of socket of maxillary central incisors. The distal border of labial surface of central incisors rotated distally than the usual flat or slightly parabolic surface.
Shoveling	Presence of a combination of lingual marginal ridges along the distal marginal ridge and mesial marginal ridge
Double shovelling	Presence of mesial and distal marginal ridges on the labial surface
Tuberculum dentale	Tuberculum projections on the basal eminence of maxillary incisors
Interruption grooves	Lingual marginal border or basal eminence of maxillary central incisors showing developmental grooves involving both the crown and root.

Descriptions of NMDTs of Human permanent dentition:

Descriptions of most commonly used non metric traits by Scott GR is given below[2]: (Table I, II, III, IV, V, VI, VII, VIII)

Role of NMDTS in Forensic Odontology:

Forensic odontology can help the police in different investigation purposes where the conventional techniques such as DNA profiling and finger prints were not available or not able to perform or certain special situations which demand a forensic odontologist analysis[1]. The usual techniques in forensic odontology include age estimation by analysing the number and sequence of teeth eruption and radiographic methods based on the stages of mineralization. The analysis of NMDTs has little value in age estimation in the present scenario. However, it can be applied in other situations such as:

a) Gender determination

b) Race determination

c) Anthropology studies

a) Gender determination:

Gender determination from the dentition is not considered as the final word. In the absence of other evidences it can give clues regarding the gender of the subject. Most methods of

Table II Maxillary Canine

Trait	Description
Tuberculum dentale	Tuberculum projections on the basal eminence of maxillary canines. Tubercles show free apexes in few cases
Distal accessory ridge	Presence of an extra ridge on the lingual surface of maxillary canine between essential ridge and distal marginal ridge
Bushman canine	The mesial marginal ridge intersects and joins a dental tubercle without a developmental groove separating the two features.

gender determination by forensic odontology are based on measurements of teeth in various aspects and on the fact that the size of teeth in females is less compared to males. However, certain NMDTs can also be used for this purpose. 'Canine distal accessory ridge' a NMDT located on the lingual surface between the medial lingual ridge and distal marginal ridge has been found to show sexual dimorphism. This ridge is more pronounced and more frequency found in males than females.[1]

Abrantes C et al (2015) investigated the application of 16 NMDTs as a potential qualitative method of sex classification in medico-legal identification performed by ASUDAS method in a Portugese population sample of 53 males and 57 females. The results of the study were not as significant as expected except for the dental tubercle of permanent maxillary right canine, for the metaconule of permanent maxillary left second molar and the canine distal accessory ridge of mandibular right and left permanent canines.[10]

'Diflecting wrinkle' is the most widely used non metric trait in differentiating gender in humans. According to studies by Alt KW et al (1988) and Scott GR et al (1997) this trait is present only in lower first molars of men.[11,12,13]

b) Race determination:

Certain NMDTs are known to show population variation which can be used to distinguish the ethnicity or ancestry.

Sejresen B et al (2005) analysed a collection of 80 historical skulls of unknown origin housed in Institute of Forensic Medicine, Copenhagen with morphological and morphometric techniques. For each skull four non-metric dental traits using the ASUDA System and three non-metric cranial traits were recorded. Nineteen cranial measures were also taken following the FORDISC programme manual. Observed non metric trait frequencies were compared with published data and FORDISC programme computed a discriminatory analysis for each skull and thereby assigned the skull to the most probable ethnic category. The non-metric traits showed 80% expected frequencies and FORDISC programme provided 70% accuracy.[10]

Table III Maxillary premolars

Trait	Description
Uto-Aztecan premolar	A pronounced buccalward rotation of the distal margin with associated fossa or pit in the first premolar.
Accessory ridges	Additional ridges present on either side of the median ridges on the occlusal surface of the buccal cusp of premolars
Odontomes	Cone shaped accessory coronal tubercle located on the central occlusal groove between the buccal and lingual cusp of premolars
Upper premolar root number	Upper premolars can express one, two or three independent roots. UP1 should only be considered to have two roots when the inter-radicular projection extends from 1/4 to 1/3 of total root length

Uthaman C et al (2015) assessed the distribution and degree of expression of cusp of Carabelli of maxillary permanent first molars and shovelling traits of maxillary central incisor between three ethnic groups of Coorg, namely Kodavas, Tibetans and Malayalees. They found statistically significant difference in shovelling trait among the three groups. But for Carabelli's trait there was no statistically significant differences found.[14]

Nagaraj T et al (2015) after studying the incisor shovelling pattern in a study group of 400 subjects including equal number of participants from East, West, North and South parts of India inferred that this trait was more pronounced in Western part followed by East and North with very minimal positivity in Southern parts of India.[15]

Krithiga M et al (2016) analysed the association between cusp of Carabelli and shovelling trait in 1885 children aged between 7-10 years in a selected Indian population of Banglore city. The results showed positive association between the two traits with 40.5% of cusp of Carabelli on first molar and 68.2% of shovelling in maxillary central incisors.[16]

Table IV Maxillary molars

Trait	Description
Hypocone	Protocone, paracone, and metacone are the three cusps present in molars of the primates in evolutionary history. Hypocone is an additional cusp originates from the distolingual cingulum and is treated as one of the four major cusps now.
Carabelli's trait	A tuberculum projection on the mesiolingual cusp of the upper molar which ranges from a slight deflected developmental groove to a large free standing cusp that is almost the size of a hypocone
Cusp 5	Accessory cusp located on the distal marginal ridge between metacone and hypocone.
Mesial marginal accessory tubercles	Three tubercles can be observed on the mesial marginal ridge of upper molars associated with paracone (mesial paracone tubercle), the protocone (protoconule) and the marginal ridge between paracone and protocone.
Enamel extensions	The cervical line deflects from typical mesio-distal straight course to the root in the area separating the mesial and distal roots. This enamel extension ranges from slight to pronounced and may terminate in an enamel pearl in the later.
Upper molar root number	Upper second molar may show variability in root number ranging from one, two or three. Fusion of two or more root cones produce reduced root number. To record root number, each distinct root should have an inter-radicular projection (bifurcation) at least 1/4 to 1/3 along the total length of the root complex.

c) Anthropology:

Non-metric dental traits are also used in the field of anthropology for analysing the dental tissues of archanic humans in the view of anthropology.

Martin RMG et al (2017) analysed certain nonmetric and metric traits at the enamel dentine junction (EDJ) of maxillary and mandibular molars of Neanderthals. Non-metric traits at the EDJ such as crista oblique, cusp 5, and post-paracone tubercle were analysed. They also compared the results with modern humans as well as between earlier and late Neanderthals at every molar position. They concluded that EDJ morphology can discriminate with high degree of reliability between Neanderthals and recent modern human beings at every molar position and between earlier and late Neanderthal samples at every molar position except in third molar shape space.[17]

A previous claim exists in anthropology that the H. florensis was evolved from a form of hominis Australopithecus or H.habilis like primitives. Kaifu Y (2015) et al analysed the NMDTs such as occasional absence of a maxillary first premolar buccal groove, a distally positioned mandibular first premolar lingual cusp, a more circular mandibular second premolar crown, the presence of a mandibular second premolar transverse crest, non-parallelogram maxillary second molar crown shape, a short mandibular second molar crown, a mandibular first molar mid-trigonid crest, equivalent mandibular first and second molar sizes, and a moderately wide alveolar arcade revealed none of

Table V Mandibular incisors

Trait	Description
Shoveling	Similar to maxillary incisors but not much prominent probably due to the smaller size of lower incisors.
Winging Tuberculum dentale	Similar to maxillary incisors but seen rarely.

Table VI Mandibular Canine

Trait	Description
Distal accessory ridge	Accessory ridge expressed on the lingual surface of canine between the median ridge and distal marginal ridge on the distal lobe segment.
Root number	The only anterior tooth which may show two roots. When the bifurcation of the buccal and lingual root cones occur in no less than 1/4 to 1/3 of total root length it can be considered as a two rooted tooth

Table VII Mandibular premolars

Trait	Description
Lingual cusp number	Single buccal cusp with extreme variation in lingual cusp/ cusps. -Lingual cusp fused to buccal cusp which lacks a free apex. -Well developed, mesially positioned lingual cusp - Extra lingual cusp on the ridge extending distally from the primary lingual cusp
Accessory ridges	Presence of mesial or distalaccessory ridges on the occlusal surfaces of the buccal cusp (protoconid) exhibiting on the accessory lobe segments
Odontomes	Con shaped accessory coronal tubercle located on the central groove between buccal and lingual cusps.
Tome's root	Rare distinct bifurcation along buccoligual plane results in two roots with slight to moderate separation.

Table VIII Mandibular molars

Trait	Description
Hypoconulid	Mandibular molars have five cusps and the distolingual cusp is called hypoconulid. Hypoconulid may show reduction in size or complete elimination. The number of cusps considered in this trait.
Groove pattern	The major cusps are separated by developmental grooves. Three groove patterns are commonly observed. The groove between cusp 2 and 3; the groove between cusp 1 and 4; the groove between all the four cusps in a molar.
Cusp 6 (tuberculum sextum)	The supernumerary cusp positioned between entoconid (cusp 4) and the hypoconulid (cusp 5) referred to as cusp 6.
Cusp 7 (tuberculum intermedium)	The supernumerary cusp, situated between metaconid (cusps 2) and entoconid (cusp 4).
Protostylid	A cingular derivative, located on the mesiobuccal cusp often associated with the buccal groove between the protoconid and the hypoconid
Deflecting wrinkle	The essential ridge of metaconid usually runs a straight course from the cusp tip to the central occlusal pit. However, in some cases, this ridge begins with a more mesial orientation before changing course toward the center of the tooth.
Root number (LM1)	A supernumerary root that can develop on the lingual border of the distal root other than the two usual roots called distolingual root.
Root number (LM2)	Reduction in root number from two to one due to fusion of roots for at least 1/4 to 1/3 of total root length.

them are very primitive traits to correlate a relation between them and Australopithecus or H.habilis. Instead they may originate from post habilis grade Early Pleisteocene Homo from East Africa, Java and Georgia.[18]

Luckas JR and JN Pal (2013) analysed 43 non-metric tooth traits of a Mesolithic lake culture (MLC) from the North India. They compared the results to a global sample and inferred that MLC's closest affinities to the Chenchu, a living tribal group of Andhra Pradesh The next closest affinity is with Chalcolithic and Neolithic groups of Pakistan and with a late Chalcolithic group of west central India.[19]

Advantage of using Non metric dental traits in forensic odontology:

a) It helps for sexual diagnosis
b) Helps to detect ancestry detection
c) Dental morphologies help in distinguish between adult individual of different racial orgin
d) Used to identify relatedness between individuals[20]
e) Biodistance studies using dental nonmetric traits can be used to identify linguistic and genetic evidence to reconstruct large migration[21]

Limitations of using non metric dental traits in forensic odontology:

a) Subjective: cannot discretely quantified, but reflect training and experience of investigators
b) Experience of investigator: While evaluating ethnicity, the NMDTs least commonly seen by the investigator may prove to be crucial[22,23]
c) Geographic variations in trait expression[2]

The use of NMDTs in anthropology and forensic odontology requires standardization of the traits. Earlier the mere presence or absence of the traits were observed in a dichotomy manner and received only a little importance. The non metric dental trait analysis is now considered as a good method for studying the biological differentiation of skeletal populations. This can be used as an excellent tool for dental morphology investigations.

► References:

1. Krishan K, Kanchan T, Garg AK. Dental Evidence in Forensic Identification - An Overview, Methodology and Present Status. Open Dent J. 2015;9:250–6.
2. Scott GR. Biological anthropology of human skull. 2nd ed. Johm Wiley & Sons; 2008. 265–266 p.
3. Wilson C. The Relationship between Size and Expression of Nonmetric Traits on the Human Skull, The arbutus review.2010;1:81-97
4. Baby TK, Sunil S, Babu SS. Nonmetric traits of permanent posterior teeth in Kerala population: A forensic overview. J Oral Maxillofac Pathol. 2017 May 1;21(2):301
5. Yu. Khudaverdyan A. Non-Metric Dental Traits in Human Skeletal Remains from Transcaucasian Populations: Phylogenetic and Diachronic Evidence. Anthropol Rev. 2014 Jan 15;77.
6. Khudaverdyan A. A dental non-metric analysis of the Classical/Late Antiquity period (1st century BC–3rd century AD) population from Armenian Plateau. Pap Anthropol. 2014 Nov 7;23(2):47–66
7. Hrdli- ka A. Shovel- shaped teeth. Am J Phys Anthropol. 1920 Oct 1;3(4):429–65.
8. Hanihara K. Morphological Pattern of the Deciduous Dentition in the Japanese-American Hybrids. J Anthropol Soc Nippon. 1968;76(3):114–21
9. Hanihara K, Tamada M, Tanaka T. Quantitative analysis of the Hypocone in the Human upper molars. J Anthr Soc Nippon. 1970;73(3):200–7
10. University of Lisbon, Pereira CP. Application of Dental Mor- phological Characteristics for Medical-Legal Identification: Sexual Diagnosis in a Portu- guese Population. Forensic Leg Investig Sci. 2015 Dec 17;1(1):1–7.
11. Dental Profiling in Forensic Science - Semantic Scholar [Internet]. Available from:paper/Dental-Profiling-in-Forensic-Science-Vodanovic Brki%C4%87/4179fd943d68d66b71de07784ce1e2920147f352
12. Dental Anthropology - Fundamentals, Limits and Prospects | Kurt W. Alt | Springer [Internet]. [cited 2018 Apr 22]. Available from: https://www.springer.com/in/book/9783709174982
13. Pietrusewsky M. The anthropology of modern human teeth: Dental morphology and its variation in recent human populations. Am J Phys Anthropol. 1998 May 1;106(1):101–3.
14. Uthaman C, Sequeira PS, Jain J. Ethnic variation of selected dental traits in Coorg. J Forensic Dent Sci. 2015 Sep 1;7(3):180.
15. Nagaraj T, Sherashiya PA, Hemavathy S. Regional variation in incisor shoveling in Indian population. J Adv Clin Res Insights. 2015;2:193–6
16. Kirthiga M, Manju M, Praveen R, Umesh W. Ethnic Association of Cusp of Carabelli Trait and Shoveling Trait in an Indian Population. J Clin Diagn Res JCDR. 2016 Mar;10(3):ZC78–81
17. Martin RMG, Hublin J-J, Gunz P, Skinner MM. The morphology of the enamel-dentine junction in Neanderthal molars: Gross morphology, non-metric traits, and temporal trends. J Hum Evol. 2017;103:20–44.
18. Kaifu Y, Kono RT, Sutikna T, Saptomo EW, Jatmiko, Due Awe R. Unique Dental Morphology of Homo floresiensis and Its Evolutionary Implications. PLoS ONE [Internet]. 2015 Nov 18
19. JN LJ and P. Dental morphology of early Holocene foragers of North India: non-metric trait frequencies and biological affinities. - PubMed - NCBI [Interne]
20. Garrette E W. Community Identity and the archeological complex of tucume, peru: A synthesis of cranial and dental non metric variation. B.A. University of West Florida.2015;1-205
21. Marado M L. Charecterization of the dental morphology of a Portuguese sample from the 19th and 20th centuries. Universidade de Coimbra.2014:1-544
22. Sejrsen B, Lynnerup N, Hejmadi M. An historical skull collection and its use in forensic odontology and anthropology. J Forensic Odontostomatol. 2005 Dec;23(2):40–4.
23. Gulaty R. Non metric dental traits for forensic profiling:assessment and comparison of a western Australian and a north Indian population. The university of western Australia.2011;1-251.

Customization and precision in orthodontics: current and future perspectives

*Asni Shebad A.

Abstract

The orthodontic specialty has observed many paradigm shifts since its evolution 119 years ago. Customization and precision is the current paradigm shift in the speciality of Orthodontics. Contemporary orthodontists need to have a thorough understanding of the advanced imaging technologies and craniofacial biology and genetics to bring precision and customization into practice. The objective of this article is to provide a background on emerging advances in 3D imaging, computer technologies and biomedicine and emphasize their current and likely futureapplications.

KDJ 2019 | Vol. 42 | No. 1 | Pg 60-63

► Introduction

Traditionally dental and medical treatment is based on an examination and assessment of the patient's status, diagnosis, and prescription of treatment. The treatment is usually based on a likely positive response in the majority of individuals with the diagnosis. While this approach will work for most patients most of the time, it may not be the optimum treatment for others. Each individual is unique with his or her own genetic build up, environment and lifestyle.

In Orthodontics and dentofacial orthopaedics, force is the medicine that is used to correct various malocclusions. Because of the above mentioned individual variability, each individual will respond to orthodontic treatment in a different manner. It is in this juncture that the role of customized appliances with individualized treatment mechanics and biomodulation come into play. This is essentially an extension of the precision medicine technique which is an emerging approach for disease treatment and prevention that takes into account individual variability in genes, environment and lifestyle for each person. The development, progression, and treatment outcomes associated with certain diseases and disorders exhibits much individual variation[1].

The human genome project was a breakthrough in developing a "map" or understanding of not only how we are so similar in our genome, but how variation occurs among us. Our genome varies from one individual to the next, most often in terms of single base changes of the DNA called single nucleotide polymorphisms (SNPs, pronounced "snips").[1] This recognition of genetic basis for heterogeneity of response to treatment of many diseases led to a new paradigm in medicine known as precision medicine.

Precision medicine can be stretched to Orthodontics to modulate orthodontic and orthopaedic effects according to the genes, environment and lifestyle of each individual. Moreover orthodontics is a science that involves the use of various appliances and technologies for effecting tooth movement and skeletal changes. So in the case of orthodontics, the typical definition of precision medicine broadens to the application of customized appliances and force delivery to tissues.

This article tries to give a glimpse into the ongoing evolutions in customization and precision and their future applications Orthodontics.

► Customization and precision of technology in orthodontics

3D imaging and computational technology

Advances in imaging technology now deliver accurate 3D digital representations of skeletal, soft tissue and dental anatomy at high resolution. It is now possible to visualize the virtual patient by creating an integral fusion model combining the data from all 3 important tissue groups using a CBCT reconstructed bony volume, digital dental models, and a textured facial soft tissue image. This model is highly effective in precisely diagnosing the problem in all 3 planes of space. This has enabled clinicians to accurately plan surgical movements in the virtual environment and generate highly accurate surgical splints using

*Post Graduate Student, Dept. of Orthodontics and Dentofacial Orthopedics, MES Dental College, Perinthalmanna
• Correspondence author: Dr Asni Shebad A, E-mail: asnishebad@gmail.com

the computer-aided design/computer-aided manufacturing (CAD/CAM) technique for effective treatment outcomes.[2]

Several surgical planning software including Virtual Surgical Planning (VSP®) Technology (3D Systems; Littleton, CO, USA), Simplant and Proplan (Materialize; http://oo.simplant.com), IPS Case Designer (Medicim; Belgium), and In Vivo5® (Anatomage; San Jose, CA, USA) integrate CT/Cone Beam CT (CBCT) data, 3D stereophotogrammetry, and intra oral occlusal scans to generate a comprehensive 3D model. Dental movements and surgical osteotomies may be simulated interactively between the surgeon and the orthodontist. The final clinical plan is transferred into an intermediate and final splint, which is typically 3D printed.[3]

Surgery first approach in the management of skeletal malocclusions has become more popular due to the advantage like decreased treatment time largely by providing favourable biologic effects to accelerate tooth movements (e.g. regional acceleratory phenomenon or RAP). Position of the final jaw and tooth relationships must be estimated prior to the surgery first approach. Custom fabrication of surgical splints and stainless steel arch wires through 3D digital treatment simulation allows both dental and skeletal movements to be planned and executed precisely and simultaneously. This approach has been shown to reduce treatment time, reinforce decompensatory tooth movements, and provide rapid improvements in aesthetics.[3]

Virtual orthodontic movements can be similarly planned and applied. Software such as In Vivo5® (Anatomage), Orchestrate® (Orchestrate 3D), and OnyxCeph3TM incorporates data either from CBCT or intra-oralscans or models, and allows individual tooth movements to be programmed and sequenced. The orthodontist creates a virtual set-up of the final occlusion, as well as the sequence and pathway for tooth movements. Sequenced models or aligners can be fabricated with a relatively inexpensive 3D printer in a dental laboratory or in the orthodontist's office.

Sure Smile technology (OraMetrix, Richardson, Tex) is a type of computer-assisted orthodontic treatment in which an intraoral dental scanner (OraScanner; OraMetrix) and 3D software generate accurate and reliable 3D digital models from which virtual treatment plans are obtained through a software interface. The planned treatment can be accurately translated to the patient using robotically assisted archwire bending technology, thus possibly improving the overall treatment efficiency and quality.[2] Insignia® (Ormco; Orange County, CA, USA) is another such treatment system through which custom archwires or orthodontic brackets are fabricated to produce sequenced tooth movements.[3] Incognito™ (3M Unitech) appliance system is another giant leap forward in orthodontic technology that provides fully customized lingual orthodontic appliances.[4]

Smart appliances

Patient compliance is considered as a critical unknown variable in orthodontic treatment outcome with removable appliances and retainers. Since a precise quantification of the appliance wear is difficult it is challenging for the orthodontist to determine whether poor results are caused by poor patient compliance or by an ineffective appliance. Removable appliances incorporated with microsensors that objectively measure the wear time is a solution for this. SmartRetainer® {Scientific Compliance (Atlanta, Ga)} (Fig. 1, 2) and Theramon® are two

Fig. 1A: Maxillary plate with SmartRetainer®, B:Maxillary plate with SmartRetainer®placed onto the proprietary USB-powered Smart Reader, within a few seconds a wireless communication link is established and all the information recorded since the last read-session is automatically downloaded, decrypted, further analyzed using proprietary algorithms for trends and use patterns.

examples for such retainers.

The SmartRetainer® environmental microsensor automatically and at preset intervals monitors the oral environment around it, and either stores the data or an empirical decision about the data in an encrypted form. This information is later used by software in the orthodontist's office to determine retainer wear frequency and duration. When an orthodontist or a staff member places a retainer with an integrated Smart Retainer environmental microsensor onto the proprietary USB-powered Smart Reader, within a few seconds, a wireless communication link is established, and all information recorded since the last read session is automatically downloaded, decrypted, further analyzed by using proprietary algorithms for trends and use patterns, and presented to the user in easy-to understand charts. The orthodontist can in turn discuss actual retainer usage vs prescribed retainer usage with the patient and the parent and make data-driven recommendations about future retention.[5]

Precise understanding of the magnitude and direction of force application by orthodontic appliances will lead to better control of tooth movement and treatment outcome. Knowledge of the biomechanical changes in the loaded tissues and the mechanisms of tissue response on an applied force are difficult to study because the stress/strain in a periodontal ligament cannot be measured directly and must be derived from mathematical models.[6] 3D Finite element analysis is a useful tool to examine the amount of force applied during traditional rapid maxillary expansion. In order to allow optimal and individualized treatment, it is essential to measure the 3D forces delivered by the expander. Goeckner et al. recently measured the Three-Dimensional force during rapid palatal expansion in Sus scrofa (freshly euthanized pig), by combining experimental measurements of strain in the palatal expander with 3D finite element analysis.[6] Similar approach may be used to monitor how the magnitude and direction of forces are disseminated to teeth and bones in either tooth or bone-anchored expanders, and the information utilized for optimized activation of the device.

Smart brackets with integrated sensor chips in fixed orthodontic appliances provide objective information about the forces and moments exerted on the teeth. The sensor systems enable the measurement of six components of force and moment vectors acting on each tooth during orthodontic treatment.[7]

SmartArch® orthodontic wires (Smart Alloys;Waterloo, ON, Canada) area revolutionary new archwire that allows orthodontists to simultaneously apply different forces to different teeth. Programing the stiffness of the wire to match the needs of individual teeth may contribute to increased treatment efficiency and fewer office visits for archwire changes.[8]

► Biomodulation in orthodontics

Mechanical, surgical and biologic modulation of tooth movement

There are mainly four methods for altering tooth movement, whether it is to speed up movement for accelerated orthodontic treatment or to decrease movement for anchorage or retention:[3]

(1) Appliance-based variables such as force levels, types of forces, and contemporary wires and appliances;

(2) Physical/mechanical stimulito teeth and bone;

(3) Surgically facilitated orthodontic treatment (SFOT) that results in RAP; and

(4) The local application of bioactive mediators.

Appliance-based approaches consist of the use of various archwires and materials, intermittent forces and specific brackets. Physical/mechanical stimuli include supplemental devices such as vibratory forces (e.g. Acceledent®, OrthoAccel Technologies; Houston, TX, USA), pulsed electromagnetic fields (PEMF), electrical current and low-level lasers. Surgery First Orthododontic Treatment and RAP-related techniques include surgery first orthodontics, corticotomy, Wilckodontics or Periodontal Accelerated Osteogenic Orthodontics (PAOO), dentoalveolar or periodontal, piezocisionor minimally invasive corticotomy, and alveocentesis or micro-osteo perforations (e.g. Propel Orthodontics, New York, NY). Biologic/pharmacologic-supplemented tooth movement comprises the local delivery of proteins, drugs designed to mimic biomolecules, and gene therapy using biologically validated pathways that regulate bone turnover.[3]

Of these methods, biologic or pharmacologic-supplemented tooth movement hold promise for precision orthodontics. The differentiation and activation of osteoclasts, the predominant bone-resorbing cells, is a critical rate-limiting step both in bone degradation to enhance tooth movement and bone maturation for enhancing post-orthodontic stability. Osteoclast differentiation and activation is primarily mediated by Receptor activator of nuclear factor kappa-Bligand (RANKL), which is expressed by osteoblasts and binds to RANK (RANKL receptor) present on the surface of pre-osteoclasts, thus activating bone resorption. On the other hand, osteoprotegerin (OPG) is a decoy ligand that competes with RANKL for binding to RANK therefore decreasing bone turnover.[9] With this information, investigators have effectively utilized RANKL protein[10] or gene therapy[11] to expedite tooth movement or OPG[12] to enhance anchorage or minimize post-orthodontic relapse.

Iglesias-L A et al.[13] compared corticotomy-like Surgery and local delivery of RANKL in rats and found that RANKL was more effective in enhancing the rate, magnitude, and duration of Orthodontic Tooth Movement than corticotomy.

Several other studies utilizing bioactive agents known to modulate bone turnover have been shown to increase or decrease tooth movement. Biologic mediators such as human growth hormone, nitric oxide, osteocalcin, parathyroid hormone, prostaglandins, and vitamin D have all shown to increase Orthodontic Tooth Movement. Whereas, OPG, bisphosphonates, butoxamine, echistatin, estradiol, MMP inhibitor, nitric oxide synthase inhibitor, and prostaglandin inhibitors contribute to decreased tooth movement.[3]

Biomodulation of skeletal growth in skeletal malocclusions

Many skeletal malocclusions are complicated with an underlying genetic etiology. Familial aggregation studies suggested that an autosomal dominant model with incomplete penetrance has the greatest validity for Class III pedigrees,

including the royal Habsburg family. In contrast, polygenic inheritance and autosomal dominance models, with incomplete penetrance and variable expressivity, have been suggested for Class II subdivision 1 and 2, respectively. The frequent presentation of malocclusion in patients with craniofacial birth defects also supports a strong genetic etiology.[14]

Several candidate genes have been identified for the development of skeletal malocclusions. For instance, FGFR2 (fibroblast growth factor receptor 2) and EDNI (endothelin-l) Single Nucleotide Polymorphisms (SNPs) are associated with increased and decreased risk of developing class II skeletal malocclusion, respectively.[15] Increased risk of class III malocclusion was associated with SNPs of FGFR2, COLIAI (collagen type 1A), ARHGAP21 (RhoGTPase Activating Protein 21)[16] and PLXNA2 (Plexin A2) to mention a few. Genes implicated in bone (TGFB3, LTBP, IGF1, ENPP1, EVC, and EVC2), cartilage development (Matrilin-1 and COL2A1), muscle function (MYO1H and DUSP6) and tooth morphogenesis (EDA, XEDAR, and BMP2), may be presumed candidates for jaw and tooth size discrepancies.[17]

A study conducted by Ealba ELet al.[18] in birds showed that altering osteoclasts during development led to changes in beak lengths. Briefly, when osteoclasts were inhibited in ovo using the bisphosphonate alendronate, OPG, or an MMP-13 (matrix metalloproteinase-13)inhibitor, there was an increase in lower beak length; conversely, an increase in osteoclasts with injection of recombinant RANKL resulted in shorter lower beaks.

Many studies have shown the growth modulation of mandible using injections of insulin like growth factor (IGF-1) in rat models.[19,20] Further research using animal models to decode the cellular and molecular mechanisms of craniofacial growth followed by human clinical trials are needed for the use of biologic or pharmacologic agents to alter craniofacial skeletal growth. With development of "smart" drug delivery systems using nanotechnology and microchip delivery methods, it will be possible for localization of effects, timed-release, and optimal duration of action of various biomodulating agents.

► Conclusion

In the upcoming era, technologies developed in computational imaging, 3D printing, and biomedicine will be integrated to apply patient-specific orthodontic therapies. In the future, orthodontic therapy may be a process beginning with precise diagnoses based on genetic and 3D phenotypic relationships, planned through virtual simulation, implemented by custom fabricated appliances and treatment mechanics, and modulated through biologic or pharmacologic agents that take into account the patient's individual genetics and molecular variability.

► References

1. Hartsfield JK Jr: Personalized orthodontics, The future of genetics in practice. SeminOrthod2008;14:166-71.
2. Janakiraman N, Feinberg M, Vishwanath M, Jayaratne YSN, Steinbacher DM, Nanda R, et al. Integration of 3-dimensional surgical and orthodontic technologies with orthognathic "surgery-first" approach in the management of unilateral condylar hyperplasia. Am J Orthod Dentofacial Orthop 2015; 148 (6):1054–66.
3. Jheon A. H, Oberoi S, Solem R. C, Kapila S Moving towards precision orthodontics: An evolving paradigm shift in the planning and delivery of customized orthodontic therapy, OrthodCraniofac Res, 2017;20(suppl.1):106-13.
4. Buckley J. Lingual orthodontics: an illustrated review with the incognito fully customised appliance. J Ir Dent Ass, 2012;58(3):149-55.
5. Ackerman MB, McRae MS, Longley WH. Microsensor technology to help monitor removable appliance wear. Am J Orthod Dentofacial Orthop 2009;135:549–51.
6. Goeckner K, Pepakayala V, Nervina J, Gianchandani Y, Kapila S. Three-dimensional force measurements during rapid palatal expansion inSus scrofa. Micromachines. 2016;7:64-75.
7. Lapatki BG, Paul O. Smart brackets for 3D-force-momentmeasurementsin orthodontic research and therapy – developmentalstatusand prospects. J OrofacOrthop. 2007;68:377-96.
8. Pequegnat, A.; Panton, B.; Zhou, Y.N.; Khan, M.I. Local composition and microstructure control for multiple pseudoelastic plateau and hybrid self-biasing shape memory alloys. Mater. Des. 2016, 92, 802–13.
9. Huang H, Williams RC, Kyrkanides S. Accelerated orthodontic tooth movement: molecular mechanisms. Am J Orthod Dentofacial Orthop.2014;146:620-32.
10. Nishimura M, Chiba M, Ohashi T, Sato M, Shimizu Y, Igarashi K, et al. Periodontal tissue activation by vibration: intermittent stimulation by resonance vibration accelerates experimental tooth movement in rats. Am J Orthod Dentofacial Orthop 2008;133:572-83.
11. Kanzaki H, Chiba M, Arai K, Takahashi I, Haruyama N, Nishimura M, et al. Local RANKL gene transfer to the periodontal tissue accelerates orthodontic tooth movement. Gene Ther 2006; 13:678-85.
12. Dunn MD, Park CH, Kostenuik PJ, Kapila S, Giannobile WV. Local delivery of osteoprotegerin inhibits mechanically mediated bone modeling in orthodontic tooth movement. Bone 2007;41: 446-55.
13. Iglesias-Linares A, Moreno-Fernandez AM, Yanez-Vico R, Mendoza-Mendoza A, Gonzalez-Moles M, Solano-Reina E. The use of genetherapy vscorticotomy surgery in accelerating orthodontic toothmovement. OrthodCraniofac Res. 2011;14:138-48.
14. Moreno Uribe LM, Miller SF. Genetics of the dentofacial variation in human malocclusion. OrthodCraniofac Res 2015;18(Suppl 1):91-9.
15. da Fontoura CS, Miller SF, Wehby GL, Amendt BA, Holton NE, Southard TE, et al. Candidate Gene Analyses of Skeletal Variation in Malocclusion. J Dent Res. 2015; 94(7):913–20
16. Perillo L, Monsurro A, Bonci E, Torella A, Mutarelli M, Nigro V. Genetic association of ARHGAP21 gene variant with mandibular prognathism.J Dent Res. 2015;94:569-76.
17. Jin YR, Turcotte TJ, Crocker AL, Han XH, Yoon JK. 2011. The canonical Wntsignaling activator, R-spondin2, regulates craniofacial patterning and morphogenesis within the branchial arch through ectodermal-mesenchymal interaction. DevBiol2011;352: 1–13.
18. Ealba EL, Jheon AH, Hall J, Curantz C, Butcher KD, Schneider RA. Neural crest-mediatedbone resorption is a determinant of species-specificjaw length. Dev Biol. 2015;408:151-63.
19. Itoh K, Suzuki S, Kuroda T. Effects of local administration of insulin-like growth factor-I on mandibular condylar growth in rats. Journal of Medical and Dental Sciences. 2003; 50:79–85.
20. Suzuki, S.,Itoh, K., and Ohyama, K. Local administration of IGF-I stimulates the growth of mandibular condyle inmature rats. J. Orthod.2004;31:138–43.

Association News

CDE Report

Dr Jose Paul
Chairman CDE

Keeping updated with the latest trends is a responsibility that lies within oneself. Today's laws are becoming strict to the tune that abstaining from continuing dental education may amount to unethical practice.

Indian Dental association has been recognized as a service provider for continuing dental education. Keeping this in mind CDE wing of IDA Kerala state is planning to conduct at least 8 state CDE's across the state this calendar year.

Our first state CDE was jointly hosted by Kodungalloor and Nedumbassery Branch on 24th of February 2019. A very informative full day program was done on Esthetic laminate Veneers by Dr Eldo Koshy, Dr Sebastian Thomas and Dr Laju Mahesh. A total of 105 members benefitted out of the program.

The second state program will be held on the 28th of april at Kanhangad on the topic 'Myofunctional appliances' by Dr Joby Peter. IDA Coastal Malabar and IDA Kasargod together will be hosting the event.

At the branch level, a number of quality CDE programmes have been conducted. I take this opportunity to congratulate the office bearers of the different branches for the same. Expecting much more to come.....

Malappuram Branch

Installation of New Office Bearers:-

Installation of new office bearers for the year 2019 was held at ' RYDGES INN'Kottakkal on 27 th Jan 2019 at 7 pm. MLA Prof. Abid Hussain Thangal was our chief guest, IDA State secretary Dr. Suresh Kumar G was our guestof honor, IDA state CDH Chairman Dr. Subash madhavan was our special invitee. Dr. Muhamed Haris KT was installed as the President of IDA Malappuram Branch. Other office bearers were installed by the president.

The short film "TEENHOOD" was released on the same day by the chief guest. The movie is showcasing the drug Abuse issues and social problems in teenagers.

A Seminar on clinical Establishment Billwas held at MES Medical college perinthalmanna on 13th Jan 2019. State secretary Dr. Suresh Kumar G and Dr. Deebu J Mathew described about the CE Bill.

CDE

1st CDE 26&27 JANUARY: A two day CDE on conscious Sedation and BLS was Conducted in Association with Educare institute of Dental science. Keynote speakers: Dr. Shipra Jaidka BDS MDS, Dr. Ravi MBBS DA, Dr. Jean K Babu, Dr. Sunil Mohammed BDS MDS.

IIND CDE 24 th FEBRUARY:

Diagnosis and management of oral musosal lesions was held at Airlines Celestial Malappuram. Speakers;Dr Deepu George Mathew MDS, Dr. Jubin Thomas MDS, Dr. Jayesh Unnithan MDS.

CDH

1stCDH Programme;Pains & palliative Day observation 15/01/2019: We observed pain and palliative day with palliative society at palliative centre valanchery. Our president Dr. Muhamed Haris KT handed over 10wheel chairs and 30 air beds to them.

IIND CDH Programme 27/01/2019: A short film" TEENHOOD" release was done by MLA Prof. Abid Hussain Thangal on the day of installation.

III rd CDH Programme 04/12/19;World Cancer Day Observation

An oral Cancer Screening camp was held at Govt. Old Age Home Thavanoor. Around 60 patients were Screened.

IVthCDH Programme08/02/2019: An oral Health Awareness class for Pregnant Ladies and Kids was conducted at Anganwadi East Arikanchira, Tirur in association with WDC Wing of our branch.

Vth CDH Programme 10/02/2019: An Oral Health checkup was held at Darul Islam Madrasa, Varambanala. Around150 patients Participated.

Executive Meeting 11/01/2019: First executive meeting was held at cosmopolitan Club Manjeri. 26 Members attended.

EOGM 24/02/2019: Conducted EOGM at Airlines celestial. 10 Members attended.

Sports

MIDA team cup: conducted a 7, s Football at Footy Arena, Kottakkal. Team Malappuram Devils Were declared as the Champions. Also Organized candle light vigil to pay Homage to the Brave Indian Martyred Soldiers.

Dr Mili James
WDC chairperson

WDC Report

Dr Priya Rajendran
WDC secretary

Dr Mili James and Dr PriyaRajendran are the IDA KSB WDC Chairperson and Secretary respectively for the year 2019. The biggest achievement this year is the formulation of the WDC AWARDS criteria for the first time in the history of IDA in India and also the inclusion of the marks of WDC activities of local branches for the awards for best branch, Branch President and Branch Secretary.

There had been an array of activities by various Local branch WDC, and to begin with is the half marathon (5Km run) conducted by IDA WDC Palakkad branch on 20.01.2019 and six WDC members participated in the marathon.

There was a CDH program by IDA WDC Malappuram on 08.02.2019, an Oral Health care and awareness for pregnant mothers and kids. On 17.02.2019 IDA WDC Trivandrum branch conducted a health talk by the famous Gynecologist Dr VeenaChoodamani for the WDC members.

IDA WDC Alappuzha conducted a CDE program on 24.02.2019 on "Successful dental practice" with Dr Mili James, Dr PriyaRajendran and Our IDA KSB Hon. State Secretary Dr Suresh Kumar G being the faculties for the program.

Sl no	Branch name	Type of program	Details
1	Malabar	CDH	Breast cancer screening, awareness class & self defense class for WDC Members
2	North Malabar	Honouring of senior WDC Members	Along with Kannur Dental College
3	Costal Malabar	Self defense class	At Pariyaram Dental college
4	Malappuram	CDH	Check up, oral health awareness class, oral health kit distribution, water purifier and kitchen kit distribution
5	Malanad	Honoring of lady members	
6	Tellichery	CDH	Dental Check up, awarenss talk, oral health kit destribution
7	Valluvanad	CDH	Oral health talk, oral health ki to Asha workers at PHC Thirumttcode.
8	Ernad	CDH	Screening camp at orphanage
9	CKK	Honoring	Honoring of senior lady police officers
10	Kodungallur	Inauguration of WDC	
11	TRipunithura	Self defense and E-safety	By POLICE computer cell kottayam and by AdvSreekala
12	Chalakkudy	Women safety class	By women cell of police deptchalakkudy
13	Kochi	CDH	Screening camp, awareness class for kudumbasree workers
14	Smart city	CDH	BCM college principal talk
15	Mavelikkara	Women safety	Inauguration of women safety cell
16	Alappuzha	CDH	Medical by Dr Anuja paediatrician W&C Alappuzha & Dental screening, Destribution of medicines, first aid kits and awareness class for diff abled students
17	Attingal Branch	CDH	Anandatheeram Chathanoor, dental screening camp, awareness talk
18	trivandrum	CDH	Screening camp and distribution of clothing and essential things to the care takers and inmates of Mental Health centre at TVM.
19	Palakkad	Honoring of eminent ladies from diff walks of life.	State Program Hosted by the Palakkad branch
20	Vadakara	Women safety class	Mrs Mallika, Sub inspector of Police Mrs Sunitha& Mrs Saritha, Vadakara

First interbranch CDE by WDC Chalakkudy was conducted on 10.03. 2019 on Principles of tooth preparation ceramic inlays &onlays by Dr Shiva Shankar M.

IDA HOPE REPORT

THE KERALA FLOODS AND THE RESPONSE OF IDA KSB

The floods that devastated Kerala during the last monsoon season was unparalleled in recent history, considering the amount of destruction it caused. The toll it took, in terms of the number of lives lost, people displaced and property damaged were of an unprecedented nature, which the state hadn't witnessed for more than a century. But as disaster struck on one side, the resilience of human spirit was also evident on the other. The whole state of Kerala rose in unison and launched a rescue/rehabilitation effort, on a scale that was never seen before.

IDA disaster relief fund transfer- Malabar branch`

Indian Dental Association, Kerala, as always, responded to the situation promptly and played an active role in both the rescue and rehab efforts. Every local branch of IDA Kerala contributed in cash and kind to aid the rescue operations, and also served the displaced people in the relief camps. Moreover, many of our members individually visited and volunteered their services, in the hundreds of shelter camps that had mushroomed across the state. Once the initial phase of rescue and relief got over, the real challenge was the long term rehabilitation of the victims.

IDA KERALA FLOOD DISASTER RELIEF FUND

Though most of the local branches under IDA Kerala had started collecting to contribute to the state govt's official relief fund, the state office realised that there were many members of our own fraternity who have suffered inexplicable losses in

IDA Palakkad district President Dr Dinesh, Hon Secretary Dr Vipin , President elect Dr Jayakrishnan, WDC Palakkad President Dr Juby and WDC Palakkad secretary Dr Shiji presenting a cheque of Rs 1.5 lakh to IDA Kerala Hope secretary Dr Anwar for IDA KSB Disaster Relief Fund .

this disaster, and since they were never going to be a priority for the authorities, the association had a duty to reach out to them and help them tide over the crisis. Thus the IDA Kerala Flood Disaster Relief Fund was launched.

COLLECTION

The idea to have a fund raising programme, to help our own colleagues affected by the floods, was wholeheartedly welcomed by our members. A separate bank account was opened for this purpose, the details of which was communicated to all the members, and soon contributions started to pour in from across the state and outside.

Every local branch contributed a tidy sum and there were some individual contributions too. Some dental college alumni associations also chipped in and altogether IDA Kerala state collected an amount of Rs.

DISBURSAL OF FUNDS

The first part in dispensing the relief amount was to identify the deserving beneficiaries. An application format was prepared and send to all our members, for the affected doctors to send in their details and quote the estimated amount required. The state office bearers then conducted a tour of the affected areas, to get a first hand information of the situation. The secretaries of local branches were entrusted to collect the applications and make an assessment of the damages incurred.

IDA disaster fund transfer held at Kannur. Dr. Ratnakaran transferring the cheque to Dr. Anil Thunoli.

The applications received were screened by the state office and after gauging the damages, the relief amount was sanctioned.

The total no of applications received was..... and the amount that was disbursed was .....

IDA Kerala flood disaster relief fund was certainly a one of a kind project in the history of our association, which brought to fore the unity and magnanimity of our members in the wake of a crisis.
We express our sincere gratitude to each and every individual who has contributed in some manner, to make this a meaningful venture.

Dr Suresh Kumar G

Handing over the second installment of IDA Relief Fund on 28th October 2018 to President Dr. Ciju A Paulose (Rs. 1,50,000/-)

Mavelikkara Branch

Installation ceremony of IDA Mavelikkara was held on 26 January 2019 @Hotel Travancore Regency Mavelikkara. IDA Kerala State president Dr Abalish was the chief Guest. Mr M Liju Alappuzha DCC President was our guest of honour.

about 150 members and their family members and other invited guests were participated. DR SAMITH V the newly installed president delivered acceptance speech and the Hon Secretory Dr Lalu mc presented the Annual Report of the year 2018. The meeting was followed by variety entertainment programs and a grant buffet dinner

Quilon Branch

1)Installation ceremony & 1ST Family Meet

The 27th installation ceremony & the firstFamily meet was held on 14.01. 2019 at Rotary Hall, Quilon from 7 pm. Dr Manoj Varghese was installed as the president of IDA Quilon & Dr Anney George as the Hon. Sec. Dr Abhilash GS -President IDA KSB was the chief guest & the guests of honour were Dr Jinu Mathew Vaidyan-VP IDA KSB, Dr Alexander K George-VP-Indian Physicians Association & Sri. Kalayapuram Jose.

2)First executive committee meeting

The 1st ECM was held at Hotel Shah International on 23rd January 2019 from 7.30 pm. The meeting was attended by 24 members.

CDH

February:

World Cancer Day: Awareness talk on" Survival of cancer" by Dr Kiran KS -Past President IDA Quilon for the general public & doctors at Kollam District Hospital & a dental screening camp for 148 patients. The highlight of the programme was the donation of a wheel chair towards the Oncology dept. of the hospital. The programme was attended by the Medical Supt., Dpty Supt., nursing staff, interns, CDH Chairman Dr Rinu Francis & 18 dental doctors

WDC

January:

National Oral cancer month & World Cancer day: Awareness talk by Dr Anney George on oral cancer, tips in oral care & the importance of Fluoride for 300 students of Govt. HSS Mangad on 30th January with the demo. of brushing techniques.

30th Jan: National Oral Cancer Month: Awareness Talk:WDC

February:

IDA WDC KSB Charters day & Congenital heart defect awareness week: Awareness talks on 'dental care for children with heart disease' & 'oral care in children with disabilities' were conducted for parents, teachers& care givers by Dr Anney George along with a dental screening camp for 61 children of Vimala Hridhaya Special School, participated by Dr Sherly Abraham-Rep. WDC & three other doctors

14th Feb:IDA WDC KSB Charters day & Congenital heart defect awareness week:

IDA NATIONAL VICE-PRESIDENT

Dr. Pratap Kumar of Central Kerala Kottayam branch and Past IDA State Preisdent 2008-2009, who got elected as National Vice President at Indore IDC 2019. He is an IDA member since 1980

Wayanad Branch

The 14th installation ceremony of IDA wayanad branch was held on January 13, 2019 at Sterling resorts, Sulthan bathery. T.L. Sabu, municipal chairman, Bathery, was the chief guest. State president Dr Abhilash was the guest of honor.

The programme started at 7.30 p.m. with the prayer song. Dr Rejith welcomed the gathering.

Dr Abhilash installed Dr. Sanoj P.B. and his team of office bearers.

The meeting was well attended by the branch members with their families and dignitaries from various organizations.

Dr George Abraham, Dr. Ranjith CK, Dr Jithendranath (IMA) and Mr. Suresh gave felicitation speech.

Eranad Branch

Installation Ceremony&Family meet

On January 13th 2019, our 6th installation ceremony was held at IMA hall, Perinthalmanna. Dr. Suresh Kumar Hon. Secretary IDA Kerala state was our chief guest and installing officer. Dr. Sharafudheen Hon. Secretary IMA, image Kerala state was our guest of honor.

CDH

IDA Eranad Conducted first CDH;Oral screening camp on 21st December at AMLP school Areekode.

IDA Eranad organised second CDH;oral screening camp and awareness class on 23rd December at GLPS, pathiripadam for NSS volunteers and public.

IDA Eranad conducted 3rd CDH;Oral awareness class and oral screening camp on dental health and hygiene at MES HSS school, Mampad on 27th December

IDA Eranad Conducted 4th CDH;Observed world Oral Cancer Day by oral cancer awareness class and dental screening camp on 4th February at manalodi, Nilambur chilla auditorium.

CDE:

IDA ERANAD Conducted First CDE '19 on the topic 'Non surgical management of large peri apical lesion' on 17th February at IMA HALL Perinthalmanna.101 Members ParticipatedFor Theory and 50 Members Participated for Hands on.

Executive Committee Meeting

IDA Eranad Conducted First Executive Meeting on 22nd Feb @ Oleno canto hall Anakkayam

Trichur Branch

The Installation meet of IDA Trichur along with X'mas and New year celebrations was held on 12th of January, 2019 at Hotel Merlin International. The Installation of the new President, Dr. Benil P and his team was done by Founder President, IDA Trichur, Dr. Antony J Maliakal. The meeting was followed by entertainment programs.

A total of 94 members attended the program with their families.

Kodungallur Branch

1. Installation Ceremony of New Office Bearers

Installation of the office bearers of IDA Kodungallur Branch 2018 -19 was held on 9th December 2018 at IMA Hall, Kodungallur at 6.30 pm. Dr. Laju Mahesh was installed as the new president of IDA Kodungallur Branch by Dr. Suresh Kumar G (Hon Secretary, IDA Kerala State) was the Chief guest and Installation officer. Outgoing President Dr. Sunitha Pradeeksh handed over the President's Collar to newly installed President. Hon. Secretary Dr Gogul KG reported the activites of IDA Kodungallur branch for 2017-18. Vote of Thanks was delive

Thiruvalla Branch

CHRISTMAS CAROLS

Our branch went for Christmas carol rounds on December 19th & 22nd. We visited about 45 houses of our members. A variety of Christmas carol songs were sung by our members. The carol rounds helped us to strengthen the bonds between our families. A charity box collection was also taken for charity work.

INSTALLATION OF OFFICE BEARERS 2019

The installation ceremony of our branch was held on December 8th 2018 at VAIDHYANS Auditorium Manakkachira, Thiruvalla.

Dr Akhilesh Prathap was sworn in as the president, Dr Thomas Jacob as Hon: Secretary, Dr Lanu Abraham as Treasurer. The Chief guest of the meeting was the then president Elect of IDA Kerala State Dr Abhilash G S. More than 100 members with family attended the function.

ACADEMIC & INTERACTIVE SESSION 2019

An Academic and interactive session was held on 27th January 2019 from 6 pm to 9 pm on the Topic PERIODONTICS for PRACTICE ENHANCEMENT by Dr Annie Kitty George, Associate professor, pushspagiri College of Dental science at Righteous path Hall.40 members attended the session.

Alappuzha Branch

Installation ceremony of 20th president Dr. Suresh P. Mathew and his team of office bearers of IDA ALAPPUZHA 2018-19 along with the chief guest Dr. Ciju A. Paulose President IDA state at majalis muziris hall, Alappuzha on 30.12.18

Chalakkudy Branch

Installation ceremony of ida chalakudy held on 20th january sunday at 6;30 pm. at hotel meadows chalakudy

The new office under the leadership of Dr. George Sebastian pullan as the president of ida chalakudy took oath from the installation officer Dr. Varghese mani.

Dr. Anjo jimmy is the secretary for the year 2019 and Dr. Lijesh Sunny is the treasurer for the year 2019.

We IDA Chalakudy Conducted Our 1st CDH Camp " *MANTHASMITHAM 2019* "

Oral Cancer Awareness Camp to observe World Oral Cancer Day In Divine Care Centre Meloor On Sunday 03-02-2019 At 10am

Divine care centre is a shelter for differently abled individuals (with an altered mental health)

They where one of the most flood affected community around chalakudy

People over there have been left to be taken care by philanthrophists

225 people where screened totally by 18 doctors n as it is a legacy project under chalakudy all further needed treatments will be carried out step by step for coming years.

Kottarakkara Branch

1. Installation of Dr Baiju P Sam and team on 26th January 2019. Dr Suresh Kumar G was the chief guest. Dr Jinu Mathew Vaidyan and Dr Biju A Nair were the guests of honour.

2. Candle light tribute to the brave martyrs of Pulwama on 16th February 2019

Nedumbassery Branch

Installation of Dr Abdhul Rafeekh &Team of office beares held at Hotel Le Maritime Kochi.

1st Vice president Dr Jinu Vaidyan was our chief guest and installation officer.

Cine artist Mr Asif Ali coloured the event with his charming nature and inaugurated IDA year activities.

IPP Dr Teny Mathew Welocmed the gathering and Secretary Dr Seby Varghese payed the vote of thanks.

It was really a five star function with member involvement & cultural activities.

Malanadu Branch

Installation ceremony: 12-01-2019

Installation ceremony of Dr Litto Manuel and his team of office bearers was held at hotel kabani, muvattupuzha. Dr Abhilash G, President IDA KSB was the chief guest and Dr Shaji Joseph, President, KDC was the guest of honour.

Executive Meeting: 22-01-2019: 1st Executive meeting of IDA Malanadu was held on 22-01-2019 at hotel kabani, Muvattupuzha

CDE Activities: First cde programme conducted by ida malanadu was held on 03.02.2017 at Hotel kabani International, muvattupuzha

Topic: "Management of deep caries and trauma in paediatric dentistry " By Dr. Kavita Vijit MDS And "Implications Of CE And Consumer Protection Acts Explained". By Adv. Shyam Padman.

CDH Activities:

1. IDA malanadu in association with Al azhar dental dental college, thodupuzha observed "NATIONAL ORAL CANCER AWARENESS MONTH " on 7/1/2019 at mangattukavala busstand thodupuzha, the program consisted of Flashmob, pamphlet distribution and Skit. The program was inaugurated by IDA State Executive member Dr Benny Augustine, Dr Zaheer (Dept Of Public Health Dentistry, Al Azhar Dental College) given the Oral Cancer awareness talk, and vote of thanks by Dr Amal E. A (CDH Chairman IDA Malanadu). Dr litto manuel (President Ida malanadu), Dr Pradeep Philip George, Dr Deepak kalarickal, Dr Ruby pradeep, Dr Jayesh J Unnithan were actively participated in the event. A crowed over 500 people benefited by the program

2. 8-01-2019: IDA MALANADU conducted checkup camp for the inmates of EMMANUEL SNEHASRAMAM. The camp was led by Dr Amal E A, DrJjayesh j unnithan Dr kavya and Dr Nimisha, Dr Amal conducted the awareness class for the students, screeing camp was benefitted for 165 inmates.

3. 4-02-2019: IDA MALANADU conducted checkup camp for the students and staff of Darul fatheh ilamic complex, Kunnam, Thodupuzha. The camp was led by Dr litto and Dr Amal E A, Dr Amal conducted the awareness class for the students.

4. 04-02-2019: Ida Malanadu observed world cancer day by conducting pencil drawing competition in the theme "Drug free kerala", and awarness class for the students of Al azhar public school, Thodupuzha. The awarness class taken by our past national president Dr Elias Thomas, Dr Merlyn Elias led the " Anti tobacco pledge for the students, Prizes distributed for the first, second and third prize in upper primary and high school category which was done by Dr Elias thomas, Dr litto manuel and Mr Noushad Kassim.

5. 17-02-2019: IDA MALANADU conducted dental camp at GHSS Mamalassery on 17/2/2019 in association with V.S Narayanan charitable foundation, The programme was inaugurated by Agricultural Minister. Shri V. S. Sunil kumar, and Shri Anoop Jacob MLA presided the function, Our Team was consisted of Dr Litto Manuel, Dr Amal E. A, Dr Jayesh J Unnithan, Dr Moushmi, Dr Noushin and Dr Elsa maria. Dental awareness classes, dental examination and dental kit distribution was done at the camp.

WDC Activities

WDC Of IDA Malanadu conducted a Program on How to adopt a healthy lifestyle on January 26th at rifle club, Thodupuzha. Faculty was Asha Krishnan, Nutritionist.

Kochi Branch

Dental camp was conducted at Sub Jail, Mattanchery on 26th January 2019 (Republic Day). A dental check up was organised for around 60 prison inmates and their authorities. Free mouth wash and oral hygiene kits were distributed.

The bike rally as a part of Cancer awareness programme

On February 4th an Oral Cancer Detection and Awareness was conducted at Gujarathi College, Mattanchery in association with Rotary, Fort Kochi with precancerous lesion detection.

dental check up camp held for students of Vidyodaya School, Thevakkal on 14th February 2019.

Installation Ceremony

Smart City Branch

The 32nd branch of IDA Kerala State, smart city, kakkanad was Inaugurated on15th Dec by Dr. M.C Dileep Kumar at Hotel. Royal Residency with the presence of State President Dr. Ciju A Paulose and secretary Dr. Suresh Kumar. All members from the branch and guest from the state attended.

1st Bimonthly meeting & 1st Executive meeting was held on Jan 15th with talk by Civi Pulayath (Topic Know Problems No Problem).

Ist CDE was conducted on 1st and 2nd Feb at Amirtha School of Dentistry by Lanka Mahesh (2nd day CDE Include live Surgery Hands on and lectures) Second executive meeting was conducted on Feb 18th.

Kasargod Branch

1. Executive committee meeting was held on 2nd January 2019, at IMA hall Kasargod. Office bearers and programmes to be conducted in the year 2019 were discussed.
2. Installation ceremony was conducted for the office bearers of 2019 on 25th January 2019, Friday, at IMA hall Kasargod
3. 1st CDE programme was conducted on ABC's Of Implantology on 25th January 2019, Friday at IMA hall Kasargod. Total of 53 members participated in the programme.

Tellichery Branch

1)INSTALLATION OF NEW OFFICE BEARERS 2019

Installation of office bearers of IDA Tellichery Branch was held on 2nd February 2019 at hotel Victoria, Thalassery. Program started at 7pm. Dr. Anil Thunoli, Vice president of IDA was the chief guest. Dr. Arun Narayan, Principal of Kannur Dental college was the guest of honor. Dr. Preetha Rajeev welcomed the gathering. Dr. Anil Thunoli installed Dr. Mohamed Jamsher as the president of IDA Tellichery branch. Other office bearers were also installed. Felicitations were given by Dr. Thasneem and Dr. Johny Sebastian. Momentos and gifts were presented to the delegates. Dr. Arun Shyam, the secretary delivered vote of thanks. Installation was followed by entertainment programs, music nights etc. It was a well attended function by our members.

2) Organized a candle light vijil to pay homage to martyrs who sacrificed their life for our nation at Pulwama on 20/2/2019 at overburys folly, Thalassery.

Malabar Branch

Installation Ceremony of New Office Bearers & Family Meet-1

Installation of the office bearers of 2019 was held on 3rd february 2019 at Hotel Malabar Palace Kozhikode at 10.00am. Dr Susha C.N was installed as the new president of IDA Malabar Branch by Dr. Suresh Kumar (Hon Secretary of IDA Kerala State) was the Chief Guest and installation officer. Votes of Thanks were delivered by Dr. Navajeevraj M.N. (Hon. Secretary IDA Malabar branch) followed by lunch.

CDH Activity-No.3 "World cancer day"

CDH organised various cancer awareness programs on 04.02.2019.

Dr Sudheesh Manoharan, Consultant, Surgical Oncology, MVR Cancer centre had taken scientific talk on oral cancer for the doctors and cancer awareness to the public. An interaction with Cancer survivors was organised and shared their experiences. A massive campaigning was also conducted among the members of IDA malabar by taking Photoclick with awareness poster showing the theme of world cancer day 2019 "I am...And I will"

Pamphlets on cancer awareness in malayalam were distributed to the public.

Executive meeting- No.1

1st Executive meeting was held on 13.02.19 at IDA hall, Kozhikode, many upcoming programs were discussed and important decisions were taken. 40 members participated.

CDH Activity-No.4

We conducted a dental check up camp and distribution of dental health kits at Sri Sri Ravisankar Bala mandir Mankavu on 14-2-19. Around 80 kids were examined. Dr. Shimna, Dr. Vani and Dr. Fairooza were attended

Sports Activity- No.1 Dr Moidheen Sha Chamba memorial football

In association with GDC Alumni Association conducted Dr Moidheen Sha Chamba memorial football tournament at grand soccer football turf on 02.03.19. The event was inaugurated by Dr Susha C N (Pesi. IDA Malabar) & Dr Binu Purushothaman (Presi. GDC Alumni Asso.). Six teams were participated and IDA Malabar became the champions of the tournament.

CDH Activity- No.6

We conducted dental check up camp, awareness class and distribution of dental health kits at Govt. L.P.S, Mundakkal. 60 students were participated. Dr Liji, dr Athira, Dr Amrutha, Dr Nithin who conducted the camp successfully.

Pathanamthitta Branch

'RESOLUTIONS' - New year Celebrations and Family meet held at De Charles Reminiscence, Aranmula on January 13th.

Installation ceremony was held at Hotel Hills Park, Pathanamthitta on 27th January. Dr. Abilash GS President IDA Kerala state was the Chief Guest and Dr Anil Thunoli, state Vice President was the Guest of Honor. President Dr. Sujith PR Installed Dr. Muraleekrishnan M. as the new President and Dr. Muraleekrishnan installed the new office bearers.

First Executive committee meeting of the branch was held at Hotel Hills Park, Pathanamthitta on 11th February.

Second Executive committee meeting of the branch was held at Hotel Hills Park, Pathanamthitta on 24th February.

EOGM of the branch was held at Hotel Hills Park, Pathanamthitta on 24th February to discuss the implementation of CE Bill and formation of IDA district committee.

Branch paid tribute and homage to the CRPF Jawans martyred in the Pulwama attack.

Dental checkup camp for students and their parents, distributed dental health kit, took class on importance of oral health and how to maintain good oral health at Govt LP School Krimpinpuzha on March 1st. Dr Parvathy G and Dr. Muraleekrishnan M. led the camp.

One Day workshop 'Go Beyond' for lady clinical staff was conducted at Hotel Mannil Regency on March 3rd. Mr. Madhumohan, JCI National Trainer was the faculty. 67 clinical staff were attended the Programme.

IDA Pathanamthitta District Committee members Dr. Johny Kutty Jacob, Dr Praveen and Dr. Muraleekrishnan M. attended the District Committee members meeting held at Thiruvananthapuram on March 6th to discuss about CE Bill.

Dr. Ralu Varghese and Dr Dhanya Krishnan of this branch Received Dental Excellence award 2019 of IDA Kerala state during the Dentist Day celebration held at Thiruvananthapuram on March 6th.

Dental checkup camp for students and their parents, distributed dental health kit, took class on importance of oral health and how to maintain good oral health at Holy Family Public School Chittar on March 8th. Dr Praveen Dr Sujith PR and Dr. Anitha led the camp.

Dentist Day and International Womens Day were celebrated on March 8th by honoring senior Lady Dentist with more than 30 years of experience in dentistry. Dr. Geetha Devi MR (Pathanamthitta), Dr. Elizbeth Somson(Ranni), Dr Elizabeth John(Maramon) and Dr Susan (Adoor) were honored. The meeting was held at Hotel Mannil Regency, Pathanamthitta and Dr. Jinu Mathew Vaidyan, IDA state Vice President was the Chief Guest.

Tripunithura Branch

1. INSTALLATION CEREMONY

Installation ceremony of new office bearers of 2019, was organised on 12/1/19 at hotel Classic fort, Gandhi square, Poonithura. The event was presided by Chief guest Dr. Suresh Kumar G, honourable Secretary, IDA Kerala State and Guest of Honour, Dr. Jinu Mathew Vaidhyan, 1st Vice President, IDA Kerala State. Dr. Krishna Kumar G was inducted as new President and Dr. Noushad as honourable secretary along with 22 office bearers.

2. CDH ACTIVITIES;

1. 24 JAN; Dental Camp at Unimoni centre, Kothamangalam, for their staff and customers. Total 20 people were screened, Dr. Mathews baby led the camp

2. 27JAN; Conducted dental treatment camp for public in association with Mar Baselious dental college, at Arakulam panchayath hall, Moolamattam, Thodupuzha,

3. 29JAN; MEDICINE BANK, was started by collecting samples from our members and other organizations for distribution at future dental camps.

4. 14FEB; ROADS OF SMILES, KOCHI 2 KASHMIR,

Dental and oral cancer awareness, road trip by IDA Tripunithura members, was flagged off by CI of Police, Mr. Ananthlal, EKM, covering 14 states,10000+ kms.

5. 14FEB;TV LIVE TALK, On oral health by, Dr. Biju Nedumpuram

6. 20 FEB; Dental check up and awareness camp for govt primary school children, Vennala Ekm.

7. 24FEB; Dental awareness and treatment camp for tribal community at Marayoor in association with excise office, Devikulam.

8. 24FEB; Dental awarness and treatment camp at Tripunithura in association with Kanivu palliative care.

9. 6FEB; DENTIST DAY CELEBRATIONS;SELFIE WITH PATIENT, a contest for members of IDA Tripunithura branch,1st 2nd and 3rd prizes were given.

10. 10FEB;As a part of dentist day celebrations senior members were honoured with ponnada at their residence. Dr. Thomas N.V. and Valiyakulangara were honoured

CDE ACTIVITIES:

IDA Tripunithura, conducted 1st CDE, on, "ART AND SCIENCE OF CROWN AND BRIDGE". On, FEB 17th, the faculties were; Dr. Indhu Raj, MDS, Dr. Rajesh C, MDS, Dr. Sandhya Raghavan, MDS, DEPT OF PROSTHODONTICS, GDC, KOTTAYAM. It was a full day programme which included, lectures, live demo and impression techiniques..

WDC ACTIVITIES.

1. Jan 24... Dental awareness and check up camp was conducted by wdc tripunithura at saraswathy vilasam primary school as a part of NATIONAL GIRL CHILD DAY.

2. 8th March.

WDC Tripunithura celebrated INTERNATIONAL WOMENS DAY, by organising an educative talk on.. CYBER CRIME AND CYBER LAWS, AT, Bharath matha college, By Mr. Shine Kumar kc, senior civil police officer, police computer cell, and advocate Mrs. Sreekala, standing counsel of muncipality, High court.

Kunnamkulam Branch

Installation was held on 20th January 2019 at K.R. Residency, Kunnamkulam. Chief Guest was Dr Joseph C.C, Guest Of Honor was Dr K.P Sudheera. A total of 130 members with family gathered for the event. Xmas and newyear celebrations were held on the same day with cultural activites from members, kids of members and ladies club.

C.D.H

1) On Feb 3rd 1st C.D.H was conducted in Thaqwa Orphanage, Andathodu- A total of 100 inmates of the orphanage were gives awareness classes and dental chechup was done. Dental kits were provided.

2) 2nd C.D.H was conducted on Feb 6th at Kadavanadu Fisheries School, Ponnani. A total of 350 students were given awareness classes on dental hygiene and dental chech-up was done. Dental kits were provided.

3) 3rd C.D.H was conducted on Feb 7th at C.M.S School at Kunnamkulam. A total of 100 students were given awareness classes and dental checkup was given along with distribution of health care kits.

4) 4th C.D.H was conducted on Feb 12th at M.J.D School, Kunnamkulam. Dental check was done on students and dental kits were provided. Awareness classes were given to all students and Staff separately.

5) 5th C.D.E was conducted on15th February at Govt. Higher Secondary School, Mannathala. Around 150 Students were given awareness classes a. Free dental checkup and dental kits were provided.

6) 6th C.D.H was conducted on 19th February at RPEES Junior School, Edakazhiyoor. Dental checkup was done on 350 students. Awareness classes and dental kits were provided to all students.

Attingal Branch

1. Instalation Ceremony of New Office Bearers 2019:

The installation ceremony of Dr AFZAL A as the PRESIDENT; Dr DEEPAK S DAS as the SECRETARY and Dr BIJU A NAIR as the Treasurer and the Team of Office bearers for the year 2019 was held on 30th Dec 2019 at ANAMTHARA RESORTS, ATTINGAL from 6:00 pm to 10:00pm. Dr ABHILASH G S (PRESIDENT IDA KSB) was the chief guest, Dr P S TAHA Chairman, PMS COLLEGE OF DENTAL SCIENCES was the guest of honor for the function.

2. CDE PROGRAMMES:

The first CDE of IDA ATTINGAL BRANCH was conducted on 10th March 2019 at Karthika Park, Kazhakoottam on the Topic " SIMPLYFING CHALLENGES IN CROWN AND BRIDGES " by the faculty Prof: Dr Dinesh N, From the Dept of Prosthodontics and Implantology, PMS College Of Dental Sciences And Research. 102 members attended the CDE.

3. CDH PROGRAMS:

A) Camp at Panavilla Sree Durga Bhagavathi Temple (21/03/2019)

IDA ATTINGAL BRANCH conducted an oral screening camp on 21st January 2019 at panavila sree durga bhagavathy Temple, Attingal, 45 pts were examined, Oral Health kit was distributed, Dr Vasudevan Vinay, Dr Arun S, Dr Jishana attended the camp.

B) Cancer awareness program (4th feb 2019)

IDA ATTINGAL BRANCH CDH Wing combined with WDC observed WORLD CANCER DAY 2019 on 4th feb 2019 At MMHS High School, Nilamel and conducted the following program.

1. A Cancer Awareness Program among students.
2. A Quiz competition on Substance Abuse and prize distribution.
3. A Skit program by the students.

The Program was inaugurated by Dr Abhilash G S (president IDAKAB) CDH Convenere Dr Vasudevan Vinay, WDC Chair person Dr Meera murali, Secretary Dr Shameema, Kdc Member Dr Biju A Nair, Dr Ameena attended the program.

C) INTERNATIONAL WOMENS DAY 2019:(8/03/2019)

IDA ATTINGAL BRANCH women's wing observed international women's day at ANANDATHEERAM (A center for differently abled) CHATHANOOR and conducted the following programs.

1. Honoured 3 vibrant lady gems with momentos for their valuable contributions to the society.
2. Parents teachers awareness program.
3. Adoption of Oral health centre
4. Check up / Treatment camp. And lunch was provided for the inmates.
5. Distribution of medicines

The program was inaugurated by Dr Abhilash G S, Dr Vinay Vsudeven, Dr Biju A Nair, Dr Alex Philiph, Dr Meera Murali, Dr Shameema, Dr Atheena Attended the function.

D) NATIONAL DENTIST DAY:

IDA ATTINGAL BRANCH celebrated NATIONAL DENTIST DAY on 10th March 2019, A Cake cutting function and a gettogether was held for the members. 97 members attended the celebration.

Vatakara Branch

INSTALLATION OF NEW OFFICE BEARERS

Installation of new office bearers of 2019 was held at hotel midtown vatakara on 03/02/2019 at 7 pm. Our state secretary Dr. Suresh Kumar Suresh Kumar G. was the chief guest and installing officer. Dr. Suresh installed Dr. Natrajan K.P as the new president of IDA vatakara. Other office bearers were installed by the new president elect Dr. Joseph C.C was the guest of honour.

Dr. Hussain, Dr. Muahammad, Dr. Ratnakaran, Dr. Saji Paul, felicitated the gathering. Dr. Pramod welcomed the gathering Dr. Abdul Salam M.K hon. Secretary deliverd the vote of thanks followed by entertainment and dinner. It was well attended by members and their family.

DENTIST DAY CELEBRATION

IDA vatakara celebrated dendist day on 6th march at IDA hall Vatakara by honoring 3 senior most dentists in our area who have succeeded their valuable services in dentistry more than 25 years.

Dr. Salil C, president elect briefed about the IDA activities like IDA-HOPE, HOPE-MEDI, IDA-ASSURE during the programme.

INTERNATIONAL WOMAN'S DAY

IDA, WDC vatakara branch celebrated women's day at IDA hall on Sunday 10/3/19.

The programme started at 10:30 by prayer, Presidential adress by Dr. Sreekala, WDC chairperson. An educative talk on Self defense and women safety by Mrs. Mallika, SI (women cell, vadakara). Self defence training session and physical test by Mrs. Savitha and Mrs. Saritha (Masters in self defense). IDA Vatakara branch Presdent Dr. Natarajan honoured the chief guest with mementos. Vote of thanks delivered by IDA, WDC secretary, Dr Hafeeda. Participation of wdc members, nears and relatives including children made the programme a grand success. The session winded up having lunch together.

North Malabar Branch

Installation of office President Dr.Thasneem Fahir and new office bearers was conducted on 13th January at IMA hall Kannur. State President Dr. Abhilash G. was the Chief Guest and State Secretary Dr. Suresh Kumar was our Guest of Honour. State Second VP Dr. Anil Thumoli, KDC Vice President Dr. O.V. Sanal, past national CDE Chairman Dr. Ravindranath etc. graced the occasion.

CDE: 30/12/2018 our 20th CDE of 2018, SIMPLIFIED FIXED PROSTHODONTICS by Dr. Santhosh Raveendran.

3/02/2019 Sunday first CDE of 2019 PIEZOELECTRIC SURGERY IN GENERAL DENTAL PRACTICE by Dr. Baiju R.M. at hotel Malabar residency, Kannur.

24/02/2019 conducted ORIENTATION ON IDA AND ITS PROJECTS AND a CDE on CLINICAL ESTABLISHMENT BILL – GAME CHANGER IN DENTISTRY. Dr. Ravindranath, Dr. Anwar M. Ali and Dr. Dinesh K.R. took on IDA and its projects. Dr. Vinod Mathew talked and explained about Clinical Establishment Bill. This was done as an interactive session which was moderated by Dr. Arun Narayanan, Kannur Dental College Principal.

CDH: 26th January a Dental Awareness and Checkup Camp was done in Kuttiyatoor U.P. School along with LIONS CLUB international. Dr. Rameshan T.V. and Dr. Roshini Rameshan conducted the programme.

30th January Dental Awareness and Checkup Camp was conducted at Poomangalam U.P. School, Taliparamba. Dr. Valsalan, Dr. Thasneem, Dr. O.P. Sanal and 8 of our members conducted the programme.

3rd February a camp was conducted with Kannur Legal Cell for tribals of Ulickal Nr Iritty at Vayathoor. We have done it as Oral Cancer Detection Camp. Dr. Valsalan, Dr. Kiran K., Dr. Raj A.C., Dr. Namitha Joyal, Dr. Jyotsna attended the camp.

A candlelight solidarity meet was organized on 17th February to respect the martyrdom of the brave CRPF Jawans at Pulwama, in the Town Square Kannur. The resident branch members including our senior members attended.

Central Kerala Kottayam Branch

1. Installation ceremony was held on 16/12/18 Sunday evening at lions Club of Pala, Nelliyani. Installing officer Dr. Ciju. P. Paulose (past president IDA KSB) installed Dr Raju Sunny as the new president and also the new office bearer's. Dr Abhilash G. S was the guest of honor and Shri. K. M Mani was the Chief guest for the occasion.

Family get together with cultural events by professionals, Gifts for the kids, Christmas Carol were the highlights of the ceremony.

2. Emergency executive meeting was held at River valley club, Pala to discuss the implications of newly enacted CE bill on daily practice of members on Jan 1st.

3. State dental conference Jan 4,5,6 Calicut – Dr Raju Sunny and Dr Nithin Joseph received awards for sports activities 2018.

3. 1st CDE of IDA CKK "The Kerala state clinical establishment act-Game changer in health Industry" by Dr Vinod Mathew was conducted on Jan 13th at IMA Hall, Kottayam.

The 2nd executive committee meeting was held prior to the CDE the same day and same venue.

4. IDA CKK in observance to palliative care day visited St. Josephs home for cancer patients on Jan 16th, Gandhinagar, Kottayam. Provided Gloves, face masks and protein drink for the patients.

5. IDA CKK in observance to National Girl Child Day on Jan 24th, visited CSI Girls Home, Pallom and delivered talk on 'Girl Empowerment'.

6. A Road safety awareness program was organized on Jan 26th Republic day at RTO OFFICE, Kollapally, Pala. CKK President Dr Raju Sunny emphasized the maxillofacial injuries and precautions to be taken to the public and police officials.

7. IDA CKK conducted a CDH CAMP in association with Rotary Club Erumely at Rotary hall, Erumely on Jan 27th.

8. IDA CKK conducted a medical and dental check up camp in association with Pushpagiri Medical and Dental College on Feb 3rd at St. Josephs Church, Kizhathadiyoor, Pala.

9. The 2nd CDE program was held on Feb 17th at Hotel Excalibur, Thellakom, Kottayam. The topic was "Beyond regular endodontics and restorative dentistry " by Dr Joj Kottoor. Branch paid tribute and homage to the martyred CRPF Jawans of the Pulwama attack.

10. The 3rd Executive Meeting was held on Feb 21st at River valley club, Pala.

11. A treatment camp was organised in association with Govt Dental College, Kottayam. VENUE-Providence Home, Ezhumuttom, Thodupuzha, 25th February.

12. An EOGM was convened as per advice from state office to discuss the implementation of CE bill and formation of IDA district committee's on Feb 28th, Kottayam club, Kanjikuzhy.

13. Dentist day celebrations were held on march 6th at IMA hall Kottayam.