



Index Copernicus ID 5385  
ISSN No. 0972-396X

# KDJ

Kerala Dental Journal

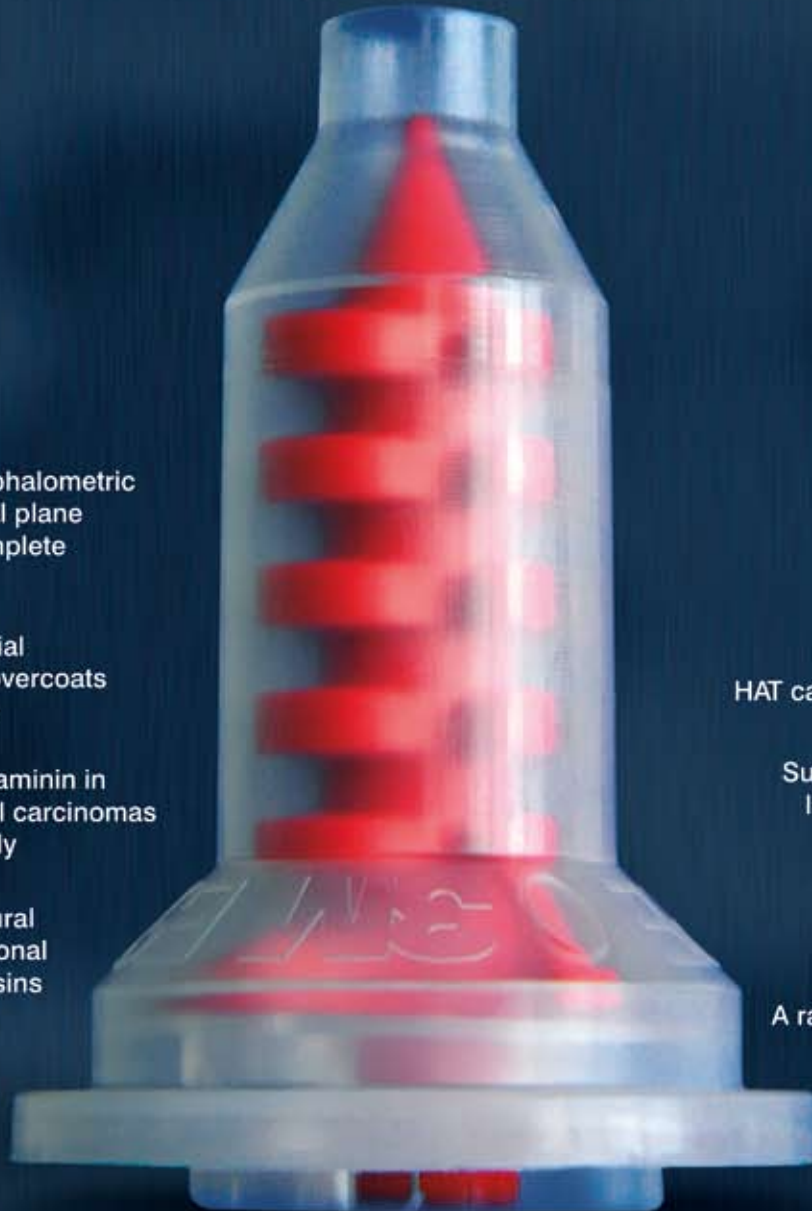Quarterly Publication of Indian Dental Association, Kerala State Branch

Vol 36 | No. 2

April 2013



- Evaluation of a cephalometric method of occlusal plane orientation for complete dentures
- A study on microbial contamination of overcoats of dental students
- Syndecan 1 and Laminin in oral squamous cell carcinomas - A correlative study
- Evaluation of Flexural strength of provisional crown & bridge resins incorporated with silver-zinc zeolite



HAT cast indexing technique ●

Surgical management of large cyst invading the maxillary sinus ●

Central giant cell granuloma of the mandibular condyle: A rare presentation and a diagnostic dilemma ●



**EDITOR**

**Dr. K. Nandakumar**

**ASST. EDITOR**

**Dr. R.M. Baiju**

**BUSINESS MANAGER**

**Dr. Mathew Jose**

**EDITORIAL CONSULTANTS**

**Dr. Santhosh Sreedhar**  
**Dr. K. Chandrasekharan Nair**  
**Dr. K. George Varghese**  
**Dr. Ipe Varghese**  
**Dr. Oommen Aju Jacob**  
**Dr. Thomas Manjooran**  
**Dr. N.O. Varghese**  
**Dr. Sobha Kuriakose**  
**Dr. T. Sreelal**  
**Dr. Siby Xavier**

**EX-OFFICIO MEMBERS**

**Dr. Antony Thomas**  
**Dr. O.V. Sanal**  
**Dr. Raveendranath M.**  
**Dr. Shibu Rajagopal**

**EDITORIAL BOARD**

**Dr. Dibyendu Mazumder**  
**Dr. Ashok Dhoble**  
**Dr. Jayakar Shetty**  
**Dr. Anita Balan**  
**Dr. Joji George**  
**Dr. Mohammed Sameer PT.**  
**Dr. Nidhish Moulana**  
**Dr. Prasad Aravind**  
**Dr. Tijo Alex**  
**Dr. Sandeep N.**  
**Dr. Anil Murali**  
**Dr. Sreela Jayakumar**  
**Dr. Twinkle S. Prasad**  
**Dr. K.S. Ravindran Nair**  
**Dr. Sooraj**  
**Dr. Ajith Kumar**  
**Dr. V.T. Beena**  
**Dr. Bindu J. Nair**  
**Dr. Ashokan C.K.**  
**Dr. Bindu R. Nayar**  
**Dr. Arun Sadasivan**  
**Dr. Anil Mathew**  
**Dr. PA. Murukan**  
**Dr. Pradeep Dethan**  
**Dr. Sheela Sreedharan**  
**Dr. M.S. Suchitra**  
**Dr. V.P. Kannan**  
**Dr. Vinod Krishnan**  
**Dr. Benoy Kurian**  
**Dr. Joseph Issac**  
**Dr. V.G. Sam Joseph**  
**Dr. V.I. Paul**  
**Dr. Gibi Paul**  
**Dr. Manju Renjith**  
**Dr. Jayakrishnan**  
**Dr. Eldo Koshy**  
**Dr. Anil Sukumaran (Saudi Arabia)**  
**Dr. Rajendran (Saudi Arabia)**

**EDITORIAL OFFICE**

Neelambikam, Attukal, Manacaud  
 Trivandrum, Kerala - 695 009  
 Phone: 0471-2459235  
 Mobile: 09447066100  
 e-mail: editorkdj@gmail.com  
 web: www.idakerala.com

**OFFICE BEARERS OF  
IDA KERALA STATE**

**PRESIDENT**

**Dr. Antony Thomas**

**IMM. PAST PRESIDENT**

**Dr. Raveendranath M.**

**PRESIDENT ELECT**

**Dr. Nizaro Siyo**

**VICE PRESIDENTS**

**Dr. Thomas K.N.**  
**Dr. Ranjith C.K.**  
**Dr. Ashok Gopan**

**HON. SECRETARY**

**Dr. O.V. Sanal**

**JOINT SECRETARY**

**Dr. Anilkumar P.K.**

**ASST. SECRETARY**

**Dr. Naveed Sait**

**TREASURER**

**Dr. T.V. Rameshan**

**EDITOR**

**Dr. K. Nandakumar**

**CDE CONVENOR**

**Dr. Anil G.**

**CDH CONVENOR**

**Dr. Civy V. Pulayath**



## The Pentamix unit



The Pentamix unit is an automatic mixing unit used for elastomeric impression materials. It is fast and mixes even the heavy body and putty impression materials. The mixing tip is shown in the cover picture. A powerful motor rotates the mixing element and pushes the mixed material faster on to the tray. As mixing becomes faster, working time to make an accurate impression is enhanced.

*Cover photo credit for issues Vol. 36 No. 1 and 2  
Dr. K. Chandrasekharan Nair and Sudheer Kumar*

**Winner of the Best State  
Branch Journal Award at the  
National Level**

2005-06, 2006-07, 2007-08  
2008-09, 2010-11, 2011-12



## Kerala Dental Journal

Vol. 36 | No. 2 | April 2013

<b>President's message</b>	98
<b>Secretary's report</b>	99
<b>Editorial</b>	100
<b>Evaluation of a cephalometric method of occlusal plane orientation for complete dentures</b> Mini V.S.	101
<b>A study on microbial contamination of overcoats of dental students</b> Sham S Bhat	105
<b>Syndecan 1 and Laminin in oral squamous cell carcinomas</b> Lalita J. Thambiah	111
<b>Evaluation of Flexural strength of provisional crown &amp; bridge resins incorporated with silver-zinc zeolite</b> Mini V.S.	116
<b>Adenoid cystic carcinoma of submandibular salivary gland</b> Priyanka	123
<b>Endodontic management of internal resorption</b> Keerthi Chand	126
<b>Hereditary gingival fibromatosis</b> Sheela Sreedharan	129
<b>HAT cast indexing technique</b> Joy P. T.	133
<b>Surgical management of large cyst invading the maxillary sinus</b> Roshni A.	135
<b>Central giant cell granuloma of the mandibular condyle: A rare presentation and a diagnostic dilemma</b> Mili James	138
<b>Propolis – the natural therapeutic agent in dentistry</b> Sheefa P.A.	142
<b>Prosthetic rehabilitation of the patient with acquired maxillo-mandibular defect</b> C. Dhinesh Kumar	146
<b>Management of an unerupted permanent maxillary incisor</b> Sheela Sreedharan	149
<b>Aneurysmal bone cyst of mandible</b> Admaja K. Nair	151
<b>Association news</b>	154

# President's Message



**Dr Antony Thomas**

Dear Members

Greetings from State office. The projects and programs what was pipelined in the first quarter are moving to the implementation stages. The presidents and secretaries seminar, "Acquire 2013" organized by IDA Kerala State & hosted by IDA North Malabar Branch was awesome and my deep sense of gratitude to the organizers. The Dentists' Day hosted by IDA Coastal Malabar branch was outstanding and my congratulations to one and all who has contributed for the success of the program. The 2nd State Executive Committee meeting held on 3rd March at Calicut was well organized and kudos to my home branch IDA Malabar for all the credits. 1st State level CDE organized by state CDE wing & IDA Pathanamthitta branch deserves special appreciation for their hard work put in for the success, and sincere thanks to KDC for the sponsorship. My special word of thanks to faculty, Dr Mathai Joseph.

IDA Kerala state joining hands with the Dept. of Higher Education and General education Govt. of Kerala are in the process of designing a Dental Assistant Course (DAC). The Curriculum committee meeting of this Additional Skill Acquisition Program (ASAP) was held on 16th April at IMG, Trivandrum. The details will be given elsewhere in the journal. Zonal cricket matches are going as scheduled. Office bearers' booklet, IDA KSED, Health policy draft, blog cum e- journal "Kerala Dental Review (KDR)" are the other projects we have done. Representations were given to Tourism minister and the director for incorporating a web page for IDA to promote dental tourism in Kerala. Additional benefits for HOPE members such as raising fraternity contribution over 10 lacs and starting benevolent scheme to members to meet the financial need during emergency medical conditions are chartered and it will be launched soon.

Unexpected delays in certain areas of our work has been noticed and I urge the responsible office bearers should be reminded of their duty and keep the trust and faith bestowed by ordinary members. We are keeping constant watch in the area of "no more dental colleges", violation of ethics and the case against Corporate. The state office has visited Quilon and evaluated the progress of Quicon. We the state office is working hard to meet your expectations and please do remind us the shortcomings so that we will be able to serve you better in the days to come.

Working with members should aim at developing confidence in members to charge, take responsibility and to take pride in every achievement of the organization. Members should own up the results, whichever way it goes. Only then organizations become truly members managed. I urge each and every member of our association to contribute their mite for the upliftment of our profession by co-operating with the programs and projects organized by state as well as the local branches.

I felt that, the most cumbersome job of organizing part is the difficulty of getting enough attendance for the programs. Members should be aware that lots of time, energy and pain are taken by the organizers to design and implement one program. Please respect and motivate them by your physical presence and good words. The organizers should treat every member as very important part of the winning team.

Congratulations to our Hon Editor Dr. K Nandakumar for releasing the 1st & 2nd issues on time with great quality and content.

Thanking you

**Dr Antony Thomas**  
President, IDA Kerala State.

My dear fellow members,

First of all I thank all the members especially office bearers of 28 branches of IDA Kerala state for their cooperation and support given me for the first three months of my 3 year term. Our activities are moving fast by conducting all the activities within a time bound limit

The IDA year started with the second executive meeting held at Kozhikode on 3rd March. Almost all the members attended. In the well arranged meeting. Thanking Malabar branch for hosting the event.

The state level celebration of IDA Kerala state dentist 's day was celebrated in a befitting manner and I congratulate the exquisite show by IDA coastal malabar branch and it's coordinator Dr. Santhosh Sreedhar. The programme was well covered by all the media's in a grand way.

The first state level CDE programme was conducted on 7th April at Pathanamthitta. The programme was well organised jointly by IDA Kerala state and pathanamthitta branch. Congratulations to Pathanamthitta branch and state CDE chairman Dr.Anil. Our CDH chairman Dr. Civy V. Pulayath working hard for the completion of susmitham and printing of booklet. Discussion about all the policy matters of government regarding several issues connecting IDA like unethical practice, ASAP, dental tourism, waste disposal, image, clinical establishment bill..etc are on the way. Our website is extremely good. Dr. Rajeev Simon is very much keen on it. Please make it a habit to check our site atleast once in two days.

I have already send the details of membership fee hike from 1st April to all the local branch secretaries. So if anybody is having any doubts, they can contact me.

We are packed with programmes in coming months like second state CDE, third state executive meeting, no tobacco day, chilamboli, ..etc. so I appeal all the members be active in all the programmes.

Regards

**Dr. O.V. Sanal**

Hon. Secretary, IDA Kerala State



**Dr. O.V. Sanal**





**Dr. K. Nandakumar**

## Bring in a dental assistant

Staffing and administration of dental clinic has never been a priority area in the dental health care of Kerala. Trained and untrained personnel got employment in the clinic as assistants who in fact are totally unaware of the duties and responsibilities. Dental Council of India has never bothered to design and implement a dental assistant course. The dental technician and dental hygienist do not fit into the slot of the dental assistant. However the Kerala Government has proposed a skill development scheme and luckily included the dental assistant's programme. IDA has given its proposal and this editorial seriously highlights the role of a dental assistant.

Dental assistants are to dentists what nurses are to doctors. They help the dentist in the clinic and act as a secretary in the office. Many assistants can learn their skills through well organised courses and through on-the-job training. Dental assistants must be friendly and must love working with others. Much like nurses, dental assistants take care of patients who are waiting for the doctor to arrive. During this time, the dental assistant might make friendly conversation with the patient to put him at ease in the dental chair and prepare him for treatment.

A dental assistant must listen carefully to the dentist while he is examining and treating the patient. During this time, the dentist will ask his assistant to hand him certain dental instruments and to perform certain tasks. A good assistant will listen carefully and ask questions when needed. Furthermore, good communication skills are needed when an assistant needs to obtain and update a patient's dental records. Dental assistants must also be able to fully explain to patients how to keep up their general oral health.

The dental assistant works as the dentist's right-hand. She must have complete knowledge of the instruments and materials the dentist is using. The dental assistant must also be able to multitask and must demonstrate good manual dexterity, as she will more than likely be using a suction hose to keep the patient's mouth dry while handing over the dentist various instruments. In short dental assistant should have love for assisting, desire to serve others, compassion and empathy, good memory, computer knowledge, language proficiency, intelligence, good chairside manners, honesty, sense of humor and team playing skills. Let us bring in a new era of clinical practice by incorporating a dental assistant to our team.

**Dr. K. Nandakumar**  
Editor, KDJ

# Evaluation of a cephalometric method of occlusal plane orientation for complete dentures

\*Mini V.S., \*\*Alex Mathews Muruppel, \*\*\*Sudeep S., \*\*\*\*Dinesh N.

## Abstract

Cephalometric analysis can be used to predict relationships between the lost teeth and other cranial landmarks that are not subject to post extraction changes, resorption and remodeling. Recent studies of dentate subjects have revealed that there is an intimate correlation between the angle encompassed by the cephalometric points porion, nasion, and the anterior nasal spine (PoNANS angle) and the angulations of the occlusal plane relative to the Frankfort horizontal plane. This correlation is a computed value derived mathematically from the PoNANS angle. This is of immediate clinical value in that it provides a scientific method of occlusal plane orientation for patients who require complete dentures. This study was designed to compare the correlation between the angle formed by the cephalometric points, porion, nasion, and the anterior nasal spine (the PoNANS angle) and the angulation of the occlusal plane relative to the Frankfort Horizontal Plane with calculated value derived mathematically from the PoNANS angle in edentulous state and after denture insertion of ten subjects requiring complete dentures.

KDJ 2013; Vol. 36, no. 2:101-104

## Introduction

In complete denture construction the prosthodontist is responsible for restoring the natural esthetics of the patient and for developing an occlusion that is compatible with functional movements of the mandible. Cephalometrics is of special value to prosthodontics in that it can be used to reestablish the spatial position of lost structures such as

the teeth<sup>1</sup>. This is achieved by identifying predictable relationships between the teeth and other cranial landmarks that are not subject to post extraction changes.

Occlusal plane is defined as, “the common plane established by the incisal and occlusal surfaces of the teeth. It is not a plane in the true sense of the word, but represents the mean of the curvature of the surfaces – GPT -7<sup>2</sup>.

No precise scientific method exists for determining the level of the occlusal plane in edentulous patients. Several principles have been postulated for determining the occlusal plane. Merkeley, Lundquist and Luther (1954) recommend positioning the occlusal plane on line with the buccinator groove<sup>4,5</sup>. Yasaki, Nagle and Sears (1962) suggested orienting the occlusal plane on the same level as the lateral border of the tongue<sup>6,7</sup>. Ismail and Bowman (1968) suggest terminating the occlusal plane posteriorly at the middle or upper third of the retromolar pad<sup>8</sup>. The use of the ala-tragus line to orient the occlusal plane has been controversial. This controversy is primarily due to disagreement on the exact point of reference for this line. Spratley (1980) describes it as running from the center of ala to the center of the tragus<sup>9</sup>. Sharry (1974) recommends the concept without defining or illustrating it<sup>10</sup>. Basker et al (1976) Grant and Johnson (1983), and Neil and Naim (1975) depict the ala-tragus line pictorially as extending to a point at the center of tragus of ear<sup>3</sup>.

Boucher (1974) stated Camper’s line as an imaginary line that runs from the inferior border of the ala of the nose to the superior border

\*PG Student, \*\*Prof. & HOD, \*\*\*Professor, \*\*\*\*Reader, Dept. of Prosthodontics, RM.S. College of Dental Sciences & Research, Vattapara, Trivandrum. **Corresponding Author: Dr Mini V.S.; Email: drminiv@gmail.com**

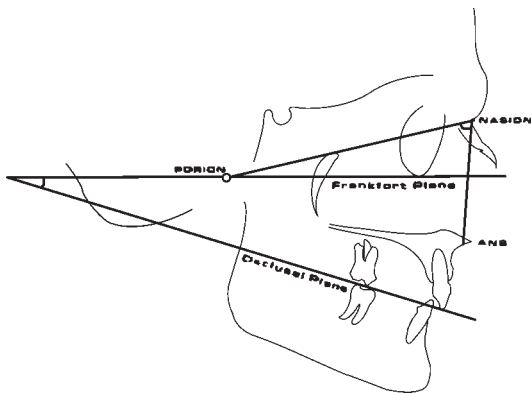


Fig. 1 Cephalometric criteria that form basis of PoNANS angle analysis. Angle between Frankfort and occlusal planes varies inversely but predictably with PoNANS angle formed by joining cephalometric points porion, nasion, and anterior nasal spine.

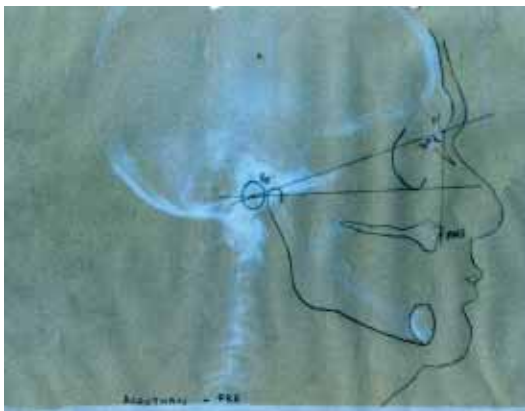


Fig. 2 Pre

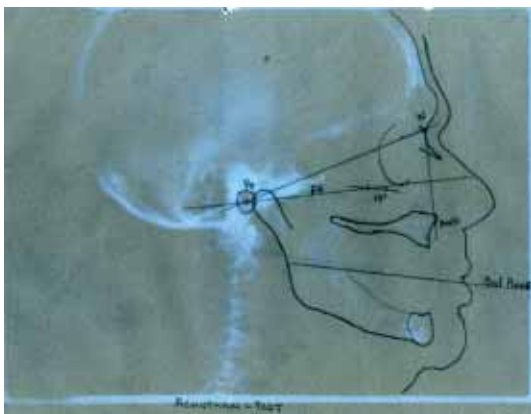


Fig. 3 Post

of the tragus of the ear<sup>11</sup>. Recent studies of dentate subjects have revealed that there is an intimate correlation between the angle encompassed by the cephalometric points porion, nasion, and the anterior nasal spine (PoNANS angle) on the one hand, and the angulation of the occlusal plane relative to the Frankfort plane on the other<sup>1,12</sup>.

This correlation is such that the latter variable (angulation of occlusal plane to FH) would be absent as in an edentulous mouth and its best computed value may be mathematically derived from the PoNANS angle. The immediate clinical value in that it provides a scientific method of occlusal plane orientation for patients who require complete dentures especially since the commonly used ala-tragus line as a method of reference been shown to be not only anomalous but also unreliable<sup>13,14,15</sup>.

## Methodology

This study was carried out in the Department of Prosthodontics Including Crown and Bridge and Implantology, PMS College of Dental Science and Research, Trivandrum. Prior Ethical clearance was obtained from the Institutional Ethics Committee (IEC).

Ten subjects requiring complete dentures were selected. Five of these were men and five were women. Two lateral cephalometric radiograph were taken

1. without denture (Fig.2)
2. with denture, by placing radio opaque marker on incisal edges of maxillary central incisors, mesiopalatal cusp of maxillary first molars. (Fig.3)

Occlusal plane angle prediction by means of PoNANS analysis

Lateral Cephalometric tracing was made for each subject and following points identified to measure PoNANS angle.

1. Porion: plotted to coincide with the center point of the ear-rod shadow of the cephalostate.
2. Nasion: the most anterior point of the suture at the junction of the frontal and nasal bones.
3. Anterior nasal spine (ANS): determined according to Harvold's criterion as "a point on the lower contour of the anterior nasal spine where the vertical thickness is three millimeters.

Points were joined on the lateral cephalogram, resultant PoNANS angle was measured to the nearest 0.25 of a degree by substituting this value for X in the regression formula

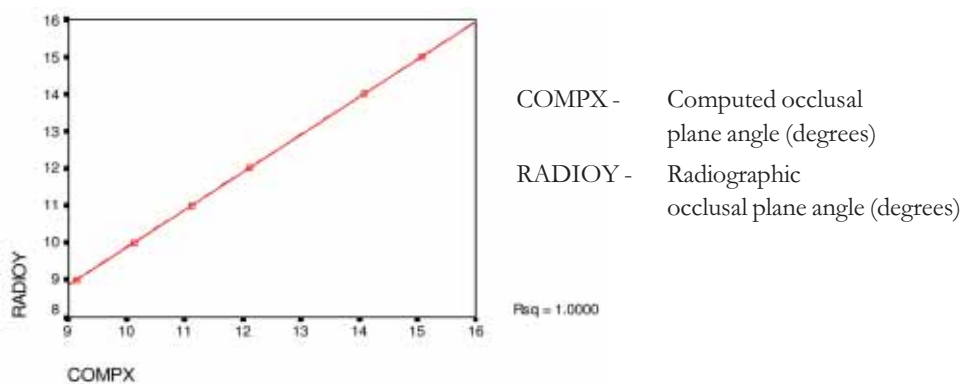
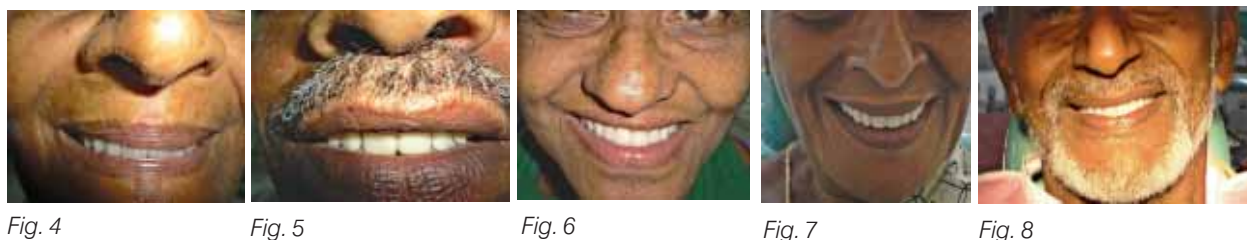
$$Y' = 83.4307 - (0.9907 \cdot X)$$

give the best computed value for the angle of occlusal plane orientation (Y) in each case.

This computed occlusal angle will provide the best esthetic orientation of an individual subject's prosthetic occlusal plane relative to his or her Frankfort plane.<sup>6,17</sup>

Conventional method of denture construction carried out. After tentative vertical dimension is





Graph 1. Scatter diagram showing the relationship between the computed and radiographic values

Table I. Computed, Radiographic occlusal plane angle (degrees) and their differences.

Patient No	Computed occlusal plane angle (degrees)	Radiographic occlusal plane angle (degrees)	Difference (degrees)
1	10.1189	10	- 0.12
2	11.1096	11	- 0.11
3	15.0724	15	- 0.07
4	11.1096	11	- 0.12
5	14.0817	14	- 0.08
6	9.1282	9	- 0.13
7	12.0998	12	- 0.10
8	9.1282	9	- 0.13
9	12.0998	12	- 0.10
10	11.1096	11	- 0.11

established face-bow transfer was done. Articulation done on Hanau Articulator. During arrangement of teeth at the try in the occlusal plane modified anteriorly to fulfill individual esthetic requirements. Posteriorly the middle third retromolar pad was used as reference point for orienting the occlusal surfaces of second molar. After denture insertion lateral cephalograms

were taken with radio opaquer (barium sulphate) on the incisal edges of upper central incisor and mesiopalatal cusp of maxillary first molar for tracing occlusal plane Fig 3). The Computed occlusal plane angle (degrees), Radiographic occlusal plane angle (degrees) and their differences are tabulated below (Table I).

## Esthetic evaluation

Post insertion photographs were made of each subject as Esthetics is a highly subjective concept and cannot be objectively measured; its assessment was limited largely to each patient's individual reaction (Fig 4 – 8).

## Results and discussion

The results are in Table I. With a mean error of less than one degree between the intended angles and those actually obtained. Use of the external ear opening as a posterior reference common to both face-bow and cephalostat was probably a significant factor in the improved result.

Co-relation co-efficient 'r' shows that there is 100% perfect correlation between the computed value and radiological values. The prediction (which  $r^2$ ), in this case it is '1'(100%). It is also showing that from the computed value we could predict the radiological value (100%). From the scattered diagram (Graph.1) all the points lie exactly in the predicted line showing the prediction is 100%.

The difference between the radiographic and predicted occlusal plane angles was such that the final angle obtained was in no case greater than that originally intended.

Notwithstanding the implications for the practicability of the PoNANS angle technique, these results appear to vindicate the role of the earbow as an acceptably accurate means of transferring the horizontal plane of orientation from patient to articulator.

## Esthetic evaluation

The range of occlusal plane angles obtained within the sample range from 9 degree angle of patient No.6 (Fig.6) at one extreme and the 15-degree angle of patient No. 3 (Fig.7) at the other. Comparing these with their respective photographs indicates that such extremes are not inconsistent with individual facial harmony.

The esthetic quality of prosthetic restoration defies objective analysis; and the individual illustrations provided are intended to serve merely as an indication of the PoNANS method's esthetic potential. The occlusal plane is not the sole arbiter of esthetic excellence, but it represents a compositional perspective line about which artistic variation in the arrangement of the six maxillary anterior teeth may take place. In the past esthetics and function were frequently

considered two separate aspect and more often than antagonists. Infact optimization of esthetics often involved functional compromise, as though idealizing the functional aspect usually implied an esthetic sacrifice. Nowadays, in prosthetic rehabilitation the functional aspect must represent the starting point for achieving optimal esthetics.

## Summary

This study has endeavored to make this aspect of predicting the occlusal plane through a scientific, easy and reliable methodology that is identifiable for practitioners.

## References

1. Monteith BD. A cephalometric method to determine the angulation of the occlusal plane in edentulous patients. *J Prosthet Dent* 1985; 54:81-87.
2. Glossary of prosthodontic terms. *J Prosthet Dent* 1994; 71:44-117.
3. Neena D'Souza and Kashyap Bhargava. A cephalometric study comparing the occlusal plane in dentulous and edentulous subjects in relation to maxillomandibular space. *J Prosthet Dent* 1996; 75:177-82.
4. Merkeley HJ. The labial and buccal accessory muscles of mastication. *J Prosthet Dent* 1954; 4:327-34.
5. Lundquist DO, Luther WW. Occlusal plane determination. *J Prosthet Dent* 1970, 23:489-98.
6. Yasaki M. The height of the occlusal rim and the interocclusal distance. *J Prosthet Dent* 1961; 11:26-31.
7. Nagle R, Sears VH. Denture prosthetics. 2nd ed. St Louis: CV Mosby, 1962:134-6.
8. Ismail YH, Bowman JF. Position of the occlusal plane in natural and artificial teeth. *J Prosthet Dent* 1968; 20:407-11.
9. Spratley MH. A simplified technique for determining the occlusal plane in full denture construction. *J Oral Rehabil* 1980, 7:31.
10. Sharry J. Complete denture prosthodontics. 3rd ed. New York: McGraw-Hill, 1974:235.
11. Boucher CO. Current clinical dental terminology. 3rd ed. St. Louis: CV Mosby, 1982:175.
12. Monteith BD. Evaluation of a cephalometric method of occlusal plane orientation for complete dentures. *J Prosthet Dent* 1986; 55:64-69.
13. Monteith BD. A cephalometrically programmed adjustable plane: A new concept in occlusal plane orientation for complete denture patients. *J Prosthet Dent* 1985; 54:388-394.
14. Ismail HY, Bowman JF. Position of the occlusal plane in natural and artificial teeth. *J Prosthet Dent* 1968; 20:407-411.
15. Abrahams, Carey. The use of the ala-tragus line for occlusal plane determination in complete dentures. *J Dent* 1979; 7: 339-341.
16. Karkazis CH. Cephalometrically predicted occlusal plane: Implications in removable prosthodontics. *J Prosthet Dent* 1991; 65:258-264.
17. Karadzic. A study of the occlusal plane orientation in complete denture construction. *J Oral Rehabil* 1987; 14:399-404.

# A study on microbial contamination of overcoats of dental students

\* Sham S Bhat, \*\* Vidya Bhat.S., \*\*\* I. Venkatakrishna Rao, \*\*\*\* Rohan Thomas Mathew

## Abstract

**Objective:** The aim of this study was to identify the amount and type of microbial contamination of Aprons used by the dental students and to see if there is any significant difference exist between the departments. The study also determined how they handled the aprons.

**Method:** Using sterile swabs, samples were collected from the chest area and pocket area which are transferred to a blood agar plate and is incubated overnight. The colony forming units of the most frequently occurring colonies are counted and identified by colony morphology. They findings were confirmed by standard biochemical tests.

**Results:** Of the 56 samples collected 46 samples showed growth of Coagulase negative Staphylococci/CNS (Gram positive Cocci) in the chest area, 53 showed growth of CNS in the pocket area, 53 showed growth of Enterobacter species (Gram negative Bacilli) in the chest area, 56 samples showed the presence of Enterobacter species in the pocket area and 3 samples showed the presence alpha haemolytic streptococci in chest area and the pocket area.

**Conclusion:** There is significant difference in the contamination of the pocket area by Gram positive Cocci species while others are seen to be non-significant (p value = .010). The majority of the pathogens isolated were found to be non pathogenic and can be spread from the wearer rather than the patients. More specific studies has to be undertaken to determine the exact source of the pathogens.

**Key words :** aprons, dental students, infection, microorganisms

KDJ 2013; Vol. 36, no. 2:105-110

during dental treatment are dental instrumentation, saliva, respiratory sources and the operative sites. The oral cavity harbors numerous bacteria and viruses from respiratory tract, dental plaque and oral fluids. Any dental procedure that has a potential to aerosolize the saliva will cause airborne contamination with organisms from some or all of these sources<sup>2</sup>. We use different protective means to reduce our exposure to this contamination. It includes gloves, eye wear, head cap, aprons etc. Among these only the white coat or apron is not disposable and are less frequently changed, hence acting as link in the spread of infection. The hazards of cross contamination are far reaching. In case of an immunosuppressed patient any cross infection can result even in the death of the person.

Working in an environment like the oral cavity would automatically predispose the apron to saliva, aerosol, splatter etc. Infectious aerosols may be generated during dental practice, especially when high speed handpieces or ultrasonic scalers are used without a high volume evacuator<sup>8</sup>. Contamination of skin and clothing by splashes or touch is practically unavoidable in hospitals. The white worn over personal clothing, is a means of protection from such contamination.<sup>3</sup>

## Introduction

White coats or aprons have always been associated with the medical profession. The patients prefer doctors wearing a white coat

to treat them. It brings confidence and trust to the subjects<sup>1</sup>.

In a dental setup there is always a risk of airborne contamination. The sources of such contamination

\* Prof. and Head, Dept. of Pedodontics, \*\* Professor, Dept. of Prosthodontics, Yenepoya Dental College, \*\*\* Senior Lecture, Dept. of Microbiology, Yenepoya Medical College, Deralakatte, Mangalore - 575 018; \*\*\*\* Intern, Yenepoya Dental College, Deralakatte, Mangalore - 575 018. **Corresponding Author: Dr. Sham S Bhat; Email: viceprincipalydc@yenepoya.edu.in**

Table 1: Results

Departments *		Present	Absent	Total
Dept 1	G+ C Chest	7	1.00	8
	G- B Chest	7	1.00	8
	G+ C Pocket	7	1.00	8
	G- B Pocket	8	.00	8
Dept 2	G+ C Chest	7	1.00	8
	G- B Chest	6	2.00	8
	G+ C Pocket	8	.00	8
	G- B Pocket	8	.00	8
Dept 3	G+ C Chest	8	.00	8
	G- B Chest	8	.00	8
	G+ C Pocket	8	.00	8
	G- B Pocket	8	.00	8
Dept 4	G+ C Chest	5	3.00	8
	G- B Chest	8	.00	8
	G+ C Pocket	6	2.00	8
	G- B Pocket	8	.00	8
Dept 5	G+ C Chest	6	2.00	8
	G- B Chest	8	.00	8
	G+ C Pocket	8	.00	8
	G- B Pocket	8	.00	8
Dept 6	G+ C Chest	7	1.00	8
	G- B Chest	8	.00	8
	G+ C Pocket	8	.00	8
	G- B Pocket	8	.00	8
Dept 7	G+ C Chest	6	2.00	8
	G- B Chest	8	.00	8
	G+ C Pocket	8	.00	8
	G- B Pocket	8	.00	8
Total	G+ C Chest	46	10.00	56
	G- B Chest	53	3.00	56
	G+ C Pocket	53	3.00	56
	G- B Pocket	56	.00	56

Dental colleges require faculty, interns and students to wear aprons during their clinical posting hours. But the study mainly aims at the under graduate students in a dental college. In a study conducted by W.Loh et al it was found that the half the students who thought their aprons to be dirty still had them washed only once in a month. They also have the least knowledge about the consequences about nosocomial infections.<sup>3</sup> Most of the students tend to carry the apron with

Table 2 Alpha haemolytic Strep – Chest area

		alpha Chest		Total
		0	1	
Department	Dept 1	8	0	8
		100.0%	.0%	100.0%
	Dept 2	5	3	8
		62.5%	37.5%	100.0%
	Dept 3	8	0	8
		100.0%	.0%	100.0%
	Dept 4	8	0	8
	100.0%	.0%	100.0%	
Dept 5	8	0	8	
	100.0%	.0%	100.0%	
Dept 6	8	0	8	
	100.0%	.0%	100.0%	
Dept 7	8	0	8	
	100.0%	.0%	100.0%	
Total		53	3	56
		94.6%	5.4%	100.0%

fishers exact test p=0.045, sig

Table 3 Alpha haemolytic Strep – Pocket area

		alpha Pocket		Total
		0	1	
Department	Dept 1	8	0	8
		100.0%	.0%	100.0%
	Dept 2	5	3	8
		62.5%	37.5%	100.0%
	Dept 3	8	0	8
		100.0%	.0%	100.0%
	Dept 4	8	0	8
	100.0%	.0%	100.0%	
Dept 5	8	0	8	
	100.0%	.0%	100.0%	
Dept 6	8	0	8	
	100.0%	.0%	100.0%	
Dept 7	8	0	8	
	100.0%	.0%	100.0%	
Total		53	3	56
		94.6%	5.4%	100.0%

fishers exact test p=0.045, sig

\*Dept 1 – Department of conservative and endodontics  
 Dept 2 – Department of Orthodontics  
 Dept 3 – Department of Oral Surgery  
 Dept 4 – Department of Oral Medicine and Radiology  
 Dept 5 – Department of Pedodontics  
 Dept 6 – Department of Periodontics  
 Dept 7 – Department of Prosthodontics  
 (This numbering would be continued throughout the text)

them to non clinical areas in the college like the canteen, library etc. They also are found to wear or carry the aprons outside the college campus to restaurants, shops, movie theatres etc. Public perception that healthcare professionals wearing uniforms to travel to and from work might contribute to the spread of healthcare- associated infections (HCAI) has become the focus of professional and media concern.<sup>4</sup> Hence the study population is determined to be the dental under graduate students and interns. It is the interest of the study to determine the amount and type of microbial contamination of aprons.

Many researches have been done on aprons worn by medical students. Most of the results are also very much consistent in establishing that the aprons worn by medical students contain some amount of

Table 4 *Kruskal- Wallis test results of G positive Cocci from chest area*

Department	N	Minimum	Maximum	Mean	Std. Deviation	Median	Kruskal-Wallis Test X2 value	d.f	p value
G+ C Chest Dept 1	7	1	10	3.00	3.215	2.00	8.108	6	.230 NS
Dept 2	7	2	15	6.86	4.413	6.00			
Dept 3	8	1	19	9.13	7.357	7.00			
Dept 4	5	1	100	21.60	43.844	2.00			
Dept 5	6	4	11	7.00	2.828	7.00			
Dept 6	7	2	11	5.14	3.024	4.00			
Dept 7	6	1	28	8.67	10.093	6.00			
Total	46	1	100	8.26	14.932	4.00			

Table 5 *Kruskal- Wallis test results of Gram negative bacilli from chest area*

Department	N	Minimum	Maximum	Mean	Std. Deviation	Median	Kruskal-Wallis Test X2 value	d.f	p value
G- B Chest Dept 1	7	1	28	7.71	9.160	5.00	10.838	6	.094 NS
Dept 2	6	2	12	6.17	4.262	4.50			
Dept 3	8	2	29	11.88	8.676	12.00			
Dept 4	8	1	30	9.50	9.487	7.50			
Dept 5	8	4	23	14.25	6.756	14.50			
Dept 6	8	1	14	5.25	4.590	5.00			
Dept 7	8	3	25	11.25	6.798	10.50			
Total	53	1	30	9.58	7.627	7.00			

nosocomial bacteria.<sup>5,6</sup> Only a few studies have been undertaken regarding the microbial contamination of aprons of dental students.<sup>2</sup> They have been done in a clinical setup and not in a college. It is in this background this study has been undertaken by the author regarding the microbial contamination of aprons of dental students and to determine if any significant differences are present between different departments.

## Materials and methods

The materials used in the study are sterile swab, sterile saline, blood agar plates and standard reagents and apparatus. The moist sterile swab is used to take samples from predetermined locations of chest area and pocket area of the dominant hand.<sup>2</sup>

A cross sectional study was done on the aprons of eight randomly selected students from the departments of Prosthodontics, Orthodontics, Oral Medicine and Radiology, Pedodontics, Oral Surgery, Conservative and Periodontics. Informed consent was obtained

from the subjects prior to taking the samples. An ethical committee clearance is also taken prior to the study. The sampling took a period of 7 days. The samples were taken from the predetermined areas of their aprons. The only exclusion criterion was that the apron is newly laundered. The sample taken from the aprons are transferred onto a previously prepared sheep blood agar plate within 15 minutes. Hence transport medium of any sort were not used. It has been proved previously that blood agar plates are a valid medium for culturing airborne bacteria<sup>7</sup>. The swabs collected are streaked on to agar plates and incubated overnight at 37 degree Celsius. Bacterial colonies are identified by colony morphology and they are expressed as colony-forming units per plate (CFU/plate). Smears are made from two commonly found colonies and their identities are confirmed by examining under a microscope and by doing standard biochemical tests. A questionnaire was distributed among the subjects to assess their durations of use, frequency of washing and ironing, practice of exchanging them and whether they touch the aprons with gloved hands. The subjects



Table 6 *Kruskal- Wallis test results of Gram positive Cocci from pocket area*

Department	N	Minimum	Maximum	Mean	Std. Deviation	Median	Kruskal-Wallis Test X2 value	d.f	p value
G+ C Pockl Dept 1	7	1	11	3.57	3.359	3.00	16.756	6	.010 sig
Dept 2	8	4	25	12.13	8.659	10.00			
Dept 3	8	3	25	13.75	7.046	13.50			
Dept 4	6	1	10	5.00	4.000	3.50			
Dept 5	8	1	15	6.25	5.523	4.00			
Dept 6	8	4	28	11.63	9.516	8.50			
Dept 7	8	2	35	9.50	10.623	5.50			
Total	53	1	35	9.08	8.009	5.00			

Table 7 *Kruskal- Wallis test results of Gram negative bacilli species from pocket area*

Department	N	Minimum	Maximum	Mean	Std. Deviation	Median	Kruskal-Wallis Test X2 value	d.f	p value
G- B Pocke Dept 1	8	2	36	11.25	11.235	7.50	7.899	6	.246 NS
Dept 2	8	3	15	7.63	3.739	7.00			
Dept 3	8	6	50	20.25	15.239	13.50			
Dept 4	8	1	35	12.50	12.638	9.00			
Dept 5	8	3	30	13.63	10.419	11.50			
Dept 6	8	3	60	19.88	18.201	14.00			
Dept 7	8	5	27	15.00	6.990	13.50			
Total	56	1	60	14.30	12.167	10.00			

were also asked to grade their aprons as clean, moderately clean or dirty. The statistical significance of the obtained values is examined.

## Results

Of the 56 samples collected 46 samples showed growth of Coagulase negative Staphylococci/CNS (Gram positive Cocci) in the chest area, 53 showed growth of CNS in the pocket area, 53 showed growth of Enterobacter species (Gram negative Bacilli) in the chest area, 56 samples showed the presence of Enterobacter species in the pocket area and 3 samples showed the presence alpha haemolytic streptococci in chest area and the pocket area. Table 1, 2 and 3 presents the values according to the departments.

The values are tested using Fishers exact test and are found to be statistically significant.

The obtained data was statistically analyzed using the Kruskal-Wallis test. The results are presented in table no's 4, 5, 6 and 7. A pair wise comparison between is done and tabulated in table 8.

There is significant difference in the contamination of the pocket area by Gram positive Cocci species while others are seen to be non-significant. The median of the obtained values are expressed in figure 1.

Gram positive Cocci (CNS) on chest area was found maximum on the samples obtained from the departments of Oral Surgery and Pedodontics. Gram positive Cocci on pocket area are found higher in department of Oral Surgery followed by the department of Orthodontics. Gram negative Bacilli on chest area are found higher from the samples taken from the department of Pedodontics followed by the department of Oral Surgery. Gram negative Bacilli on pocket area are found the maximum from the department of Periodontics followed by the departments of Prosthodontics and Oral Surgery. There is also the presence of alpha haemolytic streptococci from the samples obtained from the department of Orthodontics. Since there is significant difference between the departments in case of contamination of Gram positive Cocci on the pocket region a pair wise comparison is done. Pair wise

Table 8 Pairwise comparison

**Pairwise Comparisons**

Dependent Variable: G+ C Pocket

(I) Department	(J) Department	Mean Difference (I-J)	Mann-Whitney Test Z value	p value	
Dept 1	Dept 2	-8.554	2.79	.005	HS
	Dept 3	-10.179	2.69	.007	HS
	Dept 4	-1.429	.58	.559	NS
	Dept 5	-2.679	1.60	.110	NS
	Dept 6	-8.054	2.56	.010	sig
	Dept 7	-5.929	1.98	.047	sig
	Dept 2	Dept 3	-1.625	.58	.563
Dept 4		7.125	1.95	.052	NS
Dept 5		5.875	1.75	.079	NS
Dept 6		.500	.05	.958	NS
Dept 7		2.625	.74	.460	NS
Dept 3	Dept 4	8.750	2.27	.023	sig
	Dept 5	7.500	2.11	.035	sig
	Dept 6	2.125	.79	.429	NS
	Dept 7	4.250	1.63	.103	NS
Dept 4	Dept 5	-1.250	.59	.556	NS
	Dept 6	-6.625	1.70	.088	NS
	Dept 7	-4.500	1.04	.298	NS
Dept 5	Dept 6	-5.375	1.64	.100	NS
	Dept 7	-3.250	1.06	.290	NS
Dept 6	Dept 7	2.125	.64	.525	NS

comparison is done on the values from table 4 using the Mann-Whitney test.

It is found that the difference between the department of Conservative and department of Orthodontics is highly significant. So is the difference between the department of Conservative and department of Oral Surgery. The difference between department of conservative and department of Periodontics as well as department of Conservative and department of Prosthodontics is significant. The difference between department of Oral surgery and department of Oral Medicine and Radiology as well as department of Oral Surgery and department of Pedodontics is also found to be significant.

An anonymous survey was conducted among the subjects to know about the use and maintenance of aprons by students. (N= 56).

- 1) What is the duration of use of the apron (hours/day)?  
Less than three hours(4)/Three - Four hours(10)/more than four hours (42)
- 2) Do you wear aprons outside the clinics such as in canteen or library?  
YES(37)/NO(19)
- 3) What is the frequency of washing the apron?  
Every day(0)/Twice a week (20)/Once a week(29)/Once fortnightly(6)/Once a month (1)
- 4) Is it washed with other dress?  
YES (21)/NO (35)
- 5) Any disinfectants are used for washing aprons?  
YES (15)/NO(41)

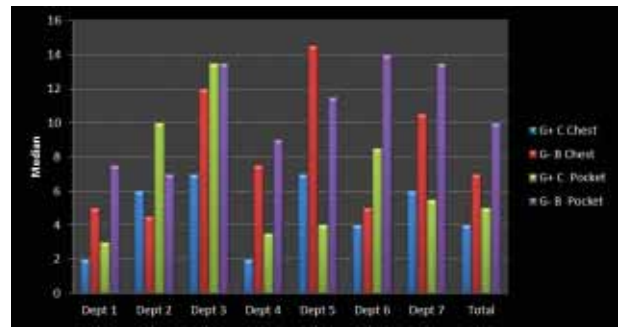


Fig. 1 Median Values

- 6) What is the frequency of ironing the aprons?  
Every day(5)/Twice a week(18)/Once a week(25)/Once fortnightly(5)/Once a month(3)
- 7) Do you have the practice of exchanging aprons?  
YES(8)/NO (48)
- 8) How do you keep your apron after college hours?  
Hang it on hanger (50)/in car (2)/in the bag (3)/in the desk (1)
- 9) Assess the cleanliness of your apron -  
Clean(8)/Moderately clean (44)/Dirty (4)
- 10) Do you touch your apron with gloved hands?  
YES(9)/NO(47)
- 11) What you think should be frequency of washing the aprons?  
Every day(25)/Twice a week(20)/Once a week(10)/Once fortnightly/Once a month(1)

## Discussion

Aprons remain important apparel in the student life. It has been made mandatory to wear an apron in the clinics. The aim of the present study was to conduct a cross sectional examination of aprons from students and interns to observe the level and type of contamination and if there is any significant difference present between the different departments. Previous studies have proved that aprons have a good amount of microbial contamination<sup>2, 3,4,5,6, 9</sup>. Hence the proper maintenance and use of aprons is essential. In the present study it has been found that the aprons were contaminated with Gram positive Cocci, Gram negative Bacilli and a small amount of alpha haemolytic streptococci. The Gram positive Cocci is found to be Coagulase negative Staphylococci (CNS) and the Gram negative Bacilli is found to be Enterobacter species. CNS is a normal skin commensal and the Enterobacter is an environmental bacteria. They are not clinically pathogenic. This finding is in accordance with previous study<sup>9</sup> in which the majority bacteria isolated were skin commensals like CNS and environment bacteria like

the Enterobacter species. Staphylococcus aureus was isolated in another study<sup>5</sup> conducted. This may be attributed to the fact that the study population in the author's study washed their apron more frequently (51.7% washed once every week and 35.7% washed twice a week. Refer Fig 8) while in the above mentioned study 34.4% of students washed their aprons once every month, 15.6% once a week and 9.4% twice a month. Remaining 40.6% washed their aprons once every two months or longer. Also it has been found in another study that ironing the aprons would reduce the microbial count by at least 10 to the power of 74. In the present study it has been found that the majority of the subjects iron their aprons regularly. 8.9% irons the apron every day, 32.1% irons twice a week and 44.6% irons once every week. (Refer Fig 11) This particular study also points out that the majority contaminations of the aprons originate from the wearer rather than the patient<sup>4</sup>. Alpha hemolytic streptococci include normal commensals of the oral cavity and S.mutans, which is a cause for dental caries.

Gram positive Cocci (CNS) on chest area was found maximum on the samples obtained from the departments of Oral Surgery and Pedodontics. Gram positive Cocci on pocket area are found higher in department of Oral Surgery followed by the department of Orthodontics. Gram negative Bacilli on chest area are found higher from the samples taken from the department of Pedodontics followed by the department of Oral Surgery. Gram negative Bacilli on pocket area are found the maximum from the department of Periodontics followed by the departments of Prosthodontics and Oral Surgery. There is also the presence of alpha hemolytic streptococci from the samples obtained from the department of Orthodontics. There is significant difference between the departments in case of contamination of Gram positive Cocci on the pocket region.

As discussed earlier the microbial contamination of the aprons can occur mainly from the wearer of the apron only<sup>4</sup>. Hence the presence of microbial contamination of Gram positive Cocci and Gram negative Bacilli should depend on the use and maintenance of the apron by the individual. Just as any other surface would have some amount of microbial contamination, the aprons also have. To know properly with certainty whether they have originated from the patients or the wearer a detailed study by taking samples from not only the aprons but also the subjects and patients they are treating is necessary. However these contaminations are not pathogenic and would not cause any oral disease per

se. But the alpha hemolytic streptococci being an oral microorganism can arise only from the patient's oral cavity especially in cases of dental caries. In the department or orthodontics where it occurred the students are not taking patients. So this can be due to exchange of aprons from other departments (14.2% of the subjects exchange their aprons). Although these bacteria were isolated and they are known to cause dental caries the question still arises as to whether they can be called as pathogenic. The bacteria have to survive on the fabric and they have to enter the oral cavity to cause dental caries. This is highly unlikely if the operator doesn't touch on the apron with a gloved hand. But as seen from the survey a percentage (16%) of the subjects has accepted that they touch the apron with gloved hands. So it is possible to transmit the bacteria from one patient to another via the operator if he/she doesn't take proper precautions.

## Acknowledgement

Financial Support: This study has received grant from the Indian Council of Medical Research.

Potential conflict of interest: All authors report no conflict of interest related to this article.

## Reference

- 1) Amir Kazory. Physicians, Their Appearance, and the White Coat. The American Journal of Medicine 2008; vol 121(no 9): 825 - 828
- 2) Acharya, Shashidhar, Priya, Harsh, Purohit, Bharathi, AND Bhat, Meghashyam. "Aerosol contamination in a rural university dental clinic in south India." International Journal of Infection Control [Online], Volume 6 Number 1 (31 October 2009)
- 3) Loh, W., Ng, V.V. and Holton, J. (2000). Bacterial Flora on the White Coats of Medical Students. Journal of Hospital Infection 45 (1): 65 - 68.
- 4) J.A. Wilson, H.P Loveday, P.N. Hoffman, R.J. Pratt. Uniform: an evidence review of the microbiological significance uniforms and uniform policy in the prevention and control of healthcare- associated infections. Journal of Hospital Infection (2007) 66, 301- 307
- 5) Muhadi SA, Aznamshah NA, Jahanfar S. A cross sectional study of microbial contamination of medical students' white coat. Malaysian Journal of Microbiology 2007; 3(1): 35-38.
- 6) Srinivasan M, Uma A, Vinodkumaradithyaa A, Gomathi S, Thirumalaikolunsubramanian P. The Medical Overcoat - Is It a Transmitting Agent for Bacterial Pathogens? Jpn J Infect Dis 2007; 60: 121-122
- 7) Johnston JR, Butchart AM, Kgamphe SJ. A comparison of sampling methods for airborne bacteria. Environ Res 1978; 15: 279-284.
- 8) King TB, Muzzin KB, Berry CW, et al. The effectiveness of an aerosol reduction device for ultrasonic scalers. J Periodontol 1997;68:45-9.
- 9) Wong D, Nye K, and Hollis P. Microbial flora on doctors' white coats. BMJ 1991; 303: 1602-1604.

# Syndecan 1 and Laminin in oral squamous cell carcinomas

\* Lalita J. Thambiah, \*\* Satish Kumaran.P

## Abstract

Over ninety per cent of malignancies arising from the oral cavity are epithelial in origin and can be regarded more number of times than not as oral squamous cell carcinomas. A correlative study of immunohistochemical and mRNA expression was made of archival blocks of biopsy specimens of patients histologically diagnosed as having oral squamous cell carcinoma. The sections were stained immunohistochemically by markers for syndecan 1 and laminin. mRNA was studied by RT-PCR. The aim of the study is to compare and correlate the expression in the archival blocks of OSCC histologically diagnosed as, Well and Poorly differentiated OSCC for expression of syndecan 1 and laminin.

**Key words:** OSCC, archival blocks, syndecan 1, laminin, IHC, mRNA

KDJ 2013; Vol. 36, no. 2:111-115

Malignant or premalignant lesions are prone to develop in the mucosal surfaces of the upper aerodigestive tract exposed to topical carcinogens. Their development is a multistep process within the mucosa. Evidence emerging in studies suggests that there might have been alterations in the tumour suppressor genes in the body of the individuals and there is evidence that these altered genes may cooperate with other oncogenes to generate cells that have propensities for aiding tumour progression. Diverse cells are involved in the

origin of neoplasms arising in the upper aerodigestive tract in the oral region such as nasopharyngeal carcinoma, lymphoma, mucosal melanoma, sarcomas and salivary gland tumours. Over ninety per cent of malignancies arising from the oral cavity are epithelial in origin and can therefore be regarded, more number of times than not, as oral squamous cell carcinomas.

The disseminated neoplastic cells cause death in most cases of OSCC. Hence we studied the altered expression of syndecan 1 and Laminin in Well differentiated

OSCC and Poorly differentiated OSCC by immunohistochemical staining for syndecan 1 and laminin the histological diagnosis of cases diagnosed as having WDSCC and PDSCC from our archival blocks immunohistochemically was compared to the expression of syndecan 1 and Laminin,

A immunohistochemical study was conducted of the archival blocks of biopsy specimens of patients diagnosed histologically as having well differentiated squamous cell carcinoma (WDSCC) and poorly differentiated squamous cell carcinoma (PDSCC). These archival blocks were studied for the expression of syndecan-1 and Laminin by immunomarkers and the intensity of their expression was compared with the histological grades assigned to them.

Laminins are major proteins in the basal lamina (one of the layers of the basement membrane), a protein network foundation for most cells and organs. Laminins are a family of glycoproteins that are an integral part of the structural scaffolding in almost every tissue of an organism. They are secreted and incorporated into cell-associated extracellular matrices. Laminin is vital for the maintenance and survival of tissues. Laminins are an important and biologically active part of the basal lamina, influencing

\* Consultant Oral Pathologist, \*\* Consultant Facio-Maxillary Surgeon, Annasawmy Mudaliar General Hospital, Bourdillon Road, off M.M.Road, Bangalore, Karnataka. **Corresponding Author: Dr. Lalita J. Thambiah; Email: ljthambiah@gmail.com**



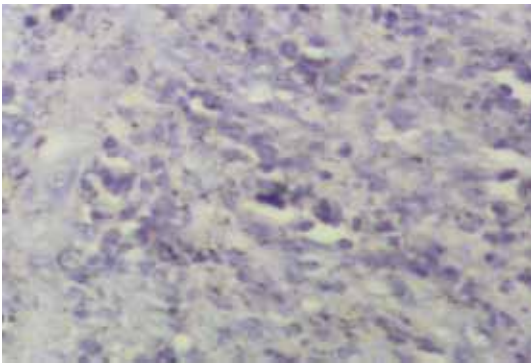


Fig. 1 10x Laminin

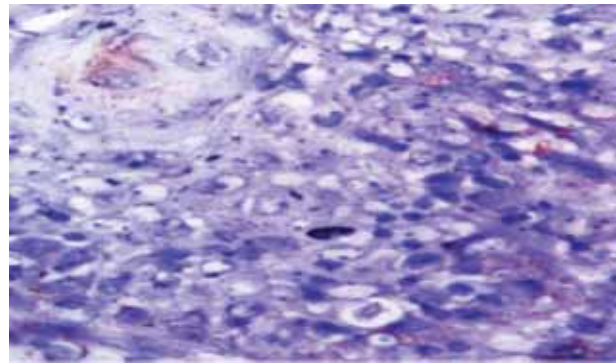


Fig. 2 10x Laminin

cell differentiation, migration, adhesion as well as phenotype and survival.<sup>1</sup> Laminins form independent networks and are associated with type IV collagen networks via entactin, fibronectin,<sup>2</sup> and perlecan. They also bind to cell membranes through integrin receptors and other plasma membrane molecules, such as the dystroglycan glycoprotein complex and Lutheran blood group glycoprotein.<sup>3</sup> Through these interactions, laminins critically contribute to cell attachment and differentiation, cell shape and movement, maintenance of tissue phenotype, and promotion of tissue survival.<sup>4</sup>

Advanced malignant transformation and invasion correlate stringently with the resynthesis of laminin 5 in carcinomas of the head and neck region.<sup>5</sup> Activation of a specific signal transduction pathway in the cell depends on the laminin isoforms the cell binds to, the conformation of the glycoprotein, the duration of exposure to laminin and the expression pattern of the different laminin receptors. All the above factors may be altered when normal tissue becomes neoplastic and various laminin mediated signaling promote tumour dissemination.<sup>6</sup>

Overexpression of laminin- $\alpha$ 2 in tumour tissues appear to be restricted to the intracellular (cytoplasmic) compartment with no evidence of extracellular export. Elevated expression however is restricted to carcinoma cells and it is not a feature of adjacent dysplastic or normal epithelium.<sup>7</sup> There is a correlation between the extent of basement membrane (BM) defects and the invasive and metastatic potential of OSCC. The correlation between the morphological pattern of invasive tumour clusters and laminin-5 immunostaining in the adjacent stroma may suggest first, say H. Kosmehl *et al.*<sup>8</sup> first, that a laminin-5 deposition outside the BM is an immunohistochemical marker for invasion and second, that invasion is guided by the laminin-5 matrix.

The syndecan protein family consists of four members of which syndecans 1 and 3 and syndecans 2 and 4, making up separate subfamilies, arise by gene

duplication and divergent evolution from a single ancestral gene.<sup>9</sup>

Mukunyadzi, M.D. *et al.*<sup>10</sup> analyzed 38 cases of head and neck SCC by immunohistochemical study for syndecan 1 staining within the stroma. It was found that the intensity of syndecan 1 staining within the stroma was generally inversely correlated with the degree of tumour cell differentiation. The stromal expression of syndecan 1 was found to be present in all grades of invasive squamous cell carcinoma, although the intensity of expression was generally higher in the (poorly differentiated) high grade tumours. This finding is in contrast to the pattern of syndecan 1 surface expression in epithelial tumour cells, in which greater intensity of expression is seen in well-differentiated squamous cell carcinoma and is reduced or absent in the poorly differentiated tumours.

The change in location of syndecan 1 from the cell surface to the extracellular compartment has therefore distinct and important pathological consequences.<sup>11</sup>

Several emerging studies point to critical roles for the extracellular protein domains of syndecan in tumour cell behaviour including cell adhesion and invasion. Alterations in syndecan expression, leading to either overexpression or loss of expression, both of which take place in tumour cells, may have significant effects on tumour cell invasion state Deanna Lee M Beauvais and Alan Rapraeger<sup>12</sup>.

Using mixed fibroblasts-carcinoma cell xenografts T. Maeda, J. Desouky and A. Friedl<sup>13</sup> found that fibroblasts expressing syndecan 1 promote tumour growth and tumour angiogenesis. They found significant correlation between stromal syndecan 1 and blood vessel density in human breast carcinoma tissue samples. Their observations support the hypothesis that the aberrant expression of syndecan 1 in carcinoma-associated fibroblasts simulates tumour angiogenesis.



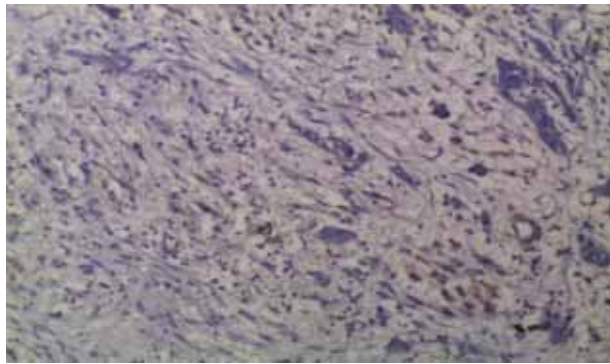


Fig. 3 10x Syndecan 1

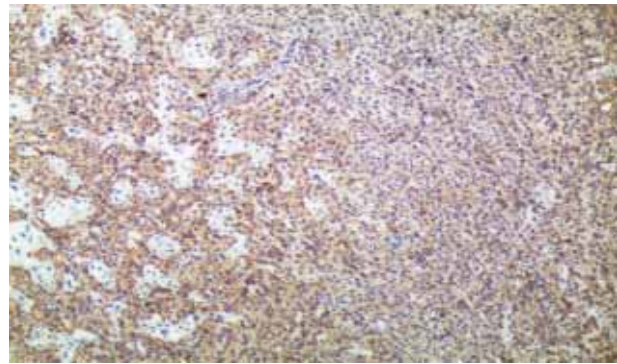


Fig. 4 10x Syndecan 1

Unlike wild-type cells, syndecan-1-deficient cells readily invade type I collagen gels demonstrating that reduction of syndecan 1 expression promotes the invasive phenotype. Ralph D. Sanderson's data indicate that loss of syndecan 1 expression may be necessary prior to the changes in cell shape that precede the invasion and metastasis of tumour cells. However there are several notable studies suggesting a more sinister role for syndecan 1 in some tumours. Initial studies strongly point to the idea that heparan sulphate as a barrier to metastasis.<sup>14</sup>

Brian F. Liebersbach and Ralph D. Sanderson found that cell lines that express syndecan 1 failed to invade gels while their counterparts not expressing syndecan 1 readily invaded the gels.<sup>15</sup>

Anne Woods<sup>16</sup> investigated the roles of syndecans in tumourigenesis. Tumourigenesis is associated with the loss of normal cell morphology, gain of invasiveness, decreased adhesion and abnormal proliferation control. syndecan 1 is reduced when epithelial cells are transformed and several studies now indicate that its decrease may be a prognostic marker in some tumours.

### Materials and methods

10 samples of archival paraffin blocks of histologically diagnosed cases of well and poorly differentiated cases of OSCC were retrieved from the archives of Annaswami Mudaliar General Hospital, Bangalore. 5 micron thick sections were made and stained with haematoxylin and eosin and histological diagnosis and grading done was confirmed. Further 4 micron sections were made on positively charged slides and were subjected to immunohistochemical studies. The primary antibodies to CD138 (Syndecan -1 From Nucleus Technologies) and laminin (from Biogenix) ready to use kit were used to locate syndecan -1 and laminin antigens.

The slides were placed in a De-cloaker (Nucleus Technologies) for heat retrieval of syndecan-antigen (Diva Decloaker solution diluted with distilled water in the ratio of 1:10 was used as the buffer). The slides were brought to room temperature and IHC staining was carried out according to the manufacturer's directions

Pepsin solution was applied for 1Hr for enzymatic retrieval of laminin antigen and the manufacturer's instruction was followed for IHC staining.

The IHC stained slides were counterstained with CAT Haematoxylin and mounted using DPX.

The sections were compared with their H & E stained counterparts. Representative 5 high power fields were taken for evaluation and scoring. (Fig 1-4)

The Scores were rated as follows:

75% staining	4
>50% <75% Staining	3
>25% <50% staining	2
<25% staining	1
No Staining	0

### Results

Table 1 Scores of the Proteins – Well Differentiated Squamous Cell Carcinoma

Sno	Histological Grade	Syndecan-1	Laminin
1	WDSCC	4	0
2	WDSCC	3	0
3	WDSCC	4	0
4	WDSCC	2	1
5	WDSCC	4	0
6	WDSCC	3	1

Table 2 Scores of the proteins – Poorly Differentiated Squamous Cell Carcinoma

Sno	Histological Grade	Syndecan-1	Laminin
1	PDSCC	1	2
2	PDSCC	0	4
3	PDSCC	0	2
4	PDSCC	1	1

A 20 micron thick section was taken in an ependoff tube for mRNA retrieval. The High-Capacity cDNA Archive Kit containing reagents for reverse transcription (RT) of total RNA to single-stranded cDNA, (Applied Biosystems, USA) was used; RNA was isolated using recover all and cDNA synthesized from the total RNA. RNA reverse transcriptase was done according to the manufacturer's protocol.

LightCycler real-time PCR using SYBR Green I fluorescence dye is a rapid and sensitive method to detect low amounts of mRNA molecules and therefore offers important physiological insights on mRNA expression level.

Light Cycler software LCS 480 1.5.0.39 was used to study 10 samples + control on the fluorescence channel 465-510. LightCycler real-time PCR using SYBR Green I fluorescence dye is a rapid and sensitive method to detect low amounts of mRNA molecules and therefore offers important physiological insights on mRNA expression level.  $\beta$ 2 microglobulin was the housekeeping gene and it was the internal control for the gene expression of the proteins of interest. The results are tabulated as shows.

Table 3 Well differentiated squamous cell carcinoma Delta Ct of Sample

	Laminin	Syndecan-1
1	33.22	28.11
2	36.73	30.22
3	34.77	30.12
4	0	35.08
5	34.95	28.99
6	37.55	33.4

Table 4 Poorly differentiated squamous cell carcinoma Delta Ct of Sample

	Laminin	Syndecan-1
1	0	34.85
2	32.52	27.13
3	34.69	29.12
4	36.98	31.58

## Discussion

Syndecan 1 and laminin are expressed right from embryonic life. Their proper expression and localization is essential to maintain the structural integrity of tissues. In our study we examined 10 samples of Oral Squamous Cell Carcinomas from our archives. In the IHC study of the 6 samples diagnosed histologically as WDSCC we found an increased expression of Syndecan 1 and decreased expression of laminin (Table 1). Of the 4 samples histologically diagnosed as PDSCC we found that the expression of Syndecan-1 was less<sup>10, 14</sup> but the expression of laminin was marginally increased (Table 2) as shown by Patel V. *et al.*<sup>7</sup> Syndecan 1 inhibits cell invasion into collagen and that loss of syndecan 1 expression may be necessary prior to the migration of normal or metastatic cells<sup>15</sup>. This increase in expression of laminin and decrease in expression of syndecan 1 can facilitate the cell attachment and migration.<sup>17</sup> The quantification of DNA by real-time PCR relies on plotting fluorescence against the number of cycles to the logarithmic scale.<sup>18</sup> Relative quantification or comparative quantification measures relative change in mRNA expression levels. It determines changes in steady state – mRNA levels of a gene across multiple samples and expresses it relating to the levels of other RNAs.

The molecular aspect of squamous cell migration into the connective tissue was studied and we found that there was increase in expression of Syndecan 1 and decrease in expression of laminin in histologically graded WDSCC and a significant decrease in the expression of Syndecan 1 and a marginal increase in Laminin expression in histologically graded PDSCC. With this correlation of the immunohistochemical staining to the histological grading the expression on level of Syndecan 1 and laminin by IHC can serve as an adjuvant to the diagnosis of oral squamous cell carcinomas.

## Conclusion

mRNA number has been quantified and the data have been correlated with and the IHC expression of the syndecan 1 and laminin proteins and the HMG grading of the neoplastic tissues. It may be concluded that *the histopathological grading of the paraffin embedded blocks of tissues and the level of expression of the proteins syndecan 1 and laminin in the tissues in the 4 point scale correlate* and hence it could very well be held that *immunohistochemical analysis can well be an auxiliary to the diagnosis of oral squamous cell carcinomas.*

## References

1. Timpl, R., H. Rhode, P.G. Robey, S.I. Rennard J M Foidart, and G R Martin "Laminin – a Glycoprotein From Basement Membranes". *J Biological Chemistry* (1979).254 (19): 9933-9937.
2. Hall, T.E., Robert J. Bryson-Richardson, Silke Berger, Arie S. Jacoby, Nicholas J. Cole, Georgina E. Hollway. "The Zebrafish Candyfloss Mutant Implicates Extracellular Matrix Adhesion Failure in Laminin  $\alpha$ 2-Deficient Congenital Muscular Dystrophy". *Proc Natl Acad Sci U S A*. 2007 April 24; 104(17): 7092-7097.
3. Haralson, M.A. and John R. Hassell (1995). *Extracellular Matrix: a Practical Approach*. Ithaca, N.Y: IRL Press. ISBN 0-19-963220-0
4. Colognato, H., Yurchenko P. "Form and Function: the Laminin Family of Heterotrimer". *Dev. Dyn.* (2000). 218 (2): 213-234.
5. Givant-Horwitz, Vered., Ben Davidson, Reuben Reich. "Laminin-induced Signaling in Tumour Cells". *Cancer Letters* 223 (2005) 1-10.
6. Patel, Vyomesh., Kay Alridge, John F. Ensley, Edward Odel, Andrea Boyd, Judith Jones *et al*. Laminin- $\alpha$ 2 "Overexpression in Head-and-Neck Squamous Cell Carcinoma". *Int. J. Cancer*: (2002) 99 583-588.
7. Koshmel H., A. Berndt, S. Strassburger, L. Borsi, P. Rousselle, U. Mandel *et al*. "Distribution of Laminin and Fibronectin Isoforms in Oral Mucosa and Oral Squamous Cell carcinoma". *British Journal of Cancer* (1989) 81 (6), 1071-1079.
8. Carey, D.J. "Syndecans: Multifunctional cell-surface co-receptors". *Biochem. J.* (1997) 327 1-16.
9. Mukunyadzi, M.D., Perkins., Kela Liu, M.D.Ph.D., Ehab Y. Hanna, M.D., James Y. Suen, M.D., Chun-Yang Fan, M.D., Ph.D. "Induced Expression of Syndecan 1 in the Stroma of Head and Neck Squamous Cell Carcinoma". *Modern Pathology* (2003) The United States and Canadian Academy of Pathology Inc. Vol. 16, No.8, 796-801.
10. Chen, Ligong., Ralph D. Sanderson. "Heparanase Regulates Levels of Syndecan 1 in the Nucleus". *PLoS ONE* March 2009 vol. 4 Issue 3 e4947.
11. Beauvais, DeannaLee M., and Alan Rapraeger. "Syndecans in Tumour Cell Adhesion and Signaling". *Reproductive Biology and Endocrinology*. 2004 2:3, 1-12.
12. Maeda, T., J. Desouky and A. Friedl. "Syndecan 1 Expression by Stromal Fibroblasts Promotes Breast Carcinoma Growth *in vivo* and Stimulates Tumor Angiogenesis". *Oncogene* (2006)25, 1408-1412.
13. Sanderson, Ralph D. "Heparan Sulfate Proteoglycans in Invasion and Metastasis". *Cell & Developmental Biology*, (2001) Vol.12, pp.89-98.
14. Liebersbach, Brian F. and Ralph D. Sanderson. "Expression of Syndecan-1 Inhibits Cell Invasion into Type I Collagen". *The Journal of Biological Chemistry*. (1994).Vol.269, No. 31, Issue of August 5, pp. 20013-20019.



INDIAN SOCIETY OF PERIODONTOLOGY

# 38<sup>th</sup> ISP National Conference



Welcome to Kerala "God's own Country"

24th October 2013 - Pre Conference — 25th, 26th & 27th October 2013 - Conference  
Sree Gokulam Convention Center, Kaloor, Kochi, Kerala  
[www.38ispperioconference.com](http://www.38ispperioconference.com)

Organizing Chairman  
**Dr. BRR Varma**

Organizing Secretary  
**Dr. Siby T Chennankara**

### REGISTRATION FEE for ISP Conference 2013

Category	Up to 31st July 2013	Up to 30th Sept 2013	Spot
Life Members	Rs. 7500	Rs. 8500	Rs. 9500
Associate Members	Rs. 6500	Rs. 7500	Rs. 9000
Non ISP Members	Rs. 8500	Rs. 9000	Rs. 10000
Accompanying Person	Rs. 4500	Rs. 5000	Rs. 5500
Foreign Delegates	375 US\$	400 US\$	425 US\$

### PAYMENT DETAILS

Kindly send the payment in the form of Cheque / DD in favour of A/c. "38th ISP Conference Kochi" payable at Kochi.

OR

You can deposit the amount in favour of "38th ISP Conference Kochi, S.B. A/c. No. 321569288 at any branch of Central Bank of India, payable at Central Bank of India, Kastavanthra Branch, Kochi - 26.

OR

You can also do a swift transfer to the above mentioned A/c. from any Bank / Branch using the NEFT Transfer using IFSC Code: CBIIN033119

Hosted by: \_\_\_\_\_



**Society of Periodontists and Implantologists of Kerala (SPIK)**

**CONFERENCE SECRETARIAL**  
Dr Siby T Chennankara, Organizing Secretary, Swiss Dental Care,  
Opp. Kandiya Vidyalya, Kallavanthra, Kochi - 20. Ph. 00037011770 (M), 0484 2204549 (O) Fax: 0484 2205512.  
Email: [dr\\_siby\\_t@rediffmail.com](mailto:dr_siby_t@rediffmail.com) Email: [organizingsecretary@38ispperioconference.com](mailto:organizingsecretary@38ispperioconference.com)



# Evaluation of Flexural strength of provisional crown & bridge resins incorporated with silver-zinc zeolite

\*Mini V.S., \*\*Alex Mathews Muruppel, \*\*\*Sudeep S., \*\*\*\*Dinesh N.

## Abstract

Provisional restorations are an essential part of fixed prosthodontic treatment. Though mechanical strength of provisional crown and fixed partial denture material is of paramount importance as this influence the integrity of a provisional restoration. The addition of antimicrobial agents to prosthetic and restorative materials serves an adjunctive protective function. Among the advantages of this process is the possibility of elution of such agents from these materials, thus preventing or reducing bacterial, fungal and yeast related infection or inflammation. Addition of zeolite to temporization materials will provide beneficial antimicrobial property that is contributory to the gingival and periodontal health, thereby preserving the planned emergence profile. However the effect of such additives on the mechanical and physical properties of Provisional Restorative material has not been investigated.

This study assessed the flexural strength of methacrylate (Trim and DPI) and resin matrix composite (Integrity, Luxatemp Star and Protemp4) based interim fixed partial dentures (FPD) to ascertain whether addition of zeolite influenced the flexural strength of these resins

The study concluded that bisacryl interim restorative material proved to be superior to others in all mechanical properties tested. Zeolite incorporation reduced the flexural strength (FS) & flexural modulus (FM) values considerably. However, FS of zeolite added Protemp 4 and Luxatemp is higher than Trim and DPI.

**Keywords:** Acrylic resin, zeolite, antimicrobial activity, strength

KDJ 2013; Vol. 36, no. 2:116-122

## Introduction

The mechanical strength of a provisional crown and fixed partial denture material is of particular importance as this influence the

integrity of a provisional restoration. Addition of antimicrobial agents to prosthetic and restorative materials serves an adjunctive protective function<sup>1</sup>, by

preventing or reducing bacterial/fungal, yeast related infection or inflammation. Addition of zeolite to temporization materials will provide a beneficial antimicrobial property that is contributory to the gingival and periodontal health, thereby preserving the planned emergence profile.<sup>2,3,4</sup> Zeolites are aluminum silicate crystalline structures that present void spaces measuring 3-10 angstroms in their structure. Antimicrobial cations such as silver and zinc are lodged within the void spaces of the zeolites and be exchanged over time with other cations from their environment. As this ion availability occurs the free cations come into contact with the environmental microorganisms, suppressing their development by inactivating vital microbial enzymes, interrupting RNA replication and blocking their respiration by an oxidative process<sup>5</sup>.

## Aims & Objectives

This study investigated the flexural strength and flexural modulus of methacrylate (Trim and DPI) and bisacrylate (Integrity, Luxatemp Star and Protemp4) based temporization materials and assessed whether addition of 2.5% by vol. zeolite alters the flexural strength of these resins after 72

\*PG Student, \*\*Prof. & HOD, \*\*\*Professor, \*\*\*\*Reader, Dept. of Prosthodontics, RM.S College of Dental Sciences & Research, Vattapara, Trivandrum. **Corresponding Author: Dr Mini V.S.; Email: drminiv@gmail.com**



Fig. 1 Split Stainless Steel mould used to fabricate the bar specimens for flexural strength



Fig. 2 Willytech Thermocycler V 3.0



Fig. 3 Flexural test under progress.

Table I. *Materials*

<i>Product Name</i>	<i>Manufacturer</i>	<i>Lot number</i>	<i>Resin Type</i>
Protemp 4	3M ESPE, Germany	463865	Bis-acryl (paste/paste)
Luxatemp Star	DMG, Hamburg, Germany	665085	Bis-acryl (paste/paste)
Integrity	Dentsply Caulk, Denmark	100804	Bis-acryl (paste/paste)
Trim Plus	Bosworth, Skokie Il), USA	1203-104 (powder) 1104184 (liquid)	Methacrylate (liquid/powder)
DPI	Dental Products of India	2103(powder) 12111(liquid)	Methacrylate (liquid/powder)
Silver-exchanged zeolite	Sigma – Aldrich, St Louis, USA	#09415DUV	nil

hours storage in deionized water followed by thermocycling.

## Methodology

This study was carried out in the Department of Prosthodontics Including Crown and Bridge & Implantology PMS College of Dental Science and Research, Trivandrum, and at Biomedical Technology Wing of Sree Chitra Tirunal Institute for Medical Sciences and Technology, Trivandrum.

A stainless steel mould (Fig 1) was used to prepare 2mm × 2mm × 25mm bar shaped specimens (n = 8 per material) according to EN ISO 4049:2000<sup>6</sup>.

According manufacturer's instruction 40 specimens were made from five materials which were used as the control. Another 40 specimens were made with 2.5% by vol. silver- zinc zeolite added to both methacrylate resin and composite resin, mixed manually for 1.5 min by the same operator to obtain an adequate particle distribution. All the specimens were measured for dimensional accuracy using an Absolute Digimatic Micrometer prior to conducting the tests. The specimens were immersed in deionized

water, coded and placed in an incubator (NSW, Model No.151. India) at 37°C for 72 hours. For thermo cycling (1000 cycles; 5–55°C; 45 s dwell time) Willytech Thermo cycler V3.0, Germany was used (Fig 2).

A universal testing device (Instron 3365 UK) equipped with a 2KN load cell (support bar distance: 20 mm) was used at a crosshead speed of 1 mm/min to record the stress–strain curve to determine the ultimate force prior to fracture (Fig 3). After testing, the fracture surface of each specimen was inspected for voids or material defects which might have affected the mechanical stability. If any of such irregularities were obvious the specimen was discarded, a new specimen produced and tested.

All data obtained from testing flexural strength (FS), and flexural modulus (FM) was subjected to One Way ANOVA Analysis for overall comparison between materials and within groups. The results were found to be highly significant (p<0.000). For multiple comparisons among the materials Post Hoc Comparison was made using Tukey's method. For pair wise comparison within the material between flexural strength (FS) with and without addition of Zeolite Paired 't' test was done



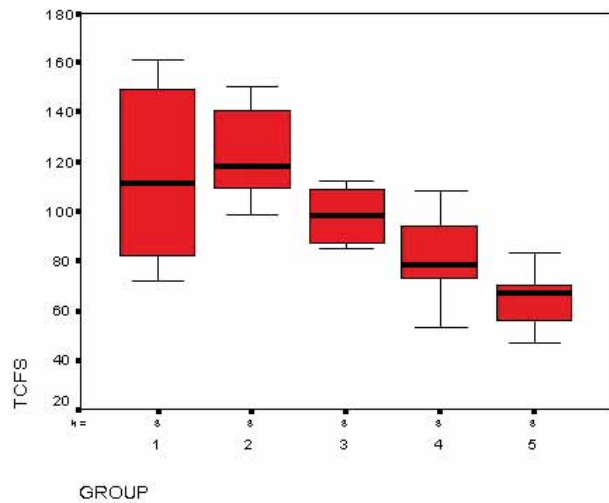
**Results**

Table II Overall comparison of flexural strength after 72 hours thermocycling between and within materials groups

Samples	Mean	Median	SD	One Way Anova		
				F	P	Sig.
Prottemp 4	114.71	111.03	35.53	10.574	0.0001	HS
Luxatemp Star	123.07	118.48	18.64			
Integrity	98.25	98.29	10.84			
Trim	81.64	78.35	17.11			
DPI	64.68	67.31	11.43			

Table III Multiple Comparisons of flexural strength after 72 hours thermocycling of materials between groups

Groups	Post hoc - Tukey's method	
	P	Sig.
Prottemp 4 vs Luxatemp Star	0.927	NS
Prottemp 4 vs Integrity	0.515	NS
Prottemp 4 vs Trim	0.023	S
Prottemp 4 vs DPI	0.001	HS
Luxatemp Star vs Integrity	0.141	NS
Luxatemp Star vs Trim	0.003	HS
Luxatemp Star vs DPI	0.000	HS
Integrity vs Trim	0.506	NS
Integrity vs DPI	0.021	S
Trim vs DPI	0.486	NS



Graph 1 Comparison of flexural strength after 72 hours thermocycling between and within materials

The overall Comparison of flexural strength after 72 hours thermocycling between and within materials groups (Table II) show very high significant difference. However the test results shown in Table 3 and Graph 1 after 72 hours thermocycling shows Luxatemp Star and Prottemp 4 shows statistically significant increase with Trim and DPI (P<0.05). Integrity also shows significant difference with DPI (P<0.05). In the

following order of increasing value, Luxatemp > Prottemp > Integrity > Trim > DPI

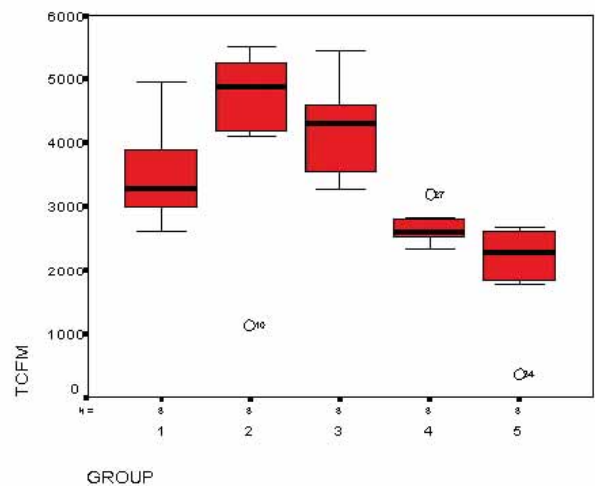
Overall Comparison (Table IV) of flexural modulus after 72 hours thermocycling between and within materials groups (Table 5 and Graph 2) shows significant difference between Prottemp4 and DPI (P<0.05), Luxatemp Star and Trim & DPI (P<0.05) and finally between Integrity and Trim & DPI (P<0.05).

Table IV Overall comparison of flexural modulus after 72 hours thermocycling between and within materials groups

Samples	Mean	Median	SD	One Way Anova		
				F	P	Sig.
Prottemp 4	3487.02	3274.78	803.11	10.393	0.0001	HS
Luxatemp Star	4408.54	4885.55	1413.25			
Integrity	4191.48	4393.26	732.75			
Trim	2666.77	2594.21	259.36			
DPI	2062.65	2273.69	757.53			

Table V Multiple Comparisons of flexural modulus after 72 hours thermocycling of materials between groups

Groups	Post hoc - Tukey's method	
	P	Sig.
Protemp 4 vs Luxatemp Star	0.239	NS
Protemp 4 vs Integrity	0.500	NS
Protemp 4 vs Trim	0.348	NS
Protemp 4 vs DPI	0.020	S
Luxatemp Star vs Integrity	0.987	NS
Luxatemp Star vs Trim	0.003	S
Luxatemp Star vs DPI	0.0001	HS
Integrity vs Trim	0.011	S
Integrity vs DPI	0.0001	HS
Trim vs DPI	0.643	NS



Graph 2. Comparison of flexural modulus after 72 hours thermocycling between and within materials

The flexural modulus corresponded to the following order of increasing value, Luxatemp > Integrity > Protemp > Trim > DPI

Overall comparison (Table VI) of flexural strength with zeolite after 72 hours thermocycling between and

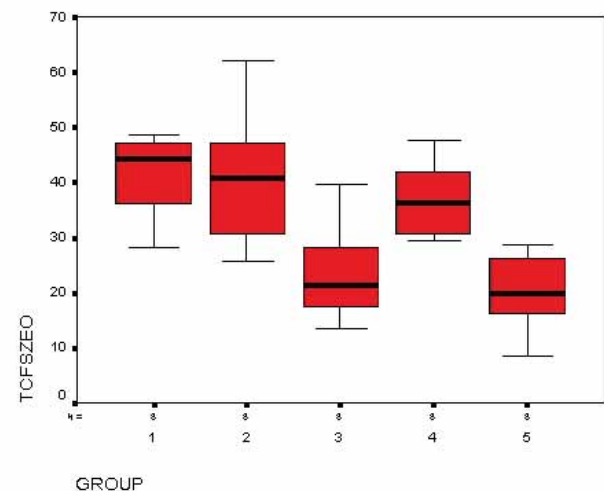
within materials groups shows significant difference (P<0.05). Multiple Comparisons (Table VII) of flexural strength with zeolite among materials (graph 3) shows significant difference (P<0.05) between Protemp4 and integrity & DPI, Luxatemp and integrity & DPI,

Table VI Overall comparison of flexural strength with zeolite after 72 hours thermocycling between and within materials groups

Samples	Mean	Median	SD	One Way Anova		
				F	P	Sig.
Protemp 4	41.45	44.28	7.93	10.539	0.0001	HS
Luxatemp Star	40.54	40.54	12.08			
Integrity	23.39	21.30	8.51			
Trim	36.89	36.21	6.68			
DPI	20.29	19.93	7.05			

Table VII Multiple Comparisons of flexural strength with zeolite after 72 hours thermocycling of materials between groups

Groups	Post hoc - Tukey's method	
	P	Sig.
Protemp 4 vs Luxatemp Star	1.000	NS
Protemp 4 vs Integrity	0.002	HS
Protemp 4 vs Trim	0.830	NS
Protemp 4 vs DPI	0.0001	HS
Luxatemp Star vs Integrity	0.003	HS
Luxatemp Star vs Trim	0.915	NS
Luxatemp Star vs DPI	0.0001	HS
Integrity vs Trim	0.028	S
Integrity vs DPI	0.952	NS
Trim vs DPI	0.004	HS



Graph III. Comparison of flexural strength with zeolite after 72 hours thermocycling between and within materials

Integrity and Trim and Trim and DPI. The flexural strength corresponded to the following order of increasing order, Prottemp > Luxatemp > Trim > Integrity > DPI.

Multiple comparisons (Table IX) of flexural modulus with zeolite shows highly significant (graph4) difference between Luxatemp and other four materials

tested ( $P < 0.05$ ). Prottemp, integrity, Trim and DPI have no statistically significant differences among themselves.

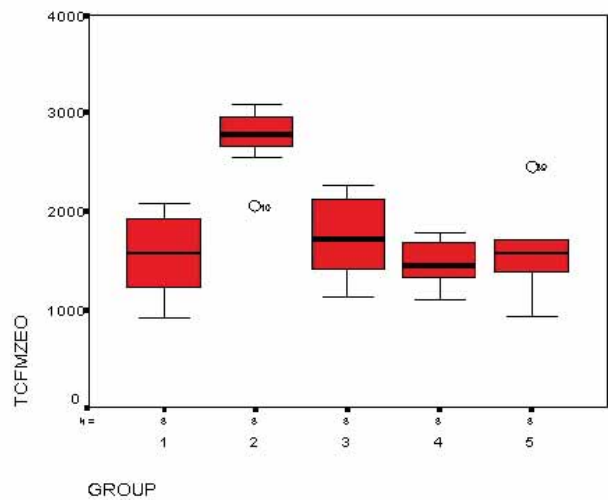
Pair wise comparison of different materials (Table X) with and without Zeolite reveal except the flexural modulus of DPI, all other materials shows significant differences ( $P < 0.05$ ) with and without zeolite in flexural strength and modulus.

Table VIII Overall comparison of flexural modulus with zeolite after 72 hours thermocycling between and within materials groups

Samples	Mean	Median	SD	One Way Anova		
				F	P	Sig.
Prottemp 4	1560.05	1584.85	413.61	15.873	0.0001	HS
Luxatemp Star	2739.14	2782.74	326.82			
Integrity	1733.52	1716.64	410.41			
Trim	1473.73	1446.10	233.07			
DPI	1594.92	1588.83	431.65			

Table IX Multiple Comparisons of flexural modulus with zeolite after 72 hours thermocycling of materials between groups

Groups	Post hoc - Tukey's method	
	P	Sig.
Prottemp 4 vs Luxatemp Star	0.0001	HS
Prottemp 4 vs Integrity	0.881	NS
Prottemp 4 vs Trim	0.990	NS
Prottemp 4 vs DPI	1.000	NS
Luxatemp Star vs Integrity	0.0001	HS
Luxatemp Star vs Trim	0.0001	HS
Luxatemp Star vs DPI	0.0001	HS
Integrity vs Trim	0.631	NS
Integrity vs DPI	0.943	NS
Trim vs DPI	0.965	NS



Graph IV. Comparison of flexural modulus with zeolite after 72 hours thermocycling between and within materials

### Discussion

The addition of silver and zinc zeolite to heat polymerized acrylic resins is consistent with the current trend of incorporating antimicrobials into dental materials.

It is important to evaluate the mechanical properties of FPD resins containing zeolites because provisional crown and bridge restorative materials are subjected to repeated flexural forces.<sup>2, 3</sup>

Fractures are related to the flexural strength of the resins, and this property is challenged every time the provisional FPD undergoes cyclic functional deformation. This study ascertained that addition of zeolite results in a significant decrease in the flexural strength and modulus of these resins, which could significantly/drastically increase the possibility of material fracture occurring during masticatory function.<sup>7, 8, 9</sup>

Table X Pair wise comparison of different materials with and without Zeolite

Materials	Properties	Paired 't' test		
		t	p	Sig
Protemp 4	TCFS – TCFS ZEO	5.317	0.001	HS
	TCFM – TCFM ZEO	5.486	0.001	HS
Luxatemp Star	TCFS – TCFS ZEO	8.788	0.0001	HS
	TCFM – TCFM ZEO	4.191	0.004	HS
Integrity	TCFS – TCFS ZEO	11.58	0.0001	HS
	TCFM – TCFM ZEO	9.80	0.0001	HS
Trim	TCFS – TCFS ZEO	6.81	0.0001	HS
	TCFM – TCFM ZEO	8.443	0.0001	HS
DPI	TCFS – TCFS ZEO	11.878	0.0001	HS
	TCFM – TCFM ZEO	1.457	0.188	NS

Among the specimens fabricated as control with no addition of zeolite, bis acrylic resins, Luxatemp star, Protemp4 controls showed the highest flexural strength and modulus values while methacrylate resins, Trim and DPI showed the lowest values with statistical significance. These differences in flexural strength can be partly attributed to differences in chemical composition.

Traditional methyl methacrylate-type resins are monofunctional. They are low-molecular-weight, linear molecules that exhibit decreased strength and rigidity. In comparison bis-acryl resin composite materials are difunctional and capable of cross-linking with another monomer chain. This cross linkage imparts strength and toughness to the material.<sup>10</sup> PMMA materials showed water absorption up to 32 µg/mm, primarily because of polar properties of resin molecules, the absorbed water may then act as a plasticizer and thus reduce the fracture strength of material.<sup>11</sup>

Flexural modulus (FM) is the ratio of stress to strain in Flexural deformation or the tendency for a material to bend. It is determined from the slope of stress strain curve produced by a flexural test and uses units of force per unit area.

After testing the composite materials exhibit significantly higher FM compared to methacrylate.<sup>8</sup> Although no data are available to compare the type of resin matrix or filler content of bis-acryl materials, it is evident that the difference in flexural strength / modulus performance was material-specific.<sup>7, 12, 13</sup> However direct comparison to other studies is not

possible due to the differences in materials tested, methodology of study, and specimen configuration used in comparative study.

A significant decrease of flexural strength in comparison to the control groups was observed with the addition of 2.5% of zeolite to Luxatemp, Protemp, Integrity, Trim and DPI. The decrease of flexural strength values is in agreement with the results of Addy and Handley<sup>14</sup> who reported that the addition of a similar agent to methacrylates used as denture base material negatively affected their mechanical properties. The conversion degree of these materials relating to the amount of residual monomer may also have influenced the values obtained.<sup>15, 16</sup> Nonetheless the addition of small percentages of zeolite to polymethyl methacrylate may be effective against microorganisms and therefore its impact on mechanical properties may be less significant than the potential benefits, especially for patients who are not able to follow an adequate oral hygiene protocol.<sup>17</sup> The major advantages of this addition could be for elderly people with restricted manual dexterity or cognitive disturbances.

The limitation of the study is that though uniform protocol was followed, the homogeneity of mix, internal porosity and the release of stress during finishing procedures could not be controlled. Moreover forces acting in oral cavity in function vary in directions and magnitude. Further studies to investigate marginal adaptation, color stability, span length, food and simulating fluids on mechanical properties is in the asking.



## Conclusion

Bisacryl interim material proved to be superior to methacrylate based on all mechanical properties tested. Bisacryl resin had higher Flexural Strength and flexural modulus values compared to methacrylate resin. Zeolite incorporation reduced the FS & FM values considerably. FS of Protemp4 and Luxatemp after zeolite addition was higher than Trim and DPI.

These higher values should be considered when fabricating interim fixed prosthesis especially when planning long term or short term, single crown or long span FPDs where more stress concentration on particular abutments is important.

## References

1. L A Casemir, C H G Martins, F C Panzeri, P Souza and H Panzeri. Antimicrobial and mechanical properties of acrylic resins with incorporated silver-zinc zeolite – part I. *Gerodontology* 2008; 10:117-125.
2. Kawahara K, Tsuruda K, Morishita M, Uchida M. Antibacterial effect of silver-zeolite on oral bacteria under anaerobic condition. *Dent Mater* 2000; 16: 452-455.
3. Chow CKW, Matear DW, Lawrence HP. Efficacy of antifungal agents in tissue conditioners in treating candidiasis. *Gerontology* 1999; 16: 110-119.
4. Abe Y, Ishii M, Takeuchi M, Ueshige S, Tanaka S, Akagawa Y. Effect of saliva on an antimicrobial tissue conditioner containing silver-zeolite. *J Oral Rehabil* 2004; 31: 568-573.
5. Nikawa H, Yamamoto T, Hamada T, Rahardjo MB, Murata H, Nakanoda S. Antifungal effect of zeolite-incorporated tissue conditioner against *Candida albicans* growth and/or acid production. *J Oral Rehabil* 1997; 24: 350-357.
6. EN ISO 4049. Dentistry – polymer based filling, restorative and luting materials. 1<sup>st</sup> ed. International Standard; 2000.
7. Ireland MF, Dixon DL, Breeding LC, Ramp MH. Invitro mechanical property comparison of four resins used for fabrication of provisional fixed restoration. *J Prosthet Dent*. 1998; 80:158-162.
8. Balkenhol M, Mautner MC, Ferger P, Wostmann B. Mechanical properties of provisional crown and bridge materials: Chemical-curing versus dual-curing systems. *J Dent Res* 2008; 36:15-20.
9. Haselton DR., Diaz-Arnold AM, Vargas MA. Flexural strength of provisional crown and fixed partial denture resins. *J Prosthet Dent*. 2002; 87:225-8
10. Anusavice KJ. *Phillip's Science of Dental Materials*. 11<sup>th</sup> edition. Elsevier. 2010.
11. Lang R, Rosentritt M, Behr M, Handel G. Fracture resistance of PMMA and resin matrix composite based interim FPD materials. *Int J Prosthodont*. 2003; 16:381-84.
12. Wang RL, Moore BK, Goodacre CJ, Swartz ML, Andres CJ. A Comparison of Resins for Fabricating Provisional Fixed Restorations. *Int J Prosthodont* 1989; 2:173 – 184..
13. Gegauff AG, Wilkerson J. Fracture Toughness Testing of Visible Light and Chemical-Initiated Provisional Restoration Resins. *Int J Prosthodont* 1995; 8:62-68.
14. Addy M, Handley R. The effects of the incorporation of chlorhexidine acetate on some physical properties of polymerized and plasticized acrylics. *J Oral Rehabil* 1981; 8: 155-163.
15. Jerolimov V, Huggett R, Brooks CS, Bates JF. The effect of the variations in the polymer/monomer mixing ratios on residual monomer levels and flexural properties of denture base materials. *Quintessence Int* 1985; 9: 431-434.
16. Arab J, Newton JP, Lloyd CH. The effect of an elevated level of residual monomer on the whitening of a denture base and its physical properties. *J Dent* 1989; 17: 189-194.
17. Pietrokovski J, Azuelos J, Tau S, Mostavoy T. Oral findings in elderly nursing home residents in selected countries: oral hygiene conditions and plaque accumulation on denture surfaces. *J Prosthet Dent* 1995; 73: 136-141.

Host: IDA KERALA STATE  
Organised by IDA Quilon Branch

**QUICON**  
KERALA STATE DENTAL CONFERENCE

**46<sup>TH</sup> KERALA STATE DENTAL CONFERENCE**  
**Date : 17, 18, 19 January 2014**  
**Venue: C.KESAVAN MEMORIAL TOWN HALL, KOLLAM**  
**Web: quicon2014.com, Email: 46KSDC@gmail.com**

**Conference Secretariate:**  
Denta Care, Super Speciality Dental Clinic  
Kadavoor, Jn, Perinad P.O, Kollam, Kerala - 691 601  
Phone: 0474 - 2705044, Mob: 9846498974  
Email: anilmurali37@gmail.com



# Adenoid cystic carcinoma of submandibular salivary gland

\* Priyanka, \* Admaja K Nair, \*\* Twinkle S. Prasad, \*\*\* Valsa Thomas

## Abstract

Adenoid cystic carcinoma is a malignant tumor that affects the major and minor salivary glands, the lacrimal glands, the ceruminous glands & occasionally the excretory glands of the female genital tract. They account for 6 to 10% of all salivary gland tumors and are the most common malignant tumors of the submandibular and minor salivary glands. This article presents a case of adenoid cystic carcinoma involving left submandibular salivary gland highlighting its clinical, radiological and histopathological aspects.

**Key words** - Adenoid cystic carcinoma, Cylindroma, Minor salivary gland neoplasm

KDJ 2013; Vol. 36, no. 2:123-125

## Introduction

Adenoid cystic carcinoma (ACC) is a slow growing but aggressive neoplasm with a remarkable capacity for recurrence. They comprise 15-30% of submandibular gland tumors, 30% of minor salivary gland tumors, and 2 to 15% of parotid gland tumors. It is characterized by proliferation of ductal (luminal) and myoepithelial cells in cribriform, tubular and cystic patterns. This article is aimed at describing the clinical, radiological and histopathological features of ACC of submandibular gland leading to an early diagnosis and management.

## Case report

A 58 years old female patient visited the Department of Oral

Medicine and Radiology, Govt Dental College, Thiruvananthapuram, with the chief complaint of swelling on left side floor of mouth since approximately one month. The history revealed that swelling had started insidiously and had steadily increased in size since its onset. Swelling was associated with dull pain during eating which started approximately one month back and it was not associated with any other symptoms. There was history of full mouth extraction and denture wearing since ten years. Medical, surgical, personal and family history was not relevant. There was no abnormality detected on general physical examination. There were no abnormal findings on extraoral examination. No regional

lymphadenopathy was found. (Fig 1&2)

Intraoral examination revealed a solitary, unilateral, roughly oval in shape swelling involving left side floor of mouth extending from midline to 3cm anterior to left retro molar area of size approximately 4x3x2 cms. The swelling was covered with normal colored mucosa. Surface was smooth with no evidence of ulceration, sinus or fistula. Wharton's duct was seen overlying the swelling. (Fig 3) There was no change in size of swelling while eating, respiration, deglutition and protrusion of tongue. On palpation swelling was firm, non tender, mobile and bimanually palpable. On the basis of clinical history and examination carried out a provisional diagnosis of salivary gland neoplasm on the left side floor of mouth was made with the differential diagnosis given as sialolith, ranula, dermoid cyst, epidermoid cyst and lipoma.

Mandibular true occlusal view showed no relevant findings suggestive of any abnormality. (Fig 4) Ultrasonography revealed heterogeneous lesion of 34x22x20 mm size noted in the left anterior submandibular region extending to the floor of the mouth. (Fig 5) Surface appears nodular. No calcification seen. No cystic areas seen. Findings suggestive of inflammatory/neoplastic mass

\* Post Graduate Student, \*\*Assistant Professor, \*\*\* Professor and Head, Department of Oral Medicine and Radiology, Govt. Dental College, Thiruvananthapuram. **Corresponding Author: Dr Priyanka; Email: priyankavatsya0285@gmail.com**



Fig. 1 Photograph showing no relevant extraoral findings

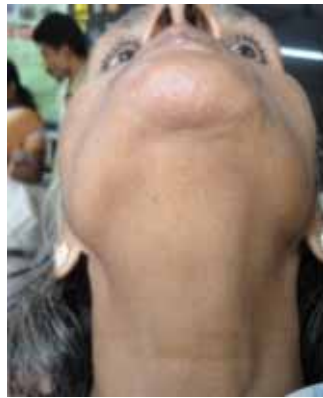

Fig. 2 Photograph showing no extraoral swelling/regional lymphadenopathy

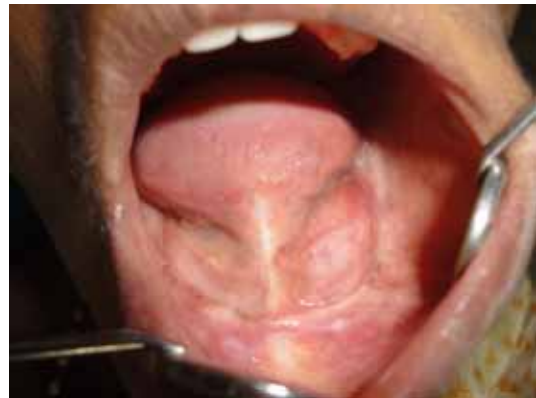

Fig. 3 Photograph showing well defined swelling on left side floor of mouth with Wharton's duct overlying it



Fig. 4 Mandibular occlusal view with no relevant findings

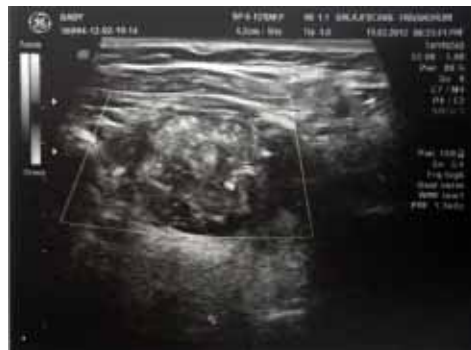

Fig. 5 Ultrasonography showing heterogeneous lesion in the left anterior submandibular region

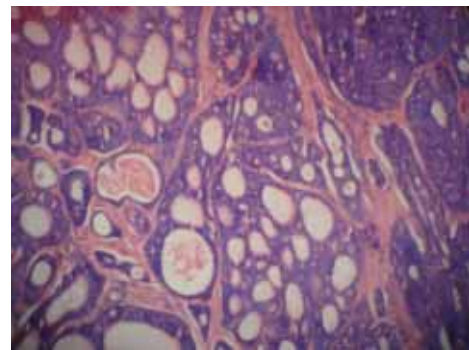


Fig. 6 Histopathology of cribriform Adenoid cystic carcinoma

lesion. FNAC/Biopsy was advised to rule out malignancy. FNAC revealed cellular smear showing malignant squamous epithelial cells with few clusters of basaloid cells.

Incisional biopsy was performed for the histopathological diagnosis and section showed a moderately collagenous connective tissue stroma exhibiting nests of basaloid epithelial cells. Multiple cylindrical pseudo cystic areas most of which contain an eosinophilic secretion are seen amidst the nest of basaloid cells, the overall growth pattern characteristically resembling a cribriform pattern. (Fig.6) In a few these basaloid cells are seen to be arranged as sheets with a few pseudo cystic areas within. Vascularity appears moderate with the presence of formed blood vessels some of which are dilated and engorged. A diffuse, mild chronic inflammatory cell infiltrate is seen in the stromal tissue. The histopathological impression was that of an adenoid cystic carcinoma of cribriform pattern.

The patient underwent surgical excision followed by radiotherapy. No local recurrence of the lesion has been observed 6 months after the treatment.

### Discussion

The term 'adenoid cystic carcinoma' was introduced by Ewing (Foote and Frazell) in 1954. This tumor was named as 'cylindroma' earlier by Billroth in 1859, because the epithelial and connective tissue elements formed a system of intertwining cylinders. The term 'basalioma' was coined by Krompecher in 1908, who considered this type of tumor to be of analogous nature to the basal cell growths of the skin.<sup>1</sup>

Adenoid cystic carcinoma may occur at any age, although in most cases the patients are middle aged or over. Females are affected more frequently than males. It can occur in any salivary gland site, but approximately 50% occur within the minor salivary glands. The remaining tumors are found mainly in the parotid and submandibular glands. It usually appears as a firm

unilobular mass in the gland. Occasionally the tumor is painful, and parotid tumors may cause facial nerve paralysis. This tumor has a propensity for perineural invasion, thus it can extend far beyond the obvious tumor margin.<sup>2, 3</sup>

Histomorphology and grading of the tumor<sup>4</sup> –

**Cribriform variant:** Extensive sheets, uniform bands, or cribriform nests usually composed of relatively small, darkly stained, slightly separated basal/myoepithelial cells and small, at times inconspicuous duct like structures, which may contain secretory products. Round to oval, often fairly uniformly sized intercellular spaces, termed pseudocysts, containing pale grayish blue to pinkish granulofibrillar material at times with a reticular pattern, which develop in relation to the basal/myoepithelial cells.

**Tubular variant:** Presence of bilayered duct like structures generally composed of an inner layer of cuboidal to columnar ductal cells with moderate amounts of eosinophilic cytoplasm and outer, smaller darker staining cells.

**Solid variant:** Arranged as variable, at times fairly uniformly sized groups or as sheets of small, darkly stained tumor cells, those are excess proliferations of the basal/myoepithelial cell component. Small duct like structures must be identifiable among the basaloid cells. Nests or sheets of basaloid cells with the above features from 30% or more of the neoplasm.

Grading of the tumor<sup>4</sup>:

a. **GRADE I:** The tumor consisting only of cribriform and tubular histomorphology.

b. **GRADE II:** A mixture of cribriform, tubular and solid growth patterns, with solid growth pattern less than 30% of the tumor.

c. **GRADE III:** Tumors with predominantly solid features (>30% or more of the tumor)

Treatment of ACC generally requires excision with the widest margins possible because the tumor cells extend well beyond the clinical or radiographic margins and that the tumor undergoes not only perineural invasion but perineural spread. Postoperative radiotherapy of 6000 cGy to 7500 cGy is usually given. Distant metastases occur in 25-50% of patients, even many years after the diagnosis, and lung is the most involved site. 5 years survival rate after effective treatment is 75%, but long term survival rates are low (10 years – 20% and 15 years – 10%).<sup>5</sup>

## Conclusion

ACC is a common malignant salivary gland neoplasm comprising approximately 15 to 30% of submandibular gland tumors. It is famous for its peculiar histopathological features, variants and tendency for perineural invasion. Thorough knowledge about the clinical, radiological & histopathological features enables for early & accurate diagnosis of this tumor leading to good prognosis.

## References

1. R. B. Lucas, Pathology of tumors of the oral tissues, fourth edition, page: 330-35.
2. Neville, Damm, Allen, Bouquot; Oral and Maxillofacial Pathology, second edition, page: 426-8
3. Shafer.Hine.Levy; Shafer's Textbook of Oral Pathology, seventh edition, page: 238 -239
4. Irving Dardick, Color atlas/text of salivary gland tumor pathology, page: 149-57
5. Robert E. Marx, Diane Stern; Oral and Maxillofacial Pathology, A rational for diagnosis and management; page 550-3.

# Endodontic management of internal resorption

\* Keerthi Chand, \* Mohammed Waseem Ahmed, \*\* Jolly Mary Varughese, \*\*\* Sam Joseph V.G., \*\*\*\* Mali G. Nair

## Abstract

Internal resorption is a relatively rare pathologic entity of dentin which starts either in the pulp chamber or in the root canal and progressively destroys the surrounding dental hard tissues. The initiating factor in internal resorption is thought to be trauma or chronic pulpal inflammation, but other etiological factors have also been suggested. It is important to diagnose this condition and intervene as early as possible to improve the prognosis of the involved tooth. Presented herein are two case reports of internal resorption involving maxillary incisors.

**Case report 1-** Clinically discolored tooth 11 with a resorptive defect in the apical and middle third of the root was treated nonsurgically. The root canal space and the resorption lacunae were prepared by chemomechanical methods. After an interim calcium hydroxide dressing, the apex was sealed with mineral trioxide aggregate (MTA) and obturation done using thermoplasticized gutta percha technique.

**Case report 2-** Nonsurgical treatment of a discolored 12 with an open apex and a resorptive defect in the apical third and associated with a periapical lesion. Routine root canal procedures were done, the resorptive defect cleaned with ultrasonic activation, and the apex sealed with MTA and obturation done using thermoplasticized gutta percha technique.

**Keywords:** Internal resorption, Pink spot, MTA, Obtura

KDJ 2013; Vol. 36, no. 2:126-128

## Introduction

Internal resorption is a condition characterized by progressive loss of tooth substance starting from the root canal wall. The process is initiated by transformation of normal pulp tissue into granulomatous tissue with giant cells, which resorb dentin. Although its etiology remains an

enigma, various causes have been proposed ranging from trauma, pulpitis, pulpotomy, cracked tooth, tooth transplantation, restorative procedures, invagination, orthodontic treatment or even as a sequel to Herpes zoster viral infection<sup>1,2</sup>. Usually, resorption is an asymptomatic condition diagnosed in routine radiographs and can

occur in any area of root canal system, the cervical third being the most common site. Radiographically, internal resorption appears as a uniform, round to oval radiolucent enlargement of the root canal. If the resorption occurs in the coronal portion of the tooth, the tooth may demonstrate a pinkish hue due to the presence of hyperplastic vascular pulp tissue filling the resorbed area.<sup>3</sup> Mummery discussed the “pink spots” in teeth with such internal granulomas<sup>4</sup> and hence the name ‘pink tooth of Mummery’.

Two case reports of internal root resorption are presented, involving anterior teeth with history of trauma and managed with a combination of ultrasonics, MTA and thermoplasticized obturation technique.

## Case report - 1

A twenty year old female patient reported to the Department of Conservative Dentistry and Endodontics, Government Dental College, Thiruvananthapuram with a chief complaint of discoloration of the upper front tooth. She gave a history of trauma four years back and gradual discoloration of the tooth. No specific dental treatment was undertaken for the same.

Clinical examination revealed a pink discoloration of 11 (Fig 1). There was no restoration or caries on the tooth. The periodontal

\* Junior Resident, \*\* Principal, \*\*\* Professor and Head, \*\*\*\*Associate Professor, Dept. of Conservative Dentistry & Endodontics, Govt. Dental College, Thiruvananthapuram. **Corresponding Author: Dr. Keerthi Chand; Email: drkeerthichand@gmail.com**



## Case report 1

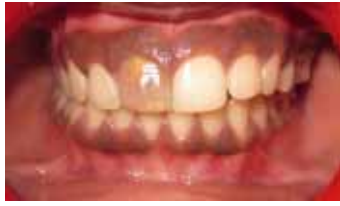

Fig. 1 Pre operative photograph showing discolored 11

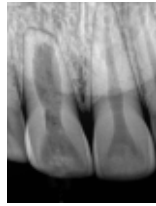


Fig. 2 Preoperative radiograph showing widened root canal space

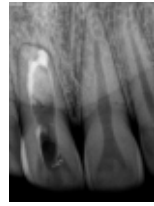


Fig. 3 Apical seal with MTA

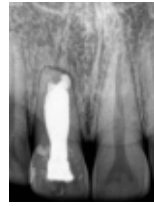


Fig. 4 Post obturation radiograph of 11

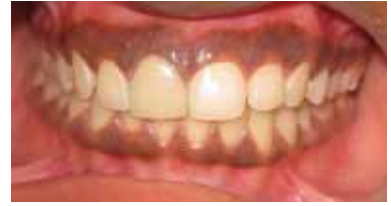

Fig. 5 Post operative photograph

condition of the tooth was excellent, with normal probing depth and absence of gingivitis. The tooth was not sensitive to palpation and percussion and yielded a negative response to electric and thermal pulp testing. There was no associated pain, swelling or pus discharge in relation to the involved tooth. The medical history was non-contributory.

Radiographic examination revealed 11 with a short root having blunt and closed apex (Fig 2). There were no associated periapical changes. An unusual widening of the pulp space in the middle and apical third was noted. Diagnosis of internal resorption of 11 was established.

### Management

After a diagnosis of internal resorption was established, nonsurgical root canal therapy was initiated. Local anaesthesia was administered and access gained into the pulp cavity. The pulp was extirpated and manual instrumentation (K file, Dentsply) along with copious irrigation with 5.2% sodium hypochlorite, ultrasonic (UDS-P, Woodpecker) activation was done. Apical hemorrhage was observed, which persisted in the subsequent visits. Calcium hydroxide was used as an intracanal medicament for six weeks, the dressing being replaced every two weeks. Subsequently, MTA was used to seal the apical third using finger plugger (Fig 3) and moist cotton pellet was placed over it for 24 h. Obturation of the resorption defect (Fig 4) and rest of the canal was done with thermoplasticized gutta percha with Obtura II (C-Fill).

Access cavity was restored with glass ionomer cement (GC Gold Label) and the tooth 11 was esthetically restored with metal free ceramic crown luted with resin cement (Fig 5).

## Case report 2

A seventeen year old male reported to the Department of Conservative Dentistry and

Endodontics, Government Dental College, Thiruvananthapuram with a presenting complaint of pain and swelling in the upper right front tooth since 4 days. He gave a history of trauma three years back. Medical history was non-contributory. No specific dental consultation was done by the patient earlier.

Clinical examination revealed discolored 12 (Fig 6) and swelling in the apical region of the tooth. The tooth was sensitive to palpation and percussion. Radiographic evaluation revealed a ballooning out of the apical root canal space and an associated periapical lesion in relation to 12 (Fig 7). The lesion showed an extension to the periapical region of 11. Thermal and electric pulp vitality tests confirmed 11 to be vital. Hence, treatment for central incisor was deferred and scheduled for follow up. After establishing a diagnosis of internal resorption of 12, nonsurgical root canal treatment was initiated.

### Management

Access opening was done under proper isolation. Purulent discharge from the canal was noted and allowed to drain until the canal was dry. Copious irrigation of the canal was done using normal saline. Calcium hydroxide powder was condensed into the canal with finger pluggers.

In the next appointment, the canal was irrigated with saline to remove previously placed intracanal medicament. 5.2% sodium hypochlorite irrigant was ultrasonically activated for debridement of the resorption defect. Upon instrumentation, a large apical foramen, located towards the mesial aspect was noted which was sealed with MTA. Moist cotton pellet was placed over the condensed MTA for 24h. Thermoplasticized gutta percha technique (Obtura II, C-Fill) was employed to backfill the rest of the canal. A coronal seal was obtained by placing GIC (GC Gold Label) in the access cavity. Periodic recalls were done at 1, 3 (Fig 8) and 6 months (Fig 9). Vitality testing of

## Case report 2

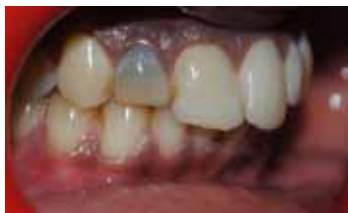

Fig. 6 Pre operative photograph showing discolored 12

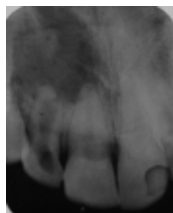


Fig. 7 Pre-operative radiograph showing ballooned out root canal space and periapical lesion

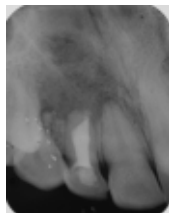

Fig. 8 Follow up radiograph after 3 months. Persisting periapical lesion in relation to 11 noted

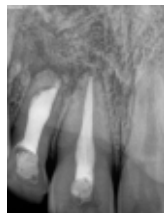

Fig. 9 Follow up radiograph after 6 months showing periapical healing

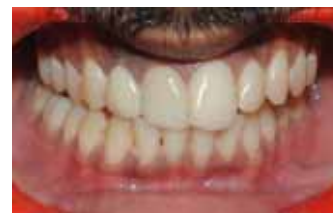

Fig. 10 Post operative photograph

the maxillary anteriors was done during the recall visits. At 3 months review, tooth 11 did not respond to thermal and electric pulp testing. Therefore root canal treatment was instituted for that tooth. Nevertheless, the periapical lesion showed a sign of healing and final restoration was done using porcelain fused to metal crowns on 11 and 12 (Fig 10).

## Discussion

Internal resorption may affect any tooth in either the primary or secondary dentition, but it is more frequently observed in permanent teeth. It occurs most often during the fourth and fifth decade, predominantly in males<sup>5</sup>. Rabinowitch reported more prevalence of internal resorption in anterior teeth<sup>6</sup>.

When internal resorption is detected, root canal therapy should be instituted as early as possible, to limit its progression. Prognosis of internal resorption is fairly good or even excellent in teeth which are not much weakened by the loss of tooth structure or perforation<sup>7</sup>. The success of treatment of teeth with depends primarily on the size of the resorptive defect. Large lesions cause a reduction in the resistance of the tooth to shear forces that may lead to tooth fracture.

Diagnosis of internal resorption in this case was based on the findings of radiographic examination (uniform radiolucence, clearly defined margins and ballooned out root canal walls), clinical examination (pink hue, inability to probe the defect via the periodontal ligament and negative response to vitality test) and history of trauma.

Limited access of endodontic instruments in the resorption defect necessitates alternatives in the form of chemomechanical debridement. The rationale of using calcium hydroxide as intracanal medicament is to control bleeding, necrotize residual pulp tissue and to make the necrotic tissue amenable to the dissolution action of sodium hypochlorite.

Ultrasonic activation of the irrigant enhances necrotic tissue removal and cleansing of the resorption lacunae. MTA was used as apical third filling material because of its excellent seal, biocompatibility and antimicrobial properties. Evidence of a long-term positive outcome supports the application of MTA<sup>8</sup>. It also facilitated the subsequent implementation of thermoplasticized gutta percha filling technique using Obtura II.

## Conclusion

The outcome of treatment of teeth with internal root resorption depends primarily on the size of the lesion. Large lesions cause a reduction in the resistance of the tooth to shear forces that may lead to tooth fracture. Therefore, it is imperative to initiate endodontic treatment as soon as possible to arrest the progression of the resorptive process and to prevent perforation defects or tooth fracture. However, it is needed to follow these cases to check for continued absence of symptoms for a long time.

## References

1. Walton RE, Leonard LA. Cracked tooth: an etiology for "idiopathic" internal resorption? *J Endod* 1986; 12: 167-169.
2. Brady J, Lewis DH. Internal resorption complicating orthodontic tooth movement. *Br J Orthod* 1984; 11: 155-157.
3. Brown CE, Steffel CL, Morrison SW. A case indicative of rapid, destructive internal resorption. *J. Endod* 1987; 13(10): 516-518.
4. Mummery JH. The pathology of "Pink spots" on teeth. *Brit. Dent. J* 1920; 41: 301.
5. Goaz PW, White SC. *Oral Radiology Principles and Interpretation*. Second Ed. St Louis, CV Mosby, 1987. p.455-.
6. Rabinowitch BZ. Internal resorption. *Oral Surg*. 1972; 33(2): 263-282.
7. Benenati FW. Treatment of a mandibular molar with perforating internal resorption. *J Endod*. 2001 Jul; 27(7): 474-475.
8. Torabinejad M, Chivian N (1999) Clinical applications of mineral trioxide aggregate. *J Endod* 25,197-205.

# Hereditary gingival fibromatosis

\* Sheela Sreedharan, \*\* Anju Thomas, \*\*\* Kavita Kumar

## Abstract

Hereditary gingival fibromatosis (HGF) is a rare condition that can occur as an isolated disease or as part of a syndrome or chromosomal abnormality. In severe cases, the gingival enlargement may cover the crowns of teeth and cause severe functional and esthetic concerns. This report addresses the complex nature of oral diagnosis, treatment and long-term case management in the hereditary form of recurrent gingival fibromatosis.

**Key words:** Hereditary gingival fibromatosis, Syndromes, Gingivectomy

KDJ 2013; Vol. 36, no. 2:129-132

## Introduction

Hereditary gingival fibromatosis (HGF) is characterized by a slowly progressive, benign enlargement of the keratinized oral gingival tissues. As a result, the teeth become buried, to varying degrees, beneath the redundant hyperplastic tissues, which results in both aesthetic and functional problems<sup>1</sup>. Hereditary gingival fibromatosis, also known as elephantiasis gingivae, hereditary gingival hyperplasia, idiopathic fibromatosis and hypertrophied gingivae, is a rare (1 in 750,000) hereditary condition. It was recognized probably more than a century ago, the first case was reported by Gross in 1856<sup>2</sup>. The enlargement is usually not seen at birth but has been observed during the eruption of the permanent

dentition. Some rare cases have been reported to affect the deciduous dentition<sup>3</sup>. Pedigree analyses of HGF families were consistent with simple mendelian autosomal dominant transmission pattern<sup>4</sup>, although autosomal recessive mode of inheritance have also been reported<sup>5</sup>. Recent research has shown that 2 genetically separate loci are responsible for the autosomal-dominant type of fibromatosis<sup>6</sup>. Linkage studies have localized loci for isolated, nonsyndromic autosomal dominant forms of gingival fibromatosis to chromosome 2p21-p22<sup>7</sup> and to chromosome 5q13-q22.<sup>8</sup> Recently, Son-of-sevenless (SOS-1) has been identified as the prime etiology for non-syndromic HGF. SOS-1 is a

guanine nucleotide-exchange factor that functions in the transduction of signals that control cell growth and differentiation<sup>9</sup>. Females and males appear to be equally affected.

Speech and mastication can be affected depending on the extent and severity of the overgrowth. Also malpositioning of the teeth, diastemas, prolonged retention of primary dentition and delayed eruption of permanent dentition have been reported.<sup>10</sup> Open bite, open lip posture, prominent lips and inability to approximate lips is a common characteristic in cases of severe gingival overgrowth.<sup>11</sup> Although HGF does not directly affect the alveolar bone, the gingival enlargement may increase plaque accumulation and prevent adequate plaque control, inducing periodontitis, bone loss and halitosis.

The gingival enlargement may occur alone or in conjunction with other abnormalities, as part of a syndrome, most commonly in association with hypertrichosis and epilepsy, with or without mental retardation. Other syndromes that have occasionally been associated with hereditary gingival fibromatosis are Zimmerman-Laband syndrome (defects of bone, ear, nail and nose, accompanied by hepatosplenomegaly), Murray-Puretic-Drescher syndrome

\* Professor and Head, \*\* Post Graduate Student, Dept. of Pedodontics and Preventive Dentistry, Government Dental College, Thiruvananthapuram; \*\*\* Senior Lecturer, Dept. of Pedodontics and Preventive Dentistry, St. Gregorious Dental College, Kothamangalam, Kerala. **Corresponding Author: Dr Anju Thomas; Email: anjuandsunil@yahoo.co.in**

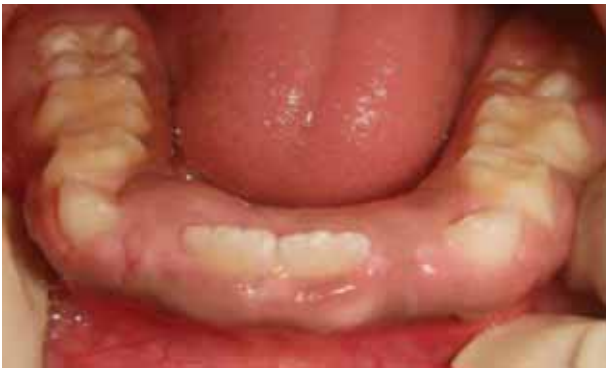

Fig. 1 Pretreatment photograph of mandibular arch

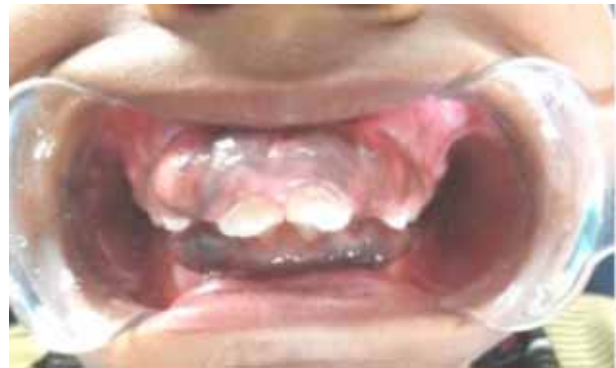

Fig. 2 Pretreatment photograph of maxillary arch

(multiple dental hyaline tumours), Rutherford syndrome (corneal dystrophy), Cowden syndrome (multiple hamartomas) and Cross syndrome (hypopigmentation with athetosis).<sup>12</sup> More recently, hearing loss and supernumerary teeth have been associated with hereditary gingival fibromatosis.<sup>13</sup> The condition has also been reported in association with deficiency of growth hormone caused by lack of growth hormone release factor.<sup>14</sup>

### Case report

An 8 year old boy accompanied by his parent, reported to the Department of Pedodontics in Govt Dental College, Thiruvananthapuram with the chief complain of gingival enlargement and unerupted lower anterior teeth. The patient's medical history was not significant and no associated endocrinological abnormality could be detected. There was no history of epilepsy or intake of medication such as anti-epileptic, antihypertensive or immunosuppressive medications that could contribute to the gingival enlargement. He did not have any history of fever, anorexia, weight loss, hearing loss, physical or mental disorder and any syndrome sign. Gingival enlargement was first noticed by parent associated with the eruption of lower permanent central incisor. The family history revealed that the patient's father and many of the members in his family were affected by same condition. His father also had gummy smile and short clinical crown in his upper anterior teeth because of gingival enlargement and was treated for the same condition in his childhood.

### Clinical examination

Intraoral examination revealed that the patient is in the mixed dentition stage. The level of oral hygiene was fair. The maxillary and mandibular dental arches

showed generalized gingival fibromatosis affecting both the vestibular and lingual–palatal surfaces. The gingival enlargement was most evident in the maxillary and mandibular anterior regions. Patient shows generalized, obese, nodular, diffuse enlargement of gingiva on both maxillary and mandibular arches which were pink in color, firm and fibrous consistency. The crowns of the teeth in the anterior region were barely visible because they were buried deep within the enlarged gingiva. Radiography showed no specific changes in the teeth or alveolar bone.

Mandibular vestibular and lingual gingivectomy, with reverse bevel incisions, was performed from canine to canine, under local anesthesia, to obtain a smoother gingival contour (Fig:1). A biopsy sample of the gingival tissues was submitted for histologic evaluation. A postoperative dressing was applied. Six months later, a similar procedure was performed for the maxilla (Fig:2). A 0.12% chlorhexidine gluconate rinse was prescribed for administration twice a day for 2 weeks. The patient was seen at 1, 3 and 5 weeks postoperatively. Postsurgical healing was uneventful (Fig:3,4).

### Histopathology

Microscopic examination of the specimens confirmed that the general appearance of the tissue was consistent with hereditary gingival hyperplasia: abundant, dense connective tissue in which markedly thickened fibre bundles alternated with relatively finer collagen fascicles, the fibre bundles being speckled with small, dark fusiform nuclei of fibroblastic cells with scanty cytoplasm plump fibroblasts were seen only focally. The surface epithelium was characteristically hyperplastic, exhibiting a pseudoepitheliomatous appearance.



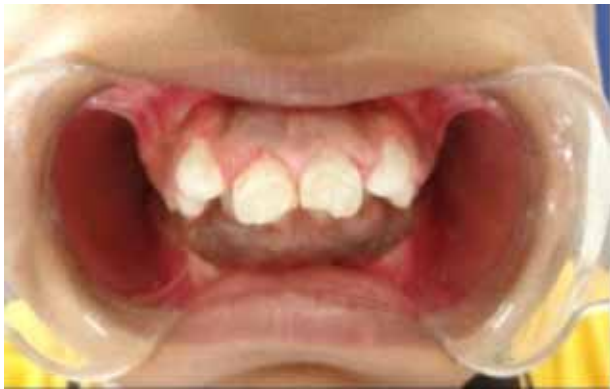

Fig. 3 Post treatment photograph of maxillary arch

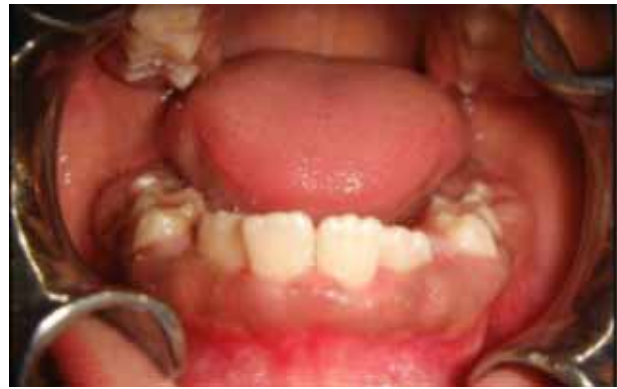

Fig. 4 Posttreatment photograph of maxillary arch

## Discussion

The mode of genetic transmission in this patient is autosomal dominant inheritance, because family members of both sexes were affected and the condition was present in successive generations (father, aunts and child). Hereditary gingival fibromatosis can occur as an isolated disorder or as part of a syndrome.<sup>15</sup> In this case, the patient did not exhibit any signs or symptoms suggesting that the condition was syndromic. The diagnosis was made on the basis of the clinical presentation, the family history, the pattern of recurrence and the characteristic microscopic features of the histology samples.

Based on the American Academy of Periodontology (AAP) 1999 Classification of Periodontal Diseases and Conditions, gingival enlargement can occur because of pregnancy-associated hormonal changes, various medications causing changes in extracellular matrix physiology, or genetic disorders. Independent from inflammatory etiological factors, periodontal tumors and cysts also may present as localized gingival enlargements. The tissue enlargement may be localized or generalized, confined to the marginal gingiva or to the papillary tissue, and involve both the marginal and attached gingivae<sup>16</sup>. The degree of enlargement can be categorized as follows:

- Grade 0: No gingival enlargement.
- Grade 1: Enlargement confined to interdental papilla.
- Grade 2: Enlargement involving papilla and marginal gingivae.
- Grade 3: Enlargement covering three quarters or more of the crown.

## Etiopathogenesis of HGF

The cellular and molecular mechanisms involved in HGF etiology are still not completely understood. HGF is characterized histologically by an accumulation of dense fibrous connective tissue. This is believed to be due to an imbalance between synthesis and degradation of extracellular matrix molecules or due to an alteration in fibroblast proliferation. Different pathogenic mechanisms have been proposed and examined over the years. Researchers found that HGF fibroblasts are phenotypically distinct from normal human gingival fibroblasts in vitro and proliferate more rapidly and produce double the amount of type I collagen and fibronectin. Autocrine stimulation of transforming growth factor (TGF- $\beta$ ) produced by HGF fibroblast contributes to this increased production. The excessive production of connective tissue products is directly related to the increase in gingival bulk<sup>17</sup>.

Another possible mechanism of HGF pathogenesis is impairment in extracellular matrix degradation. Collagen turnover in gingival tissues is high and degradation occurs by two main pathways: fibroblast phagocytosis and degradation in the extracellular space by members of the matrix metalloproteinase (MMP) family of proteases. The MMP pathway is impaired in HGF: a decreased level of expression and activity of MMP-1 and MMP-2 has been described in HGF cells, resulting in collagen type I accumulation<sup>18</sup>. In addition, MMP-2 inhibition results to an abnormal accumulation of glycosaminoglycans and fibronectin in the gingival tissues. It has been documented that TGF- $\beta$ 1 downregulates MMP-1 and MMP-2 expression in an autocrine fashion, thus playing a key role in the biochemical mechanisms associated in the pathogenesis of gingival overgrowth<sup>19</sup>. Furthermore, TGF- $\beta$ 1 may induce fibroblast differentiation into

myofibroblasts, which are considered predominant cells in matrix synthesis in interstitial fibrosis such as HGF<sup>20</sup>. All of these actions of TGF- $\beta$ 1 result in a dysregulation of the connective tissue homeostasis, leading to the accumulation of extracellular matrix which clinically results in gingival enlargement.

## Conclusion

This report presents hereditary gingival fibromatosis in a family, described with multiple affected subjects in successive generations, consistent with an autosomal dominant mode of inheritance. Recent investigations have yielded new invaluable information on the genetic and molecular mechanisms of gingival overgrowth, but further research is needed to elucidate the etiology and complex pathogenesis of this condition.

## Bibliography

1. Thomas C, Hart, Debra Pallos, Donald W. Bowden, Joey Bolyard, Mark J. Pettenati, and Jose R. Cortelli. Genetic Linkage of Hereditary Gingival Fibromatosis to Chromosome 2p21. *Am. J. Hum. Genet* 1998;62:876–883.
2. Fletcher J. Gingival abnormalities of genetic origin: a preliminary communication with special reference to hereditary generalized gingival fibromatosis. *J Dent Res* 1966;45:597-612.
3. Breen GH, Addante R, Black CC.: Early Onset of Hereditary Gingival Fibromatosis in a 28 month-old. *Pediatr Den*. 2009 Jul-Aug; 31(4):286-8.
4. Bozzo L, de Almedia OP, Scully C, Aldred MJ. Hereditary gingival fibromatosis. Report of an extensive four-generation pedigree. *Oral Surg Oral Med Oral Pathol* 1994; 78(4):452-4.
5. Jorgenson RJ, Cocker EM. Variation in the inheritance and expression of gingival fibromatosis. *J Periodontol* 1974; 45(7):472-7.
6. Hart IC, Pallos D, Bozzo L, Almeida OP, Marazita ML, O'Connell JR, and other. Evidence of genetic heterogeneity for hereditary gingival fibromatosis. *J Dent Res* 2000; 79(10):1758-64.
7. Xiao S, Wang X, Qu B, Yang M, Liu G, Bu L, Wang Y, Zhu L, Lei H, Hu L, Zhang X, Liu J, Zhao G, Kong X (2000) Refinement of the locus for autosomal dominant hereditary gingival fibromatosis (GINGF) to a 3.8-cM region on 2p21. *Genomics* 68:247–252.
8. Xiao S, Bu L, Zhu L, Zheng G, Yang M, Qian M, Hu L, Liu J, Zhao G, Kong X (2001) A new locus for hereditary gingival fibromatosis (GINGF2) maps to 5q13-q22. *Genomics* 74:180–185.
9. Hakkinen L, Csiszar A. Hereditary gingival fibromatosis: characteristics and novel putative pathogenic mechanisms. *J Dent Res*. 2007;86:25-34.
10. Kavvadia K, Pepelassi E, Alexandridis C, Arkadopoulou A, Polyzois G, Tossios K. Gingival Fibromatosis and Significant Tooth Eruption Delay in an 11-year-old male: A 30-month Follow-up. *Int J Paediatr Dent* 2005; 15:294-302.
11. Baptista IP. Hereditary Gingival Fibromatosis: A Case Report. *J Clin Periodontol* 2002; 29:871-874.
12. Gorlin RJ, Pinborg JJ, Cohen Jr MM. Syndromes of the head and neck. 2nd edition. New York: McGraw Hill; 1976. p. 329-36.
13. Wynne SE, Aldred MJ, Bartold MP. Hereditary gingival fibromatosis associated with hearing loss and supernumerary teeth — a new syndrome. *J Periodontol* 1995; 66(1):75-9.
14. Oikarinen K, Salo T, Kaar ML, Lahtela P, Altonen M. Hereditary gingival fibromatosis associated with growth hormone deficiency. *Br J Oral Maxillofac Surg* 1990; 28(5):335-9.
15. Wynne SE, Aldred MJ, Bartold MP. Hereditary gingival fibromatosis associated with hearing loss and supernumerary teeth — a new syndrome. *J Periodontol* 1995; 66(1):75-9.
16. Carranza F. Gingival enlargement. In: Carranza F, ed. *Clinical Periodontology*. 7th ed. Philadelphia, Pa: WB Saunders; 1990:125-149.
17. Tipton DA, Dabbous MK. Autocrine Transforming Growth Factor Beta Stimulation of Extracellular Matrix Production by Fibroblasts From Fibrotic Human Gingiva. *J Periodontol* 1998; 69:609-619.
18. Martelli-Junior H, Cotrim P, Graner E, Sauk JJ, Coletta RD. Effect of Transforming Growth Factor Beta1, Interleukin-6, and Interferon-gamma on the Expression of Type I Collagen, Heat Shock Protein 47, Matrix Metalloproteinase (MMP)-1 and MMP-2 by Fibroblasts From Normal Gingiva and Hereditary Gingival Fibromatosis. *J Periodontol* 2003; 74:296-306.
19. Cotrim P, Martelli-Junior H, Graner E, Sauk JJ, Coletta RD. Cyclosporin A Induces Proliferation in Human Gingival Fibroblasts Via Induction of Transforming Growth Factor-beta1. *J Periodontol* 2003;74:1625-1633.
20. Grotendorst GR, Rahmanic H, Duncan MR. Combinatorial Signaling Pathways Determine Fibroblast Proliferation and Myofibroblast Differentiation. *FASEB J* 2004;18:469-479.



**JOIN**

**IDA-HOPE** (Help Offered to Professionals in Emergencies). Members are requested to contact their respective IDA local branch HOPE representative to receive original application forms

# HAT cast indexing technique

\* Joy P.T., \*\* A.Q. Azad, \*\*\* K. Harshakumar, \* Zeenath H.

## Abstract

Indexing of the cast is an integral part of the surveying procedure since it records the relation of the cast to the surveyor and helps to return the cast to the surveyor for future reference. Various techniques are available for the same. The 'HAT Cast Indexing Technique' is unique in this category as it is very easy to learn.

**Key words :** Surveyor, Indexing technique

KDJ 2013; Vol. 36, no. 2:133-134

## Introduction

Cast surveyor relationship can be verified by indexing so that the cast can be repositioned to the surveying table repeatedly. Various methods are practiced for the indexing of the cast.<sup>1-4</sup> 'Tripoding' is the most popular one. Another method is to score two sides and the dorsal aspect of the art portion of the cast with a sharp instrument held against the analysing rod.<sup>5</sup> These techniques experience difficulty when the cast is reoriented frequently especially in the diagnostic stages of fabrication of prosthesis. A simple technique for reorienting the cast to the surveyor is described here by incorporating an indexing device which was designed at the Dept. of Prosthodontics, Govt. Dental College, Thiruvananthapuram namely HAT (Harshakumar Azad

Thiruvananthapuram) Cast Indexing Technique.

Parts of the indexing device

- (1) A hollow cylinder, one end of which was closed (Fig 1).
- (2) An orientation rod having a length of 50mm; one end of which snugly fitted into the hollow cylinder (Fig 1).
- (3) A transfer coping that fitted in to the cylinder (Fig 4).

## Technique

### Indexing of the cast

Once the tilt of the cast in the surveying table was finalised, a straight hand-piece was attached to the surveyor. A hole was made in the cast to a depth of 6mm with a drill of diameter 3mm (Black & Decker). The orientation rod with the cylinder was attached to the hand piece and the cylinder was

fixed into the hole on the model using cyanoacrylate (Fig 2). The rod was removed from the cylinder (Fig 3).

### Reorienting the cast to the surveyor

Cast was secured onto the surveyor and locking screw was loosened. The orientation rod was attached to the straight headpiece fitted on the surveyor. The cast was tilted in such a manner that the rod will engage into the cylinder. Then the survey table was fixed.

### Transferring the index to the duplicating cast

The transfer coping was attached to the cylinder and the cast was duplicated (Fig 4,5). While duplicating, the transfer coping got attached to the impression (Fig 6). Another cylinder of same dimension was attached to the transfer coping and the cast was poured (Fig 7). The new cylinder thus became a part of the duplicated cast (Fig 8).

### Multiple indexing

In certain clinical conditions multiple implants have to be placed in different angulations. For making surgical guides in such situations separate tilt has to be given for each implant. By using HAT Indexing Technique we can incorporate multiple indexing in different tilts in the same cast (Fig 9).

\* Asst Professor, \*\* PG Student, \*\*\* Prof & HOD, Dept. of Prosthodontics, Govt. Dental College, Thiruvananthapuram  
Corresponding Author: Dr. Joy P T; Email: jyomaria1980@yahoo.co.in



Fig 1



Fig 2

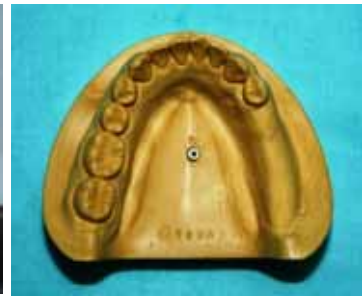

Fig 3



Fig 4

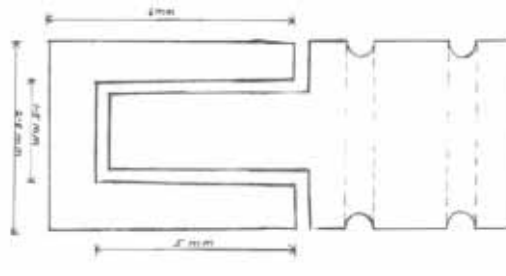


Fig 5

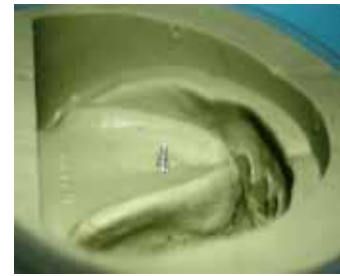

Fig 6



Fig 7



Fig 8

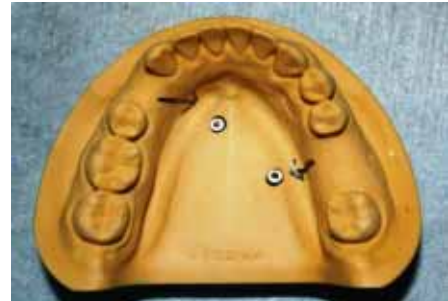

Fig 9

## Conclusion

The technique described for indexing is easy, and accurate. Reorienting the cast becomes effortless with this technique. Any number of duplicate casts can be fabricated and which can be reoriented to the surveyor. Multiple indexing according to multiple tilt can be given in same cast.

## References

- 1) Sergio Reinaldo De Fiori. Transferring the path of insertion from the diagnostic cast to multiple master casts. *J Prosthet Dent.*1983; 50:733-34
- 2) Antony D Steas. Recording and reproducing the tilt of the cast on a surveyor. . *J Prosthet Dent.*1987; 57: 121-25.
- 3) Sykora O. A new tripodding technique. *J Prosthet Dent.* 1980 Oct;44(4):463-4.
- 4) Bezzon OL; Ribeiro RF; Pagnano VO Device for recording the path of insertion for removable partial dentures. *J Prosthet Dent.*2000; 84: 136-8
- 5) Alan B.Carr, Glen P. McGivney, David T. Brown. *McCracken's Removable Partial Prosthodontics.* 11th ed. Mosby; 2005



# Surgical management of large cyst invading the maxillary sinus

\* Roshni.A

## Abstract

Cyst is a pathological cavity or sac within the hard or soft tissue that may contain fluid, semi fluid or gas. It may be lined with epithelium, fibrous tissue or occasionally even by a euplastic tissue. 1Cyst in maxilla destroy a large portion of maxilla, may encroach on the antrum or nasal cavity. In this paper a case of periapical cyst extending into the maxillary sinus and attaining a considerably large size with facial asymmetry is presented.

KDJ 2013; Vol. 36, no. 2:135-137

## Introduction

Cyst of the jaws are classified with several categories depending on histogenesis and etiology. Those arising from odontogenic epithelium are called odontogenic, those that have their sources in other epithelial structures are known as non odontogenic. According to international classification of disease (ICD-10), odontogenic cyst are classified into radicular cyst which is further divided into apical, periapical, residual cyst and embrogenic cyst further classified into follicular and lateral periodontal.<sup>2</sup> The formation of radicular cyst associated with epithelial cellular inclusion in the apical area of tooth root. These cysts derive from remnants of embrogenic epithelium so called the malassez or epithelial debris.<sup>2</sup> These epithelial inclusions are being

irritated by periodontal inflammatory process which results in their growth and proliferation ending with formation of microscopic cavities gradually filling with transudation.<sup>3</sup> A cyst granuloma forms a reaction to the transudation induced pressure increase. The volume of cystic formation expands because of pressure inducing the resorption of cancellous bone and finally cortical bone. The pressure of transudation may vary from 1.3 pa (10mm Hg) to 10.7 pa (80mm of Hg) depending on intensity of inflammatory process.<sup>3</sup>

The distribution of jaw cyst according to diagnosis in general population is radicular cyst 56%, dentigerous cyst 17%, nasopalatine cyst 13%, odontogenic keratocyst 11%, globulomaxillary cyst 2.3%, traumatic bone cyst 1% and

eruption cyst 0.7%.<sup>4</sup> Radicular cyst are rare in primary dentition, representing only 0.5-3.3% of total number of radicular cyst in primary dentition.<sup>5</sup> Several long term development process are taking place in maxillofacial area during the paediatric age group. These include the three dimensional growth of maxillofacial skeleton as well as odontogenesis of deciduous and permanent dentition all of which may be associated with cyst formation. The incidence is highest in the anterior maxilla than mandible as maxillary incisors are more prone to caries, pulpal death due to developmental defects and irritating effects of synthetic restorable material. During first stage when there is no visible deformity in alveolar process nor body of maxilla the cyst or cyst granuloma usually develops asymptotically, thus the lesion may be diagnosed only radiographically.<sup>6</sup> As cyst grows visible facial asymmetry may appear. A change in configuration of alveolar process or body of jaw bone may be observed as a round prominence, the size of prominence varies according to development stage of cyst ranging from pea size to large size. The maxillary cyst tend to displace the fundus of nasal cavity if the maxillary sinus giving ground to root apices are well devolped, the cyst grows gradually

\*Professor, Department of Oral and Maxillofacial Surgery, MES Dental College, Perithalmanna, Kerala.  
Corresponding Author: Dr. Roshni A.; Email: roshnidr2000@yahoo.co.in

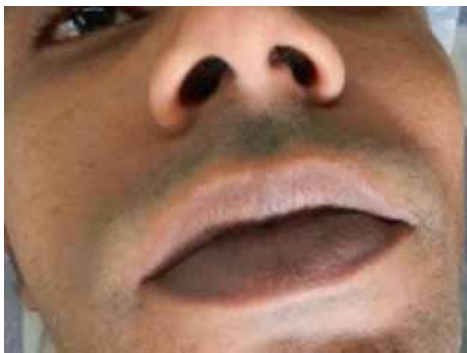

Fig 1 Extra oral swelling

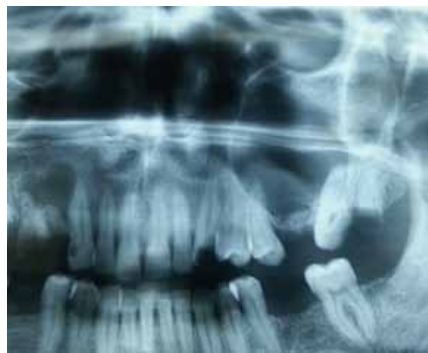

Fig 2 OPG picture of cyst

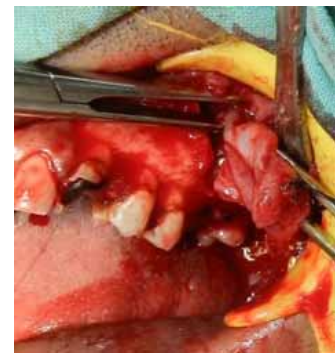

Fig 3 Removal of cyst

into sinus cavity displacing its fundus. The growth of cyst causes the atrophy of nerve and vessel strand entering the root apex which leads to insufficient blood supply to tooth pulp and finally pulp necrosis.<sup>7</sup> As cyst grows a sensation of an egg shell crackling may be felt under finger pressure, as the atrophy of bone progresses a window opens into the cortical part of the bone, with periosteum and gingival left above. A new symptom of fluctuation develops. Additionally roots of adjacent teeth are displaced. The soft tissue overlying the cyst may be normal in colour.

In case of infection of cyst, bacteriologic examination often reveals cocci, klebsiella, gram negative bacilli, gram positive microorganisms, sporangium bacteria, candida species, seldom obligate anaerobic forms of bacteria as well as bacterioids may be detected.<sup>8</sup> Contents of suspected cyst should be aspirated and examined for presence of cholesterol crystals. It is essential to use a wide bore needle as cyst contents may be viscous. Xray finding reveals a radiolucency surrounded by a radioopaque line of condensed bone. This characteristic margin may not be present when a cyst is either very large or is infected or when the contents are draining through a sinus. The treatment of choice is dependent on the size and localisation of the lesion, the bone integrity of cystic wall and its proximity to vital structures. The surgical approach to cystic lesions of the jaw is either marsupialisation or nucleation.

### Case report

A 29 year old male patient reported to department of oral and maxillofacial surgery with the chief complaint of facial swelling on the left side since two months. On examination swelling in the left cheek area which was painless, firm in consistency and irregular in shape. Intraorally swelling was noted on the buccal sulcus extending from canine region to third molar region on the left side. The cyst was seen extending

superiorly also, roughly measuring 3.5 cm by 3 cm. The overlying mucosa is normal. Grossly decayed tooth was visible in relation to upper left first molar, second and third molar. On palpation swelling was soft and fluctuant. Palatal mucosa was intact. No lymph nodes were palpable. On aspiration of the lesion produced straw coloured fluid which was given for biochemical analysis which revealed cholesterol crystals. Radiograph examination revealed radiolucent lesion seen extending from first left premolar to third molar area. The lesion is seen extending to maxillary sinus and has a radio opaque line. The provisional diagnosis was periapical cyst. Surgical removal of cyst under general anaesthesia was planned.

Total enucleation is removal of cyst along with the entire lining to be done, for which a full thickness mucoperiosteal flap was raised from lateral incisors to third molar region on left side. Two releasing incision done in the region of lateral incisor and third molar region for better accessibility. Creation of large mucoperiosteal flap is an essential preliminary to enucleation of cyst lining. A periosteal elevator is carefully inserted under the margins of the flap and elevate the mucoperiosteum from the underlying bone until the margins of the bony defect is exposed. In this way any area in which the cyst lining is attached to the soft tissue overlying it is visualized. After separating the bony margins of the defect from the cystic lining, the thin bone overlying the lesion is removed with rongeur forceps until cyst sac is widely exposed. A plane of cleavage is created between the soft tissue lining of the cyst and enclosing bone to deliver the cyst sac in one piece. Grossly decayed tooth in relation to left first molar, second molar and third molar was extracted. Sharp bony margins were trimmed and smoothed. For complete haemostasis and to prevent wound break down, a ribbon gauze pack soaked with iodoform was placed in the cavity and flap was closed with 3-0 silk. This pack was left in situ for one week

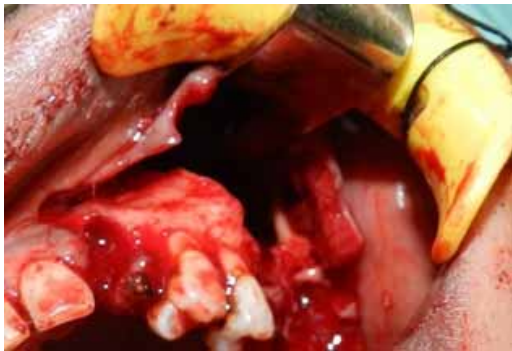

Fig. 4 Bony cavity after removal of cyst

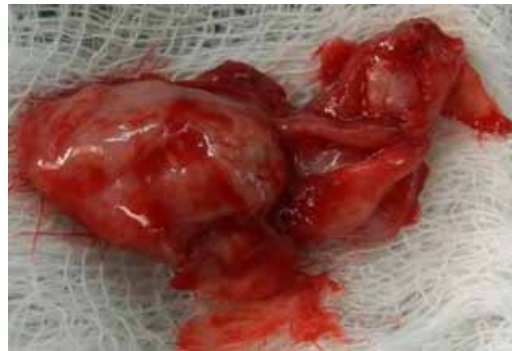

Fig. 5 Excised tissue

postoperatively and removed in dental outpatient department under local anaesthesia. The excised tissue was sent for histopathological examination which was confirmed as periapical cyst.

## Discussion

Jaw cysts usually have unspecific clinical appearance. Cysts have asymptomatic periods of growth and development. Smooth, painless, inconsistent swellings with tissue above that appears normal is suggestive for the cyst formation and may equally mean that the underlying tissue is benign and malignant.<sup>9</sup> Cysts lesions must be carefully analyzed and differentiated from normal anatomic structures using radiological finding. It is important to determine the size of the lesion. By observing the edge of the lesion, essential data on lesion behaviour can be determined, as well as its histological character assumed. Majority of lesions associated with crown of an interrupted tooth are either odontogenic cysts or benign tumours. Nowadays, surgical methods are exclusively used in cysts therapy. There are many of them, and a relevant method depends on size and localization. Each cyst formation, after its shelling, needs to be taken for a pathohistological finding. In planning the surgical intervention it is critical to be aware of potential complications that can occur during and after the intervention. At this, it is especially important to beware of a potential injury of the vital anatomical elements and the ensuing postoperative infection. Bone structures should carefully be protected because a regeneration process itself is reliant on them. The regeneration process should be monitored by regular check-ups and roentgenogram analysis. Enucleation is defined as a complete removal of the cystic lining with healing by primary intention while marsupialisation is synonymous with Partsch's operation, and is the conversion of a cyst into a pouch<sup>10</sup>, it requires considerable aftercare and patient cooperation in keeping the cavity clean whilst it resolves and heals by

relieving the internal pressure, it is indicated when cyst is in close proximity to vital structures and where there is significant risk of injury with enucleation. The marsupialisation concerns not only the radicular cysts, also follicular cysts can be treated by this technique in order to conserve and guide the eruption of permanent teeth. Although small cystic lesions frequently heal simply with endodontic therapy, larger lesions may need additional treatment. Untreated cysts may expand causing local tissue destruction and deformities. In a mixed dentition, several odontogenic developmental processes take place. Final confirmation of diagnosis can be done based on symptoms and clinical results in pathohistological finding, but surprises are also possible. In clinical and pathological studies, as well as based on histology, pathohistological similarity of some heterogeneous phenomenon is sometimes implied.<sup>11</sup>

## References

1. Neelima mallik Text book of oral and maxillofacial surgery 3<sup>rd</sup> edition, jaypee.. 2012 pg 491
2. Bernardskij JI principles of facial mandibular and dental surgery 3<sup>rd</sup> edition Vitebsk 1998 pg 303-318
3. Peterson LJ et al contemporary oral and maxillofacial surgery 4<sup>th</sup> edition st, Louis: mosby 2003.pg 480-491.
4. Shear M et al cyst of oral and maxillofacial region, 4<sup>th</sup> edition, oxford Blackwell munksgaard 2007.
5. Shear M, Radicular and residual cyst in cyst of oral region 3<sup>rd</sup> edition. wright, Bristol: 1992 pp 136-162.
6. Moore GJ Principles of oral and maxillofacial surgery. 5<sup>th</sup> edition Blackwell science 2001;pg 175-90
7. Tanomoto K, et al T. radiographic characteristics of calcifying odontogenic cyst. Int J oral maxillofac surg 1988;17:29-32.
8. Bezrokov VM et al principles of dental and facial mandibular surgery, Moscow 2000pg 6466-63.
9. Coromians O et al Acta stomologica Belbica, 90(1993)149-7.
10. Neaverth EJ et al Decompression of periapical cystic lesions J endodont 1982;8:175-182.
11. Paulus. W et al Histopathology 30(1997)172-8.

# Central giant cell granuloma of the mandibular condyle: A rare presentation and a diagnostic dilemma

\* Mili James, \*\* K. George Verghese, \*\*\* S. Mohan

## Introduction

According to the World Health Organization, central giant cell granuloma (CGCG) is an intraosseous lesion consisting of cellular fibrous tissue that contains multiple foci of hemorrhage, multinucleated giant cells, and trabecules of woven bone<sup>1</sup>. This lesion accounts for less than 7% of all benign jaw tumors<sup>2</sup> and was considered by Jaffe<sup>3</sup> as a locally reparative reaction of bone possibly due to either an inflammatory response, hemorrhage, or local trauma.

CGCG of the jaws, occurs over a wide age range<sup>4</sup>. Kaffe et al<sup>5</sup> reported that CGCG is diagnosed during the first 2 decades of life in approximately 48% of the cases, whereas almost 60% of lesions are evident before the age of 30. Waldrom and Shafer<sup>4</sup> and Eisenbud et al<sup>6</sup> found a significant female predominance for CGCG, whereas others have reported only slight female prevalence. CGCG is considerably more common in the mandible than in the maxilla. Most investigators have found that about 70% of CGCGs involve the mandible. The majority of cases have occurred in the molar-premolar area, and some of those extended to the ascending ramus.<sup>5-7</sup>

## Abstract

The mandibular condyle is a very rare location for central giant cell granuloma (CGCG), and there are only a few case reports in the literature regarding the involvement of this region. The presence of CGCG in the mandibular condyle creates a diagnostic and therapeutic challenge for the oral and maxillofacial surgeon. The CGCG is not usually included in the differential diagnosis of lesions of the mandibular condyle. The purpose of this report was to describe an unusual presentation of CGCG involving the mandibular condyle and to discuss the differential diagnosis, radiographic presentation, and treatment of this lesion.

**Key words:** central giant cell granuloma, mandibular condyle, diagnostic dilemma

KDJ 2013; Vol. 36, no. 2:138-141

The mandibular condyle is a very rare location for the CGCG, and there are only a few case reports in the literature regarding the involvement of this region<sup>8,10</sup>. The presence of CGCG in the mandibular condyle creates a diagnostic and therapeutic challenge for the oral and maxillofacial surgeon. The CGCG is not usually included in the differential diagnosis of lesions of the mandibular condyle. The purpose of this report was to describe an unusual presentation of CGCG involving the mandibular condyle and to

discuss the differential diagnosis, radiographic presentation, and treatment of this lesion.

## Case report

A 48 old man reported to the Dept of Oral and Maxillofacial surgery, Govt Dental College, Kottayam complaining of swelling in relation to right preauricular area since five months and with a history of assault one year back.

## Clinical findings

The clinical examination

\* Junior Resident, \*\* Prof & Principal, \*\*\* Prof & HOD, Dept. of Oral & Maxillofacial Surgery, Govt. Dental College, Kottayam  
**Corresponding Author: Dr Mili James; Email: drmili@gmail.com**



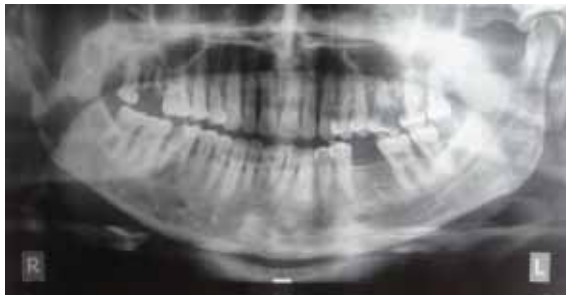

Fig. 1 Preoperative OPG

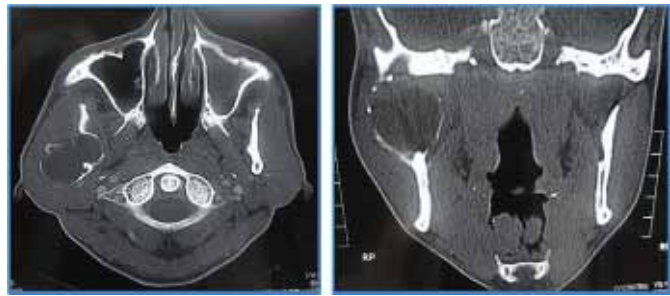


Fig. 2 CT scan axial and coronal

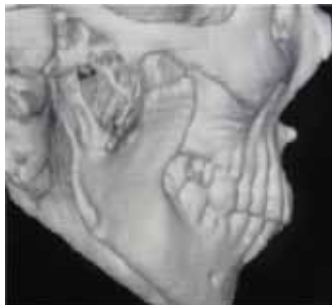

Fig. 3 3D CT Reconstruction showed gross destruction of the right condyle

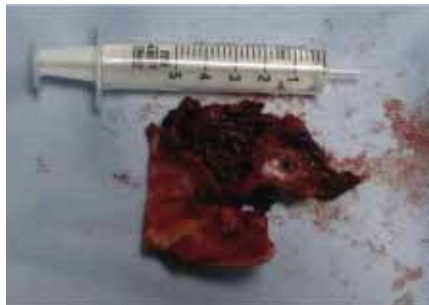


Fig. 4 Resected specimen

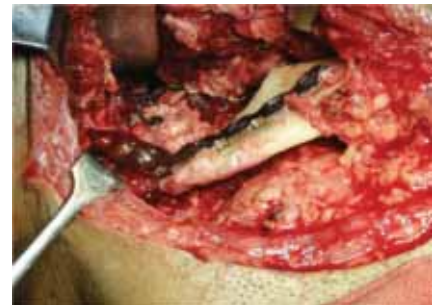

Fig. 5 After reconstruction

revealed a non-tender firm to hard swelling of 3x2cm size in the right pre auricular region without any associated trismus, derangement of occlusion or deviation while opening the mouth.

### Diagnostic work up

OPG (Fig. 1) revealed a multilocular radiolucent lesion involving the right condyle. For further evaluation an ultra sound scan of the lesion was done and it yielded a report of well defined anechoic lesion of 3x2cm noted in the preauricular region suggestive of resolved abscess or retention cyst. For a conclusive diagnosis of the lesion FNAC was done and the report was suggestive of cystic lesion of salivary gland origin. Repeat FNAC report of the lesion came as multiple myeloma. Since all these diagnostic modalities failed to produce a definitive diagnosis regarding the nature of the lesion it was decided to do a CT scan (Fig.2) with 3D reconstruction (Fig.3) of the involved right condyle. The CT scan revealed a grossly destroyed right condyle with numerous perforations on both lateral and medial aspect giving it a net like appearance. To add to the diagnostic dilemma the CT report came as ameloblastoma.

### Treatment plan

Based on the investigation findings a plan for

resection and reconstruction of right mandibular condyle was planned. The mandibular condyle was approached via submandibular incision and was resected (Fig. 4) in toto along with a soft tissue margin of 1 cm. A stainless steel reconstruction plate was used to correct the defect (Fig. 5).

Post operative histopathology report showed loose fibrillar connective tissue stroma interspersed with many fibroblasts, small capillaries and collagen fibres. In addition there are multinucleated giant cells, foci of extravasated blood and hemosiderin pigment. At the periphery new bone formation is also seen. All these histopathological features were suggestive of Central giant cell granuloma. (Fig.7)

The patient was followed up for one year after surgery and there was no evidence of recurrence or occlusal disharmony (Fig. 8). The condyle movements were found to be normal in both anteroposterior and lateral excursions.

### Discussion

This lesion accounts for less than 7% of all benign jaw tumors<sup>2</sup> and was considered by Jaffe<sup>3</sup> as a locally reparative reaction of bone possibly due to either an inflammatory response, hemorrhage, or local trauma. The CGCG appears as a painless expansile mass. Some investigators separate the CGCG into

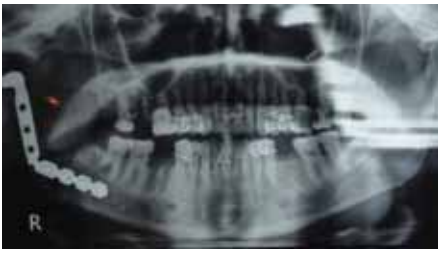


Fig. 6 Post operative OPG

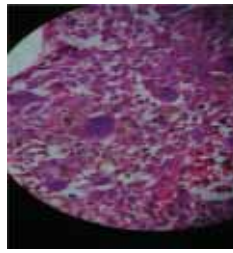


Fig. 7 Histopathology slide showing multinucleated giant cells, fibroblasts and hemosiderin pigment

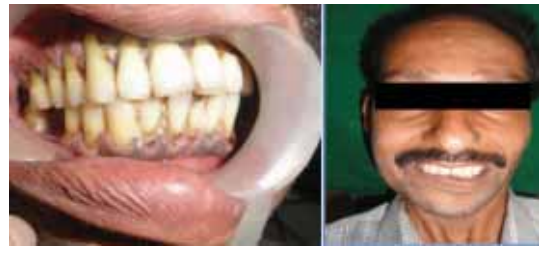

Fig. 8 One year post operative occlusion and facial photograph

aggressive and nonaggressive types. The aggressive type is usually encountered in younger patients, has a higher rate of growth associated with bone expansion, and has a tendency to recur. The nonaggressive type is usually an asymptomatic painless swelling with slow growth<sup>11</sup>.

The CGCG can present as a unilocular or multilocular radiolucency<sup>4,5,7</sup>. Reports indicate 44% to 50% of CGCGs appear as a unilocular radiolucency and 50% to 60% present as a multilocular radiolucency<sup>4,5,7</sup>. The presentation of this lesion outside the jawbone is very rare. Many authors believe that when it occurs in locations other than the jaws, it is considered a central giant cell tumor<sup>12-14</sup>. Central giant cell tumor presents most commonly in long bones, it shows a distinguishable histology and indicates an aggressive clinical course. There have been several reports of CGCG occurring in association with pregnancy or menarche<sup>15-18</sup>. The CGCG is more common in the mandible than the maxilla, and most investigators have found that 70% of lesions occur in the lower jaw. Patients with CGCG present with asymptomatic localized swelling of the affected area and 20% or more have pain or paresthesia<sup>2,4,5</sup>. Waldron and Shafer<sup>4</sup> reported that the CGCG tends to occur anterior to the first molars in either jaw. In addition, they reported that in 21% of the cases the lesions crossed the midline. Other studies reported cases of CGCG extended to the mandibular ramus.

### Clinical features

Generally central giant cell granuloma is found to affect young age group, <sup>5-15</sup>, below 30 years. The male: female ratio is found to be 1:2. Mandible is seen to get affected three times greater than maxilla with the predominant site being premolar, molar area, rarely

crossing the midline. Radiologically it appears as a unilocular or multilocular radiolucent lesion which thins cortices and often displaces teeth. In the present case it was an older male with a radiolucent lesion involving the right condyle of the mandible which is an unusual site.

The differential diagnosis based on the clinical features include, odontogenic keratocyst, odontogenic myxoma, ameloblastic fibroma, langerhans cell histiocytosis, central arteriovenous hemangioma and if the patient is above 15 years of age then ameloblastoma may also be considered as a diagnosis.

### Histopathology

Histopathologically the lesion appears to be of red to brown in colour with a fibroblastic stroma, collagen fibres, extravasated RBCs, hemociderin, macrophages [containing hemociderin] multinucleated giant cells osteoclasts and osteoid at periphery.

The proliferating cell in the development of central giant cell granuloma is fibroblast and was proven by immunocytochemistry. Fibroblast with the help of cytokines attract monocytes to the site of trauma. These monocytes get converted to multinucleated giant cells of osteoclastic variety.<sup>21</sup> Differential diagnosis based on histopathologic report includes mixed lesions like cherubism, fibrous dysplasia and brown tumours of hyperparathyroidism.

### Management

Various methods have been described for the treatment of CGCG of the jaws. Curettage alone or in combination with resection without continuity loss is the treatment modality most often used. Kremer et al<sup>19</sup> reported successful treatment, using intralesional corticosteroid injection Triamcinolone 10mg/ml for

each 1ml/1cm of lesion for 6 wks. Harris<sup>20</sup> who used human calcitonin administered subcutaneously [Inj. Calcitonin subcutaneously daily for 18 months], has reported a total regression of CGCG by inhibition of osteoclastogenesis. Injection of alpha interferon subcutaneously is found to cure CGCG by a process of antiangiogenesis.

Till date there were only four reports of primary CGCG involving the mandibular condyle. Tasanen et al<sup>8</sup> and Shensa and Nasser<sup>10</sup> reported a case of CGCG of the mandibular condyle. Cohen and Hertzanu<sup>9</sup> studied 16 cases of CGCG and reported that two patients had involvement of the condylar process.

The differential diagnosis of condylar lesions includes tumors, cysts, and tumor-like conditions. Biopsy of condylar lesions creates difficulty because of the complicated surgical approach to this region. Some condylar lesions can arise primarily from the joints, whereas others can metastasize. These lesions can potentially originate from bone, cartilage, or synovium membrane. Bony and cartilaginous tumors of the condyle are more common than synovial disorders. Osteoblastoma, osteochondroma, chondroblastoma, chondrosarcoma, and neurofibroma were reported to involve the condyle. These can present as radiolucent, radiopaque, or mixed lesions causing distortion or erosion. Malignant tumors can involve the condyle and may arise from the joint capsule or tendon sheath.

Usually, malignant condylar tumors cause irregular bony destruction due to their rapid rate of growth. In the present case, the lesion was considered to be benign according to the clinical and radiographic presentation. This is the main reason an excision biopsy was performed.

## Summary

The presentation of CGCG in the mandibular condyle is very rare and can be a diagnostic challenge. In the present case and in the four other cases reported in the literature, the clinical and radiographic presentations of CGCG of the mandibular condyle were well circumscribed without evidence of aggressive behaviour. In the present case the condyle was resected due to the gross destruction and reconstructed with stainless steel reconstruction plate. The patient was followed upto one year without any sign of recurrence or occlusal disharmony.

## References

1. Kramer IR, Pindborg JJ, Shear M: Histological Typing of Odontogenic Tumors (ed 2). Berlin, Germany, Springer-Verlag, 1991,p 31
2. Austin LT, Dahlin CD, Royer QR: Central giant cell granuloma and related condition affecting the jawbone. *Oral Surg Oral Med Oral Pathol* 12:1259, 1955
3. Jaffe HL: Giant cell reparative granuloma, traumatic bone cyst and fibrous (fibro-osseous) dysplasia of the jawbones. *Oral Surg Oral Med Oral Pathol* 6:159, 1953
4. Waldron CA, Shafer WG: The central giant cell granuloma of the jaws: An analysis of 38 cases. *Am J Clin Pathol* 45:437, 1966
5. Kaffe I, Ardekian L, Taicher S, et al: Radiographic features of central giant cell granuloma of the jaws. *Oral Surg Oral Med Oral Pathol Oral Radiol Endod* 81:720, 1996
6. Eisenbud L, Stern M, Rothberg M, et al: Central giant cell granuloma of the jaws: Experience in the management of 37 cases. *J Oral Maxillofac Surg* 46:376, 1988
7. Whitaker SB, Waldron CA: Central giant cell lesion of the jaws: A clinical, radiological, and histopathologic study. *Oral Surg Oral Med Oral Pathol* 75:199, 1993
8. Tasanen A, von Konow L, Nordling S: Central giant cell lesion in the mandibular condyle: Report of a case. *Oral Surg Oral Med Oral Pathol* 45:532, 1978
9. Cohen MA, Hertzanu Y: Radiologic features, including those seen with computed tomography, of central giant cell granuloma of the jaws. *Oral Surg Oral Med Oral Pathol* 65:255, 1988
10. Shensa DR, Nasser S: Central giant cell reparative granuloma of the mandibular condyle. *J Oral Surg* 36:642, 1978
11. Chuong R, Kaban LB, Kozakewich H, et al: Central giant cell lesions of the jaws: A clinicopathologic study. *J Oral Maxillofac Surg* 44:708, 1986
12. Bertoni F, Biscaglia R, Bacchini P: Giant cell reparative granuloma of the phalanx of the hand with aggressive radiographic features. *Skeletal Radiol* 27:584, 1998
13. Mercado GV, Shields CL, Gunduz K, et al: Giant cell reparative granuloma of the orbit. *Am J Ophthalmol* 127:485, 1999
14. Ugwonalu O, Eisen RN, Wolfe SW: Repair of a multiply recurrent giant cell reparative granuloma of the hand with wide resection and fibular grafting. *J Hand Surg [Am]* 24:1331, 1999
15. Fechner RE, Fitz-Hugh GS, Pope TL Jr: Extraordinary growth of giant cell reparative granuloma during pregnancy. *Arch Otolaryngol* 110:116, 1984
16. Henry TC: A giant cell reparative granuloma? *Br J Oral Surg* 2:94, 1964
17. Horner K: Central giant cell granuloma of the jaws: A clinicoradiological study. *Clin Radiol* 40:622, 1981
18. Flaggert JJ III, Heldt LU, Gareis FJ: Recurrent giant cell granuloma occurring in the mandible in patients on high dose estrogen therapy for treatment of Soto's syndrome. *J Oral Maxillofac Surg* 45:1074, 1987
19. Kremer C, Millesiw LB, Watzue IM: Local injections of corticosteroids for central giant cell granuloma: A case report. *Int J Oral Maxillofac Surg* 23:366, 1994
20. Harris M: Central giant cell granuloma of the jaws regress with calcitonin therapy. *Br J Oral Maxillofac Surg* 31:89, 1993
21. Flanagan AM, Nui B, Tinkler SM et al; *Cancer* 62[6]:1139-1145, 1988

# Propolis – the natural therapeutic agent in dentistry

\* Sheefa P.A., \*\* Mali G. Nair, \*\*\* Sam Joseph V.G., \*\*\*\* Anulekh Babu

Etymologically, the word *propolis* derives from the Greek *pro* (in front of /at the entrance) and *polis* (community or city) - meaning that this product contributes to hive defence (defender of the city). Propolis is a complex mixture composed of beeswax, resins and plant balsams, aromatic and ethereal oils, pollen and some other organic and mineral compounds. It is a lipophilic material which is hard and brittle when cold, but soft, pliable and sticky when warm - hence the name bee-glye. These compounds are derived from three sources - plant exudates collected by bees, secreted substances from bee metabolism and materials introduced during propolis extraction.

## History

Apitherapy (therapy with bee products like honey, pollen and propolis) is an old tradition that has been revitalized in recent times. The term propolis was coined by Aristotle who identified how propolis was used to protect and defend the hive. Egyptians knew its anti putrefactive properties and used bee glue to embalm their cadavers. Incas employed propolis as an antipyretic agent. Hippocrates, the founder of modern medicine used it for

## Abstract

The use of natural alternatives for conventional dental materials is a viable option considering some of the undesirable characteristics of these materials. Recently, a natural product, propolis (Russian penicillin) was introduced in dentistry as it possesses potent antimicrobial and anti-inflammatory properties. Propolis or bee glue is a natural resinous mixture collected by honey bee (*Apis Mellifera*) from buds, plant exudates and other parts of plants. It is then mixed with wax flakes and saliva, and is used to cover the interior of the hive. Propolis forms the bees' external immune defense system, making the beehive one of the most sterile environments known to nature. It helps to protect against predators, maintains temperature and promotes hygienic conditions. Propolis has antibacterial, antifungal, antiviral, antiprotozoan, antitumor, antiinflammatory, local-anesthetic, antioxidant, immunostimulating, and hepatoprotective properties. The material has shown positive results in wound healing, direct pulp capping and pulpotomy, in the management of dentin hypersensitivity, periodontitis, candidiasis, acute necrotizing ulcerative gingivitis and denture stomatitis. It is also recommended as an intracanal irrigant, mouth rinse, media for storage of avulsed teeth, cariostatic agent and intracanal medicament.

KDJ 2013; Vol. 36, no. 2:142-145

healing sores and ulcers internally and externally. Greek and Roman physicians used it as mouth disinfectant and as an antiseptic agent. Propolis was very popular in Europe between 17<sup>th</sup> and 20<sup>th</sup> centuries because of its antibacterial activities. During World War II, the

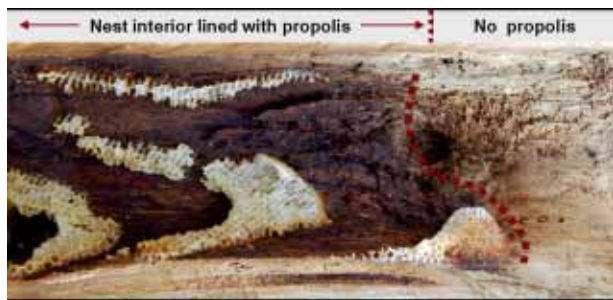
Soviets used it as an antituberculous agent. The first scientific work with propolis reporting its chemical properties and composition was published in 1908 and indexed to *Chemical Abstracts*<sup>1</sup>.

## Chemical composition

Chemical composition of

\* Junior Resident, \*\* Asso. Professor, \*\*\* Professor & HOD, \*\*\*\* Assistant Professor, Dept. of Conservative Dentistry & Endodontics, Govt. Dental College, Thiruvananthapuram. **Corresponding Author: Dr Sheefa P.A.; Email: sheefapa@gmail.com**





A cross-section of a feral honey bee hive within a tree cavity.

propolis is not only complex but also highly variable depending on the season and local flora at the site of collection as well as on the type of bees foraging. In general, raw propolis is composed of around 50% resins, 30% waxes, 10% essential oils, 5% pollen and 5% various other organic compounds. The most important pharmacologically active constituents are flavanoids (flavones, flavonols, flavonones) phenolics, and aromatics. Other important components of propolis include terpanoids, steroids, ketones, dihydro chalcones, caffeic acid, and ferrulic acid. Vitamins B<sub>1</sub>, B<sub>2</sub>, B<sub>6</sub>, vitamin C, vitamin E and minerals containing silver, cesium, mercury, lanthanum, antimony, copper, manganese, iron, calcium, aluminium, vanadium and silicon have been identified in propolis samples<sup>2</sup>. It also contains histamine and serotonin. Propolis from North Argentina has the highest antimicrobial and antioxidant properties correlating with having the highest concentration of flavonoids<sup>3</sup>. In spite of the phytochemical differences, all varieties exhibit significant antibacterial, antiviral and anti fungal properties.

## Extraction of propolis

A crude sample is collected from hives and kept in a deep freezer at -20°C for a few days. The hardened propolis is ground, dissolved in ethanol and then filtered. Ethanol is the most common solvent of choice, but other solvents like water, methanol, chloroform, dichloromethane, ether and acetone can also be used. For obtaining water extract of propolis, raw propolis is mixed with distilled water (1:10 w/v) by means of continuous stirring at room temperature for 48h and a rotary evaporator is employed to get the crude extract.<sup>2</sup>

## Therapeutic uses in dentistry

### 1. Surgical wound repair

As a mouth rinse, propolis was found to promote wound healing. This is primarily due to its anti-

inflammatory effect. Exfoliative cytology has revealed epithelization of infrabuccal surgical wounds<sup>4</sup>. Flavonoids present in propolis are well known plant compounds which have antioxidant, antibacterial, antifungal, antiviral and anti-inflammatory properties which might be responsible for wound healing. Propolis as an anti-inflammatory agent has shown to inhibit synthesis of prostaglandins by inhibiting lipoxygenase pathway of arachidonic acid. It also stimulates various enzyme systems, cell metabolism, circulation and collagen formation. These effects have been shown to be the result of the presence of arginine, vitamin C, provitamin A, vitamin B complex and trace minerals such as copper, iron, zinc as well as bioflavonoids<sup>5</sup>.

Application of Propolis in hydro-alcoholic solution accelerated oral epithelial repair after tooth extraction. Propolis is a pharmacologically safe compound, known to suppress lipid peroxidation and stimulates the activity of antioxidant enzymes<sup>6</sup>: The antioxidants present in propolis play a great role in its immunomodulatory properties. Propolis increases the cellular immune response through the increase of mRNA for interferon- $\gamma$  and activates the production of cytokines. Ferulic acid, quercetin, prenylated compounds, apigenin and also galangin, *p*-coumaric and CAPE (Caffeic acid phenethyl ester) were identified as bioactive compounds responsible for antioxidant potential in different propolis samples<sup>6</sup>.  $\alpha$ -tocopherol is contained in almost all propolis samples and this correlates with its antioxidative effect. These factors help in application of propolis to dental sockets and surgical wounds.

### 2. Root canal irrigant

Antibacterial activity of propolis is due to the presence of flavonoids, aromatic acids and esters present in the resin. In addition, propolis prevents bacterial cell division and breaks down bacterial cell wall and cytoplasm. Propolis tablet dissolved in warm sterile water, when used as root canal irrigant exhibited significant reduction in bacterial growth. Biologic samples taken from the root canals indicated propolis as having antimicrobial activity equivalent to that of sodium hypochlorite<sup>7</sup>. In another study, ethanolic extract of propolis inhibited growth of *Streptococcus* sp., *Escherichia coli*, *P.aeruginosa*, *B.subtilis* and *S.epidermidis*. It also potentiates the effect of certain antibiotics<sup>8</sup>.

### 3. Direct pulp capping

As a direct capping agent, propolis formed a protective film at the site of pulp exposure and there

was no evidence of pulpal degeneration in the rest of the pulpal tissue. Hence the material may be more histophilic than the pastes based on calcium hydroxide, where an area of necrosis occurred at the opening of the chamber, and fibrous degeneration occurred in the coronal pulp. Flavonoids and caffeic acid present in propolis are known to play an important role in reducing the inflammatory response by inhibiting the lipoxygenase pathway of arachidonic acid. Flavonoids and caffeic acid also aid the immune system by promoting phagocytic activities and stimulating cellular immunity. The stimulation of various enzyme systems, cell metabolism, circulation and collagen formation could contribute to the hard tissue bridge formation by propolis. These effects have been shown to be the result of the presence of arginine, vitamin C, provitamin A, vitamin B complex and trace minerals such as copper, iron, zinc as well as bioflavonoids. All these factors assist in faster healing of the wound. Dentin formation following pulp capping is known to involve differentiation of odontoblast-like cells forming reparative dentin and biosynthesis activity of surrounding primary odontoblasts; phenomena that require interaction between extracellular matrix molecules and growth factors such as TGF- $\beta$ 1. Propolis is capable of stimulating the production of TGF- $\beta$ 1, a growth factor known to be important for odontoblast-like cell differentiation, and the synthesis of collagen by dental pulp cells<sup>5</sup>.

#### 4. Storage media for avulsed teeth

Propolis may be a better alternative to HBSS, milk, or saline as a storage medium in terms of maintaining PDL cell viability after avulsion<sup>9</sup>. The cell viability after propolis treatment was analyzed by crystal violet staining of the cells followed by spectrophotometric analysis. Data revealed that exposure of PDL cells or pulp fibroblasts to 4 mg/ml or lower concentrations of propolis resulted in > 75% viability of cells<sup>10</sup>. Propolis can hence be recommended as a suitable transport medium for avulsed teeth.

#### 5. Treatment of dentin hyper sensitivity

Propolis occluded the dentinal tubules in both 60 and 120 seconds application. 10% Propolis gel when applied on dentin, showed more homogeneous dentin surface due to two actions; one obliterates dentin tubules and another because of formation of superficial deposits on dentin<sup>11</sup>.

#### 6. Treatment of periodontitis

An experimental mouthrinse containing propolis was efficient in reducing supragingival plaque formation

and insoluble plaque formation under conditions of high plaque accumulation<sup>12</sup>. When propolis was irrigated in certain periodontal pockets once a week for five weeks, a 95% decline in gingivitis was appreciated. Because propolis is cheap and accessible to the population, its effectiveness in treating periodontal disease is extremely relevant to public health. Propolis exerts viricidal action on enveloped viruses like herpes simplex and vesicular stomatitis viruses. Flavonoids and aromatic acids derivatives are responsible for the antiviral activity of propolis extracts. Some flavonoids (baicalin) have inhibitory effect on HIV infection and replication as showed by *in vitro* studies. Although antibacterial activity is more relevant than the antifungal properties of propolis, many studies have reported the susceptibility of clinically important yeasts belonging to *Candida* genera such as *Candida albicans* as well as the sensitivity of some filamentous fungi, mainly dermatophytes to propolis. The fungicidal effect was associated with the presence of flavonoids and other phenolic components. Differences in antifungal activity of propolis extracts can be attributed to the differences in chemical composition and concentration of propolis. Synergistic effect with conventional antimycotic drugs was also observed. Hence propolis can be a medicament of choice in treating denture stomatitis and oral candidiasis<sup>13</sup>.

#### 7. Intracanal medicament

Propolis is biocompatible and its antimicrobial action against endodontic pathogens increases its potential indication in dentistry as an intracanal medicament. The combined use of propolis and calcium hydroxide could aggregate the benefits of each medicament<sup>14</sup>. A combination of propolis and propylene glycol has yielded favorable results in periapical healing. Propylene glycol was used as vehicle because of its sustained release effect<sup>15</sup>. Bee glue when added with 4% alcohol solution can be used as an obturating material. It does not stain the tooth crown, promotes regeneration of the bone structure and prolongs the effect of 0.4% water-alcohol bee glue emulsion. In future, propolis may be used as a viable root filling material.

#### 8. As cariostatic agent

Hayacibara et al. (2005) evaluated the influence of propolis on viability of *S. mutans*, glucosyltransferases (GTFs) activity and caries development in rats. The data suggested its potential use as novel anti-caries agent. Several investigations carried out with propolis showed reduction in *S. mutans* count, interference with their adhesion capacity and glucosyl transferase activity

which are considered major properties in establishment of dental caries. Data from *in vivo* studies have demonstrated reduction in *S. mutans* count in saliva, plaque index, and insoluble polysaccharide formation. These findings indicate that propolis and its compounds are promising cariostatic agents. Water insoluble glycan synthesis was also inhibited. Propolis extract as mouthrinse possesses antimicrobial activity against *S. mutans* present in the oral cavity and can be used as an alternative measure to prevent dental caries<sup>16</sup>.

### Conclusion

Propolis as an alternative to conventional dental materials and medicaments holds immense potential to be developed, according to the requirements and specifications of treatment methods. With its wide range of clinical applications in dentistry, it will definitely be a valuable addition to every clinician's armamentarium in coming times. Nonuniformity in the chemical composition, due to its geographical distribution is a significant drawback to its routine use. Thus further studies in this area can help to establish propolis - a natural product - as one of the primary dental materials of choice.

### Reference

1. Helfenberg, K.D. Chemiker Zeitung. 1908; 31, 987.
2. Marcucci M. Propolis: chemical composition, biological properties and therapeutic activity. Apidologie 1995; 26:83-99.
3. Isla MI et al. Some chemical composition and biological activity of Northern Argentine propolis. Journal of Agricultural and Food Chemistry. 2005; 53:1166-1172.
4. Margo-Filho O and de Carvalho AC. Topical effect of Propolis in the repair of sulcoplasties by the modified Kazanjian techniques. Cytological and clinical evaluation. J Nihon Univ Sch Dent 1994; 36:102-11
5. Parolia A, Kundabala M, (2010). A comparative histologic analysis of human pulp following direct pulp capping with Propolis, MTA, and Dycal. Aust dentJ; 59-64
6. Yagmurca M et al 2004, Caffeic acid phenethyl ester as a protective agent against doxorubicin nephrotoxicity in rats, Clin Chim Acta, 348, 27-34.
7. Al-Qathami H, Al-Madi E (2003). Comparison of sodium hypochlorite, propolis and saline as root canal irrigants: A pilot study. Saudi Dental J., 5: 100-102.
8. Silici S, Kutluca S. Chemical composition and antibacterial activity of propolis collected by three different races of honeybees in the same region. Journal of Ethnopharmacology. 2005; 99:69–73.
9. Payal Saxena et al Potential of the propolis as storage medium to preserve the viability of cultured human periodontal ligament cells: An *in vitro* study Dental Traumatology 2011; 27: 102–108
10. Al-Shaher A, WJ, Agarwal S, Bretz W, Baugh D. Effect of propolis on human fibroblasts from the pulp and periodontal ligament. J Endod 2004;30(5):359-61.
11. Silvia Helena de Carvalho Sales-peres et al Effect of propolis gel on the *in vitro* reduction of dentin permeability J Appl Oral Sci 2010 ; 318-323
12. Koo H et al. Effect of a mouthrinse containing selected propolis on 3-day dental plaque accumulation and polysaccharide formation. Caries Res. 2002 Nov-Dec;36(6):445-8.
13. V.R. Santos. Oral candidiasis treatment with Brazilian ethanol propolis extract. Phytotherapy Research 2005; 19:652-654.
14. Lama Awawdeh, Maha AL-Beitawi, and Mohammad Hammad Effectiveness of propolis and calcium hydroxide as a short-term intracanal medicament against Enterococcus faecalis: A laboratory study, Aust Endod J 2009; 35: 52–58
15. G P Rezende, L R Costa, F C Pimenta, D A Baroni *In vitro* Antimicrobial Activity of Endodontic Pastes with Propolis Extracts and Calcium Hydroxide: A Preliminary Study. Braz Dent J 2008;19(4): 301-305.
16. Hayacibara MF, Koo H, Rosalen PL *et al.* *In vitro* and *in vivo* effects of isolated fractions of Brazilian propolis on caries development. J Ethnopharmacol 2005; 101: 110–15.

# Prosthodontic rehabilitation of the patient with acquired maxillo-mandibular defect

\* C. Dhinesh Kumar, \*\* Vidya Zankari, \*\*\* Sudesna Harichandan, \*\*\* G. Yuvaraja

## Introduction

Maxillofacial Prosthodontia is the art and science of functional or cosmetic reconstruction by means of non-living substitutes for those regions of maxilla, mandible and the face that are missing or defective because of surgical intervention, trauma, pathology or developmental or congenital malformations.<sup>1</sup> The design of the maxillofacial prosthesis was diligently carried out with central and critical emphasis on prosthodontic principles such as the creation of lip seal, elimination of deviation of the mandible in function, prevention of seepage of food and fluids from oral to nasal cavity and establishment of facial symmetry.

## Case report

A 45 year old male patient reported to the college with the chief complaint of deviation of mandible to the right side and inability to have food due to leakage into the nasal cavity (Fig 1). He had history of hemimaxillectomy (Aramany classification - Class II defect) and hemimandibulectomy (Cantor and Curtis classification Class II-modification b defect) on right side because of surgical resection carried out due to squamous cell carcinoma about a year ago<sup>2</sup> (Fig 2). On clinical examination there was facial asymmetry, drooling of saliva from angle of mouth, deviation of mandible to right side

## Abstract

Surgical and Prosthodontic rehabilitation of the patient with maxillofacial defects has the potential of being extremely gratifying to the clinician and also makes an enormous impact on the quality of life for the patient. Proper diagnosis and treatment planning will make the final outcome of the treatment more functionally and esthetically satisfactory to the patient. This case report describes functional and esthetic rehabilitation of patient with acquired maxillary and mandibular defects using obturator and mandibular guiding flange prosthesis.

**Key words-** guiding flange, hemimandibulectomy, obturator, removable partial denture, segmental resection.

KDJ 2013; Vol. 36, no. 2:146-148

on attempt to open the mouth, moderate defect on right side maxilla and mandible (behind first molar region), unesthetic appearance. Both maxilla and mandible are partially edentulous - Kennedy's Class II partially edentulous condition. Radiographic evaluation shows that part of right side maxilla and mandible from first premolar including condyle has been resected (Fig 3).

## Prosthetic rehabilitation

After achieving proper diagnosis and treatment plan, the preliminary impressions were taken with irreversible hydrocolloid material for both the maxillary and mandibular arches and primary casts were made. Custom trays were constructed using the primary cast. The final impression for both the arches was made with polyvinyl

siloxane impression material (Fig 4). Then the master casts were made and duplicated in reversible hydrocolloid material to make working casts for fabricating the permanent denture bases.

From the working casts the wax up of permanent denture bases for both the arches was completed. The clasps for retention were made and get attached to the maxillary and mandibular denture bases (fig 5). The denture bases were processed with heat cure acrylic. The maxillary permanent denture base with obturator made with adequate extension into the defect. The patient was instructed and the mandible was guided into the normal centric occlusion with maximum intercuspation. Bite registration was done and the casts were articulated in same relation.

To correct the deviation of

\* Senior Lecturer, \*\* Reader, \*\*\* PG student, Department of Prosthodontics, Vinayaka Missions Sankarachariyar Dental College, Salem - Tamil Nadu. **Corresponding Author: C. Dhinesh Kumar; Email: cdhineshkumar\_bds@yahoo.com**





Fig. 1 Patient profile

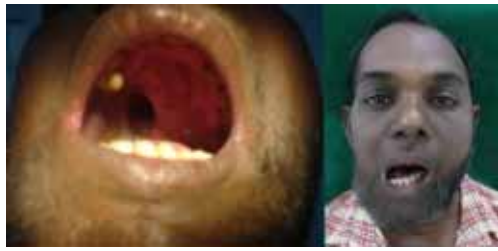

Fig. 2 Intra-oral defect

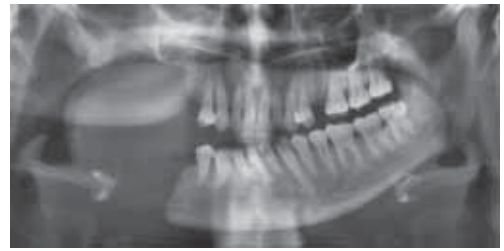

Fig. 3 OPG

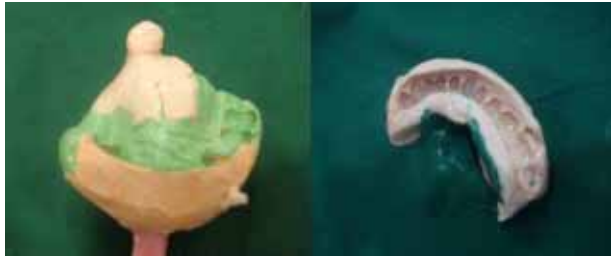


Fig. 4 Final impression

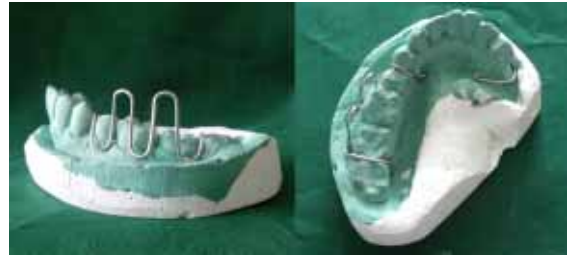

Fig. 5 Cast with wire loops

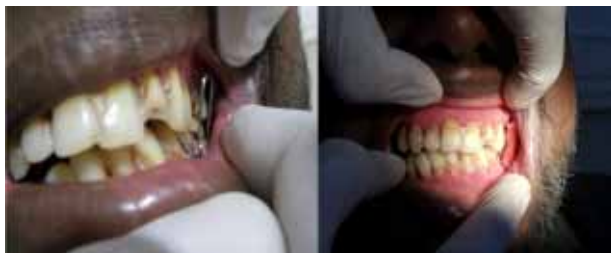

Fig. 6 Wire loop with wax up in patient mouth

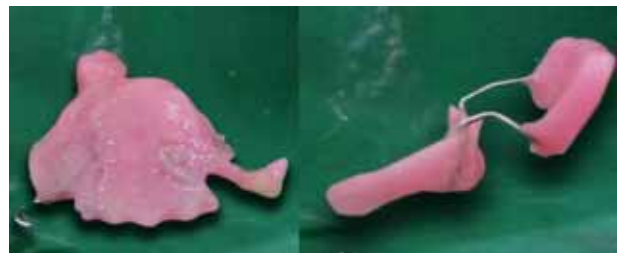

Fig. 7 Finished prosthesis

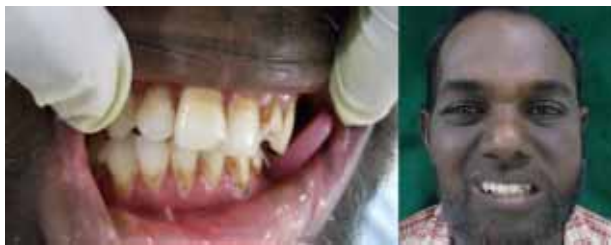

Fig. 8 Post operative

mandible and to guide into the existing centric occlusion, a wire loop was made to support the wax up of the buccal flange extending into the left buccal vestibule and get attached to the mandibular denture base with autopolymerising acrylic resin. Wax up of buccal flange was done so that when placed into the patient mouth it prevents the deviation towards left side on opening the mouth and guides the mandible to right side by engaging the left side maxillary teeth (Fig 6).<sup>3,4</sup> The esthetics of the patient was improved and finally verified. The facial asymmetry becomes less apparent. There was no leakage of fluids into the nasal cavity on wearing the maxillary prosthesis with obturator. The wax up was then completed for mandibular guiding flange and maxillary prosthesis with

obturator portion. Final processing was done with heat cure acrylic. The maxillary and mandibular prosthesis was then finished, polished and delivered to the patient (Fig 7,8). The patient was then instructed about wearing of the prostheses and instructed for review for every four weeks.

## Discussion

Hemimaxillectomy defects creates opening into the nasal cavity there by resulting in leakage of fluids from oral to nasal cavity, inability to swallow the food, collapse of facial musculature and change in resonance of voice. The hemimandibulectomy defect results in facial asymmetry, unesthetic appearance, loss of lip seal and deviation of mandible towards the unaffected side. The mandibular deviation occurs due to pull of the muscles of mastication and facial expression towards unaffected side that gets exaggerated on attempting to open the mouth.<sup>6</sup> In the present case report a variation of standard prosthodontic procedures has been described that resulted in an advanced esthetic and functional outcome of the patient.<sup>5</sup> There was no space to set the artificial teeth so that the maxillary and mandibular

prostheses were just fabricated for two primary purposes to prevent the leakage of fluids into the nasal cavity from oral cavity and to correct the mandibular deviation. The patient was instructed to hold the citrus fluid in the mouth and the maxillary occlusal rim was moulded until there was no leakage into the nasal cavity. The mandibular occlusal rim was shaped to restrict the soft tissue from collapsing during the opening of mouth towards the side of the pull and effectively masked the clinical deviation.

On follow up the patient reported with a little discomfort on placement of the prosthesis which was considerably reduced on subsequent visits. After four weeks the patient was able to masticate and swallow satisfactorily. Patient was advised for soft diets, oral hygiene maintenance and educated for the maintenance of the prosthesis.

## Summary

In this case report, both the maxillary and mandibular prostheses becomes an appliance because no missing teeth are supplied. A final prosthesis was fabricated to fulfil the goals within physiological limits and a welcome addition was the psychological boost to the patient to face the world with a better smile.

## Conclusion

A proper diagnosis, step by step treatment planning and good communication with the patient helps us to better appreciate their treatment needs and achieve an acceptable and satisfactory result in patients with maxillofacial defects. There will be change in the surgical environment as healing progresses and patient efforts to train movement during this healing period will help to maintain the position and the movement range. Over a period of time this guided function should promote scar relaxation, allowing the patient to make unassisted masticatory movements.

## References:

- 1) Thomas.D.Taylor - Textbook of Clinical Maxillofacial Prosthetics-2000 edition.
- 2) Kratchovil FT; Lateral discontinuity defects –Partial denture design; maxillofacial rehabilitation, St Louis 1979.
- 3) Adisman IK, Birnbach S: Surgical prosthesis for reconstructive mandibular surgery. J Prosthet Dent 1966; 16; 98.
- 4) Chalian VA et al; Maxillofacial Prosthetics: Multidisciplinary Practice. Baltimore 1972.
- 5) Robinson JE; The use of a guide plane for maintaining a residual fragment in hemimandibulectomy. J Prosthet dent 1964; 14; 922.
- 6) Atkinson HF-Masticatory movements of patients after major oral surgery. J Prosthet Dent-1969; 21; 175.

## INFORMATION FOR AUTHORS

## Kerala Dental Journal



### GUIDELINES

**Manuscripts:** Articles should be type written on one side of A4 size (21x28cm) White paper in double spacing with a sufficient margin. One Original and two high quality photocopies copies should be submitted. The author's name is to be written only on the original copy and not on the two photocopies copies. **In addition to the printed version, a CD containing the article file also should be submitted compulsorily.** Use a clear and concise reporting style. KDJ reserves the right to edit, manuscript, to accommodate space and style requirements. Authors are advised to retain a copy for the reference.

**Title Page:** Title page should include the title of the article and the name, degrees, positions, professional affiliations of each author. The corresponding authors, telephone, e-mail address, fax and complete mailing address must be given.

**Abstract:** An abstract of the article not exceeding 200 words should be included with abbreviated title for the page head use. Abstract should state the purpose of the study, investigations, basic procedures and the main findings.

**Tables:** Tables should be self explanatory, numbered in roman numbers, according to the order in the text and type on separate sheets of paper like legends for illustrations.

**Illustrations:** Illustrations should be clearly numbered and legends should be typed on a separate sheet of paper, while each figure should be referred to the text. Good black and white glossy photographs or drawings drawn in black Indian ink on drawing paper should be provided. **Colour photographs will be published as per availability of funds. It will incur printing cost. Otherwise the cost of printing will be at the expense of authors and charges will be advanced by KDJ at the time of receipt of accepted manuscripts.** Photographs of X-rays should be sent and not the original X-rays. Prints should be clear and glossy. On the back of each print in the upper right corner, write lightly the figure number and author's name; indicate top of the photograph with an arrow of word 'Top' Slides and X-ray photographs should be identified similarly.

**Photographs:- Author's photograph - Stamp size, Black and White, glossy photographs should be sent along with the article.**

**Reference:** Reference should be selective and keyed in numerical order to the text in Vancouver Style (not alphabetical). Type them double spaced on a separate sheet of paper. Journal references must include author's names, article title, journal name, volume number, page number and year. Book reference must include author's or editor's names,

chapter title, book title, edition number, publisher, year and page numbers.

**Copyright:** Submission of manuscripts implied that the work described has and not been published before (except in the form of an abstract or as part of published lectures, review or thesis) and it is not under consideration for publication else where, and if accepted, it will not be published else where in the same form, in either the same or another language without the comment of copyright holders. The copyright covers the exclusive rights of reproduction and distribution, photographic reprints, video cassettes and such other similar things. The views/opinions expressed by the authors are their own. The journal bears no responsibility what so ever.

The editors and publishers can accept no legal responsibility for any errors, omissions or opinions expressed by authors. The publisher makes no warranty, for expression implied with respect to the material contained therein. The journal is edited and published under the directions of the editorial board who reserve the right to reject any material without giving explanations. All communications should be addressed to the Editor. No responsibility will be taken for undelivered issues due to circumstances beyond the control of the publishers.

**Books for review:** Books and monographs will be reviewed based on their relevance to KDJ readers. Books should be sent to the Editor and will become property of KDJ.

**Return of articles:** Unaccepted articles will be returned to the authors only if sufficient postage is enclosed with the manuscripts.

**Subscription Rates:** Free distribution for all the members of the Indian Dental Association Kerala State.

**Inland Subscription:** Rs. 400 per issue, Rs. 1500 for 1 Year, Rs. 2500 for 2 years, Rs. 3500 for 3 years.

**For on-line Submission of articles: visit [www.idakerala.com](http://www.idakerala.com)**

*All correspondence may please be send to the following address :*

Dr. K. Nandakumar,

Hon. Editor, Kerala Dental Journal

Neelambikam, Attukal, Manacaud, Trivandrum - 695 009

Phone: 0471-2459235 / Cell: 09447066100

e-mail: [editorkdj@gmail.com](mailto:editorkdj@gmail.com)

# Management of an unerupted permanent maxillary incisor

\* Sheela Sreedharan, \*\* Alice Lyngdoh, \*\*\* Kavita Kumar Krishnan

## Abstract

Impaction of maxillary central incisors is frequent in dental practice. However its management is challenging because of its importance in aesthetics. Supernumerary teeth are the most common dental anomaly that can cause impaction of adjacent teeth, crowding, diastema, rotation and displacement of teeth. The present paper reports the successful management of an unerupted central incisor which is complicated by the presence of a supernumerary tooth. Treatment planning with a combination of Surgical extraction of the supernumerary tooth followed by orthodontically force eruption of the impacted left maxillary central incisor and alignment of the rotated central incisor with removable orthodontic appliance.

**Key words:** impacted central incisor, supernumerary tooth, surgical exposure.

KDJ 2013; Vol. 36, no. 2:149-150

## Introduction

Missing and unerupted maxillary incisors can have a major impact on dental and facial aesthetics and were considered to be the most unattractive deviant occlusal trait<sup>1</sup>. Missing upper incisors can also have a psychological impact on a child because of its unattractiveness. There are two approaches in Orthodontically forced eruption<sup>2</sup>:

1. Open eruption by raising a flap and leaving an open window to the tooth to allow traction or eruption.

2. Closed eruptions by doing a flap, installing attachment

components for orthodontically forced eruption, and then closing the flap.

## Case report

A healthy, 9 years old boy was referred to the Department of Pedodontics, Government Dental College, Thiruvananthapuram with the complaint of a unusually erupting tooth in the upper front region. Clinical examination showed presence of a malformed tooth in 21 region (fig. 1). The teeth present were

16, 55, 54,53,12,11 63,64,65,26  
46, 85,84,83,42, 41 31, 32,73,74,75

Intraoral Maxillary Occlusal radiograph showed that the erupting tooth was a supernumerary tooth in region of 21 obstructing the eruption of 21 which was tilted mesially (Fig. 2).

It was decided to extract the supernumerary tooth and an informed consent was obtained after explanation of the treatment procedure to the parent. The supernumerary tooth was extracted under local anaesthesia. On recall after 1 month, it was observed that 22 had erupted and no signs of eruption of 21. Intraoral periapical radiograph revealed an ectopic path of eruption of 21. Orthodontically forced eruption was undertaken with a removable orthodontic appliance to facilitate eruption of 21 (fig. 3) and the malposed erupted 21 was corrected in the second stage using a Hawley's removable appliance incorporated with a Z spring on 21, jack screw for anterior expansion and posterior bite plane. A stable occlusion was achieved with 21 in normal aligned and normal overjet (fig. 4).

## Discussion

The presence of supernumerary tooth is one of the most common causes for failure of eruption of maxillary central

\* Professor and Head, \*\* Post Graduate Student, Dept. of Pedodontics & Preventive Dentistry, Govt. Dental College, Thiruvananthapuram; \*\*\* Senior Lecturer, Dept. of Pedodontics & Preventive Dentistry, St. Grogorious Dental College, Kothamangalam  
**Corresponding Author: Dr Alice Lyngdoh, Email: alicelyngdoh@gmail.com**



Fig.1  
Preoperative  
view of  
impacted Left  
central incisor

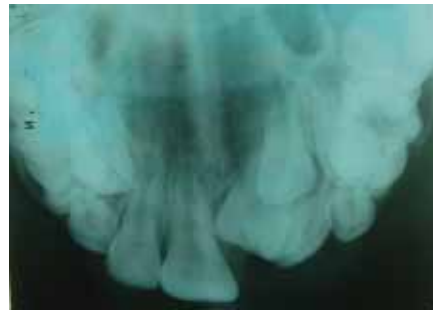
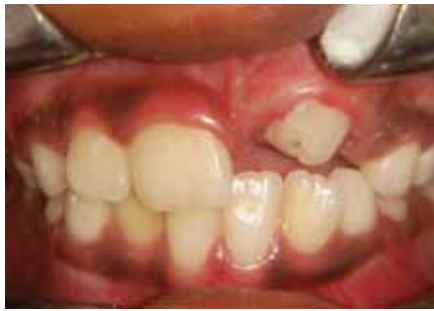

Fig. 2  
Maxillary  
occlusal X ray  
showing  
Supernumerary  
tooth.

Fig. 3  
Bracket  
placement and  
attachment of  
elastic for  
orthodontic  
traction.

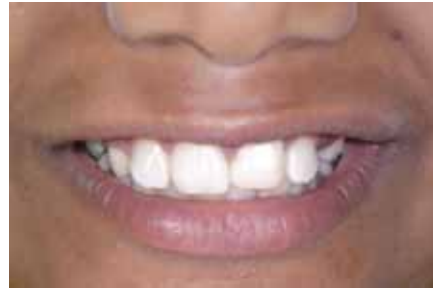
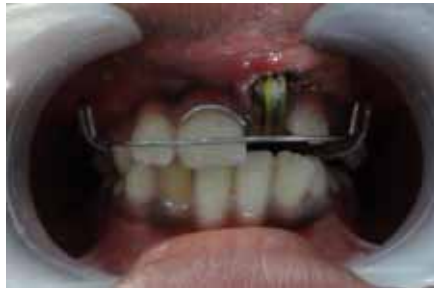
Fig. 4  
Postoperative  
view.

incisors. There are various other problems that may be associated with supernumerary teeth like crowding, displacement of permanent teeth and cystic formation. In order to avoid pathologies relating to supernumerary teeth it is always suggestive that supernumerary teeth should be extracted<sup>3</sup>. The literature reports that 80% to 90% of all supernumerary teeth occur in the maxilla. The greatest proportion are found in the maxillary anterior region<sup>4</sup>. Failure of eruption of permanent incisors due to supernumerary teeth have been reported variably at 28 % and 38%<sup>5,6</sup>. Tuberculate supernumerary teeth are more likely to cause an obstruction than conical supernumerary teeth<sup>7</sup>. The technique to be used during forced eruption should be based on the angulations, degree of impaction, root completion and other local factors<sup>8</sup>. These factors were considered during treatment planning of the case. Closed eruption surgical technique was not used for this case. Circular excision of the overlying mucosa immediately over the impacted central incisor was done as suggested by Becker A in 1998<sup>9</sup>.

Epithelial attachment of the impacted central incisor should be retained as possible in order to obtain normal contour of gingiva and attached gingiva.

### Conclusion

Impaction of maxillary anterior teeth can be a challenging orthodontic problem. Treatment of

impacted teeth varies widely depending on the state of the impacted tooth, the degree of impaction and its position. Every case should be analyzed individually to develop the proper treatment plan. Multidisciplinary team approach should be utilized to ensure successful outcome of the treatment.

### References

1. Cons NC, Jenny J, Kohout FJ. *DAI: the dental aesthetic index*. Iowa: College of Dentistry, University of Iowa; 1986.
2. Hyo-Sang Park, Oh-Won Kwon, Jae-Hyun Sung. Micro-Implant Anchorage for forced Eruption of Impacted Canines. *J Clin Ortho*. 2004; Vol. XXXVIII, No. 5:297-300.
3. Becker A. Early treatment for impacted maxillary incisors. *Am J Orthod Dentofacial Orthop*. 2002;121:586-587.
4. Primosch RE. Anterior supernumerary teeth — assessment and surgical intervention in children. *Pediatr Dent* 1981; 3(2):204-15.
5. Leyland L, Batra P, Wong F, Llewelyn R. A retrospective evaluation of the eruption of impacted permanent incisors after extraction of supernumerary teeth. *J Clin Pediat Dent* 2006; 30: 225-31.
6. Betts A, Camilleri G. A review of 47 cases of unerupted maxillary incisors. *Int J Paediatr Dent* 1999; 9: 285-92.
7. Foster TD, Taylor GS. Characteristics of supernumerary teeth in the upper central incisor region. *Dent Pract Dent Rec* 1969; 20: 8-12.
8. Chaushu S, Becker A, Zeltser R, Branski S, Vasker N, Chaushu G. Patients perception of recovery after exposure of impacted teeth: A comparison of closed-versus open-eruption techniques. *J Oral Maxillofacial Surg*. 2005; 63:323-9.
9. Becker A. *The orthodontic treatment of impacted teeth*. Martin Dunitz: London, 1998.



# Aneurysmal bone cyst of mandible

\* Admaja K. Nair, \* Priyanka, \*\* Girja K.L., \*\*\* Valsa Thomas

## Abstract

Aneurysmal bone cyst (ABC) is a rare non neoplastic expansile osteolytic bone lesion of unknown etiology, most commonly affecting the metaphysis-epiphyseal areas of long bones or vertebrae with eccentric expansion. It usually occurs in the first two decades of life. They are infrequent in craniofacial skeleton. Early diagnosis is important because of the characteristic rapid growth pattern with resultant bony expansion and facial asymmetry. A case of ABC affecting the body of the mandible with rapid expansion in a child patient is described here.

**Keywords:** Aneurysmal bone cyst, mandible

KDJ 2013; Vol. 36, no. 2:151-153

## Introduction

An aneurysmal bone cyst (ABC) is a benign expansile tumour like bone lesion of uncertain aetiology, composed of numerous blood filled channels.<sup>1</sup> It is primarily seen in children and adolescents, with 80% occurring in the patients less than 20 years of age. Patients may present with pain (which may be of insidious onset or abrupt due to pathological fracture), with a palpable swelling or with restricted movement. Historically, ABCs have been considered as nonneoplastic cystic masses that have been divided into primary and secondary (histologically indistinguishable) types. It can be a primary bone lesion or a secondary lesion arising from other osseous conditions. It accounts for 1.5% of the nonodontogenic, nonepithelial cysts of the mandible. It is found more

frequently in the mandible than the maxilla (3:1) with preponderance for the body, ramus and angle of the mandible. It affects young persons under 20 years of age with no gender predilection.<sup>2</sup> Owing to varied radiologic features and its often rapid growth, the clinical differential diagnosis, in addition to ABC, most commonly includes malignant processes such as osteosarcoma and metastases. Because ABC has essentially no metastatic potential, distinction between these entities is of paramount importance.

## Case report

An 11-year old female patient reported to the Department of Oral Medicine and Radiology with a complaint of an asymptomatic swelling in the left side lower jaw since 1 month, which had gradually

increased to the present size. Her medical and family history was unremarkable and there was no history of trauma. All milestones of development were normal for her age. On extra oral examination, facial asymmetry was apparent with a diffuse swelling on the left side body region of the mandible to symphysis slightly crossing the midline. The swelling was hard and non tender. Intraoral examination revealed a well defined swelling in relation to unerupted 35 region to 41 region, measuring approximately 5×3×3 cms. There was expansion of buccal cortical plate and a cystic area was palpable in relation to 33 region buccally (Fig. 1). Electrical pulp testing showed that the involved teeth were vital. Aspiration from the lesion yielded 2ml thin blood coloured fluid. Mandibular occlusal radiograph showed expansion of the buccal cortical plates with altered trabecular pattern and thin trabeculae radiating buccally (Fig. 2). Panoramic radiograph revealed a large well defined multilocular radiolucency, extending from 35 to 43 region. Root resorption was seen on 33 and 34. There was thinning but no discontinuity of the lower border of the mandible (Fig.3). Computed tomographic examination was performed which revealed a well-circumscribed bony expansile multilocular lytic lesion in the body of mandible measuring 6×3×3 cm in size, with moderate

\* Post Graduate Student, \*\* Assistant Professor, \*\*\* Professor and Head, Department of Oral Medicine and Radiology, Govt. Dental College, Thiruvananthapuram. **Corresponding Author: Dr Admaja K Nair; Email: admajaknair@gmail.com**

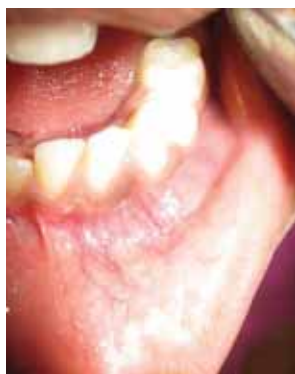

Fig. 1 Swelling involving left body region mandible

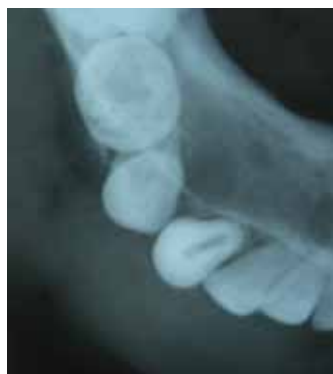

Fig. 2 Occlusal view mandible showing cortical expansion and buccally radiating trabeculae

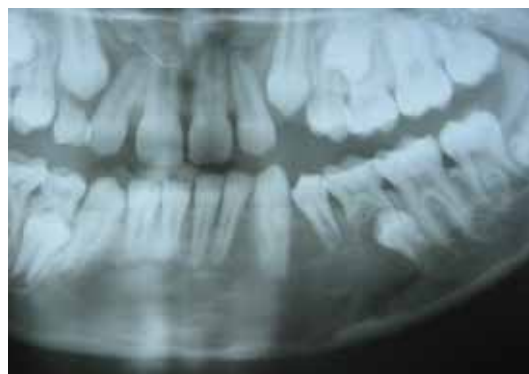

Fig. 3 Cropped panoramic view Multilocular radiolucency involving left mandibular body and symphysis

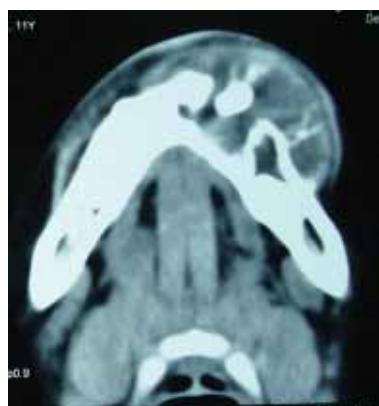

Fig. 4 Axial CT sections showing expansile lytic lesion with moderate contrast enhancement

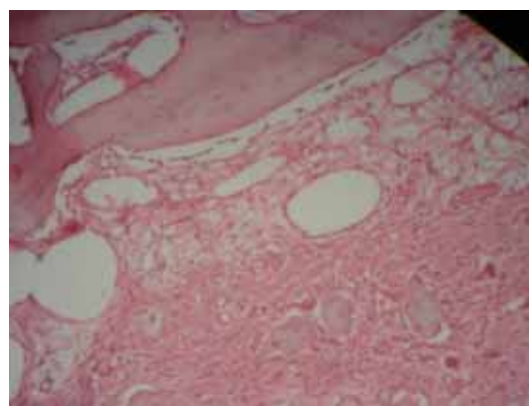


Fig. 5 Histopathologic appearance of aneurysmal bone cyst

contrast enhancement (Fig. 4). Provisional diagnosis of ameloblastoma or aneurysmal bone cyst was made. Histopathological examination following incisional biopsy was suggestive of aneurysmal bone cyst (Fig.5). Surgical excision of the lesion was done which confirmed the diagnosis.

## Discussion

Aneurysmal bone cysts are non-neoplastic, highly vascular, eccentric, osteolytic lesion of unknown origin that may present difficult therapeutic problems. The term was derived from the typical “blow-out” effect or expansion of the affected bone that appears in these types of lesions and it is considered as a pseudocyst of jaws as it lacks an epithelial lining.<sup>3</sup> It comprises 5% of all the lesions of the cranial and maxillofacial bone<sup>4</sup> and is most common in those regions of the skeleton where there is both a relatively high venous and marrow content. It can be a primary lesion or a secondary lesion arising from other osseous conditions.<sup>5</sup> Some have identified trauma as an etiological factor<sup>6</sup>

but in many instances no traumatic history can be elicited, like in this case. Primary could be congenital or acquired and could originate from pre-existing arterio venous malformations. The congenital type is seen in children and young adults with no history of trauma, whereas the acquired type is found in adults with a history of trauma. The secondary type is postulated to be associated with degeneration of pre-existing lesions such as a cyst, tumour or fibrous lesion. The two lesions could exist independently. Hence, ABC is considered as nonneoplastic, fibro dysplastic, noncystic bone entity.<sup>7</sup> In the present case as no history of trauma was reported, the etiology could be either due to alterations in local hemodynamics or degeneration of any pre-existing lesion at the involved site. Familial incidence of ABC has also been reported in literature. They are typically eccentrically located in the metaphysis of long bones. Although they have been described in most bones, the most common locations are long bones, spine, sacrum and are infrequent in the cranio facial skeleton. An

unusual location for ABC, i.e., mandibular condyle and coronoid process has also been reported.<sup>8</sup> ABC is extremely variable in clinical presentation, ranging from a small, indolent, asymptomatic lesion to rapidly growing, expansile, destructive lesion causing pain, swelling, deformity, neurologic symptoms pathologic fracture and perforation of the cortex.<sup>4</sup> The radiological features of ABC can be either an expanding lesion or appears cystic resembling a honeycomb or soap bubble and is eccentrically ballooned. There may be destruction or perforation of the cortex and a periosteal reaction may be evident.<sup>9</sup> It may appear radiolucent, radiopaque or mixed. In our case, a multilocular radiolucency causing expansion of the buccal cortical plates and thinning of the lower border of the mandible with root resorption of the involved teeth was present. There was also radiating trabeculae towards the buccal aspect. It is important to differentiate the ABC from other pathologies that occur in the maxillofacial region. Fibrous dysplasia is one of the many bone lesions associated with the development of a secondary aneurysmal bone cyst. The other primary lesions include solitary or unicameral bone cyst, osteoclastomas, osteosarcoma, non osteogenic fibroma, osteoblastoma, hemangioendothelioma and hemangioma of bone.

Histologically, ABC consists of many sinusoidal blood-filled spaces set in a fibrous stroma, with multinucleated giant cells and osteoid. Hemosiderin is present in variable amounts and there is evidence of osteoid and bone formation.<sup>2</sup> Treatment of ABC is usually directed toward complete removal of the lesion. The treatment modalities are percutaneous sclerotherapy, diagnostic and therapeutic embolization, curettage, block resection and reconstruction, radiotherapy and systemic calcitonin therapy.<sup>10</sup> Self-healing cases have also been reported on long-term follow-up.<sup>11</sup>

## Conclusion

Owing to the varied radiologic features and its often rapid growth, the clinical differential diagnosis, in addition to ABC, most commonly includes malignant processes such as osteosarcoma and metastases. Because ABC has essentially no metastatic potential, distinction between these entities is of paramount importance.

## References

1. Motamedi MH, Yazdi E (1994) Aneurysmal bone cyst of the jaws: analysis of 11 cases. *J Oral Maxillofac Surg* 52, 471-475.
2. Capote Moreno A, Acero J, García-Recuero I, Ruiz J, Serran R, de Paz V. Giant aneurysmal bone cyst of the mandible with unusual presentation. *Med Oral Pathol Oral Cir Bucal*. 2009 Mar 1;14 (3):E137-40.
3. Rapidis AD, Vallianatou D, Apostolidis C, Lagogiannis G. Large lytic lesion of the ascending ramus, the condyle, and the infratemporal region. *J Oral Maxillofac Surg*. 2004;62:996-1001.
4. Kalantar Motamedi MH. Aneurysmal bone cyst of the jaws: Clinicopathological features, radiographic evaluation and treatment analysis of 17 cases. *J Craniomaxillofac Surg* 1998;26:56-62.
5. Jaffe HL, Lichtenstein L (1942) Solitary unicameral bone cyst with emphasis on the roentgen picture, the pathologic appearance and the pathogenesis. *Arch Surg* 44, 1004-1025.
6. Struthers PJ, Shear M. Aneurysmal bone cyst of the jaws. (I). Clinicopathological features. *Int J Oral Surg*. 1984;13:85-91.
7. Eisenbud L, Attie J, Garlick J, Platt N. Aneurysmal bone cyst of the mandible. *Oral Surg Oral Med Oral Pathol* 1987;64:202-6.
8. Martins WD, Fávoro DM. Aneurysmal bone cyst of the coronoid process of the mandible: A case report. *J Contemp Dent Pract* 2005;6:130-8.
9. Kiattavorncharoen S, Joos U, Brinkschmidt C, Werkmeister R. Aneurysmal bone cyst of the mandible: A case report. *Int J Oral Maxillofac Surg* 2003;32:419-22.
10. Goyal A, Tyagi I, Syal R, Agrawal T, Jain M. Primary aneurysmal bone cyst of coronoid process. *BMC Ear Nose Throat Disord* 2006;6:4.
11. Malghem J, Maldague B, Esselinck XW, Noel H, De Nayer P, Vincent A. Spontaneous healing of aneurysmal bone cysts: A report of three cases. *J Bone Joint Surg Br* 1989;71:645-50.



## CDE Report

Dr Anil G.  
CDE Convenor, IDA Kerala State



Warm greetings to all IDA members. It is a great pleasure to inform you all about the continuing success of our CDE programs. My hearty congratulations to all local branches for conducting CDE's regularly. I really appreciate your interest and support in conducting interbranch CDE's. Many other local CDE's and interbranch CDE's have been planned. Kindly visit our website for more details.

Our first state level CDE programme conducted on 7th april 2013 was inaugurated by State Dental Council member Dr.Johnykutty Jacob. It was held at Hotel Hillspark, Kumbazha, Pathanamthitta, hosted by IDA Pathanamthitta branch. The topic

was on Occlusal harmony in fixed prosthodontics, taken by Dr.Mathai Joseph. My special congratulations to IDA Pathanamthitta branch for hosting the state CDE. I would like to thank Dr.Anthony Thomas [President IDA Kerala state], Dr.K.M.Thomas[vice president IDA Kerala state], Dr.Johnykutty Jacob[State Dental Council member], Dr.Binu Chacko [Branch President IDA Pathanamthitta], Dr.Manoj. M.Kumar[Branch Secretary IDA Pathanamthitta] for their wholehearted participation.

## Website Report IDAKerala.com

Dr. Rajeev Simon K.  
Website Chairman, IDA Kerala State.



Dear Friends,  
IDAKerala.com has once again secured the Best State Branch Website Award. Continuously winning national award for the third time. "Nothing great is ever achieved without sincerity & hard work" So with all of you to support there is always scope for more recognition to come to IDA Kerala.

Our Journal KDJ has won world wide appreciation. Log statistics reveal surprising number of visitors to journal section. KDJ is seen to be widely accessed from United States, Norway, United Arab Emirates, China, Qatar, Indonesia, Saudi Arabia, Great Britain and Canada.

I feel the days gone by were successful with your constant support and encouragement. I thank you all for your support.

## WDC Report



**Dr. Thaj.S.Prasad**  
Chairperson



**Dr. Mercy Joji**  
Secretary



Installation of office bearers of WDC 2013 at Lulu International Convention Centre, Thrissur.



National award to WDC 2012 at IDC Kolkata.



IDA state award to WDC 2012 at 45th KSDC - Thrissur.



Inauguration of WDC 2012 exhibition cum sale at 45th KSDC - Thrissur.



WDC 2012 exhibition cum sale at 45th KSDC - Thrissur.



Poster release - 45th KSDC - Thrissur.



Annual general body meeting of WDC 2012 at Lulu International Convention Centre - Thrissur.



International women's day celebrations at Azeezia Dental College, Kollam.

## KOTTAYAM (Vembanad) BRANCH



Inter branch CDE programme conducted by Kottayam branch on March 17 at Hotel Arcadia, Kottayam. The one day course was conducted by Dr. Yohan Chacko and the topic was ENDO EVOLUTION.

IDA members from neighbouring branches and post graduate students from Mar basaleous dental college and Amrita dental college have attended the course.

## CHALAKUDY BRANCH

IDA Chalakudy organized 1st executive meeting on 23/1/2013 at Cosmos Club, Chalakudy. The first general body was conducted on 27/2/2013 at Cosmos Club, IDA Chalakudy. We



also celebrated dentist day in Seon Ashram, Kadukutty, organizing a dental camp for mentally disabled people. As a part of dentist day we honoured dr Aby Hormis.



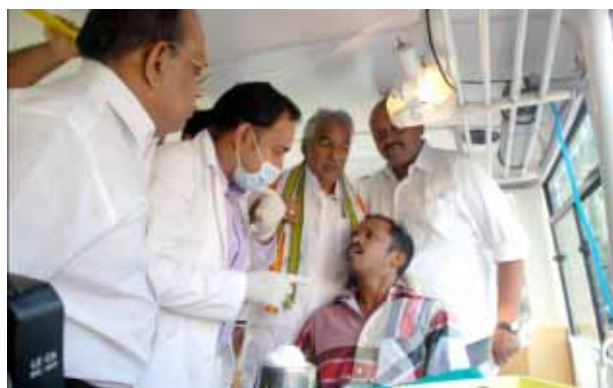

Dr. Civy V Pulayath  
CDH Chairman, IDA Kerala State

## CDH Report

### 1. Susmitham - All Kerala Oral Health Survey

**Survey** : This historic venture is in progress at 140 assembly constituencies of Kerala and had covered more than 1.5 lakhs subjects. All IDA branch CDH chairmen are requested to contact the state chairman and do the needful for successful implementation of this event. [cdh@idakerala.com](mailto:cdh@idakerala.com)



CDH Chairman Dr. Civy V. Pulayath and others with Chief Minister Sri. Oommen Chandy during inauguration of Kerala Oral Health Survey

**2. Dentist Day - Hosted by IDA Coastal Malabar:** The fabulous celebration was a mega success with competition for children, awareness program for health workers, dental street play, public meeting, media awards, cultural events. The rural beauty of Pilathara near Kasargod witnessed this mega event. Accomplishes all CMB IDA members especially Dr. Santhosh Sreedhar and Dr. Jayakrishnan.



Chief Guest Cini Director Sri Madhupal handing over media awards during Dentist Day celebrations 2013 at Pilathara, Kasargod.



Cultural programs by dental college students in connection with dentist day public function.

### 3. Dyuthi - Awareness printouts on innovative topics

a. Dental Snake and Ladder, b. Dental Playing Cards, c. Dental Health Magazine, d. Dental Health Education CD  
Soft copies have been sent to all available emails and uploaded in website. Hard copies are available on request. Please contact 9895677477.



**4. Water Fluoride Estimation of Kerala:** This innovative project in association with Kerala Water authority has started after the ministerial level discussion by IDA officials at Trivandrum. The research is aimed at disclosing the invisible fluoride belt existing in Kerala. Awareness about fluoride toxicity and anti fluoridation plant implementation are also planned.

**5. World Health Day:** World Health Day talk was held on April 7 in association with IMA at Kochi based on this years theme " Hypertension the silent Killer".

**6. SMILE TRAIN - Coming Soon... :** Another innovative venture of state CDH wing is planned in the month of July to spread the oral health awareness among the public through magic, chakyarkoothu and palmlet distribution in TRAINS. A journey from Kasargod to Trivandrum is being planned with the support from all local branches in their respective railway stations.

## ATTINGAL BRANCH

**Acquire 2013:** The President & Secretaries seminar on Feb 17th was attended by Dr. Rudy A. George, Dr. Abhilash G.S, Dr. Ashok Gopan & Dr. Afzal .A at Kannur.

**CDH Activities: CDH activity No. 1 :** IDA Attingal branch, in association with Lions club of Nagaroor, conducted Oral screening camp and awareness programme at Nagaroor Govt. LPS on 25th January 2013.

**CDH activity No. 2:** IDA Attingal branch conducted a Dental awareness program on February 1, at LM UPS, Benglamkunnu, Nilamel at 11am

**CDH activity No. 3:** IDA Attingal branch conducted dental awareness camp in Govt UPS Nilamel on February 1 at 2.30 pm

**CDH activity No. 4 : World Cancer Day observed on February 4:** Awareness on oral cancer and anti tobacco campaign was done by IDA Attingal branch at Triumph tuition centre, Nilamel with the help of Poursamithi kannankode at 4pm. Dr. Arshad B.H, CDH Convenor took classes on various oral cancers, tobacco misuse and its role in oral cancer.

**CDH activity No. 5:** Drawing Competition held for Children

**Dentist's Day** (March 6th) was observed by conducting a full day programme start-

ing with a painting competition at Kamala Hridaya L.P School, Nilamel on dental animation topic. This was followed by children's fun school activities including plays relating to dental health awareness and its applications.

**Benefiting Schemes for IDA Attingal members :** At 6:00 pm, a get-together programme of the executive members was held at Sky lounge resort, Varkala beach. Dr. Vijayan, a senior and dedicated member of IDA Attingal branch was honored with a Ponnada that evening. He related many old stories commenting how the dental scenario has changed over the years. Secretary announced the initiation of 'IDA Attingal Help line' in the website, which included specialists from all branches of dentistry, for the benefit of our members.

**CDH activity No. 6 - Women's Day (March 8th):** Dental Health Awareness & Adoption of Navajyothi Rehabilitation Centre for Women & Children in Distress', Kariyavattom, Thiruvananthapuram. This program was attended by the State WDC Chairperson, Dr. Thaj Mohan. Inmates of 'Navajyothi Rehabilitation Centre for Women & Children in Distress', Kariyavattom, had benefited from this program. 50 toothpaste sachets were distributed. The WDC (IDA

Attingal br.) has agreed to adopt this institution for a period of 1 year. As an initial contribution, a monetary assistance of Rs. 5000/- was given to Sr. Elsy, the Chief nun of this institution.

**CDE Activities:**

**CDE Program No.1** The first Inter branch CDE program of IDA Attingal branch for 2013 was conducted on 24th Feb 2013 at Technopark club, Technopark, Kazhakuttom, Thiruvananthapuram. The topic of the programme was, 'Science & Arts in Design of Complete Dentures'. The faculty was Prof. Dr. K. Chandrasekharan Nair. Member of Kerala Dental Council, Dr. Johnykutty Jacob was the chief guest. Dr. Anil .G, CDE Chairman of IDA Kerala State was the guest of Honour.

**CDE Program No.2:** The 2nd CDE program of IDA Attingal branch for 2013 was conducted on 21st April 2013 at Technopark club, Technopark, Kazhakuttom, Thiruvananthapuram. The topic of the programme was, 'Child Management & Clinical Pedodontics'. The faculty was Dr. Sarada P. Nampi.

**1st Executive meeting:** The 1st executive meeting of IDA Attingal branch was held on 2nd Feb 2013 at Attingal club, Attingal, 7.30pm. The various proposed projects and programmes for the year 2013, on behalf of the ida attingal calendar was read out by the secretary, Dr. Rudy A. George.

**2nd Executive meeting:** The 2nd executive meeting was held on 3rd April 2013 at Rotary Club of Attingal, at 7.00pm. Many decisions regarding CDE, CDH, Cricket tournament, Journal, Hope & Image were taken.

**News Bulletin (IOPA) released:** The 1st & 2nd issue (Jan & Feb issue) of the monthly news bulletin, IOPA (Internal Official Publication) was released. It was uploaded in IDA Attingal website.



## MALANADU BRANCH

**REPORT OF THE DENTISTS' DAY OF IDA MALANADU BRANCH 2013:** IDA Malanadu observed the "Dentists' Day" 2013 by conducting dental treatment camp and organizing a family get-together. The dental treatment camp was held on Wednesday, 6th March, at Nirmalagiri Vocational Rehabilitation Center, Mudavoor, Muvattupuzha, which is a higher secondary school for the differently abled adults, run by the FCC congregation of Sisters. The camp was conducted in association with Mar Baselios Dental College, Kothamangalam. The camp started with an inaugural interactive session with the staff and students, which was attended by the President Dr Ciju A. Paulose, Hon. Secretary Dr Jayan Jacob Mathew, CDH Convener Dr Joby J. Parappuram, IDA Central Council Member Dr Alias Thomas, Past President & Senior Member Dr Mathew Pylee. This was followed by the treatment session for nearly 40 students led by Dr Ciju A. Paulose, Dr Joby Parappuram, and Dr Pearly Peter. An awareness class was conducted for the teachers of the institution by Dr Pearly Peter.



At the State Dentists' Day Celebrations held at Pilathara, Payyannur on March 6th, our member Dr Mathew Pylee was honored for completing 40 years of practice. Dr Jayan Jacob Mathew was awarded as the promising member from IDA Malanadu Branch.

The family get-together in connection with the Dentists' Day was held on Saturday, 9th March, 7:30 PM at Hotel Kabani International, Muvattupuzha. Ms Rose Johny, noted performance artist and Principal of Vimalagiri International School, Muvattupuzha, was the chief guest. President Dr Ciju A. Paulose honored our couple members Dr John Joseph and Dr Jolly John, on completing 40 years of practice together. The first issue of Malanadu Dental Journal (Vol 2 issue 1) was released by our Past President Dr Babu John by handing over to Dr Litto Manuel, Editor. There were performances by the Chief Guest and the children of our members. Variety entertainments were organized by Ganam Orchestra, a professional music troupe.



## MALAPPURAM BRANCH

**CDH Activities :** 1. 4th CDH Camp was held at Valancheri on 09/02/2013. 52 patients were examined by 6 doctors and 15 patients received treatments.  
 2. 5th CDH camp was held at Pulloor on 23/02/2013 in association with Valavil group. 74 patients were examined by 6 doctors.  
 3. 6th CDH camp was held at Pullengode near Nilambur in association with Pullengode Pourasamithi on 23/03/2013. 110 patients were examined by 7 doctors.  
 4. On the world Health Day the dream CDH project of the year, "Hridayapoorvam" (donating 100 waterbeds to the pain and palliative patients of the Malappuram district) was inaugurated by Dr. Chandrasekharan Nair. The distribution of the waterbeds will be done on 1st July 2013  
 5. A press release was done on 12th April 2013 at Malappuram Press Club explaining the details of the "Mission: Quackery Free District" project of the CDH wing of the IDA

Malappuram and it was well covered in the media  
**CDE Activities:** 1. 2nd Inter branch CDE was held at Hotel Rydges Inn, Kottakkal on Saturday 23rd March 2013. The CDE included lecture & demo on "SPINERGY" by Dr. Mohammed Sameer PT.  
 2. 3rd inter branch CDE was held at Hotel Surya Regency, Malappuram on Sunday 7th April 2013. from 9.30 am to 4.30 pm. The CDE included the lecture and demo on Complete Denture Impression by Dr. Chandrasekharan Nair. The CDE was well attended by 44 members including from neighboring branches  
**Day Celebrations / Observation** 1. Dentist's Day was observed at Surya Regency, Malappuram  
 2. International Women's day was observed at Surya Regency Malappuram  
 3. World Health Day was celebrated on 7th April 2013 at Surya Regency, Malappuram

**Family Get together** 1. Kalikkalam 2013 ( IDA Malappuram Sports) and family get together was held on 21st April 2013 at Cosmopolitan Club, Manjeri. Various sports items like badminton, table tennis, chess, caroms, cricket, football etc were conducted. Games for the children and family were also conducted. 19 members attended with their family  
 IDA Malappuram visited Dental South China Conference from 27/02/2013 to 03/03/2013 held at Pazhou International Exhibition Centre, Guangzhou, China  
**Executive committee meetings:** 2nd Executive committee meeting held on 6/02/13 Wednesday 8pm onwards at Surya Regency, Malappuram. 20 members attended. 3rd Executive committee meeting held on 6/03/13 Wednesday 8pm onwards at Surya Regency, Malappuram. 28 members attended. 4th Executive committee meeting held on 3/04/13 Wednesday 8pm onwards at Surya Regency, Malappuram.



## PATHANAMTHITTA BRANCH

### Activity Report - February 2013

1. Second executive committee meeting of IDA Pathanamthitta was held on 31st January 2013 at Hotel Hills Park, Pathanamthitta at 7 30 pm. Seventeen executive committee members attended the meeting and decisions on cleft lip and palate diagnosis camp, inter-branch women empowerment seminar, IDA Pathanamthitta face book account starting, CDH activities etc was taken.  
 2. A bachelors tour was conducted to llaveezhaponchira near wagamon along with the engagement ceremony of Dr.Shine M at Thodupuzha on 10th February 2013. Ten members participated in the tour. It was a great experience of joy and adventure for all of us.

3. President Dr. Binu Chacko and Secretary Dr. Manoj M Kumar attended the president-secretary seminar conducted by the IDA Kerala State at Kannur on 17th February.  
 4. Third executive committee meeting of IDA Pathanamthitta was held on 26th February 2013 at Hotel Hills Park, Pathanamthitta at 7 30 pm. Sixteen executive committee members and the state CDE convener Dr. Anil G attended the meeting and decisions on Dentist day



programme, branch CDE on march 10th, state CDE on April 7th etc was taken.

## TELLICHERRY BRANCH

### CDE PROGRAMMES

1st CDE Programme was held on 26-3-13 at IDA hall Podikundu, Kannur. The topic of the CDE was "Occupational Safety and Sterilization in Dental Practice". Dr. Ashokan C.K was the faculty. The Programme started at 7:30 p.m and ended at 9:30 p.m. The attendance was 48. The CDE Activities for the year 2013-14 was inaugurated by Dr. Rameshan. T.V.

2nd CDE Programme was held on 16 April 2013 at IDA hall, Podikundu, Kannur. The topic of the CDE was "Perio - Ortho inter relation and Perio - Restorative inter



relation" and the faculties were Dr. Arun Narayanan and Dr. Ajay Kumar. The



Programme started at 8:00 p.m and ended at 9:30 p.m. The attendance was 42.

## KOTTARAKKARA BRANCH

**Dentists Day :** Ida Kottarakkara celebrated Dentists day on March 6th, 2013 in a grand manner at Deeni Bhavan, A rehabilitation centre for poor and mentally challenged run by St Teresas Missionaries of Charity at Punalur. Programme started at 6pm with cultural activities by inmates, Ida members and family.



Dental awareness class was given to inmates. More than 25 dentists along with members participated. Food was supplied to inmates and a sum of Rs 20,000 donated to the institution for their well being.

### CDE Activities:

1st CDE of IDA Kottarakkara on Medical Emergencies by Dr John Benjamin,

Physician and Diabetologist at Hotel Highland with participation of 30 members.

2nd CDE BY eminent Paediatrician Dr Anil K Tharian. Topic was Paediatrics in Dentistry on 21st April at Hotel Highland with participation of more than 35 members.



## QUILON BRANCH

Indian Dental Association, Quilon branch, with its excellent team support successfully held the first Women's Dental Council programme on International Women's Day, 8th March, 2013 by conducting free dental check-up camps for needy women to create "Oral Health Awareness" in our society. The theme of 2013 International Women's Day being "The gender Agenda: Gaining Momentum" motivated and geared up twenty one lady dentists in and around Quilon, to actively participate and render social work by conducting free dental check-up camps along with patient education in their own private clinics.

**The second WDC programme:** The second WDC programme of IDA, Quilon branch was held on World Health Day, 7th April, 2013 at 6 pm in Lions club, Kollam. The talk was delivered by a reputed gynaecologist in Kollam, Dr Deepthi Prem who has an MD in gynaecology. She's a consultant gynaecologist in Upasana Hospital, Kollam. She also has her own Infertility Clinic "Janani" in asramam, Kollam which is running very successfully.

Dr. Deepthi Prem was greeted and welcomed with a flower bouquet. An introductory speech was then given by

the ladies council representative to familiarise the audience with the professional as well as personal achievements of the speaker. A briefing of the importance of World Health Day was also touched upon. Since the theme of World health day, 2013 was hypertension, Dr Deepthi was requested to take one topic in relevance to that Dr Deepthi was then called on stage to deliver the talk. The topics included were PRE-ECLAMPSIA, URINARY TRACT INFECTION & PREMENSTRUAL SYNDROME. Dr Deepthi gave a fantastic talk with power point presentation. This was followed by an active interactive session wherein the doubts / questions prepared anonymously by the participants were answered & cleared. The participants included dentists, non-dentists, housesurgeons and final year students too.

### Dentists Day Celebration 06/03/2013

1. As part of Dentists day celebrations. A dental awareness and check-up camp was organized at S.N. Women's College, Kollam. The inaugural session started at 1.30 p.m. Cash prizes of Rs. 1500/- each were distributed to 6 meritorious and poor students of the college. The inaugural session was followed by a

Dental Awareness programme conducted by Dr. Shibu Rajagopal with audio- Visual aids. Followed by Dental Check-up programme.

**2. 2nd G.B.Meeting 16/02/2013:** The Meeting was called to order by president at 7.30 pm at hotel Vaidya, Kollam.

**3. 2nd CDE Programme:** 2nd CDE Programme on 16/02/2013 was conducted at hotel Vaidya, Kollam The faculty was Dr. Vishnu Mohan MDS, Oral Maxillo Facial Surgeon, the topic was Dento alveolar complications.

**4. 3rd G.B. Meeting 16/03/2013:-** The meeting was called to order by president at 7.00 pm at Lion's Hal Kollam. A resolution to be sent to Hope secretary was discussed. Accounts of the first quarter was presented by the treasurer.

**5. 3rd CDE Programme** was conducted at Lions Hall Kollam, the faculty was Dr.Sonnu, MDS Endodontist, the topic was esthetic dentistry.

6. 10/04/2013 Dental Check up and cancer detection camp jointly with IMA and Rotary Club at Ashirvad Auditorum Uliyakovil Kollam. Almost 500 patients from neighboring areas were checked. CDH convener Dr. Deep Mohandas organized the programme.





## NEBUMBASSERY BRANCH

**AGM AND INSTALLATION:** AGM and Installation was conducted on the eve of 22nd December 2012 at Dr Jaibins Residence at Kalamassery. Chief guest was Dr Antony Thomas, (President, elect IDA Kerala State). Dr Vinu Pr and his team OF Office bearers were installed. Dr ShibuRajagopal (Secretary, IDA Kerala State). Dr O.V. Sanal, (Vice president IDA kerala state) felicitated the new office bearers.

**DENTIST DAY CELEBRATIONS MARCH 6th:** Dentist day celebrations were held at Carnival cinemas, Angamaly on March 6th 2013 in a beautiful manner. DrSanthosh Thomas had given the dentist day message. As a part of celebrations, cake cutting was done by Dr A.K.Balachandran,our senior member. Members presented various cultural programmes, which was followed by fellowship, dinner and cinema.

**EXECUTIVE MEETING:** We have conducted three executive meetings till now. 1st executive meeting held at Hotel Surya, Angamaly on 3-1-2013. Goals and plans for the year 2013 was discussed. Budget for the year was presented. 2nd executive meeting was held at Periyar Club,Aluva on 14-2-2013. Minutes and action taken

were discussed. 3rd executive meeting was held at Periyar Club, Aluva on 14-3-2013. Sub Committee was formed to commemorate the clinical standardisation.

**CLINICAL MEETING:** A Clinical meeting was held at Hotel Surya, Angamaly on 16-2-2013. Topic was "case history management in practise using paper /software". Faculties were Dr Binu Abraham and Dr Senny Thomas. 50 Members from our branch attended the meeting.

**STAFF TRAINING PROGRAMME:** Our branch conducted a staff training programme on clinical management and sterilisation protocols on 17-3-2013, Sunday at Dr BinoyAmbookens Clinic at Kalamassery.Faculties were Dr Binu Abraham and Dr BinoyAmbooken.More

than 30 staff attended the programme. Certificates were issued.

**CDE PROGRAMME:** 1st CDE of this year of our branch was conducted on 21-4-2013 at Carnival Cinema Complex, Angamaly from 10 am to 2 pm. DrVinu P. R (President) inaugurated the CDE.Faculty Dr SantoshSreedar gave a talk and live demo on TEETH WHITENING. 32 Members from our branch and 8 members from other branches attended the CDE programme.

**CDH PROGRAMME:** Our branch adopted various orphanages for CDH programmes. This year we are planning to conduct free check up camps there.Every month last Sunday we have a free dental treatment at Daivadanoldage home at Malayatoor which is for the inmates and for the public.



## TELLICHERRY BRANCH



**Installation Ceremony** of office Bearers of Tellicherry branch for the year 2013 was held on 10.2.13 at Deract Hall, Dharmadam, Thalassery. Dr. Antony Thomas, President IDA Kerala State was the chief guest of the day. Dr. O.V. Sanal, Hon. Secretary IDA Kerala State and Dr. M.C. Mohan, Past IDA National President were the guests of honour. A total number of 62 members from different branches with their family members attended the event. The official ceremony was followed by dinner and entertainment.

**1st Executvie Meeting** held on 2-3-13 at Deract Hall decided to conduct 1st CDE

programme and to participate in Dentist day celebration on 6th March Pilathara.

**CDE Report:** An intra-branch CDE is conducted by Tellicheri branch on 31st March 2013 at Hotel Sherera Plaza, Thalassery. The Topic was Internal Derangement-Treatment Dilemma Systemic Health Status Evaluation - Why the Need. The Faculty was Dr. Vivev Narayan, Professor and HOD, Dept. of Oral and Maxillofacial Surgery, Priyadarshini Dental College Tamilnadu.

**2nd Exeuctive meeting** held on 23.4.13 at Deract Hall decided to host 2nd State CDE programme on 19th May the Teh Village, Pandakkal Mahe.

## TRIVANDRUM BRANCH

**Activites -1st quarter**

Greetings from Trivandrum.Association was very active in its first quarter in terms of accademicals and social activities.

**CDE-**Dr.Achuthan Nair, CDE Convener could co-ordinate two clinical club meetings and one CDE programme successfully.

February 12th, Tuesday: Symbiosis clinical club, at Innu Appartments, talk by Dr. Sreekumar District Health officer, regarding registration formalities to be undertaken for Dental Clinics. 66 members attended.

March 12th, Tuesday: Symbiosis clinical club, at Innu Appartments, video presentation of Dr. Christensen's lecture on preparation for metal free ceramics. Chaired by Dr.C.P John, 32 members

attended.

April 21 st Sunday: CDE programme on Basic Life Support at Hotel Nandanam Park, conducted by MIMS Emergency Medicine Team with lecture and hands on demonstrations. 55 members attended.

CDH – Dr.Tharun, CDH Convener arranged one dental check up camp at East Fort Sanskrit Govt.School, East Fort, Trivandrum on 20th Feb.2013 with 10 doctors attended -70 students (primary and high school) were screened. Oral care and hygiene instructions were done... Oral hygiene kits and dental brochures were distributed..

**Publications-** Editor Capt.Dr.Vivek released Volume 4 issue 1 of Trivandrum

dental journal on 20th April which is available on line at [www.trivandrumdentaljournal.org](http://www.trivandrumdentaljournal.org)

Sports- Dr.Shibu Pillai orchestrated our participation in the inter branch cricket tournament at LNCP Ground organised by Attingal branch.

1st general body meeting was conducted on 20-3-2013 at Trans Towers-Vazhuthakadu. Dr.Ramachandran, Chief diabetologist made a keynote speech on diabetes management.

1st executive meeting was conducted on 31-01-2013 at Innu apartment, Second executive meeting on 7-03-2013 and third on 15-04-2013.

**COASTAL MALABAR BRANCH**

**IIInd CDE Programme 27-02-2013:** IIInd CDE Programme of IDA Coastal Malabar Branch held at Farmers Bank Auditorium, Cheruvathur, On 27-02-2013 at 7.30 p.m. Faculty for the programme was Dr. Dennis Mohan, Asst. Prof. Dept. of Conservative Dentistry & Endodontics Pariyaram Dental College. The Topic was Case Selection and Treatment Planning in Endodontics. Nearly 60 members of our branch attended the CDE Programme.

**IIIrd Executive Committee Meeting 27-02-2013:** IIIrd Executive Committee Meeting of IDA Coastal Malabar Branch held at Farmers Bank Auditorium, Cheruvathur. The main agenda was Dentists' Day Celebrations. Chief Co-ordinator for the programme was Dr. Santhosh Sreedhar (Past President, IDA Kerala State) and various sub-committee chairman spoke about the up-coming Dentists' Day Celebration.

**IIIrd CDE Programme, 24.03.2013:** IIIrd CDE Programme of IDA Coastal Malabar Branch held at Hotel Food Palace, Payyanur On 24.03.2013 at 4.30 pm. The faculty was Dr. Regish. K.M, Asst. Prof. Dept of Prosthodontics, Coorg Institute of Dental Science, Virajpet. Topic for the programme was shade selection – A Dilemma. Nearly 60 members of our branch attended the CDE Programme. Programme was sponsored by Colgate Palmolive India Ltd.

**24.03.2013 IDA HOPE :** After CDE Programme the IDA HOPE Representative Dr. Ranjith Raveendran briefed about prestigious scheme of IDA Kerala State - HOPE. And motivated the non-members to join the scheme.



**IN MEMORIAM**

*"The song may have ended, but the melody lingers on....."*

**Dr. Sharafuddeen, MDS**

Asst. Prof: Dept. of Oral Medicine & Radiology, GDC, Calicut

Past President IDA Malabar

1st VP, IDA HOPE & State Executive member, IDA Kerala State