



# KDJ

K e r a l a   D e n t a l   J o u r n a l

Vol 40 | No. 4  
October 2017

Quarterly Publication of Indian Dental Association, Kerala State Branch

- Microscopic evaluation of effects of various storage media on periodontal ligament cells of human teeth: an in vitro study
- Comparative Study of pulse rate and behavioural anxiety reactions in children during skin prick test with local anesthetic solution under different clinical settings
- A case report on PAOO; A recourse for conventional orthodontic treatment
- Guided bone regeneration and two stage implant surgery for anterior single tooth replacement
- Costello syndrome – A rare multisystem disorder
- Anterior esthetic zone rehabilitation using rochette bridge
- Peripheral ossifying fibroma
- Principles of lasers in dentistry
- Critical evaluation of minimally invasive surgical techniques in Periodontics
- A novel costeffective device for chairside preparation of PRF membrane
- Prosthetic rehabilitation of missing anterior tooth using ever stick C&B bridge
- A novel technique for the fabrication of a lightweight maxillary hollow denture
- Understanding angular cheilitis: a review of its etiopathogenesis and therapeutic approach
- Presurgical nasoalveolar molding
- Cheek plumper prosthesis using button attachment
- Digital Smile Designing
- Management of excessive gingival display
- Noonan Syndrome
- Diagnose
- Quiz
- Association News

SIS Index ID 833

[kdj.idakerala.com](http://kdj.idakerala.com)





**EDITOR**

**Dr. K. Nandakumar**

**ASST. EDITOR**

**Dr. R.M. Baiju**

**BUSINESS MANAGER**

**Dr. Mathew Jose**

**EDITORIAL CONSULTANTS**

**Dr. Santhosh Sreedhar**  
**Dr. K. Chandrasekharan Nair**  
**Dr. K. George Varghese**  
**Dr. Ipe Varghese**  
**Dr. Oommen Aju Jacob**  
**Dr. V.I. Paul**  
**Dr. Thomas Manjooran**  
**Dr. Sobha Kuriakose**  
**Dr. N.O. Varghese**  
**Dr. T. Sreelal**  
**Dr. Siby Xavier**

**EX-OFFICIO MEMBERS**

**Dr. Sabu Kurian**  
**Dr. Suresh Kumar G.**  
**Dr. Mohammed Sameer P.T.**  
**Dr. Ciju A. Paulose**

**EDITORIAL BOARD**

**Dr. Dibyendu Mazumder**  
**Dr. Ashok Dhoble**  
**Dr. Jayakar Shetty**  
**Dr. K.T. Sreelatha**  
**Dr. M.K. Mangalam**  
**Dr. Ratnakumari**  
**Dr. Gilsa K Vasunni**  
**Dr. Anitha Balan**  
**Dr. Jolly Mary Varughese**  
**Dr. V A Afzal**  
**Dr. Sunil Sunny**  
**Dr. Radhakrishnan .K**  
**Dr. Pramod John**  
**Dr. Ajay Kumar Haridas**  
**Dr. Romel Joseph**  
**Dr. Arun Narayanan**  
**Dr. Pradeep Kumar.C**  
**Dr. Vinod R B**  
**Dr. George P John**  
**Dr. P G Francis**  
**Dr. M.Sadique Hussain**  
**Dr. Saji P**  
**Dr. Thajuraj P K**  
**Dr. Aby Mathew**  
**Dr. E.Anuradha Sunil Jagan**  
**Dr. Thomas Joseph**  
**Dr. Manoj Nair**  
**Dr. Jain Mathew**

**EDITORIAL OFFICE**

Neelambikam, Attukal, Manacaud  
Trivandrum, Kerala - 695 009  
Phone: 0471-2459235  
Mobile: 09447066100  
e-mail: editorkdj@gmail.com  
web: www.idakerala.com

**OFFICE BEARERS OF  
IDA KERALA STATE**

**PRESIDENT**

**Dr. Sabu Kurian**

**IMM. PAST PRESIDENT**

**Dr Mohammed Sameer P.T.**

**PRESIDENT ELECT**

**Dr. Ciju A. Paulose**

**VICE PRESIDENTS**

**Dr. Subash K Madhavan**  
**Dr. Arun Roy S**  
**Dr. Biju Kumar S D**

**HON. SECRETARY**

**Dr Suresh Kumar G**

**JOINT SECRETARY**

**Dr Binoy Stanly**

**ASST. SECRETARY**

**Dr. Krishna Kumar K S**

**TREASURER**

**Dr. Santhoshkumar P.U.**

**EDITOR**

**Dr. K. Nandakumar**

**CDE CHAIRMAN**

**Dr. Anil Thunoli**

**CDH CHAIRMAN**

**Dr. Rajesh V**



## Digital dentistry: Is this the future of dentistry?

Digital dentistry may be defined in a broad scope as any dental technology or device that incorporates digital or computer-controlled components in contrast to that of mechanical or electrical alone. This broad definition can range from the most commonly thought area of digital dentistry – CAD/CAM (computer aided design/computer aided manufacturing) – to those that may not even be recognized, such as computer-controlled delivery of nitrous oxide.

The following list represents the majority of the areas of digital dentistry. All are assumed to incorporate some type of digital components; not every conceivable area is listed.

1. CAD/CAM and intraoral imaging – both laboratory- and clinician-controlled
2. Caries diagnosis
3. Computer-aided implant dentistry – including design and fabrication of surgical guides
4. Digital radiography – intraoral and extraoral, including cone beam computed tomography (CBCT)
5. Electric and surgical/implant hand pieces
6. Lasers
7. Occlusion and TMJ analysis and diagnosis
8. Photography – extraoral and intraoral
9. Practice and patient record management – including digital patient education
10. Shade matching

There are many other areas of digital dentistry available, and many more are being researched. It is an exciting time to be in the dental profession as more technologies are being introduced that make dentistry easier, faster, better, and – most important – enjoyable.

Digital dentistry is more than just hype. When properly implemented and fully educated, return on investment can be excellent, increased joy in practicing dentistry can be experienced, and better care for your patients can be delivered.

The future of dentistry is now. Waiting another 10 years to adopt or integrate these new areas of dentistry will leave you decades behind. Decide which areas will best augment your practice, make informed decisions regarding your choice of product/technology, obtain education and training, and have fun!



Secretary's Message	192
President's Message	193
Editorial	194
<b>Microscopic evaluation of effects of various storage media on periodontal ligament cells of human teeth: an in vitro study</b> — Soumya Rajan	195
<b>Comparative Study of pulse rate and behavioural anxiety reactions in children during skin prick test with local anesthetic solution under different clinical settings</b> — Lekshmy S.R. Nair	199
<b>A case report on PAOO; A recourse for conventional orthodontic treatment</b> — Mahesh Raj V.V.	203
<b>Guided bone regeneration and two stage implant surgery for anterior single tooth replacement</b> — Tessa Paul	207
<b>Costello syndrome – A rare multisystem disorder</b> — Veena S Ravi	212
<b>Anterior esthetic zone rehabilitation using Rochette bridge</b> — Abha Nair	215
<b>Peripheral ossifying fibroma</b> — Haseeba K.	218
<b>Principles of lasers in Dentistry</b> — Ebinu A.	221
<b>Critical evaluation of minimally invasive surgical techniques in Periodontics</b> — Thomas George V.	225
<b>A novel costeffective device for chairside preparation of PRF membrane</b> — Joshy P Abraham	230
<b>Prosthetic rehabilitation of missing anterior tooth using ever stick C&amp;B bridge</b> — Reshmi Raghuvaran	232
<b>A novel technique for the fabrication of a lightweight maxillary hollow denture</b> — Himanath K.	235
<b>Understanding angular cheilitis: a review of its etiopathogenesis and therapeutic approach</b> — Shalini Nair	239
<b>Presurgical nasoalveolar molding</b> — Anna Oommen	242
<b>Cheek plumper prosthesis using button attachment</b> — Layana Theodore	245
<b>Digital Smile Designing</b> — Soumya Mohan B	248
<b>Management of excessive gingival display</b> — Remya Karingattil Sasidharan	251
<b>Noonan Syndrome</b> — Jaseena PM.	254
<b>Nager syndrome (Preaxial acrofacial dysostosis)</b> — Lubna M.	256
<b>Dentigerous cyst involving maxillary sinus</b> — Remya K.C.	259
<b>The referral process-concerns and considerations in referring a patient to a periodontist</b> — K. Harikumar	262
<b>Diagnose</b> — Jacob John	264
<b>Quiz</b> — Jayanthi	265
<b>Association News</b>	266

# Message from the Secretary

---



**Dr. Suresh Kumar G**

Dear members,

Warm wishes to all members.

With less than a couple of months to go for the 50th Annual State Conference of IDA Kerala State we are coming to the end of yet another organisational year. Looking back the office is pleased with the membership growth that we have achieved and diversification of activities which are mainly member oriented.

IDA associating itself in policy matters concerning the profession and implementing projects that explain its significance in virtually all sectors of the profession calls for a much larger and responsible role as a professional organisation.

Two very significant programmes namely IDA CAN (IDA Clinical Accreditation Network) and IDA MARK (IDA Marketing) are being launched.

Clinical Accreditation -A long awaited project will eventually benefit all sections of the practicing professional and pave the way for standardisation and a healthy practice environment. Self Regulation is the basis for this activity and promises a hassle free and transparent process. We are very confident that a credible and practical approach will lead to governmental recognition in due course.

The spinoffs of the project like the custom made clinical management software (IDA Assist) specifically developed and updated with inputs from the association and provided to IDA Members at a affordable cost is an apt example of the benefits that the project can offer.

IDA KSB's foray into the marketing field is focussed with clear objectives of providing quality clinical accessories and materials at reasonable prices, create a mechanism for achieving price control and helping the association to be self reliant. Although the task is daunting and will need continuous monitoring we are extremely encouraged by the enthusiasm and participation that the branches have echoed.

The office requests all members to make use of the several projects which will eventually present a win win situation for the members and the association as such.

Thanking you

**Dr. Suresh Kumar G.**  
Secretary, IDA Kerala State

# Message from the President

---

Dear colleagues

During the last executive meeting at Calicut, we implemented the clinic standardization programs, “IDA-CAN”. Hope you all have received the detailed letter from our secretary by now. From November 1st, IDA members can apply for standardization of their clinics. During the implementation of Clinical Establishment bill the government will have to set certain criteria’s for functioning of a dental clinic. We hope we can convince the CE implementation committee to adopt the standards we have set for our clinic standardization, as the norms for the CE standards.

With standardization we aim to create a brand value for IDA accredited dental clinics. With that we can effectively counter the threats from clinic chains of various corporates.

The executive committee also finalized the proposal for “IDA –MARK”, which will be operational this year itself. We are planning to market dental materials in Kerala, initially only non-perishable disposables, which will be followed by dental materials and equipments later. We believe we can achieve three goals with marketing. First the branches are finding it very difficult to find sponsors for various activities. The profit from this may be used for branch activities, so this will act as a source of income for the branches. Second we can stabilize the prices of various dental products, and lastly, we can assure availability of quality products at reasonable prices. We have more than 3500 clinics in Kerala, even if half of them purchase 25% of their materials through IDA-MARK it will be a huge success. Please ensure your wholehearted support for this new venture.

Initially members will receive only marginal financial benefits, but once we stabilize you will definitely get substantial benefits.

At present HOPE is providing four Lakhs as professional indemnity to its members. We are negotiating with various insurance companies for providing an additional professional indemnity cover of 25 lakhs, and also fire and theft coverage for clinics with little extra premium. Hope that also will get finalized this year itself.

Once again I am requesting all of you to actively campaign to add all the dental surgeons in your area as members of IDA, also spread details about the benefits you can get by joining HOPE and HOPE-MEDI. Group insurance programs give better returns with more members. So participate passionately to add more members and you will be benefitted indirectly.

The subject committee for CE bill has scheduled their hearings, we are prepared, met all the members, and they all promised that we will be included in the implementation committee so let’s hope for the best. It’s very unfortunate that we don’t have any statistically reliable data regarding the incidence and prevalence of dental diseases in Kerala/India, Total number of dental graduates, practicing dentists, dental faculty members, dental clinics etc. A pilot study was conducted at Malappuram this year, but we couldn’t go any further because of paucity of funds and reluctance of government agencies to join us, without them our study will not be considered as an authentic one.

I am very happy to inform you that we got an assurance from Dr MKC Nair, Honorable vice chancellor of KUHAS, that the university will give their co-operation and guidance for conducting the study. Dr Shaji K Joseph, KDC president has agreed to finance the project. So it will become a tripartite study with KUHAS as the guiding agency, IDA as the facilitator, and KDC as the fund provider. We are extremely thankful to both of them. To conduct such a herculean authentic study we need lot of support from our members and branches, and it might take some time to initiate and also many months to complete., I hope we can start it by the beginning of next year, and request you all, especially the future state office bearers to fulfill this dream.

Thank you.

**Dr Sabu Kurien**  
President, IDA Kerala State



**Dr. Sabu Kurien**



**Dr. K. Nandakumar**

## Let us have a research agenda

India is a vast country with huge population and naturally the oral health needs have attained mammoth proportions. To meet the situation we started producing dentists initially with great constraint but later we lost all control and started producing thousands of dentists not to satisfy Indian needs but people have realized that dental education is a lucrative business proposal. We never bothered to find out the oral health needs of the country. Everything was planned according to western standards because only they had statistics. Now sadly we realize that we have only fictional figures not statistics based on our own research. Though belated let us frame a research agenda for our country.

Let us expand the oral health research infrastructure to facilitate research conduct and scholarly activity by the dental college faculty members to support their successful career development and scientific contributions. This would enable them to contribute as role models and mentors for dental students, residents and postgraduate students. Our research should promote the integration of principles and practices of evidence-based dentistry. We have to make inroads and explore the role and complexity of human oral microbial ecology in the etiology and pathogenesis of dental caries, periodontal diseases and oral cancer. We should make rapid progress in the field of safe, novel restorative and biomimetic materials for oral and craniofacial health care, including the restoration and regeneration of hard and soft tissues affected by trauma, disease and developmental defects.

We should find out funding to develop electronic dental health record system with the goal of promoting the integration of oral health care within the overall health care system. We should develop a comprehensive clinical database, to improve oral health surveillance and oral disease monitoring and eventually an effective oral health planning.

Within the next ten years our society should readily infuse new knowledge, implement effective treatment and de- implement ineffective treatments. The first step will be to get a definitive data of oral diseases prevailing in our country. Let our dental colleges, district, taluk and primary health centres and IDA take an initiative in formulating appropriate research.

**Dr. K. Nandakumar**  
Editor, KDJ

# Microscopic evaluation of effects of various storage media on periodontal ligament cells of human teeth: an in vitro study

\* Soumya Rajan, \*\* Bobby John Varghese, \*\*\* Suprasidh Suprakasam, \*\*\*\* Nissy Elizabeth George, \*\*\*\*\* Reshmi Reghuvaran

## Abstract

Avulsion is a dental injury causing de-attachment of tooth from its socket. Avulsion management needs tooth replantation. If replantation is delayed, storage media is required.

**Aim:** To evaluate the efficacy of bovine milk, chicken egg white and coconut water as storage media for avulsed permanent tooth.

**Materials and methods:** forty freshly extracted premolars are immediately transferred to 4 groups of 30ml storage media. Group 1- bovine milk, group 2 – egg white, group 3 – coconut water, group 4 – 10% formalin (control). After 60 minutes of storage in different media, teeth are fixed and then demineralised for 15-20 days. Samples were sectioned and analysed with help of light microscope containing a square reticule using Image J software for the number of cells in periodontal ligament. Statistical analysis was done using Anova and Tukey test.

**Results:** Analysis showed statistically significant ( $p < 0.001$ ) results among all the groups (ANOVA). Inter group comparison also showed statistical significance ( $p < 0.05$ ) except group 2 and 3 in Tukey test.

**Conclusion:** Bovine milk showed significantly better results.

**Key words:** Avulsion, replantation, storage media

## ► Introduction

Dental trauma is one among the serious conditions occurring in children.<sup>1</sup> With regard to injuries, trauma to oral region constitutes to about 5% and dental injuries were common among oral injuries, comprising about 1-16%.<sup>2,3</sup> Avulsion is a serious dental injury resulting from loss of periodontal ligament attachment from the alveolar socket and there is damage to cementum, alveolar bone, and pulp.<sup>3,4</sup>

The treatment for avulsion is immediate replacement of tooth into the socket to preserve the vitality of periodontal ligament cells.<sup>3</sup> If immediate reimplantation is not possible, the tooth should be kept in storage medium which helps the PDL cells to overcome the deleterious effects of trauma and nutritional deprivation till treatment is provided.<sup>4,5</sup> The periodontal ligament healing following reimplantation depends on amount of physical damage to root surface, the storage medium used and desiccation period.<sup>6,7</sup> Inflammatory or replacement resorption and pulpal necrosis could result following replantation of avulsed tooth.<sup>4</sup>

Storage media should have pH, osmolarity suitable for survival of PDL cells, provide nourishment and be free of bacteria and impurities.<sup>6</sup> Saliva, saline, milk, culture media, Viaspan, and Hank's Balanced Salt Solution (HBSS) (marketed

as Save-A Tooth), etc. have been used as storage media.<sup>4</sup> The media must also be easily available.

The aim of this study was to evaluate the efficacy of commercial pasteurized bovine milk, chicken egg white and coconut water as storage media for avulsed permanent tooth.

## ► Materials and methods

The present study was conducted on forty freshly extracted human maxillary and mandibular premolars indicated for extraction due to orthodontic reasons, with vital pulp and periodontal integrity. Teeth were extracted with forceps, as atraumatic as possible, to avoid the occurrence of root and bone fracture. The extracted teeth were dry stored for 10 minutes at room temperature and then transferred to labelled plastic flask containing 30.0 ml of the storage medium, with the aid of tweezer held by their crowns. The teeth were randomly divided into 3 experimental groups consisting of 10 teeth each: group I -Commercial pasteurized homogenized toned bovine milk; group II - chicken egg white, group III – fresh coconut water. To assess the damages caused by extraction, a control group was used, in which the teeth were extracted and immediately immersed in 10% neutral buffered formalin.

After a pre-established period of

60 minutes, the teeth in groups 1, 2 and 3 were washed with 0.9% saline solution and were immediately transferred to individual plastic flasks containing 30.0 ml of 10% neutral buffered formalin and stored for at least 48 hours for fixation.

**Laboratory processing**

After fixation, the specimens were washed in tap water and demineralized in 3% Nitric acid. The demineralization process was maintained for 15 – 20 days and then the teeth were sectioned into cervical, middle and apical thirds using bard parker blades. Tooth sections were submitted to dehydration, diaphanization and immersion in paraffin, for later inclusion in paraffin blocks. Semiserial sections of 6 micro meters thickness were made using microtome and stained with hematoxylin and eosin for light microscopy assessment with 20X and 40X magnification.

One section of each third was submitted to quantitative analysis and the number of cells in the periodontal ligament was quantified by morphometric analysis, by using a light microscope containing a square reticule using Image J software (W. Rasband, Research Services Branch, National Institute of Health, Bethesda, Maryland).

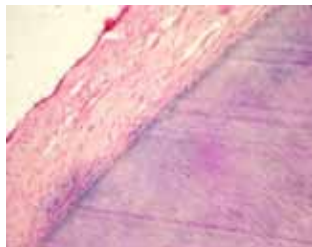
The mean number of cells in the periodontal ligament per mm<sup>2</sup> and respective standard deviations, observed for each group, were assessed and statistically analyzed by analysis of variance (Anova) followed by the Tukey test.

► **Results**

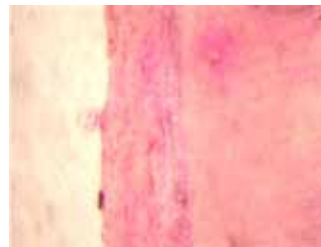
The mean number of cells in the periodontal ligament per mm<sup>2</sup> in Group I (commercial pasteurized bovine milk) was 3133.6080 cells/mm<sup>2</sup>, in Group II (chicken egg white)

**Table I** - Analysis of variance related to quantitative evaluation of the cells in the periodontal ligament between groups, provided by the different storage media.

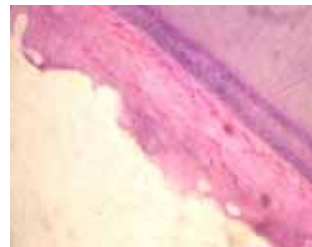Source of Variation	Sum of squares	Degrees of freedom	Mean square	F	Probability
Between Groups	19914530	3	6638176.762	42.645	Significant 0.001
Residue	5603756.1	36	155659.691		
Total	25518286	39			



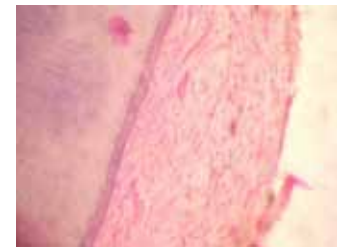
**Figure 1:** Microscopic view of periodontal ligament cells of tooth stored in commercial pasteurized homogenized toned bovine milk



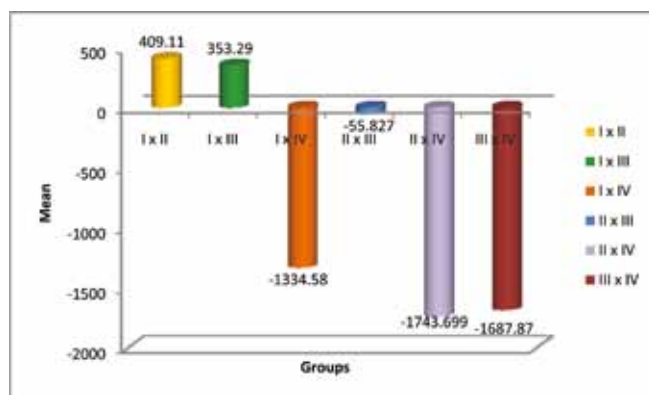
**Figure 2:** Microscopic view of periodontal ligament cells of tooth stored in chicken egg white



**Figure 3:** Microscopic view of periodontal ligament cells of tooth stored in coconut water



**Figure 4:** Microscopic view of periodontal ligament cells of tooth stored in 10% neutral buffered formalin



**Graph 1:** Inter group comparison

**Table II** - Individual comparisons between specimens of different groups as to the quantitative evaluation of the cells in the periodontal ligament, provided by the different storage media.

Group Comparison	Difference	Critical Value	p value
I x II	409.11	2.16	0.04
I x III	353.29	2.47	0.02
I x IV	-1334.58	6.85	0.001
II x III	-55.8270	0.35	0.72
II x IV	-1743.699	8.51	0.001
III x IV	-1687.87	10.38	0.001

Significance level: 0.05(p<0.05)



was 2724.4890 cells/mm<sup>2</sup>, in Group III (coconut water) was 2780.3160 cells/mm<sup>2</sup>, and in Group IV (control – 10% neutral buffered formalin) was 4468.1880 cells/mm<sup>2</sup>. Figure 1-4 shows the microscopic view of periodontal ligament cells of tooth stored in various storage media.

Table 1 shows Analysis of Variance related to quantitative evaluation of the cells in the periodontal ligament between groups, provided by the different storage media. The statistical result showed that the p - value was significant at 0.001 level. There was a significant difference in number of periodontal ligament cells among the groups.

Table 2 shows individual comparisons, after application of the Tukey test, between specimens of different groups as to the quantitative evaluation of the cells in the periodontal ligament, provided by the different storage media. When comparing Group I with Group II, Group III and Group IV they were all statistically significant in number of periodontal ligament cells. Also comparing the Group II with IV there was a statistical significant difference. But there was no statistical significance between Group II and Group III. Further comparing Group III with IV there was a significant difference. Graph I shows intergroup comparison of different groups as to the quantitative evaluation of the cells in the periodontal ligament in the study groups.

### ► Discussion

Traumatic injuries to orofacial region occurs more frequently in children and young adults.<sup>8</sup> Avulsion results from displacement of tooth out of alveolus due to dentoalveolar trauma and maxillary central incisors are frequently affected.<sup>9</sup> The best treatment for avulsed tooth is replantation which provides esthetics and function. As a sequelae root resorption can occur that compromises the prognosis.<sup>10</sup> Factors responsible for prognosis of avulsed tooth are lack of knowledge in providing emergency dental aid among parents and caregivers, time elapsed since injury, lack of storage media at the accident site, developmental stage of root and type of definitive treatment provided at the dental office.<sup>9,11</sup> The storage medium should have physiological osmolality and pH for maintaining viability and growth of PDL cells. The storage media should also be readily available.<sup>12</sup>

In the present study, after the extraction teeth were kept at room temperature for 10 minutes before immersion into the selected storage media. This was done to replicate the clinical condition of the time required to find a suitable storage medium. The storage time of 60 minutes was employed to simulate the extraalveolar time for replanted teeth.

The mean number of cells in the periodontal ligament per mm<sup>2</sup> in teeth stored in commercial pasteurized bovine milk was 3133.6080 cells/mm<sup>2</sup>, in chicken egg white was 2724.4890 cells/mm<sup>2</sup>, in coconut water was 2780.3160 cells/mm<sup>2</sup>, and in control – 10% neutral buffered formalin

was 4468.1880 cells/mm<sup>2</sup>. The results of the present study demonstrated statistically significant difference in number of cells per mm<sup>2</sup> between the groups. There was no significant difference between Group II and III. Teeth stored in pasteurized bovine milk showed number of periodontal ligament cells per mm<sup>2</sup>. Teeth stored in chicken egg white and coconut water had similar cellularity.

The results of this study was in accordance with study by Hugo Alexandre de Sousa et al. (2008),<sup>13</sup> comparing milk, egg white and artificial saliva which concluded that the maximum number of cells per mm<sup>2</sup> of periodontal ligament was shown by teeth stored in egg white and milk.<sup>13</sup> The American Association of Endodontists indicates milk as a storage media as it is capable of maintaining viability of PDL cells.<sup>15,16</sup> Various other studies also support the use of milk as preferred storage media.<sup>7,17,18,19,20,21</sup> Due to easy availability of milk, for uncomplicated avulsion cases, milk can be considered the best storage medium when compared with HBSS.<sup>22,23</sup> Milk as a storage medium can provide conditions that allows the PDL cells being less affected by the external medium.<sup>24</sup>

Milk has an osmolality (230–400 mOsm) that was not damaging to the cells<sup>24,25,26</sup> and has a pH around<sup>6,7,6,21</sup> The milk contains epithelial growth factor which would stimulate the action of osteoclasts in the prevention of ankylosis.<sup>6,19,20,21</sup> Nutritional substances like amino acids, carbohydrates and vitamins are also present in milk.<sup>17,19,21,24</sup>

In this study pasteurized homogenized toned milk was used, pasteurization might inactivate enzymes and removes bacteria that could be potentially harmful to the PDL.<sup>17,27</sup> The suitability of milk as a storage medium was further emphasized by its general availability.<sup>6,27</sup>

In the present study, teeth stored in chicken egg white were found to have less number of periodontal ligament cells as compared to teeth stored in bovine milk. Egg albumen appears to be a good choice because of the presence of albumen, vitamins, water, and is devoid of microbial contamination.<sup>28</sup> The present results disagree with the findings of another study by Abbas Ali Khademi et al. (2008),<sup>28</sup> comparing periodontal healing of replanted dog teeth stored in milk and egg albumen, in which egg albumen showed extremely high incidence of PDL healing when compared with milk. It could be explained that, the environment of socket between 24 and 48 hours might have resulted in surface reactions that interfered with the superior capacity of egg albumen to maintain the health of periodontal ligament cells.<sup>28</sup>

In the present study, the coconut water was less effective than commercial pasteurized bovine milk in maintaining the number of periodontal ligament cells. But in a study by Gopikrishna et al. (2008)<sup>4</sup>, coconut water as a storage medium demonstrated significantly more viable PDL cells than HBSS and milk. The electrolyte composition is similar to intracellular fluid. It has a high osmolality and is rich in many essential

amino acids, vitamins and minerals. Superior maintenance of viability of the PDL cells in the coconut water group may be due to the nutrients that are present in coconut water such as proteins, amino acids, vitamins, and minerals, which help in nourishing the cells and maintaining their viability.<sup>4</sup>

### ► Conclusion

Dental trauma is commonly seen among children. The treatment prognosis of avulsion would be better if the periodontal ligament cells can be preserved. Milk has been widely accepted as a storage medium due to its pH, osmolarity, nutrients and growth factors. More importantly, it is easily available also. Other media like egg white and coconut water can be used for storage of avulsed teeth.

### ► Reference

- Osman Sabuncuoglu. Traumatic dental injuries and attention – deficit/ hyperactivity disorder: is there a link? *Dental Traumatology* 2007; 23: 137 – 142.
- Flores MT, Andersson L, Andreassen JO, Bakland LK, Malmgren B, Barnett F, Bourguignon C, Di Angelis A, Hicks L, Sigurdsson A, Trope M, Tsukiboshi M and Von Arx T. Guidelines for the management of traumatic dental injuries. II. Avulsion of Permanent Teeth. *Dental Traumatology* 2007; 23:130-136.
- Geeta Hiremath and Krishnamurthy H. Kidiyoor. Avulsion and storage media. *Journal of Investigative and Clinical Dentistry* 2011; 2: 89–94.
- Velayutham Gopikrishna, Toby Thomas and Deivanayagam Kandaswamy. A quantitative analysis of coconut water: a new storage media for avulsed teeth. *Oral Surg Oral Med Oral Pathol Oral Radiol Endod* 2008; 105: e61-e65
- E Caglar, N Sandalli, OO Kuscü, MA Durhan, R Pisiriciler, E Ak Caliskan and B Kargul. Viability of fibroblasts in a novel probiotic storage media. *Dental Traumatology* 2010; 26: 383–387.
- André Dotto Sottovia, Dagoberto Sottovia Filho, Wilson Roberto Poi, Sônia Regina Panzarini, Danielle Shima Luize and Celso Koogi Sonoda. Tooth Replantation After Use of Euro-Collins Solution or Bovine Milk as Storage Medium: A Histomorphometric Analysis in Dogs. *J Oral Maxillofac Surg* 2010; 68:111-119.
- Roberta Pileggi, Thomas C. Dumsha and Jacques E. Nor. Assessment of post-traumatic PDL cell viability by a novel collagenase assay. *Dent Traumatol* 2002; 18: 186-189.
- Yixiang Wang, Gary Shun-pan Cheung, Xiangliang Xu, Shijie Zhao and Chengfei Zhang. The Effect of Cultured Autologous Periodontal Ligament Cells on the Healing of Delayed Autotransplanted Dog's Teeth. *J Endod* 2010;36:264–267.
- Mehmet Kemal Caliskan, Murat Turkun and Necmi Gokay. Delayed Replantation of Avulsed Mature Teeth with Calcium Hydroxide Treatment. *Journal of Endodontics* 2000; 26 (8): 472 – 476.
- Liliane Roskamp, Vania P.D. Westphalen, Everdan Carneiro, Luiz F. Fariniuk and Ulisses X. Silva Neto. The positive influence of atopy on the prognosis of avulsed and replanted teeth despite differences in post-trauma management. *J Endod* 2011; 37: 463 – 465.
- Huseyin Koca, Asli Topaloglu-Ak, Evren Sutekin and Olgu Koca, Sibel Acar. Delayed replantation of an avulsed tooth after 5 hours of storage in saliva: a case report. *Dental Traumatology* 2010; 26: 370–373.
- Monica M. Chamorro, John D. Regan, Lynne A. Opperman and Phillip R. Kramer. Effect of storage media on human periodontal ligament cell apoptosis. *Dental Traumatology* 2007: 1-6.
- Hugo Alexandre de Sousa, Ana Helena G. de Alencar, Kely Firmino Bruno, Aline Carvalho Batista and Antonio Cesar Perri de Carvalho. Microscopic evaluation of the effect of different storage media on the periodontal ligament of surgically extracted human teeth. *Dental Traumatology* 2008; 24: 628 – 632.
- Ji Young Hwang, Sung Chul Choi, Jae-Hong Park and Sang Wook Kang. The Use of Green Tea Extract as a Storage Medium for the Avulsed Tooth. *J Endod* 2011; 37: 962–967.
- Maria Claudia Baggio Gomes, Vania Portela Ditzel Westphalen, Fernando Henrique Westphalen, Ulisses Xavier da Silva Neto, Luis Fernando Fariniuk and Everdan Carneiro. Study of storage media for avulsed teeth. *Brazilian Journal of Dental Traumatology* 2009; 1 (2): 69-76.
- Robert M. Pearson, Frederick R. Liewehr, Leslie A. West, William R. Patton, James C. McPherson and Royce R. Runner. Human Periodontal Ligament Cell Viability in Milk and Milk Substitutes. *Journal Of Endodontics* 2003; 29 (3):184-186.
- Thomas G. Marino, Lesley A. West, Frederick R. Liewehr, Jason M. Mailhot, Thomas B. Buxton, Royce R. Runner and James C. McPherson. Determination of Periodontal Ligament Cell Viability in Long Shelf-Life Milk. *Journal Of Endodontics* 2000; 26 (12): 699-702.
- Moreira-Neto J. J. S, Gondim J. O, Raddi M. S. G and Pansani C. A. Viability of human fibroblasts in coconut water as a storage medium. *International Endodontic Journal* 2009; 42: 827–830.
- Beatriz Dulcinea Mendes Souza, De'borá Denardin Luckemeyer, Wilson Tadeu Felipe, Claudia Maria Oliveira Simoes and Mara Cristina Santos Felipe. Effect of temperature and storage media on human periodontal ligament fibroblast viability. *Dental Traumatology* 2010; 26: 271–275.
- Ana Regina Casaroto, Mirian Marubayashi Hidalgo, Ana Maria Sell, Selma Lucy Franco, Roberto Kenji Nakamura Cuman, Eduardo Moreschi, Fausto Rodrigo Victorino, Vania Antunes Steffens and Ciomar Aparecida Bersani-Amado. Study of the effectiveness of propolis extract as a storage medium for avulsed teeth. *Dental Traumatology* 2010; 26: 323–331.
- Souza B. D. M, Luckemeyer D. D, Reyes-Carmona J. F, Felipe W. T, Simoes C. M. O and Felipe M. C. S. Viability of human periodontal ligament fibroblasts in milk, Hank's balanced salt solution and coconut water as storage media. *International Endodontic Journal* 2011; 44, 111–115.
- Trope M. Clinical management of the avulsed tooth. *Dent Clin North Am* 1995; 39 (1): 93-112.
- Lekic P. C, Kenny D. J and Barrett E. J. The influence of storage conditions on the clonogenic capacity of periodontal ligament cells: implications for tooth replantation. *International Endodontic Journal* 1998; 31: 137–140.
- Brian D. Olson, Jason M. Mailhot, Ronald W. Anderson, George S. Schuster and Norman Weller R. Comparison of Various Transport Media on Human Periodontal Ligament Cell Viability. *Journal of Endodontics* 1997; 23 (11): 676 – 679.
- Claudia Leticia Vendrame dos Santos, Celso Koogi Sonoda, Wilson Roberto Poi1, Sonia Regina Panzarini, Maria Lucia Marcal Mazza Sundefeld and Marcia Regina Negri. Delayed replantation of rat teeth after use of reconstituted powdered milk as a storage medium. *Dental Traumatology* 2009; 25: 51–57.
- Patil S, Dumsha T.C and Sydskis R.J. Determining periodontal ligament (PDL) cell vitality from exarticulated teeth stored in saline or milk using fluorescein diacetate. *International Endodontic Journal* 1994; 27: 1-5.
- Ashkenazi M, Sarnat H and Keila S. In vitro viability, mitogenicity and clonogenic capacity of periodontal ligament cells after storage in six different media. *Endod Dent Traumatol* 1999; 15: 149-156.
- Abbas Ali Khademi, Adnan Atbaee, Seyed-Mohammad Razavi and Mitra Shabani. Periodontal healing of replanted dog teeth stored in milk and egg albumen. *Dental Traumatology* 2008; 24: 510–514.

# Comparative Study of pulse rate and behavioural anxiety reactions in children during skin prick test with local anesthetic solution under different clinical settings

\*Lekshmy S.R. Nair, \*\*Anandaraj S, \*\*\* Sageena George

## Abstract

**Purpose:** The aim of this study was to compare children's pulse rate and behavioural anxiety reactions when receiving skin prick test with the local anaesthetic prior to its administration, under different clinical settings.

**Method:** This observational study was conducted among 84 children, of age 7-9 years, divided into 2 groups and skin prick test for local anesthesia was performed in the first group in a well set pedodontic clinic and for the second group in the medical OP Department. The change in the anxiety level between the two groups was assessed by considering pulse rate values and Venham's Clinical Rating Scale. Statistical analysis was by Mann-Whitney U Test.

**Results:** The pulse rates as well as the behavioral anxiety levels in children were reduced in the pedodontic clinical settings than in the medical OP Department. Result was statistically significant for a probability level of  $p < 0.05$ .

**Conclusion:** We can utilize various distraction aids present in our clinic for reducing the anxiety of a child who needs a local anesthesia test dose administration prior to being injected.

**Keywords:** Distraction, First dental visit, Pedodontic clinic, Pulse rate, Skin prick test, Venham's Clinical Rating Scale.

## ► Introduction

Local anaesthesia forms the backbone of pain control techniques in dentistry and has a major role in dentistry for children. A Pedodontist will often be the first caregiver to administer local anesthesia for a child, which necessitates the importance of giving test dose for ruling out allergic reactions. Administration of test dose may create anxiety among children about further treatment procedure. Since children who showed signs of initial anxiety are likely to display more disruptive behaviours during the later stage of the procedure, it is necessary to find out a suitable clinical setting for carrying out the local anaesthetic skin prick test.

The aim of this study was to compare children's pulse rate and behavioural anxiety reactions when receiving skin prick test with the local anaesthetic prior to its administration, thus to offer a suitable setting for the performance of skin allergy test which would create minimal apprehension in children on future dental visits.

## ► Materials and methods

This observational study was conducted among 84 children, of

age 7-9 years, who reported in the Outpatient Department of Pedodontics and Preventive Dentistry, PMS College of Dental Science and Research, Trivandrum. The following were the inclusion criteria.

### Inclusion criteria:

- Parents and children willing to participate in the study, with no prior dental history.
- Children having no history of systemic or psychological diseases.
- Children exhibiting Frankl 2 or 3 behaviour pattern during the initial full mouth prophylaxis session.

### Exclusion criteria:

- Parents and children not willing to participate in the study.
- Children having a history of systemic or psychological diseases.
- Children not exhibiting Frankl 2 or 3 behaviour pattern during the initial full mouth prophylaxis session.

Consent was initially obtained from the Institutional Ethical Committee of

\* Post Graduate Student, \*\*Professor, \*\*\*Professor and Head of the Department, Department of Pedodontics and Preventive Dentistry, PMS College of Dental Science and Research, Vattapara, Thiruvananthapuram  
• Corresponding Author: Dr Lekshmy S.R. Nair, E-mail: lekshmysrnair@gmail.com

PMS College of Dental Science and Research, Trivandrum and also from the Parents/Guardian of all children, ensuring the confidentiality of the personal details of the respective individual.

**Study procedure**

Children were introduced to dentistry through full mouth prophylaxis with a rubber cup in a slow-speed hand piece, during which their behaviour pattern was assessed. Only those who exhibited Frankl 2 or 3 type of behaviour were selected for study. This group was then randomly divided into 2 groups, each group having almost equal number of boys and girls.

Before the first session of treatment with local anesthesia injection, Skin prick test (SPT) was performed in the first group in the forementioned pedodontic clinic with audiovisual distraction aids and for the second group in the medical OP Department without audiovisual distraction aids, by trained personnels.

**SPT Procedure:**

The location of test solution administration was marked with a pen as shown in figure 1.

Tests was performed on the volar aspect of the forearm,

at least 2 – 3 cm from the ante cubital fossae. A drop of test solution was placed on the skin and immediately pricked. A single-head metal lancet was the preferred testing instrument for SPT. It was pressed through the drop of test solution held against the skin for at least 1 second as shown in figure 2.

The epithelial layer of the skin was penetrated without inducing bleeding. Excess solution from drops on the skin was blotted using a clean tissue.

The anxiety level was assessed immediately before and after test dose administration using Venham’s Clinical Anxiety Rating Scale (VCRS) with the scores are assigned as in table I.

Simultaneously, the pulse rate was also measured by using a finger tip pulse oximeter as in figure 3. The change in the anxiety level between the two groups was assessed by considering pulse rate values and Venham’s Clinical Rating Scale. To be more precise, these reactions were recorded by those who were unaware of the philosophy of the research.

**Statistical analysis**

Analysis strategy was by non-parametric method by using Mann-Whitney U Test. Result was statistically significant for a probability level of  $p < 0.05$ .

<p><b>0 = Relaxed: smiling, willing, able to converse, displays behavior desired by the dentist</b></p> <p><b>1 = Uneasy: concerned, may protest briefly to indicate discomfort, hands remain down or partially raised. Tense facial expression. 'high chest'. Capable of cooperating</b></p> <p><b>2 = Tense: tone of voice, questions and answers reflect anxiety. During stressful procedure, verbal protest, crying, hands tense and raised, but not interfering very much. Protest more distracting and troublesome. Child still complies with request to cooperate.</b></p> <p><b>3 = Reluctant: pronounced verbal protest, crying. Using hands to try to stop procedure. Treatment proceeds with difficulty.</b></p> <p><b>4 = Interference: general crying, body movements sometimes needing physical restraint. Protest disrupts procedure</b></p> <p><b>5 = Out of contact: hard loud swearing, screaming unable to listen, trying to escape. Physical restraint required</b></p>
---

Table 1

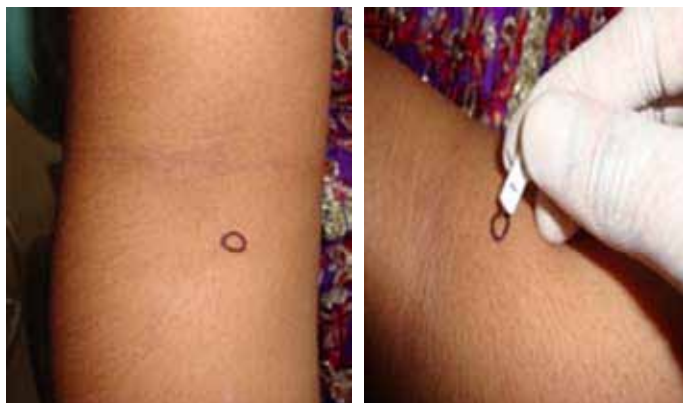

Fig. 1 & 2 Performing Skin Prick test in the child

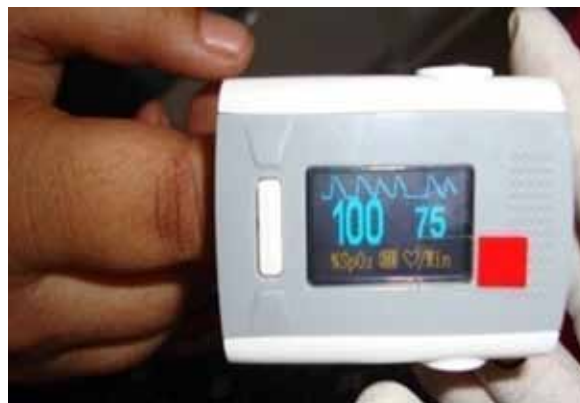

Fig. 3 Checking the pulse rate using pulse oximeter

► **Results**

The pulse rates as well as the behavioral anxiety levels in children were reduced in the pedodontic clinical settings than

in the medical OP Department. The values are depicted in the form of histograms as in figure 4, figure 5, figure 6 and figure 7.

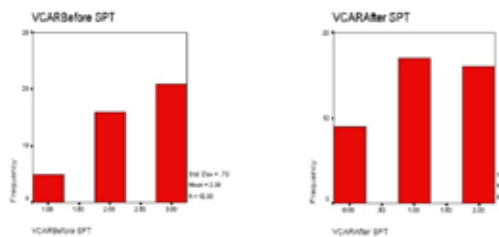


Fig. 4 Venhams Clinical Anxiety Rating Scores in the medical OP




Fig. 5 Venhams Clinical Anxiety Rating Scores in the pediatric dental settings




Fig 6 Pulse rate values in the medical OP




Fig. 7 Pulse rate values in the pediatric dental settings

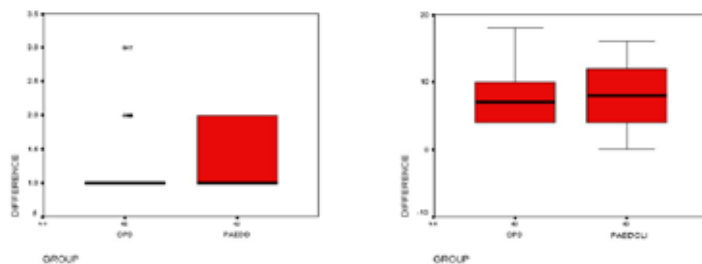


Fig. 8 Situation 1

Situation 2

When the pre and post anxiety values were compared from situation 1 (using Venhams Clinical Anxiety Rating Scale) and situation 2 (using pulse rate values), greater reduction in post anxiety level was found in the pediatric dental settings as in figure 8.

### ► Discussion

Making good memories for children during dental visits is one of the most important aims of pediatric dentistry. Dental anxiety and fear-related behaviors associated with dental injections are undoubtedly among the most challenging aspects of pediatric dentistry, and proper intraoral local anesthesia is the mainstay of pain control during dentistry procedures.<sup>1</sup>

The inherent use of local anaesthetic injections allows practitioners to use them frequently with the confidence that adverse events, ranging from urticaria, dermatitis to toxic reactions like anaphylaxis, are rare.<sup>2,3,4,5</sup> Patients, with a history of allergy to a local anesthetic, who cannot identify the specific agent used, present a problem. The patient should be referred for evaluation and testing, which will usually include both skin testing and provocative dose testing (PVT).<sup>7</sup>

Behavioural pain reaction ratings by direct observation, reports from the child or accompanying parent and physiological measures are three main techniques that could be used to assess dental fear and behaviour management problems during the skin prick test.<sup>6</sup> Venham's Clinical Anxiety Rating Scale (VCRS) is used to measure the situational anxiety of the child by the clinician. It is a six-point scale, with scale points anchored in objective, specific and readily-observable behaviour. Reports from accompanying parents are not emphasized since their opinion will be dependent on their age, social status and educational qualifications. The objective measurement of fear can be done by measuring the pulse rate using a fingertip pulse oximeter. Pulse rate is a direct measure of physiological arousal and its increase is attributed to stress during dental procedures because of which it is an index of patient's response to dental stimuli.

As far as pediatric dental settings is considered, distraction during an injection has always been a technique to avert

discomfort and negative feelings about that procedure as well as the entire dental appointment.<sup>7</sup> Introduction of distraction conditions was associated with higher calm behavior and less fine and gross movement, suggesting significant calming effects of the distraction conditions.<sup>8</sup> In an ideal pedodontic clinical setting, this could be easily achieved by the display of cartoons, toys, the music played in the clinic etc. An additional well standard method is for dentists to speak to patients as they work so that patients pay attention to them rather than focusing on the treatment procedure.<sup>9</sup>

### ► Conclusion

The practice of modern pediatric dentistry requires delivery of quality care in combination with adherence to excellent management principles. We can utilize various distraction aids present in our clinic for reducing the anxiety of a child who needs a local anesthesia test dose administration prior to being injected. Further studies are needed to check the reliability of the skin prick test performed as such standards are likely to improve the quality of patient diagnosis and care.

### ► References

1. Porritt J, Marshman Z, Rodd HD. Understanding children's dental anxiety and psychological approaches to its reduction. *Int J Paediatr Dent.* 2012;22: 397-405.
2. Malamed SF. *Hand-book of Local Anesthesia.* 5th ed. St. Louis, Mo: Mosby; 2004. Pharmacology of vasoconstrictors; pp. 41-54.
3. Jeske AH, Blanton PL. Misconceptions involving dental local anesthesia. Part 2: Pharmacology. *Tex Dent J.* 2002;119:310-4.
4. Malamed SF. *Handbook of Local Anesthesia.* 5th ed. St. Louis, Mo: Mosby; 2004. Local complications; pp. 285-7.
5. Haas DA. An update on local anesthetics in dentistry. *J Can Dent Assoc.* 2002;68: 546-51.
6. Arif-Rahu M, Fisher D, Matsuda Y. Biobehavioral measures for pain in the pediatric patient. *Pain Manag Nurs.* 2012;13:157-68.
7. Wilson S. Local anesthesia and oral surgery in children. In: Casamassimo PS, Fields HW, McTigue DJ, Nowak AJ, editors. *Pediatric Dentistry: Infancy Through Adolescence.* 5th ed. St. Louis: Elsevier Saunders; 2013. pp. 398-410.
8. Debajyoti Pati. Influence of Positive Distractions on Children in Two Clinic Waiting Areas. *Health Environments Research & Design Journal* 2011. Vol. 4, No. 3.
9. Milgrom P, Coldwell SE, Getz T, Weinstein P, Ramsay DS. Four dimensions of fear of dental injections. *J Am Dent Assoc.* 1997;128:756-66.

# A case report on PAOO; A recourse for conventional orthodontic treatment

\* Mahesh Raj V.V., \*\* Anil Melath, \*\*\* Subair K., \*\*\*\* Mohammed Feroz T.P.

## Abstract

Periodontally accelerated osteogenic orthodontics (PAOO) is a clinical procedure that combines alveolar corticotomy, particulate bone grafting, and the application of orthodontic forces. This is theoretically based on the bone healing pattern known as the regional acceleratory phenomenon (RAP). PAOO results in an increase in alveolar bone width, shorter treatment time, increased post-treatment stability, reduced chances of relapse and decreased amount of apical root resorption.

KDJ 2017 | Vol. 40 | No. 4 | Pg 203-206

## ► Introduction

The increase in adult patients seeking for orthodontic treatment has progressed the use of Wilckodontics. Wilckodontics is the procedure by which teeth can be moved approximately 4 times faster than ever before possible with conventional orthodontics, due to which the treatment duration can be reduced to 3–9 months rather than 18–31 months.

The difficulty in adult orthodontics is due to the shut down of dento-alveolar development after adolescence, less vascular periodontal membrane which is accountable for increased rate of root resorption, increased chances of hyalinization and non flexible alveolar bone.

The healing pattern used here is RAP otherwise known as Regional Acceleratory Phenomenon which brings about easy tooth movement in a minimal duration. What happens here is, on to the surgically scarred alveolar bone (both lingually and labially) graft material is placed which later deposits calcium and new bone begins to mineralize in 20–55 days. Alveolar bone, in this transient state, being soft and less resistant to force of orthodontic braces, allows teeth to be moved very quickly.

## ► History

Surgically assisted orthodontic tooth movement has been used since the 1800s. Corticotomy-facilitated tooth movement was first described by L.C. Bryan in 1893, published in a textbook by S.H. Guilford<sup>4</sup>. In the past 50 years, rapid tooth movement without significant root resorption has been reported. The current corticotomy procedures are based on Heinrich Köle's combined radicular corticotomy first described in 1959<sup>4</sup>.

Wilcko et al further modified the corticotomy-assisted orthodontic technique with the addition of alveolar augmentation and patented the procedure as periodontally accelerated osteogenic orthodontics (PAOO).<sup>2</sup>

## ► Case selection

People of any age, provided their periodontal status is healthy and no systematic contraindications present.

## ► Indications<sup>3</sup>

1. Class I malocclusions with moderate to severe crowding
2. Class II malocclusions requiring expansion or extraction.
3. To accelerate canine retraction after premolar extraction
4. To enhance post orthodontic stability
5. To facilitate the eruption of impacted teeth
6. In molar intrusion and open bite correction
7. To facilitate slow orthodontic expansion

## ► Contraindications<sup>3</sup>

1. Patients with dental bone loss or gingival recession
2. Root damage or poor roots.
3. Patients having disease like rheumatoid arthritis which requires regular doses of NSAIDs.
4. Class III condition, in which the lower jaw is too long relative to the rest of the face and chin protrudes.
5. Patients who are on bisphosphonate therapy\* (slows down bone metabolism)
6. Patients with compromised width of attached gingiva.

\* PG Student, \*\*Principal, \*\*\*Reader, \*\*\*\*Professor, Dept. of Periodontics, Mahe Institute of Dental Sciences & Hospital. Mahe.  
• Corresponding Author: Dr. Mahesh Raj V.V., E-mail: drraj83@gmail.com

### Advantages

1. Speedy treatment
2. More intact periodontium
3. Reduced need for extraction or orthognathic surgeries
4. Less pain during adjustments

### Disadvantages<sup>3</sup>

1. Expensive.
2. Mildly invasive and carries its own risk
3. Possibility of infection
4. Cannot be used in patients with uncontrolled osteoporosis or other bone diseases.

### Technique

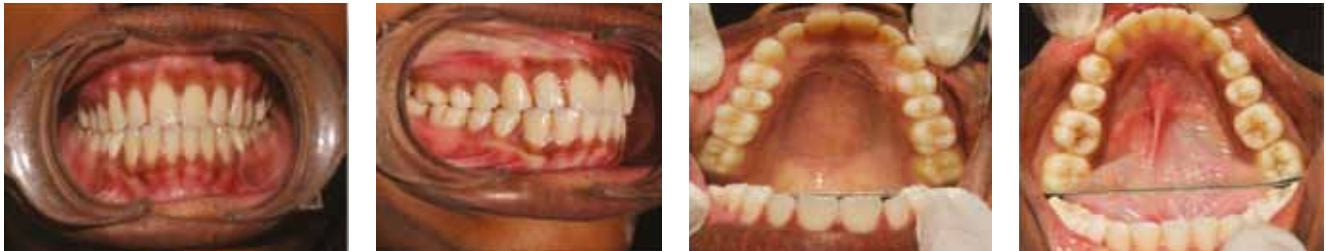1. Flap Design<sup>3</sup>

The objectives of the flap design are to

- 1) provide access to the alveolar bone
- 2) provide for coverage of the particulate graft
- 3) maintain the height and volume of the interdental tissues
- 4) enhance the esthetic appearance of the gingival form where necessary.

The basic flap design is a combination of a full thickness flap in the most coronal aspect of the flap with a split-thickness dissection performed in the apical portions. The purpose of the split-thickness dissection is to provide mobility of the flap so that it maybe sutured with minimal tension. Extending at least up to 2 teeth beyond the area to be corrected. Flaps reflected beyond the apices of the teeth. Care should be taken not to damage any of the neurovascular bundle nor muscle attachments.

Pre- Operative view:



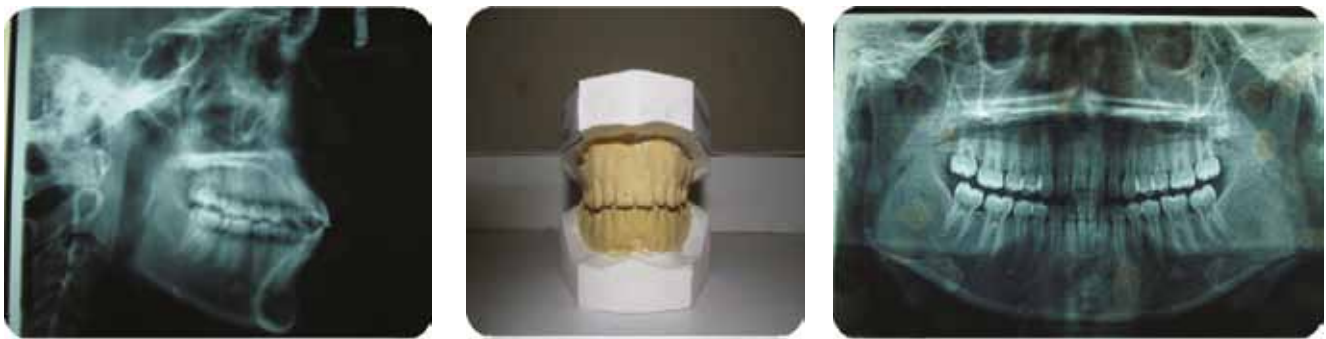Facial view

Lateral view

Palatal view

Lingual view

Investigations:

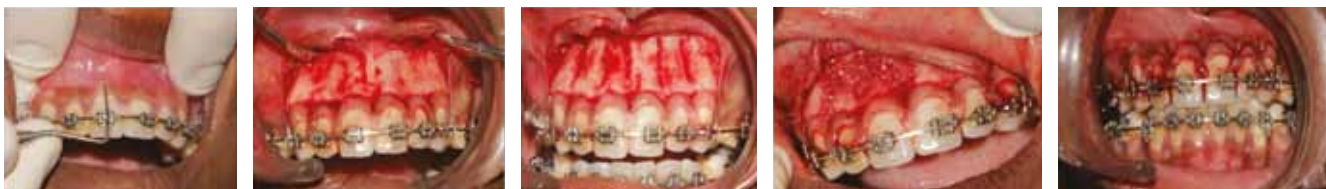

Lateral Cephalogram

Cast Model

Ortho pantomograph

Surgical Procedures: INTRA OPERATIVE [ MAXILLA]



Pre operative clinical evaluation of Gingiva

Reflection of Full thickness Flap

Vertical Corticotomies using No.2 carbide bur

Particulate Grafting using DFDBA bone graft

Interrupted Suture



2. Decortication<sup>3</sup>: refers to removal of cortical portion of alveolar bone. Purpose of this being initiation of RAP and not mere creation of movable bone segments. Vertical decortications of bone adjacent to the problematic area is done. Inadvertent perforation of maxillary sinus and mandibular canine to be prevented. Solitary perforations are placed in the alveolar bone to increase the blood supply to the graft material only when there is sufficient thickness of alveolar bone, however if the thickness is less than 2mm, perforations are to be omitted to ensure no damage to the radicular surface.

3. Particulate grafting<sup>3</sup>: materials that are used are deproteinized bovine bone, autogenous bone, decalcified freeze dried bone graft or a combination of above. The amount of material to be used is determined by the direction and tooth movement predicted.

4. Closure techniques: Primary closure of the gingival flaps to be done without excessive tension. These are typically achieved with nonresorbable interrupted sutures. The specific

suture used is determined by the thickness of the tissue. The sutures that approximate the tissues at the midline are placed first to ensure the proper alignment of the papillae. The remaining interproximal sutures are placed next, followed by the closure of any vertical incisions. No packing is required. The sutures are usually left in place for 1 to 2 weeks.

► **Case Report**

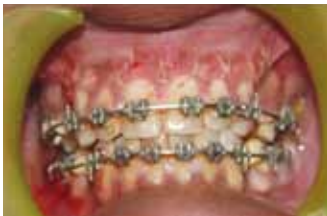A 17 year female patient was referred to our Department of Periodontology by Department of Orthodontics of Mahe Dental College & Hospital to perform Periodontally accelerated osteogenic orthodontic treatment.

After evaluating history of the patient, explaining the treatment protocol a informed consent was taken from the patient and the treatment plan was formulated.

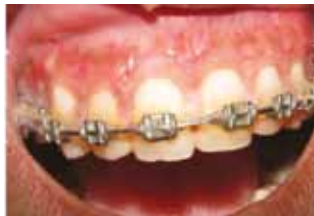► **Discussion:**

In this case, ideal esthetic and functional results were achieved around 1 year. According to Hajii, an average

POST OPERATIVE VIEW:

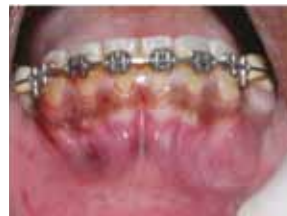

1 Week post operative view

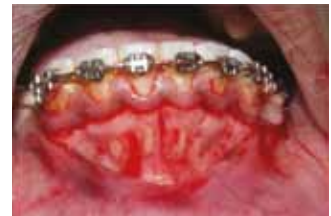

2 Week post operative view

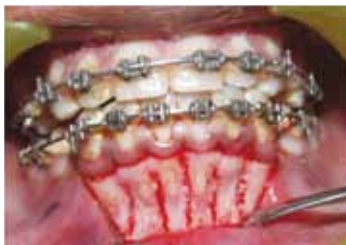INTRAOPERATIVE [ MANDIBLE].....



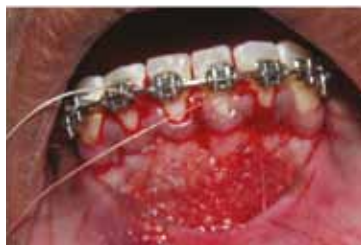Pre operative clinical evaluation of gingiva



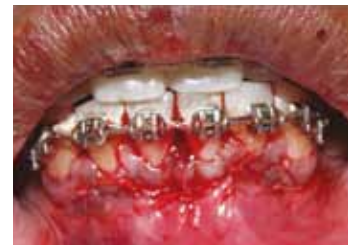Reflection of full thickness flap



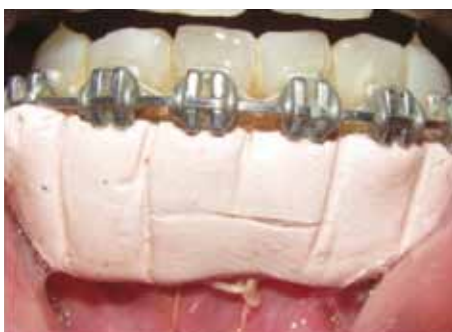Vertical corticotomies using no.1 carbide burr



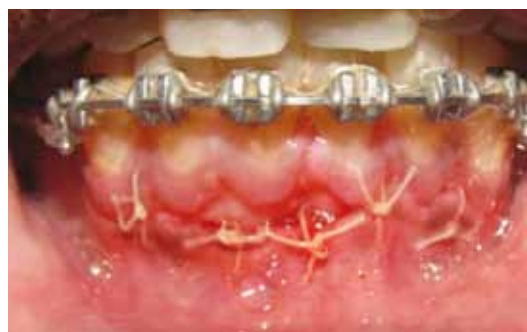Particulate Grafting using DFDBA bone graft



Interrupted sutures given



Periodontal dressing given



1 week post operative

treatment time is one third to one fourth of normal orthodontic treatment<sup>7</sup>. Wilko et al given an average treatment time for PAOO is 6, months<sup>1</sup>. Corticotomy was performed only at the buccal aspects of alveolar bone. The elimination of palatal and lingual corticotomy reduces the length and the extent of surgery and avoid the risk of violating vital lingual anatomy<sup>1</sup>. Intramembranous autogenous bone graft have been used in restoration of osseous volume as the gold standard of ridge construction. Facial tipping of incisors can result in thinning of alveolar bone, thickness of maxillary and mandibular buccal plates was not increased, a sound alveolar configuration was maintained<sup>1</sup>. This results may be partially attributed to the autogenous bone graft. More clinical research should be undertaken to determine the optimal amount of autogenous bone graft.

### ► Conclusion

Research into corticotomy assisted orthodontics is still in its infancy. There is a need to move away from the case reports and case series of the present and future research should focus on well designed and executed, randomised, clinical trials. Specific questions which need answers are related to loss of anchorage, the stability of results, possible reduction in root resorption and, of course, further confirmation that the rate of tooth movement is indeed increased.

PAOO is an effective treatment approach in adults to decrease treatment time and reduce the risk of root resorption.<sup>1</sup>

Surgical approach limiting the corticotomy to the buccal and labial aspects produced the RAP needed to significantly reduce treatment time. The reduction of surgery time, patient discomfort and reduced chances of relapse are basic advantages to a modified surgical approach. More clinical research is needed to determine the optimal amount of autogenous bone graft as well as the superiority of one graft material over the others.

### ► References

1. Periodontally Accelerated Osteogenic Orthodontics Combined with Autogenous Bone Grafting HessamNowzari, DDS, PhD;1 Frank Kazuo Yorita, DDS;2 and Hsuan-Chen Chang, PhD, DDS3.
2. Periodontally accelerated osteogenic orthodontics presentation by Dr. RavikanthLakkakula.
3. Periodontally Accelerated Osteogenic Orthodontics-A Review by Dr. Manikandan G.R (Junior Resident) Dr. Presanthila Janan (Professor & HOD, Principal Department of Periodontics) Government Dental College Trivandrum.
4. Periodontally Accelerated Osteogenic Orthodontics- The Past and the Future by Dr.VirangiSagane,Dr. Suresh Kangane, Dr.AnandAmbekar, Dr. PraveenkumarMarure,Dr. Yatish Joshi, Dr.ChaitanyaKhanapure.
5. Kocadereli I. Changes in soft tissue profile after orthodontic treatment with and without extractions. Am J OrthodDentofacialOrthop2002;122(1);67-72.
6. KoleH. Surgical operations on the alveolar ridge to correct occulsalabnormalities. OralSurg Oral Med Oral Pathol.1959; 12(5);515-529.
7. Hajji S.S. The influence of accelerated osteogenic responses on mandibular de crowding [thesis]. St. LouisMO;St. Louis University: 2000.

## New research discovers way to eliminate needles for dental anesthetic

The new procedure could save dentists time and money, and alleviate patient anxiety.

It may be scary to get into the dentist's chair, but thanks to new research, there's one thing uneasy patients might not have to worry about anymore: needles. A new study from the University of São Paulo found that there might be no need for needles when administering anesthetic for dental procedures. Instead, dentists could use a small electric current to give the anesthetic, saving time, money and unnecessary patient anxiety—which could potentially get more patients into the chair for procedures they might otherwise avoid because of a fear of needles. “Needle-free administration could save costs, improve patient compliance, facilitate application and decrease the risks of intoxication and contamination,” explained study author Professor Renata Fonseca Vianna Lopez of the University of São Paulo. “This may facilitate access to more effective and safe dental treatments for thousands of people around the world.”

# Guided bone regeneration and two stage implant surgery for anterior single tooth replacement

\* Tessa Paul, \*\* Remya Karingattil Sasidharan, \*\*\*Angel Jacob

## Abstract

The use of dental implants have become a more popular and acceptable mode for replacement of missing teeth in current dental practice. But presence of adequate bone volume is an important prerequisite for the long term success of implant therapy. So insufficient bone volume can limit the use of dental implants in many patients. Ridge augmentation procedures have gained popularity to help these scenarios. Guided Bone Regeneration (GBR) is a reliable ridge augmentation technique for obtaining bone formation and placing dental implants in cases where it would otherwise not be possible. The predictability of GBR techniques has increased the number of implant candidates and has facilitated prosthetically driven restorations.

KDJ 2017 | Vol. 40 | No. 4 | Pg 207-211

## ► Introduction

Advancement in the field of dentistry offers numerous vistas to improve oral health and wellbeing. Dental implants assure an advanced treatment option for the patients by providing a more stable, predictable, esthetically pleasing long term solution for their lost natural dentition.

Sufficient alveolar bone volume and favorable architecture of the alveolar ridge are essential to obtain ideal functional and esthetic prosthetic reconstruction following implant therapy<sup>1</sup>. A lack of horizontal and/or vertical bone in implant sites may cause major clinical problems<sup>2</sup> and needs to be corrected prior to implant placement. To regenerate enough bone for successful implant placement, a ridge augmentation technique is often required. One technique of ridge augmentation is Guided Bone Regeneration (GBR)<sup>3</sup>. GBR should be considered a reliable technique for obtaining bone formation and placing dental implants in cases in which it would otherwise not be possible<sup>4</sup>. GBR evolved from guided tissue regeneration (GTR) techniques directed toward regenerating tissues in osseous defects adjacent to natural teeth<sup>5</sup>. GBR is a surgical procedure that uses barrier membranes with or without particulate bone grafts or bone substitutes. Osseous regeneration by GBR depends on the migration of pluripotential and osteogenic cells (e.g. osteoblasts derived from the periosteum and/or adjacent bone and/or bone marrow) to the bone defect site and exclusion of cells impeding bone formation (e.g. epithelial cells and fibroblasts). To accomplish the regeneration of a bone defect, the rate

of osteogenesis extending inward from the adjacent bony margins must exceed the rate of fibrogenesis growing in from the surrounding soft tissue<sup>6</sup>. To ensure successful GBR, four principles need to be met: exclusion of epithelium and connective tissue, space maintenance, stability of the fibrin clot, and primary wound closure<sup>7</sup>.

There are two approaches of GBR in implant therapy: GBR at implant placement (simultaneous approach) and GBR before implant placement to increase the alveolar ridge or improve ridge morphology (staged approach). The size and type of each particular osseous defect influence the selection of the most suitable grafting procedure<sup>3</sup>. The case report in this article used a staged approach to replace a missing tooth in the maxillary esthetic zone.

## ► Case presentation

A 45 year old male patient came to the department with a chief complaint of loose maxillary partial denture in relation to 21. Patient lost his tooth due to trauma 10 years back was using a partial denture since then (Fig 1). Patient was not comfortable with the current prosthesis and wanted to replace the removable prosthesis with a fixed one. So the patient was given the options of a fixed partial denture and implant prosthesis. Since

\* Assistant Professor, Dept. of Dentistry, Government Medical College, Ernakulam; \*\*Assistant Professor, Dept of Periodontics, Al Azhar Dental College, Muvattupuzha; \*\*\*Professor, Dept. of Periodontics, Amrita Institute of Medical Sciences, Kochi • Corresponding Author: Dr. Tessa Paul, E-mail: drtessapaul@gmail.com

fixed partial denture compromises the adjacent teeth and the tooth to be replaced was in the esthetic area he decided to go for an implant. Detailed history was taken and the significant findings included the history of type II diabetes mellitus since 2 years for which he was under medication and the patient is a former smoker, stopped smoking since 5 years. The case was discussed in detail including the alveolar bone volume and risk factors. The patient's glycemic level were under control and there was no family history of diabetes mellitus. Since the patient was a former smoker he was educated regarding the risk of smoking on the implant prosthesis.

The alveolar bone volume was found to be inadequate when measured clinically using a bone gauge and by assessing an orthopantomogram (Fig 2). The factors that the area is edentulous since 10 years and the long term use of partial denture may be attributable to the deficiency in alveolar bone volume. So we planned for a ridge augmentation procedure with GBR followed by two stage implant therapy.

After routine blood examinations and thorough supragingival and subgingival scaling, we scheduled for the ridge augmentation procedure. An informed consent was signed by the patient. Preparation of perioral tissues were done using betadine (10 % povidone – Iodine) solution and the patient was asked to rinse the oral cavity with 0.12% chlorhexidine mouth wash for 1 minute. Local anesthesia was achieved using 2% lignocaine infiltration with 1:80000 adrenaline. A remote incision was placed palatal to alveolar ridge in relation to 21 to minimize the incidence of bone graft exposure during ridge augmentation. Vertical incisions were placed on the mesial aspect of 11 and 22 (Fig 3). A full thickness trapezoidal flap was reflected in relation to 11, 21 and 22 (Fig 4).

Decortication of labial bone was done in relation to 21 using a round bur with continuous saline irrigation (Fig 5). The bone defect was then filled with demineralized bone matrix (xenograft) (Fig 6) and a resorbable type I collagen membrane (bovine origin) was placed over the graft. The flaps

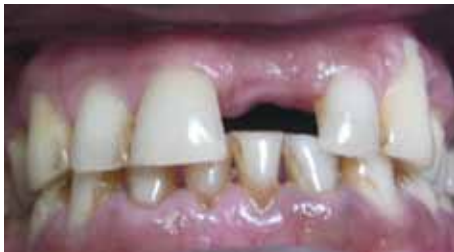

Fig. 1 Preoperative view-Edentulous area in relation to 21

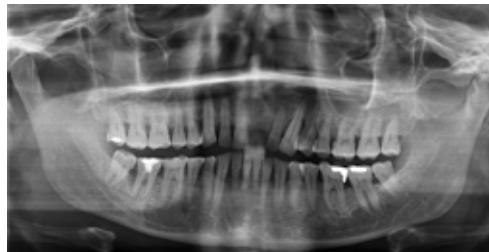

Fig. 2 Preoperative OPG showing missing 21

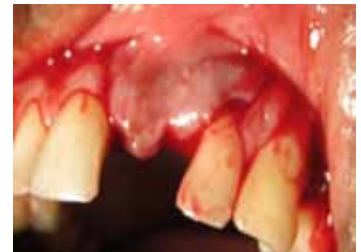

Fig. 3 Remote incision placed. Vertical incisions placed on the mesial aspect of 11 and 22

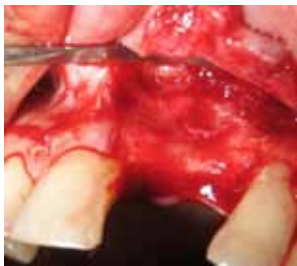

Fig. 4 Full thickness trapezoidal flap reflected in relation to 11, 21 and 22

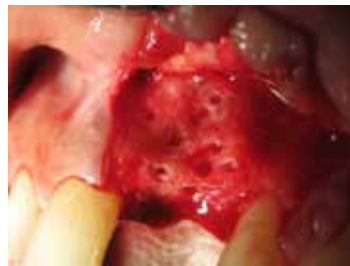

Fig. 5 Decortication done with round bur in relation to 21 region. Bleeding induced

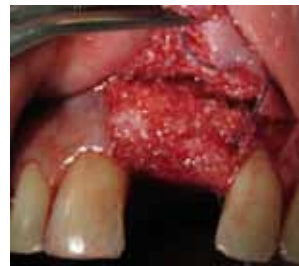

Fig. 6 Demineralized bone matrix [xenograft] placed in relation to 21 region

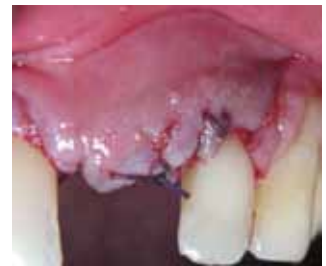

Fig. 7 Guided bone regeneration using resorbable type 1 collagen membrane (bovine origin). Resorbable sutures placed with 3-0 vicryl

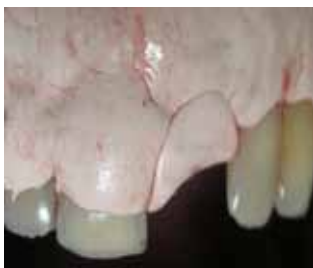

Fig. 8 Non eugenol pack placed

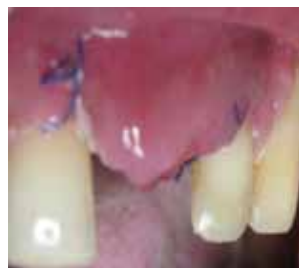

Fig. 9 1 week post-operative view

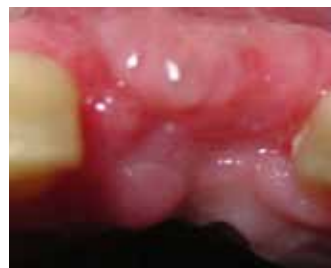

Fig. 10 3 weeks post-operative view

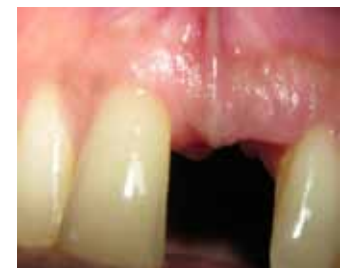

Fig. 11 3 months post-operative view

were approximated with resorbable 3-0 vicryl sutures (Fig 7). To protect the surgical site non eugenol pack was placed (Fig 8). Post operative instructions were given including soft diet and maintenance of proper oral hygiene. Patient was also refrained from using partial denture for a minimum of 2 weeks to avoid pressure on the wound during the early healing phase. Antibiotics, analgesics, serratiopeptidase and mouth wash were prescribed.

Patient was on regular follow ups at 1 week, 3 weeks, 3 months and 6 months (Fig 9, 10, 11, 12). The post operative healing and patient's oral hygiene status were satisfactory. The diabetic levels were under control and patient never

resumed smoking. So we decided to move forward with the two stage implant prosthesis in relation to 21. Bone mapping was done to determine the size of implant. Basic disinfection protocols were followed and infiltration was given with 2% lignocaine with 1:80000 adrenaline. After achieving adequate anesthesia a remote incision was placed in relation to 21 and a full thickness envelop flap was reflected (Fig 13). Osteotomy site was prepared (Fig 14) with copious saline irrigation and a 3.5mm X 10mm Toureg S endosseous implant was placed (Fig 15) with adequate primary stability. Cover screw was placed (Fig 16). The surgical area was properly irrigated and flaps were sutured with simple interrupted 3-0 silk sutures (Fig 17). An immediate post operative periapical radiograph

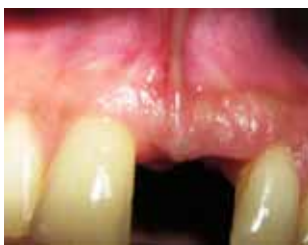

Fig. 12 6 months post-operative view

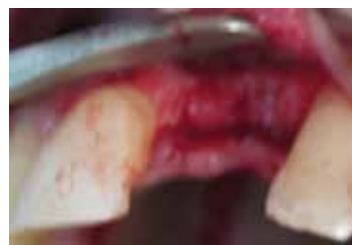

Fig. 13 Remote incision placed in relation to 21, full thickness envelop flap reflected

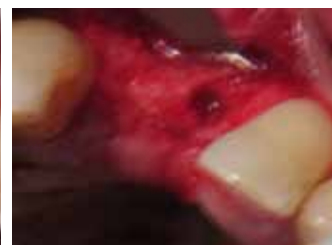

Fig. 14 Osteotomy site prepared in relation to 21

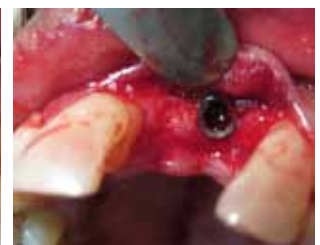

Fig. 15 3.5mm x 10 mm Toureg S endosseous dental implants placed in 21 region

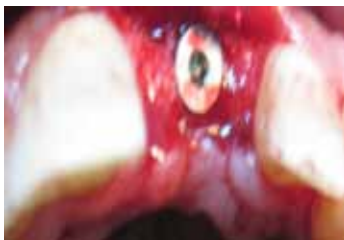

Fig. 16 Cover screw placed

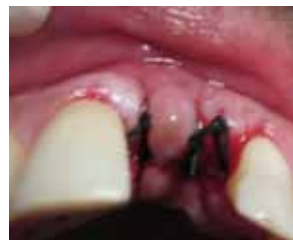

Fig. 17 Simple interrupted sutures placed with 3-0 silk

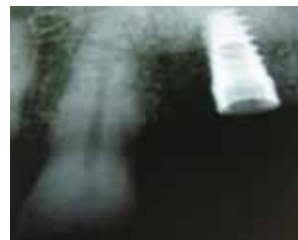


Fig. 18 Immediate postoperative periapical radiograph

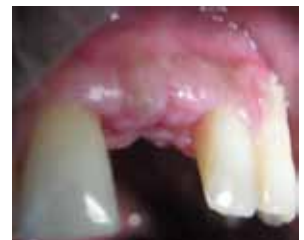

Fig. 19 1 week post-operative view

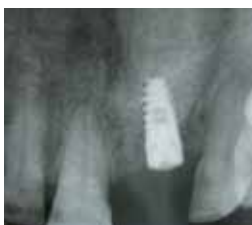

Fig. 20 1 week postoperative periapical radiograph

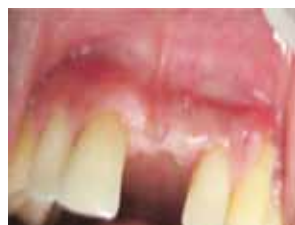

Fig. 21 After 6 months

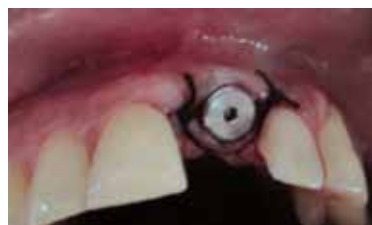

Fig. 22 Cover screw removed, healing cap placed and interrupted sutures given in 21 region

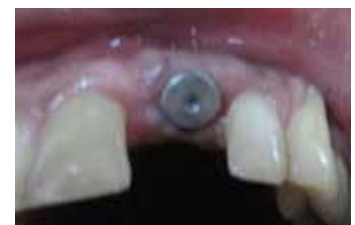

Fig. 23 After 2 weeks

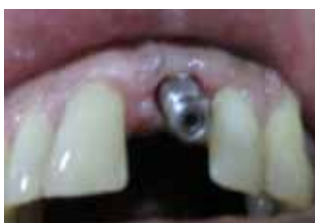

Fig. 24 Healing cap removed and closed tray transfer coping placed after 2 weeks

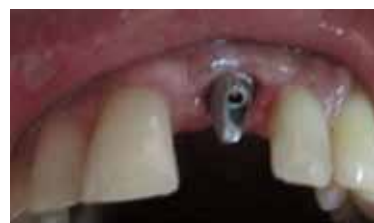

Fig. 25 Angled abutment placed

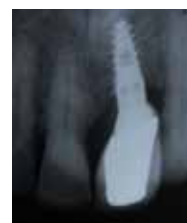

Fig. 26 Postoperative periapical radiograph

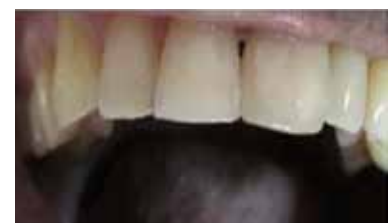

Fig. 27 21 Jacket crown restoration given

was taken (Fig 18). The patient was put on antibiotics and analgesics. Post surgical instructions were given and oral hygiene instructions reinforced. The sutures were removed after 1 week (Fig 19). An IOPAR was taken (Fig 20).

The patient was recalled after 6 months for placement of the prosthesis (Fig 21). Supragingival scaling was done. After anesthetizing the 21 region, a crestal incision was placed to expose the cover screw which was removed and healing cap placed. Simple interrupted sutures given (Fig 22). After 1 week sutures were removed. A proper gingival cuff was formed around the healing cap after 2 weeks (Fig 23). The healing cap was removed, impression coping was placed (Fig 24) and impression was taken using closed tray technique with rubber based impression material. Healing cap screwed back and patient was recalled after one week. The impression along with the implant analogue, coping and abutment were sent to the lab and the ceramic crown was fabricated. In the next appointment, abutment was placed (Fig 25) and an IOPAR was taken (Fig 26), followed by cementation of crown with Type I GIC (Fig 27). Patient was advised to maintain proper oral hygiene and is under follow up.

### ► Discussion

Loss of alveolar bone can occur prior to tooth extraction due to periodontal disease, periapical pathology or trauma to teeth and bone. Damage of the bone tissues during tooth extraction procedures may also result in bone loss. Finally, alveolar bone atrophy after tooth extraction is a well-known phenomenon<sup>5</sup>. Adequate bone volume is an important prerequisite for a predictable, long-term prognosis in implant dentistry. So presence of insufficient horizontal or vertical bone can preclude the successful outcome of an ideal implant placement<sup>8</sup>. GBR procedures are a reliable means for augmenting bone in cases of vertical and/or horizontal defects in partially edentulous patients<sup>4</sup>.

The basic principle of GBR involves the placement of mechanical barriers to protect blood clots and to isolate the bone defect from the surrounding connective tissue, thus providing bone forming cells with access to a secluded space intended for bone regeneration<sup>9</sup>. It has been recommended that the use of synthetic bone graft material with dental implant placement, as with guided bone regeneration, is important for the preservation of ridge width<sup>4</sup>.

When a tooth is lost, the blood supply from the periodontal ligament disappears, and the blood supply is only from the soft tissue and the suprapariosteal blood vessels of the bone. In our case, the patient lost his tooth 10 years back. So cortical perforation was planned to enhance angiogenesis and ample blood supply which are mandatory for bone development and

maintenance. Moreover, he was using partial denture which also might have contributed for bone resorption in the area<sup>3</sup>. Thus staged approach was selected as our treatment plan.

After flap reflection, the cortical bone surface was perforated with a small round bur prior to placing bone graft to open the marrow cavity and to stimulate bleeding into the defect area, which is an important biological requirement for bone regeneration. This is called decortication or bone marrow penetration<sup>10</sup>. The rationale may include: (1) to enhance the healing process by promoting bleeding and blood clot formation; (2) to allow progenitor cells and blood vessels to reach the bone graft site<sup>11</sup> which facilitate angiogenesis; and (3) to improve the physical interlocking of grafted bone and a recipient site<sup>12</sup>. However, bone marrow penetration may also have some negative effects; additional blood loss, potentially greater postoperative pain, increased bone loss and increased operative time<sup>13</sup>.

Demineralized bone matrix is a bone inductive sterile bioresorbable xenograft composed of type I collagen. It is prepared from bovine cortical bone samples, resulting in nonimmunogenic flowable particles of approximately 250  $\mu\text{m}$  that are completely replaced by host bone in 4–24 weeks<sup>14</sup>. Better biocompatibility, excellent handling properties and the improved response of tissues to the material are definite benefits of using DMBM<sup>15</sup>.

The use of the barrier membrane enhances complete osteogenesis by preventing the rapid ingrowth of fibroblasts into a bony defect and promoting the migration of osteogenic cells from the adjacent bony edges or bone marrow into the defect in an unimpeded fashion. Leaving the barrier membrane in place for an extended period of time and sealing off the bony defect permits uninterrupted osteogenesis to occur and allows maturation of the newly formed bone<sup>5</sup>. During GBR procedures, it is crucial to create a space that is properly isolated from the surrounding soft tissues and can be maintained for an appropriate period of time to ensure osteogenesis. In addition to space maintenance, the membrane plays a role in clot stabilization while simultaneously preventing migration of non-osteogenic tissues into the area<sup>16</sup>.

Studies have shown that survival rate of dental implants in well-controlled diabetic patients is similar to non-diabetics, so this disease, if properly controlled, is not a contraindication. Moy et al.<sup>17</sup> indicate that diabetes can cause osseointegration problems and that these failures would be associated with the duration of diabetes and the length of the implants. Also researches show that type 1 diabetes produces a reduction in bone mineral density through mechanisms that has been attributed to both a lower formation of bone and also to a

greater bone resorption. On the other hand, this alteration has not been demonstrated in patients with type 2 diabetes<sup>18</sup>. More over implant failure in diabetic patients usually occur when placing multiple implants due to the large masticatory force and larger wound. Normally, when one implant is integrated into bone, the force during mastication is dispersed to the surrounding healthy teeth<sup>19</sup>. In this case, we have placed only a single implant and the patient is not diabetic for long duration. Also the patient whom we selected for this case was a former smoker and patients who quit smoking before the implant procedure get the same result as non-smoking group<sup>20</sup>, as evidenced from literature reviews.

### ► Conclusion

Without the assistance of augmentation materials, endosseous implants would be limited only to those patients having alveolar ridges with adequate bone volume. The predictability of GBR techniques has increased the number of implant candidates and has facilitated prosthetically driven restorations<sup>21</sup>. The case selection and treatment plan are crucial factors determining the long term success of implant placement in such patients. Based on our present case we consider that implant placement is a better option to replace teeth which is lost over a longer span of time, if combined with ridge augmentation procedures, especially in esthetic zones. Further studies are required to evaluate the long term results of such cases.


### ► References

- Schropp L, Wenzel A, Kostopoulos L, Karring T. Bone healing and soft tissue contour changes following single-tooth extraction: a clinical and radiographic 12-month prospective study. *Int J Periodontics Restorative Dent* 2003; 23: 313-23.
- Kornman KS, Robertson PB. Fundamental principles affecting the outcomes of therapy for osseous lesions. *Periodontol* 2000; 22: 22-43.
- Liu J and Kerns DG. Mechanisms of Guided Bone Regeneration: A Review. *Open Dent J* 2014; 8 (Suppl 1-M3): 56-65.
- El Haddad E, Lauritano D, Candotto V, Carinci F. Guided bone regeneration is a reliable technique in implant dentistry: An overview and a case report. *OA Dentistry* 2014 Mar 10;2(1):5.
- Hitti RA and Kerns DG. Guided Bone Regeneration in the Oral Cavity: A Review. *Open Pathol J* 2011; 5: 33-45.
- Gher ME, Quintero G, Assad D, et al. Bone grafting and guided bone regeneration for immediate dental implants in humans. *J Periodontol* 1994; 65: 881-91.
- Wang HL, Boyapati L. "PASS" principles for predictable bone regeneration. *Implant Dent* 2006; 15: 8-17.
- Rakhmatia YD, Ayukawa Y, Furuhashi A, Koyano K. Current barrier membranes: titanium mesh and other membranes for guided bone regeneration in dental applications. *J Prosthodont Res.* 2013 Jan;57(1):3-14.
- Buser D, Dahlin C, Schenk RK. Guided bone regeneration in implant dentistry. Quintessence Publishing Co, Inc.; 1994: 32-4.
- Buser D. 20 years of guided bone regeneration in implant dentistry. 2nd ed. Chicago: Quintessence Pub. Co; 2009.
- Buser D, Bragger U, Lang NP, et al. Regeneration and enlargement of jaw bone using guided tissue regeneration. *Clinl Oral Implants Res* 1990; 1: 22-32.
- Alberius P, Gordh M, Lindberg L, et al. Onlay bone graft behaviour after marrow exposure of the recipient rat skull bone. *Scand J Plast Reconstr Surg Hand Surg* 1996; 30: 257-66.
- Greenstein G, Greenstein B, Cavallaro J, et al. The role of bone decortication in enhancing the results of guided bone regeneration: a literature review. *J Periodontol* 2009; 80: 175-89.
- Blumenthal N, Sabet T, Barrington E. Healing responses to grafting of combined collagen. *J Periodontol* 1986; 57(2):84-94.
- Rajan Gupta R, Pandit N, Malik R, Sood S. Clinical and Radiological Evaluation of an Osseous Xenograft for the Treatment of Infrabony Defects. *J Can Dent Assoc* 2007 July/Aug; 73(6):513- 513f.
- Machtei EE. The effect of membrane exposure on the outcome of regenerative procedures in humans: a meta- analysis. *J Periodontol* 2001;72:512-16.
- Moy PK, Medina D, Shetty V, Agha-loo TL. Dental implant failure rates and as-associated risk factors. *Int J Oral Maxillofac Implants.* 2005;20(4):569-77.
- Tuominen JT, Impivaara O, Puukka P, Ronnema T. Bone mineral density in patients with type 1 and type 2 diabetes. *Diabetes care.* 1999;22(7):1196-200.
- Loo WTY, Jin LJ, Cheung MNB and Wang M. The impact of diabetes on the success of dental implants and periodontal healing. *Afr. J. Biotechnol.* 2009 Oct 5;8(19):5122-7.
- Goutam M, Singh M, Patel D. Effects of smoking on the success of dental implants: A literature review. *International Dental Journal of Student's Research.* Oct 2012-Jan 2013;1(3): 44-50.21. Faigan S. Implant Placement with Simultaneous Guided Bone Regeneration. *The Citagenix Clinical Report* 2004 June;1.

## Emmott On Technology: Caries Diagnostics Steps Ahead With The Canary System

The Canary System uses a low-power, pulsating laser light to scan teeth for the presence of dental caries. The laser light is absorbed by the tooth and converted into luminescence and a tiny amount of heat. Simultaneous measurement of the reflected heat and light using fifty-two different algorithms evaluates the crystalline structure and can help determine the presence and extent of tooth decay.

Canary can detect decay on smooth enamel surfaces, root surfaces, biting surfaces, between teeth and around existing amalgam or composite fillings up to 5 mm deep. That means in theory the Canary could be used in place of radiographs for the detection of interproximal decay.



# Costello syndrome – A rare multisystem disorder

\* Veena S Ravi, \*\* Rita Zarina A., \*\*\*Digesh Balachandran, \*\*\*\*Jaseena P.M, \*\*\*\*\*Lubna M.

## Abstract

Costello syndrome is an extremely rare disorder that affects multiple organ systems of the body. It was first described by J.M. Costello in 1971. This condition is characterized by a wide range of developmental, musculoskeletal, dermatologic and cardiac abnormalities. It is an autosomal dominant genetic disorder caused by mutations in HRAS gene. This report is about a 9 year old girl, clinically and genetically diagnosed with Costello syndrome. Early intervention and multidisciplinary approach is important to ensure that children with Costello syndrome reach their potential.

**Key words:** Costello syndrome, RASopathy, HRAS gene mutation, polyhydramnios.

KDJ 2017 | Vol. 40 | No. 4 | Pg 212-214

## ► Background

Costello syndrome (CS) is an extremely rare disorder that affects multiple organ systems of the body. In 1971 and 1977, J.M. Costello described two children with mental retardation, poor post natal growth, distinctive physical appearance and nasal papillomata.<sup>1,2</sup> CS is characterized by a wide range of developmental, musculoskeletal, dermatological and cardiac abnormalities. The condition involves prenatal overgrowth, postnatal failure to thrive, and a distinctive physical appearance, with craniofacial features resembling those observed in lysosomal

storage disorders. Dermatologic manifestations include soft skin with excessive wrinkling over the dorsum of the hands and deep creases on the palms and soles, hyperextensible joints, generalized hyperpigmentation, pigmented nevi often on the palms and soles, papillomata around nose, mouth, anus, or less commonly elsewhere on the body and acanthosis nigricans. Affected individuals manifest polyhydramnios prenatally and feeding difficulty and failure to thrive postnatally, have short stature and severe mental retardation, and may have a silent or clinically significant hypertrophic cardiomyopathy.<sup>3</sup>

Occurrence of this syndrome may be sporadic or inherited as an autosomal dominant trait caused by mutations in HRAS gene. Reported estimates of CS prevalence range from 1 in 300,000 to 1 in 1.25 million, affecting 200 to 300 people worldwide.<sup>4</sup>

## ► Case Report

A 9 year old girl reported to our OPD with a chief complaint of pain and swelling of gums in relation to her left upper front tooth. History revealed that she was the second child of a consanguineous marriage, has a normal elder sibling and the mother had polyhydramnios during pregnancy. The child had a premature birth at 34 weeks of gestation with a birth weight of 3.1 Kg. Postnatally she had feeding difficulties and was later diagnosed to have global developmental delay.

The child's medical reports indicated that she had Costello syndrome. The condition was diagnosed clinically as well as genetically at the age of 2 years. General examination revealed short stature, ulnar deviation of wrists [Fig 1], cutis laxa, and hyperextensible joints with abnormal feet position [Fig 2a and 2b]. The characteristic facial features were macrocephaly, bitemporal narrowing, curly sparse hair, frontal bossing, strabismus, epicanthal folds, wide nostrils, papillomata around nose and mouth, unusually thick lips and low set ears [Fig 3]. Oral manifestations included delayed eruption and posterior cross bite. Intraoral examination revealed multiple carious teeth with a periapical abscess in relation to root remnant of 61 [Figure 4].

[Figure 5: OPG showing delayed dental development].

After obtaining medical clearance from pediatrician, oral prophylaxis, restoration of carious teeth and extraction of 61 was done. Full mouth rehabilitation was planned for the child and is currently under follow up.

## ► Discussion

Costello syndrome is a RASopathy characterized by craniofacial malformations, dermatologic and musculoskeletal abnormalities, generalized growth delay and cognitive deficits.<sup>5</sup> RASopathies are caused by mutations that increase signaling through the RAS pathway.<sup>6</sup>

\*Junior Resident, \*\*Professor and Head, \*\*\* Assistant Professor, \*\*\*\*Junior Resident, Department of Pedodontics and Preventive Dentistry, Government Dental College, Kottayam, Kerala, India • Corresponding Author: Dr. Veena S Ravi, E-mail: veenasravi@gmail.com



Characteristic findings of CS include coarse facial features, intellectual disability, cardiac problems and severe failure-to-thrive with short stature.<sup>7</sup> Delayed milestones and poor post natal growth were present in 100% of reported cases.<sup>3</sup> Polyhydramnios during pregnancy and normal or high birth weight were other common findings.<sup>3</sup> The predisposition to neoplasia includes a spectrum ranging from benign wart-like skin lesions termed papillomata to malignant tumors including rhabdomyosarcoma, neuroblastoma in children, and transitional cell carcinoma of the bladder in young adults. No single feature is unique for CS, although the combination of findings like curly or fine hair, prominent epicanthal folds, long eyelashes, depressed nasal bridge, full nasal tip, fleshy ear lobes, and a wide mouth with full lips usually gives the characteristic facial appearance. When supplemented by the distinctive hand position (severe ulnar deviation), cutis laxa, diffuse hyperpigmentation and hoarse voice, the phenotype becomes complete.<sup>7</sup> Children with CS generally have warm sociable personalities.

Cardiovascular abnormalities are usually present in infancy or early childhood, but may be recognized at any age. Cardiac problems typically include cardiac hypertrophy and less commonly atrial tachycardia or pulmonic stenosis.<sup>7</sup> However, we could not elicit any cardiac abnormalities for

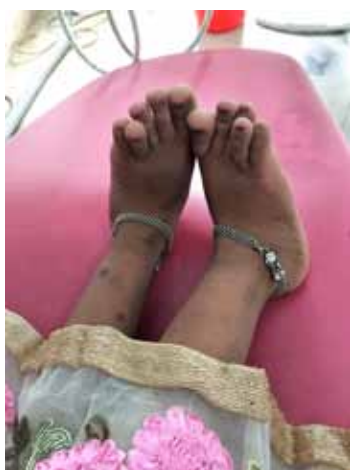this particular patient either from medical records or from general examination.

The common dental findings include a generalized delay in the development and eruption of teeth, along with frequent enamel defects.<sup>7</sup> Anterior open bite and posterior cross bite were seen in about 30-40% cases.<sup>8</sup>

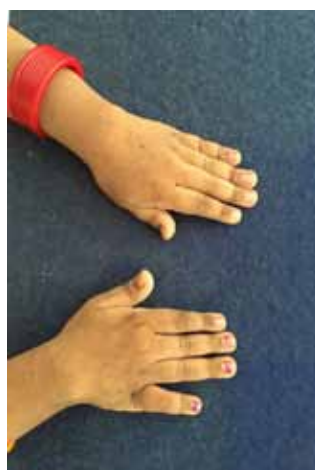A suspected clinical diagnosis of CS is confirmed through molecular genetic testing by the identification of a specific germline mutation in the proto-oncogene HRAS, which is the only gene associated with Costello syndrome according to a review by expert clinicians.<sup>9,10</sup> Sequence analysis of HRAS exon 2 (the first coding exon) detects missense mutations in 80–90% of individuals tested.<sup>7,9</sup> Failure to identify an HRAS mutation in an individual with clinical features typical for Costello syndrome can result from either (1) the rare occurrence of low level of somatic mosaicism for the HRAS disease-causing mutation in the tested tissue or (2) the more common presence of a mutation in another gene, consistent with a diagnosis of Cardiofaciocutaneous (CFC) syndrome or another disorder of the RAS/MAPK pathway. HRAS is a well-known proto-oncogene, and aberrant activation is often found in sporadic somatic tumors; which is responsible for the increased cancer incidence in individuals with a germline HRAS mutation.<sup>7</sup>



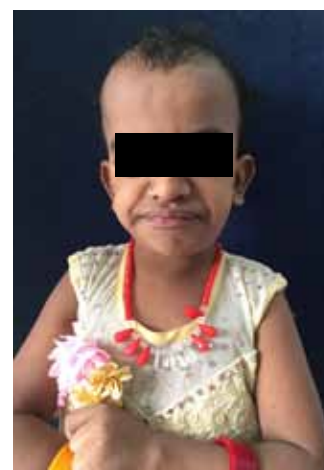**Fig. 1** Showing general features of the child like short stature, hyperextensible joints.



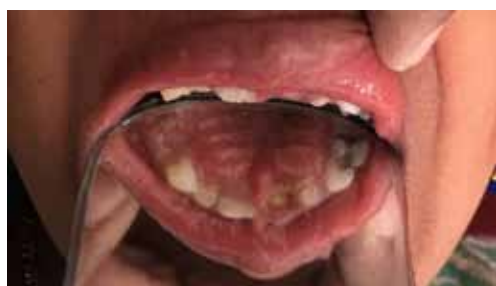**Fig. 2a** Abnormal feet position



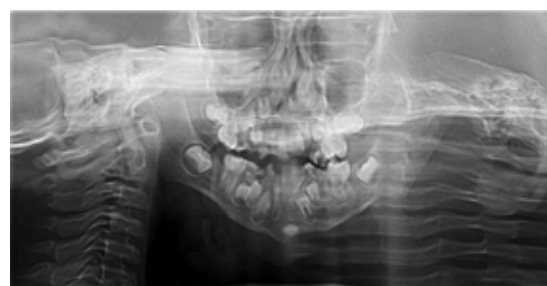**Fig. 2b** Cutis laxa of palms



**Fig. 3** Showing characteristic facial features of the syndrome



**Fig. 4** Intraoral view



**Fig. 5** OPG showing generalized delay in development and eruption of teeth

The differential diagnosis include other RASopathies like Noonan syndrome or CFC syndrome which share many similar clinical features with CS. However, Costello syndrome is distinguished from these conditions by a characteristic prenatal and postnatal history and by the distinctive physical appearance and examination findings. The findings in patients with CS are usually more extensive than those observed in the previously mentioned conditions.<sup>3</sup>

Oral health is considered as an intimate part of general health and well-being. The prevalence of oral health problems are high in children with special health care needs because of the fact that they are unable to take care of their basic oral health care needs and the parent or caregiver often loses focus on oral health. Education of parents and caregivers is important for appropriate and regular supervision of oral hygiene. A non cariogenic diet along with sugar free medicines should be discussed with caregivers as well as child's pediatrician. A modified manual toothbrush or electronic tooth brush may improve patient compliance.<sup>11</sup>

► **Conclusion**

Costello syndrome is a rare genetic syndrome. Medical care for individuals with CS involves a multidisciplinary approach to improve overall health and development, through early identification of anticipated medical problems and prompt

treatment. Its ultimate goal is to improve the quality of life for affected individuals and their families. Hence early intervention is important to ensure that children with Costello syndrome reach their full potential.

► **References**

1. Costello JM. A new syndrome (abstract). *N Z Med J* 1971;74:397.
2. Costello JM. A new syndrome: mental subnormality and nasal papillomata. *AustPaediat J* 1977;13:114-8.
3. Johnson et al. Costello syndrome: phenotype, natural history, differential diagnosis and possible cause. *J Pediatr* 1998;133:441-8.
4. <https://ghr.nlm.nih.gov/condition/costello-syndrome>.
5. Rauen KA. HRAS and the Costello syndrome. *Clin Genet*. 2007; 71:101–108.
6. Tidyman WE, Rauen KA. The RASopathies: Developmental syndromes of Ras/MAPK pathway dysregulation. *Curr Opin Genet Dev*. 2009; 19:230–236.
7. Gripp KW, Lin AE. Costello syndrome: a Ras/mitogen activated protein kinase pathway syndrome (rasopathy) resulting from HRAS germline mutations. *Genet Med* 2012;14(3):285–292.
8. Goodwin AF et al. Craniofacial and dental development in Costello syndrome. *Am J Med Genet A*. 2014 June; 0(6): 1425–1430.
9. Aoki Y, Niihori T, Kawame H, et al. Germline mutations in HRAS protooncogene cause Costello syndrome. *Nat Genet* 2005; 37:1038–1040.
10. Kerr B, Allanson J, Delrue MA, et al. The diagnosis of Costello syndrome: nomenclature in Ras/MAPK pathway disorders. *Am J Med Genet A* 2008;146A: 1218–1220.
11. Alhashmi H (2017) Dental management of children with Special Health Care Needs: A Review. *JSM Dent* 5(2): 1090.

## Composite restorations of the future may be made of glass

**A new study has found that bioactive glass may help reduce the ability of bacteria to attack composite tooth fillings.**

A few years from now millions of people around the world might be walking around with an unusual kind of glass in their mouth, and using it every time they eat. Engineers at Oregon State University have made some promising findings about the ability of “bioactive” glass to help reduce the ability of bacteria to attack composite tooth fillings – and perhaps even provide some of the minerals needed to replace those lost to tooth decay.

Prolonging the life of composite tooth fillings could be an important step forward for dental treatment, the researchers say, since more than 122 million composite tooth restorations are made in the United States every year. An average person uses their teeth for more than 600,000 “chews” a year, and some studies suggest the average lifetime of a posterior dental composite is only six years.

# Anterior esthetic zone rehabilitation using Rochette bridge

\*Abha Nair, \*Layana Theodore, \*\*Sudeep S., \*\*\*Dinesh N., \*\*\*Sapna Bhaskar

## Abstract

A restoration that is frequently prescribed to provisionally restore the single unit edentulous space is the removable acrylic partial prosthesis. The Rochette bridge design provides an effective alternative when confronted with this clinical situation. The adaptable nature of this technique means that it can be utilised in a variety of clinical situations with success. The greatest benefits are seen in clinical situations where simple and aesthetic alteration of the pontic dimensions during treatment is necessary. It can also be used in long-term provisional situations where, if a removable acrylic partial prosthesis was used, multiple adjustments or remakes would be necessary. This case report mentions a simplified technique to restore the missing maxillary central incisor in a young adult patient with fabrication of Rochette bridge.

**Keywords:** Anterior esthetics, Rochette bridge, Resin Bonded Fixed Restoration

KDJ 2017 | Vol. 40 | No. 4 | Pg 215-217

## ► Introduction

Resin bonded or resin retained bridges (RBBs/RRBs) are minimally invasive fixed prostheses which rely on composite resin cements for retention. Since the introduction of Rochette bridge in 1973, the resin bonded bridge has undergone a number of developments to become a commonly used technique

for replacement of a missing tooth. The first type of RBB was the Rochette Bridge, which relied on the retention generated by resin cement tags through a characteristic perforated metal retainer<sup>1</sup>.

One of the major advantages is that it requires minimal tooth preparation than conventional bridgework. Most frequently the patient may ask, “Is it really necessary to cutaway all that good tooth?” This question has troubled dentist in prescribing the replacement of missing tooth as they have tried to balance the periodontal, occlusal and esthetic benefits of prosthesis against the damage to the abutment teeth.<sup>2</sup>

Some reports have suggested poor long term success rates; however, if used in appropriate clinical situations, this treatment modality can be extremely successful. Recent systematic reviews have estimated the five-year survival rates for bridgework as 87.7% for resin bonded prostheses<sup>3</sup> and just over 90% for conventional bridges depending on design.<sup>4</sup> Although these rates are lower than the 94.5% success<sup>5</sup> reported for implant retained single crowns over the same five year follow up, resin bonded bridgework has the advantages of being less invasive, requiring a shorter total treatment time and less financial commitment.

Thus in recent years, regardless of whether the location is posterior

or anterior, RBFDPs, as well as oral implants, have been accepted as an alternative to conventional fixed partial dentures when intact abutments are present and minimal intervention is desired<sup>6</sup>.

However, there are certain limitations of resin bonded prosthesis such as short clinical crowns, long edentulous spans, restored or damaged abutments, para-functional habits, deep bite and compromised enamel hyperplasia. This case report mentions a simplified technique to restore the missing maxillary central incisor in a young adult patient with fabrication of Rochette bridge.

## ► Review of literature

In the 1970s, Howe and Denehy<sup>1</sup> adapted the Rochette bonded cast-metal periodontal splint concept<sup>7</sup> to create the first RBFDP. The early procedures were conservative, but problems with debonding resulted in a survival rate of only 28% at 7.5 years<sup>8</sup>. To enhance retention and resistance form of posterior RBFDPs, Livaditis recommended preparation of parallel guide surfaces on the interproximal and lingual aspects of the adjacent teeth along with rests on the occlusal aspect to counteract dislodging forces. Resin bonding was further enhanced by using solid electrolytic ally etched base metal-alloy casting.<sup>9</sup> The result was a doubling of the survival rate to 64% at 7.5 years. In the 1980s and 1990s, significant

\*PG Student, \*\* Professor & HOD, \*\*\* Professor, Dept. of Prosthodontics and Crown and Bridge, PMS College of Dental Science and Research, Trivandrum • Corresponding Author: Dr. Abha Nair, E-mail: abha369rajagopal@gmail.com

advances in metal surface treatment, dentin bonding and resin cements potentially improved the clinical success rate of RBFDPs.

► **Case report**

A 22 year old female patient reported to the Dept. of Prosthodontics with the chief complaint of missing upper front tooth. Dental history revealed extraction of the tooth due to traumatic injury in a road accident 14 months back as evidenced by Fig 1. Clinical examination revealed missing tooth # 11 as seen in Fig 2. Radiographic evaluation revealed no pathology or root remnant in #11 region. Her expectations were reasonable and her psychological profile was good. After considering the patients wish and the clinical situation, the option of removable partial denture, fixed partial denture and implant were eliminated and it was decided to replace it with a resin bonded bridge [Rochette bridge] using #12 and # 21 as abutments.

Minimal tooth preparation of the abutments (#12 and #21) were performed following the standard technique on the lingual surfaces only. Care was taken to ensure that the preparations did not extend beyond the linguo-proximal line angles on the abutments. Lingual preparation ended 1 mm from the incisal edge and a light chamfer finish line was prepared 1 mm supragingivally. Parallel retentive grooves

were made in each preparation on the surface facing the edentulous space.

Impression procedures were carried out with addition silicone(Express XT, 3M ESPE, Germany). A metal framework with ‘wings’ extending onto the preparations was fabricated with non-precious alloy. Metal try in of the frame work showed minimum interferences. [ Fig 3 and Fig 4] Shade selection was done using Vita 3-D Master shade guide. The trial fitting of the prosthesis was done and then esthetics mastication and speech were evaluated. The metal wings of the prosthesis was kept off the incisal third to prevent darkening of the tooth because of the inhibition of light transmission. In addition, care was taken to make sure metal would not be visible inter proximally or at the embrasure areas.

The restoration was cemented in place using universal self-etch resin cement (Rely X U100, 3MESPE, Germany). The occlusion was verified in centric and eccentric mandibular positions and it was made sure that there were no interferences. [Fig 5 and Fig 6] Post cementation instructions were given and patient was followed up at regular intervals.[Fig 7]

► **Discussion**

A missing tooth in the anterior region is not only a physical loss, but also may be an emotional experience for the patient

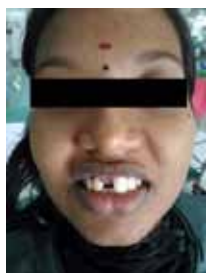

Fig 1: Pre Operative Photograph

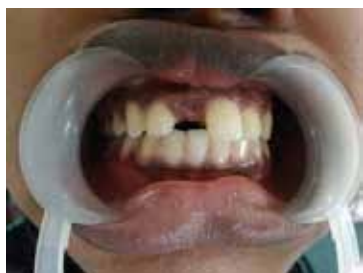

Fig 2: Missing 11



Fig 3: Metal Framework

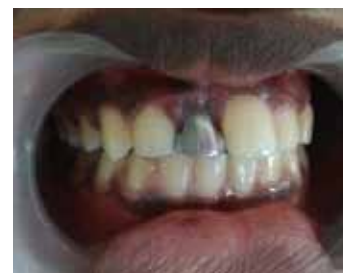

Fig 4: Metal Try In; Note the visibility of metal wings of the prosthesis in 12, which was corrected & kept off the incisal third to prevent darkening of the tooth because of the inhibition of light transmission.

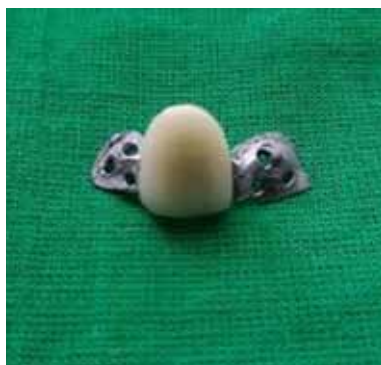

Fig 5: Finished Rochette Bridge

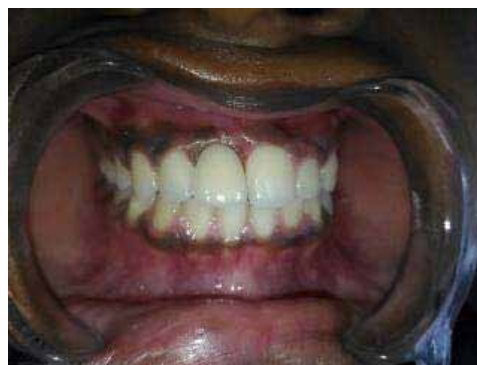

Fig 6: Final Intra oral Photograph

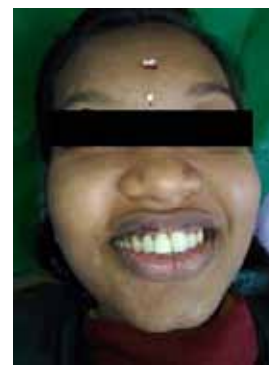

Fig 7: Post Operative Photograph

as well. To remove healthy tooth structure of adjacent teeth to replace a congenitally missing tooth or a tooth lost to decay, trauma, root fracture, failed root canal treatment, or pathology is, for some patients and dentists, a very aggressive treatment option.<sup>10</sup>

Many treatment modalities are available for replacing a single missing tooth; removable partial denture, fixed partial denture or dental implant. Each modality is a possible treatment option and has its own advantages and disadvantages. Patient awareness of the advantages and disadvantages of different treatment modalities is very important for decision making, therefore there are many factors make single-tooth replacement one of the most challenging restorations in dentistry.<sup>11</sup>

The traditional treatment for a single edentulous space is a conventional fixed partial denture. A major shortcoming of this alternative is the significant tooth reduction of the abutments.<sup>12</sup> The use of fixed partial denture should be avoided in young actively growing patients this is because the rigid fixed partial denture could interfere with jaw growth.<sup>13</sup> Even after 10 years of service the periodontal response for resin bonded fixed partial dentures is minimal.<sup>12</sup> The three most common complications associated with resin-bonded prosthesis are deboning (21%), tooth discoloration (18%) and. Caries (7%).<sup>14</sup>

### ► Conclusion

One of the basic principles of tooth preparation in fixed prosthodontics is conservation of tooth structure. This is the primary advantage of resin bonded fixed dental prosthesis. Precision and attention to detail are just as important in RBFDP as in conventional prosthesis. To provide a long lasting prosthesis, the clinician must plan and fabricate a resin bonded restoration with the same diligence used for conventional restorations. The techniques can be very rewarding, provided they are approached carefully. Careful patient selection is an important factor in predetermining clinical success.

### ► References

1. Howe D F, Denehy G E. Anterior fixed partial dentures utilizing the acid-etch technique and a cast metal framework. *J Prosthet Dent* 1977; 37: 28–31.
2. Schillingberg H.T, Hobo S, Whitsett L.D. *Fundamental of fixed prosthodontics*, ed 3rd Chicago, Quintessence publication Co;1996: p 537-561.
3. Pjetursson B E, Tan W C, Tan K, Bragger U, Zwahlen M, Lang N P. A systematic review of the survival and complication rates of resin-bonded bridges after an observation period of at least 5 years. *Clin Oral Implants Res* 2008; 19: 131–141.
4. Pjetursson B E, Bragger U, Lang N P, Zwahlen M. Comparison of survival and complication rates of tooth-supported fixed dental prostheses (FDPs) and implant-supported FDPs and single crowns (SCs). *Clin Oral Implants Res* 2007; 18 Suppl 3: 97–113.
5. Jung R E, Pjetursson B E, Glauser R, Zembic A, Zwahlen M, Lang N P. A systematic review of the 5-year survival and complication rates of implant-supported single crowns. *Clin Oral Implants Res* 2008; 19: 119–130.
6. Tyas MJ, Anusavice KJ, Frencken JE, Mount GJ. Minimal intervention dentistry—a review. FDI Commission Project 1-97. *Int Dent J* 2000;50:1–12.
7. Rochette AL. Attachment of a splint to enamel of lower anterior teeth. *J Prosthet Dent* 1973; 30(4):418–23.
8. Creugers NH, Kayser AF, van't Hof MA. A seven-and-a-half-year survival study of resin-bonded bridges. *J Dent Res* 1992; 71(11):1822–5.
9. Livaditis GJ, Thompson VP. Etched castings: an improved retentive mechanism for resin-bonded retainers. *JProsthet Dent* 1982; 47(1):52–8.
10. Al-Quran A, Al-Ghalayini FR, Al-Zubi BN. Single tooth replacement: factors affecting different prosthetic treatment modalities. *Oral Health* 2
11. Cosme DC, Baldisserotto SM, Fernandes EDL, Rivaldo EDL, Rosing CK, Shinkai RSA. Functional evaluation of oral rehabilitation with Removable partial dentures after five years. *Journal of Applied Oral Sciences* 2006;14(2):111-116. 011;11(34): 1-7
12. Pratyusha P, Jyoti S, Kaul RB, Sethi N. Maryland Bridge: An interim prosthesis for tooth replacement in adolescents. *International journal of clinical pediatric dentistry* 2011; 4(2):135-138.
13. Shigli A, Reddy RPV, Hugar SM, Deshpande D. Hypohidrotic ectodermal dysplasia: A unique approach to esthetic and prosthetic management: A case report. *Journal Indian Society Pedodontic Preventive Dentistry* 2005:31-34.
14. Goodacre CJ, Bernal G, Rungcharassaeng K, YK Kan J. Clinical complications in fixed prosthodontics. *TheJournalOf Prosthetic Dentistry* 2003; 90:31-41.

## Dental Shade Equipment



You want your restorations to look as natural as possible, which is why it's so important to get the shade just right. Natural dentition features a wide array of nuanced shades and translucencies, making finding the perfect match challenging. Dental Shade Equipment helps you match the restoration to the surrounding dentition so patients walk out of your office happy with their final restoration and confident in their smile. Dental shade equipment also offers a powerful communication tool, whether you're communicating with your lab or talking with patients about potential whitening treatment.

Dentists have a variety of options when choosing shade equipment. Shade matching can be done manually using a shade guide system with augmentation from dental shade lights or digitally with shade matching systems also known as Tooth Shade Scanners.



# Peripheral ossifying fibroma

\* Haseeba K. \*\*Harish Kumar VV, \*\*\* Santhosh VC, \*\*\*\* Sreekanth Puthalath

## Abstract

One of the most frequently encountered lesion of oral cavity is gingival overgrowth. Most of them arises due to localised chronic irritation such as plaque, calculus, restorative or orthodontic appliances. These over growths were termed broadly as epulis. Peripheral ossifying fibroma (POF) is one among them that shows considerable variation in its nomenclature and etiopathogenesis. Any slowly growing soft tissue mass in the anterior oral cavity of young adults should raise a suspicion of reactive oral lesion such as POF. Etiology of POF is unclear and the treatment must be total excision to prevent recurrence. Commonly used synonyms for POF includes calcifying fibroblastic granuloma, peripheral fibroma with calcification, peripheral cementifying fibroma, calcifying or ossifying fibrous epulis. This case report presents a 17 years old female with gingival overgrowth in maxillary anterior region on buccal side since 1 year.

**Key words:** Peripheral ossifying fibroma, Gingival overgrowth

KDJ 2017 | Vol. 40 | No. 4 | Pg 218-220

## ► Introduction

The gingiva is subjected to constant irritation from plaque, calculus, food impaction, irregular restorations, low-grade trauma, and iatrogenic factors and the gingival tissues react to these irritants by developing a type of growth which was known by the Greek term

epulis for many years. This common localized overgrowth is not considered as neoplasm but a nonspecific hyperplastic inflammatory reaction. POF is a focal, reactive, non-neoplastic tumor like growth of the soft tissue that often arises from the interdental papilla.<sup>1</sup> Though the etiopathogenesis is uncertain, an origin from cells of the periodontal ligament has been suggested.<sup>2</sup> It accounts for 3.1% of all oral tumors and 9.6% of gingival lesion.<sup>3</sup>

## ► Case report

A healthy 17 yrs old female patient reported with chief complaint of lump on upper right front teeth region since one year (Fig. 1), giving unpleasant appearance to her smile. Patient was otherwise healthy. Swelling started as small growth and grew to the present size of 1 to 1.5 cm. There was no associated history of bleeding or pain. The patient did not give any history of trauma or food impaction.

Clinical examination revealed a well-circumscribed, solitary, sessile, firm swelling measuring approximately 1 cm to 1.5 cm on the inter dental papilla in relation to upper right maxillary canine and premolar, extending to middle third of labial aspect of canine. The lesion appeared reddish pink. It was non fluctuant, non tender, non compressible, non reducible on palpation. The surface of the lesion was non ulcerated and the overlying mucosa appeared normal. No periodontal pocket / tooth mobility

was noted in relation to canine. After performing oral prophylaxis, growth was excised completely and area was curetted. After controlling bleeding, the area was sutured and covered with periodontal pack. Excised tissue was sent for histopathological examination. Radiographically, there were no signs of bone resorption or any findings pertaining to the exophytic bony lesion (fig. 2). Clinically provisional diagnosis for this growth were fibroma and peripheral ossifying fibroma.

The histopathological examination of the lesion using Haematoxylin and Eosin staining method showed parakeratinized stratified squamous epithelium with adjoining fibrocollagenous connective tissue. The overlying epithelium is atrophic at focal area and shows pseudo epitheliomatous hyperplasia. The bulk of the lesion is composed of large number of plump proliferating fibroblast intermingled throughout a very delicate fibrillar stroma. Ovoid circular and linear calcification resembling bone are evident (Figures 3a and 3b). Depending upon clinical, histopathological examination diagnosis of peripheral ossifying fibroma was confirmed.

The periodontal treatment plan included patient education and motivation for oral hygiene instructions, scaling and root planing, reevaluation and surgical excision of the lesion under local anesthesia. Scaling and root planing was performed for elimination of local

\*P.G. Student \*Professor and Head, \*\* Professor, \*\*\*Associate Professor, Dept of Periodontics, KMCT Dental College, Kozhikode • Corresponding Author: Dr. Haseeba K., E-mail: haseebashabeer@gmail.com

factors. After one week of SRP, a reevaluation and surgical excision of the lesion was performed (Fig. 4).

Review of the patient revealed, persistence of bony prominence in the region of canine and premolar (Fig. 5). So resective osseous surgery was performed in this region (Fig. 6). Sutures and periodontal pack was given. The patient was prescribed with analgesic and antibiotics. The patient presented for a follow up examination 1, 3 and 6 months post operatively (Fig. 7). There was no evidence of recurrence of the lesion and the patient was asymptomatic.

#### ► Discussion:

Menzel first described the lesion ossifying fibroma in 1875<sup>4</sup> but its terminology was given by Montgomery in 1927.<sup>4</sup> Peripheral ossifying fibroma occurs mostly in craniofacial bones and categorized into two types central and peripheral.

The central type arises from the endosteum or the periodontal ligament adjacent to the root apex and expands from the medullary cavity of the bone, and the peripheral type occurs on the soft tissues overlying the alveolar process.<sup>5</sup>

The etiopathogenesis of POF is uncertain. There are multiple etiological factors. It was believed that lesion arise from periodontal membrane due to exclusive occurrence of peripheral ossifying fibroma in the interdental papilla in proximity to periodontal ligament and the presence of oxytalan fibres within the mineralized matrix of some lesions.<sup>6,2</sup> Another factor is chronic irritation from local irritants such as; dental plaque, calculus, microorganisms, masticatory forces, ill-fitting dentures and poor quality restorations leads to excessive proliferation of mature fibrous connective tissue and resultant initiation of formation of bone or dystrophic calcification. It has been suggested that the lesion may be caused by

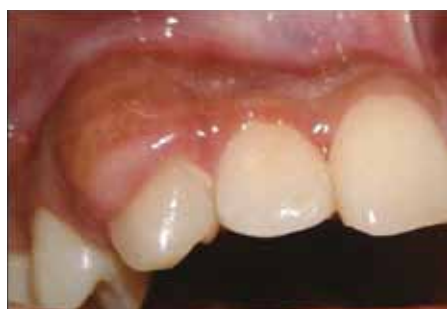

Fig. 1: Clinical presentation

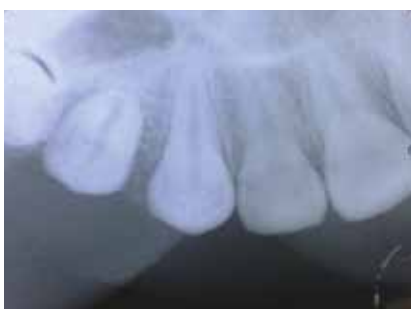

Fig. 2: IOPA of 13 (film kept occlusally at low exposure)

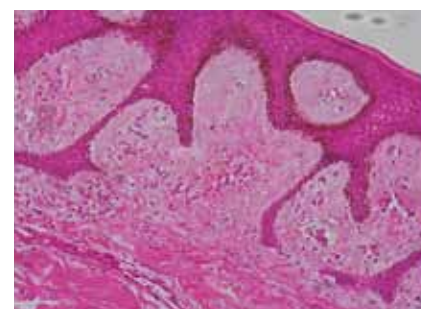


Fig. 3a: Pseudo epitheliomatous hyperplasia (100x)

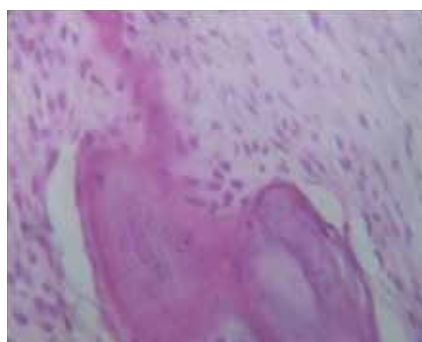


Fig. 3b: Ovoid calcification resembling bone and numerous plump fibroblasts (400x)

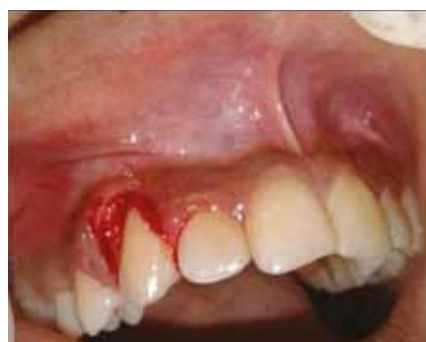

Fig. 4: Immediately after excision

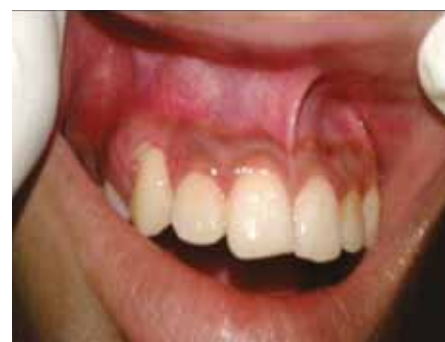

Fig. 5: One week after excision

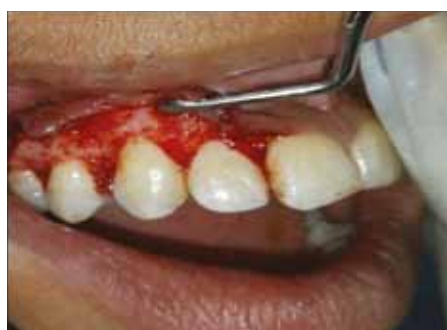

Fig. 6: After resective osseous surgery

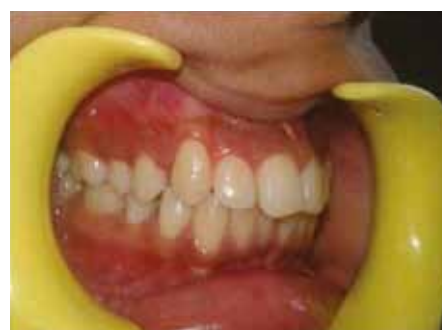

Fig. 7: After 6 months

fibrosis of the granulation tissues.<sup>6</sup> Rare manifestation of multicentric lesion point towards a possible role of genetics in the pathogenesis of this disease.<sup>2</sup>

Almost two-third of all cases occur in females, with predilection for the anterior maxilla.<sup>3</sup> Hormonal influences may play a role, giving higher incidence of POF among females, increasing occurrence in the 2nd decade and declining incidence after the 3rd decade.<sup>3</sup> With respect to race, there is a predominance in Whites (71%) compared to Blacks (36%).<sup>7</sup> It is usually less than 1.5 cm in diameter but, lesion up to 9 cm diameter has been reported.<sup>7</sup> Clinically appear as red to pink, solitary nodular mass arising usually from interdental papilla, either pedunculated or sessile and the surface is frequently ulcerated. Radiographic lesion shows radio opacity, mature lesion show flecks and patches of radiopacity in the centre of lesion. Underlying bone involvement is rarely evident on a periapical radiograph.<sup>8</sup>

Histopathologically, the lesion shows stratified squamous epithelium with cellular mass of connective tissue made up of plump fibroblasts, and areas of lamellar or woven osteoid pattern predominates. Confirmatory diagnosis of POF is made by histopathologic evaluation of biopsy specimens.

Local surgical excision including the involved periodontal ligament and periosteum is the preferred treatment. Due to the high rate of recurrence (8% to 20%), long term postoperative monitoring is required in all cases of POF.<sup>4</sup> Incomplete removal of the lesion, failure to eliminate local factors and difficulty in accessing the lesion during surgical manipulation result in higher recurrence rate.<sup>4</sup> However, Walters et al<sup>9</sup> also stated that total excision of the lesion in the maxillary anterior region can result in an unsightly gingival defect unless appropriate efforts are taken to repair the periosteal defects. Various different

surgical techniques like lateral sliding flap of full thickness or partial thickness, coronally positioned flap or subepithelial connective tissue graft, may be used to manage this defect and minimize patient esthetic concerns.

### ► Conclusion

Peripheral ossifying fibroma is slow growing reactive lesions which usually show limited growth potential. It should be carefully differentiated from other reactive gingival lesion. Treatment includes surgical excision including underlying periosteum and periodontal ligament with close postoperative re-evaluation due to high recurrence potential.

### ► References

1. Farquhar T, MacLellan J, Dymont H, Anderson RD. Peripheral ossifying fibroma: a case report. *J Can Dent Assoc.* 2008 Nov 1;74(9):809-12.
2. Kumar SK, Ram S, Jorgensen MG, Shuler CF, Sedghizadeh PP. Multicentric peripheral ossifying fibroma. *Journal of oral science.* 2006;48(4):239-43.
3. Cuisia ZE, Brannon RB. Peripheral ossifying fibroma--a clinical evaluation of 134 pediatric cases. *Pediatric dentistry.* 2001;23(3):245-8.
4. Sujatha, G., Sivakumar, G., Muruganandhan, J., Selvakumar, J. and Ramasamy, M. "Peripheral ossifying fibroma-report of a case." *Indian Journal of Multidisciplinary Dentistry* 2012; 2(1):415-418
5. Miller CS, Henry RG, Damm DD. Proliferative mass found in the gingiva. *Journal of the American Dental Association* (1939). 1990 Oct;121(4):559-60
6. Eversole LR, Rovin S. Reactive lesions of the gingiva. *Journal of Oral Pathology & Medicine.* 1972 Jan 1;1(1):30-8.
7. Kenney JN, Kaugars GE, Abbey LM. Comparison between the peripheral ossifying fibroma and peripheral odontogenic fibroma. *Journal of Oral and Maxillofacial Surgery.* 1989 Apr 1;47(4):378-82
8. Keluskar V, Byakodi R, Shah N. Peripheral ossifying fibroma. *Journal of Indian Academy of Oral Medicine and Radiology.* 2008 Apr 1;20(2):54.
9. Walters JD, Will JK, Hatfield RD, Cacchillo DA, Raabe DA. Excision and repair of the peripheral ossifying fibroma: a report of 3 cases. *Journal of periodontology.* 2001 Jul 1;72(7):939-44.

## The study discovered that mouth acidity levels can be affected by sleeping with an open mouth

Mouthbreathers beware: Annoying your spouse isn't the only downside of breathing through your mouth while you sleep. A new study has found that people who breathe through their mouth while sleeping are at a higher risk for tooth decay.

Saliva plays a key role in caries prevention in a variety of ways (a recent study found that salivary mucins limit the growth of cavity-causing bacterial biofilm that forms on a tooth's surface), and mouth breathing can dry out the mouth. This can cause the oral environment to become acidic, and higher acidity levels can lead to the erosion and loss of tooth enamel.



# Principles of lasers in Dentistry

\*Ebinu A., \*Soumya Mohan, \*\*Allen Jim Hines, \*\*\*T. Sreelal, \*\*\*\*Giri Chandramohan, \*\*\*\*Aparna Mohan

## Abstract

Since the development of the ruby laser by Maiman in 1960, there has been great interest among dental practitioners and scientists, to use this tool to make dental treatment more pleasant. With the availability and future development of different laser wavelengths and methods of pulsing, much interest is developing in this growing field. This article reviews the principles of lasers in dentistry.

KDJ 2017 | Vol. 40 | No. 4 | Pg 221-224

## ► Introduction

The dental lasers of today have benefited from decades of laser research and have their basis in certain theories from the field of quantum mechanics, initially formulated during the early 1900s by Danish physicist Bohr, among others. Nearly 40 years later, American physicist Townes first amplified microwave frequencies by the stimulated emission process, and the acronym MASER (Microwave Amplification by Stimulated Emission of Radiation) came into use. In 1958, Schawlow and Townes discussed extending the maser principle to the optical portion of the electromagnetic field, hence, LASER (Light Amplification by Stimulated Emission of Radiation) was invented.

## ► Principle of lasers

In an atom, an electron whirls in an orbit surrounding nucleus. This electron

ordinarily is in a low energy state. If a photon - a unit of energy strikes the atom, the electron absorbs the energy and is transferred to a more excited state which is less stable than the resting or low – energy state. This process is called absorption.

Once an electron moves to a higher-energy orbit, it eventually wants to return to the ground state. When it does, it releases its energy as a photon -- a particle of light. This phenomenon is termed spontaneous emission of radiation.

When an atom in the excited state becomes irradiated with a photon of light energy of the same wavelength and frequency that was previously absorbed, as it returns to its resting state, it will emit two photons of light energy of the same direction in spatial and temporal phase. This is the stimulated emission of radiation.

## Properties of laser light:

A laser light has one specific color; a property called monochromatic. Collimation refers to the beam having specific spatial boundaries. Coherency is a property unique to lasers. A laser produces light waves that are physically identical. They are all in phase with one another; that is, they have identical amplitude and identical frequency.

## Classification of lasers:

### I. Based on application

- Soft tissue laser - eg: Argon, CO<sub>2</sub>, diode; Nd:YAG.
- Hard tissue laser - eg: Er: YAG
- Resin curing laser - eg: Argon

### II. Mode of action

- Contact mode (focused or defocused) - eg: Ho: YAG; Nd: YAG
- Non-contact mode (focused or defocused) - eg: CO<sub>2</sub>

### III. Based on level of energy emission:

- Soft lasers (low level energy): A thermal low energy lasers emitted at wave length, which are supposed to stimulate cellular activity.

### Ex: He-Neon; Ga-Arsenide.

- Hard lasers (High level energy): Thermal lasers emitted at wavelength in the visible infra red and U.V range. Ex: Er:YAG laser; Nd: YAG laser.

### IV. Based on radiant energy generation:

- Continuous wave or continuous form
- Discrete or single pulses
- Multiple timed pulses (Pulse modes)

### V. Based on wavelength and medium

#### ► Laser delivery systems:

The coherent, collimated beam of laser light must be able to be delivered

\*PG Student, \*\*Senior Lecturer, \*\*\*Professor & Head of the Department, \*\*\*\*Reader, Department of Prosthodontics, Sree Mookambika Institute of Dental Sciences, Kulasekharam, Kanyakumari, Tamil Nadu.  
• Corresponding Author: Dr Ebinu A, Email: ebinu.abdul@gmail.com

to the target tissue in a manner that is ergonomic and precise. Two delivery systems are used in dental lasers. One is a flexible hollow wave-guide or tube that has an interior mirror finish. The laser energy is reflected along this tube and exits through a hand piece at the surgical end, with the beam striking the tissue in a non contact fashion (ie, without directly touching the tissue). Second delivery system is a glass fiberoptic cable. The cable is pliant and comes in various diameters, with sizes ranging from 200 to 1000 $\mu$ . The glass fiber, although encased in a resilient sheath, can be fragile and cannot be bent into sharp angle. This fiber system can be used in contact or non-contact mode, mostly contact mode.

**Emission modes:**

Laser device can emit the light energy in one of 3 basic modes:

Continuous wave: the beam is emitted at one power level continuously as long as the device is activated. Gated pulse mode: there are periodic alterations of the laser energy being on and off, similar to a blinking light. This mode is achieved by the opening and closing of a mechanical shutter in front of the beam path of a continuous wave emission. Duration of on and off times normally is as small as a few milliseconds. Free running pulsed mode: This mode is unique in that large peak energies of laser light are emitted for an extremely short time span, usually in micro seconds, followed by a relatively long time in which the laser is off.

**Laser tissue interaction:**

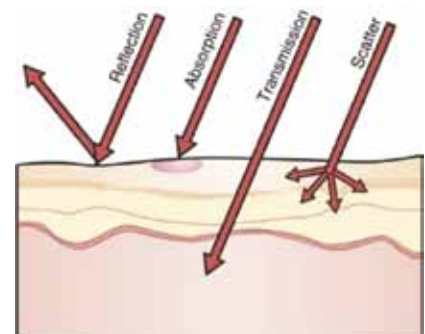
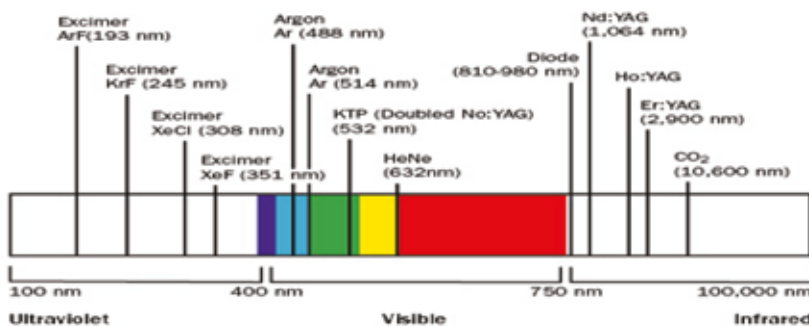
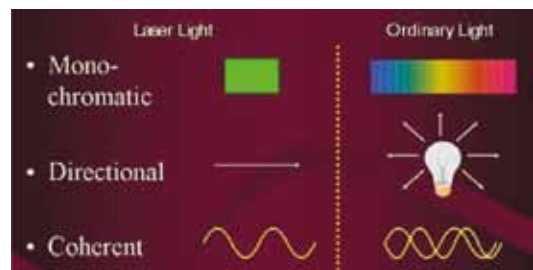
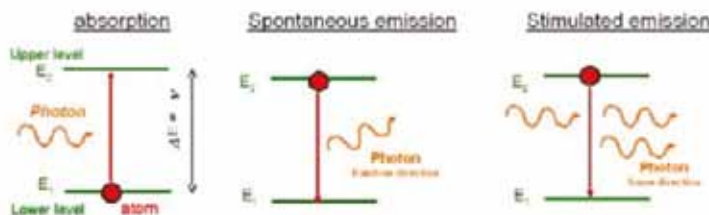
Laser has four different interactions with the target tissues, depending on the on the optical properties of that tissue.

The first and the most desired interaction is the absorption of the laser energy by the intended tissue. The amount of energy that is absorbed by the tissue depends on the tissue characteristics, such as pigmentation and water content, and on the laser wavelength and emission mode. In general, the shorter wavelengths (from about 500-1000nm) are readily absorbed in pigmented tissue and blood elements. The longer wavelengths are more interactive with water and Hydroxyapatite.

The second effect is the transmission of laser energy directly through the tissue with no effect on the target tissue, the inverse of absorption.

The third effect is reflection, which is the beam redirecting itself off the surface, having no effect on the target tissue. The caries detecting laser device uses the reflected light to measure the degree of sound tooth structure. The reflection can be dangerous because the energy is directed to an unintentional target, such as the eyes: this is the major safety concern for the laser operation.

The fourth effect is the scattering of the laser light, weakening the intended energy and possibly producing no useful biologic effect. Scattering of the laser beam could cause



heat transfer to the tissue adjacent to the surgical site, and unwanted damage could occur. However, a beam deflected in different directions is useful in facilitating the curing of composite resin or in covering a broad area.

### Laser wavelengths used for dentistry

#### ARGON

Argon lasers is fiberoptically delivered in continuous – wave and gated – pulse modes. Two emission wavelengths 488nm (blue in color) and 514 nm (blue – green). Both wavelengths are not well absorbed in dental hard tissues and are poorly absorbed in water. It can be used as an aid in caries detection. The diseased, carious area appears as dark orange-red color and is easily discernible from the healthy structures.

#### CO<sub>2</sub> LASER:

CO<sub>2</sub> laser delivered through a hollow-tube like wave guide in continuous or gated pulse mode. Wavelength – 10,600 nm. Well absorbed by water. Rapid soft tissue remover and has a shallow depth of tissue penetration, which is important when treating mucosal lesions. Especially useful for cutting dense fibrous tissue. Focused onto the surgical site in a non-contact fashion. Loss of tactile sensation is disadvantageous.

#### Nd:YAG

Has a solid active medium, a crystal of yttrium – aluminium – garnet doped with neodymium. Fiberoptically delivered in a free running pulsed mode. Most often in contact with the tissue. First laser designed exclusively for dentistry. Emission wavelength is 1064 nm. Highly absorbed by pigmented tissue and is about 10,000 times more absorbed by water than an argon laser. Common clinical applications are for cutting and coagulation of dental soft tissues with good hemostatic capability.

#### Ho: YAG

Has solid active medium, a crystal of Y.A.G. doped with Holmium. Fiberoptically delivered in contact with the tissue in free-running pulsed mode. Wavelength – 2120 nm. Absorbency by tooth structures is low. Frequently used for arthroscopy surgery on the TMJ.

#### DIODE

Have a solid active medium; it is a solid-state semiconductor laser that uses some combination of Al, gallium and arsenide to change electric energy into light energy. Wave length range from 800-980nm. Laser energy is delivered fiberoptically in continuous-wave and gated – pulse mode; used in contact with the tissue. Poorly absorbed by tooth structure so that soft tissue surgery can be performed safely

in close proximity to enamel, dentine and cementum. An excellent soft tissue surgical laser indicated for cutting and coagulating gingiva and mucosa and for soft tissue curettage, or sulcular debridement.

#### ► Er, Cr:YSGG and Er:YAG

Er, Cr:YSGG (2790 nm) has an active medium of a solid crystal of yttrium – scandium-gallium-garnet that is doped with erbium and chromium. Er:YAG (2940 nm) has an active medium of a solid crystal of Yttrium-Al-Garnet that is doped with erbium.

Both are delivered fiber optically in the free running pulsed mode. The fibers are air-cooled and have a larger diameter than the other lasers mentioned, making the delivery system somewhat less flexible. They have the highest absorption in water of any dental wave length and have a high affinity for hydroxyapatite. These lasers are ideal for caries removal and tooth preparation when used with a water spray.

#### ► Applications of laser in dentistry

##### Periodontics

- Frenectomy
- Gingivectomy
- Graft
- Periodontal regeneration surgery
- De- epithelialization
- Removal of granulomatous tissues
- Osseous recontouring

##### Fixed prosthetics

- Crown lengthening/ soft tissue management around abutment.
- Osseous crown lengthening.
- Gingival troughing
- Formation of ovate pontic sites.
- Altered passive eruption management.
- Modification of soft tissue around laminates.

##### Implantology

- Second stage recovery
- Peri-implantitis

##### Removable prosthetics

- Epulis Fissuratum.
- Denture stomatitis.
- Residual ridge modification.
- Tuberosity reduction.
- Torus reduction.
- Soft tissue modification.

### Pediatrics/ Orthodontics

- Exposure of teeth.
- Soft tissue management of orthodontic patients.

### Oral surgery/ Oral medicine/ Oral Pathology

- Biopsy
- Operculectomy.
- Apisectomy.
- Oral soft tissue pathologies.

### Operative dentistry

- Detection of caries
- Removing decay painlessly and atraumatically without affecting the surrounding healthy tissues.
- For removal of defective composite, GIC, compomer restorations quickly and easily without the use of analgesia.
- Bleaching of teeth (Power Bleaching).

### Endodontics

- Debridement of the canal.
- Instrumentation of the canal.
- Removal of the smear layer.
- Sterilization of the canal.
- Sealing of the main and accessory canals.

### ► Conclusion

Laser technology for hard tissue and soft tissue is at a high state of refinement, having several decades of development, up to the present time, and further improvements can occur. A further area of future growth is expected to be a combination of diagnostic and therapeutic laser techniques. Looking to the future, it is expected that specific laser technologies will become essential components of contemporary dental practice over the next decade.

### ► References

1. Lasers in Dentistry - Leo.J. Miserendino / Robert M. Pick.
2. Lasers in Maxillofacial surgery and dentistry - By: Lewis, Clayman, and Paul Kuo.
3. Miserendino LJ. The history and development of laser dentistry. Ch 1 in: Miserendino LJ, Pick RM, editors. Lasers in dentistry. Chicago:Quintessence; 1995: p 17-26.
4. Miller M, Truhe T. Lasers in dentistry. An overview. J Am Dent Assoc 1993; 124: 32-36.
5. Coluzzi DJ. An overview of laser wavelengths in dentistry. Dent Clin N Am 2000; 44(4) 753-65.
6. Coluzzi DJ. Fundamentals of dental lasers: science and instruments. Dent Clin N Am 2004; 48: 751-70.
7. Suleiman M. An overview of the use of lasers in general dental practice: 1. Laser physics and tissue interactions. Dental update 2005; 32(4): 228-236.
8. Pick RM, Colvard MD. Current status in soft tissue dental surgery. J periodontal 1993; 64: 589-602.
9. Rice JH. Laser use in fixed, removable and implant dentistry. Dent Clin N Am 2000; 44(4): 767-77
10. Zakariasen KL. Shedding new lights on lasers. J Am Dent Assoc 1993; 124: 30-31.

## Link discovered between oral health and low testosterone in men

### A new study uncovered valuable information that could have major implications for men's health.

More than 20 species of macaques, the most widely distributed nonhuman primates in the world, socialize in lively troops and make frequent appearances on National Geographic documentaries. But, what can we learn from one of our closest primate relatives about our own oral health?

Quite a bit, according to findings from a retrospective study done by Texas A&M University Baylor College of Dentistry researchers. Their work, which was recently published in the *American Journal of Physical Anthropology*, indicated that lack of testosterone left these monkeys with periodontal disease.

# Critical evaluation of minimally invasive surgical techniques in Periodontics

\*Thomas George V, \*\*Bindiya Balram, \*\*Annu Elizabeth Joseph,  
\*\*Merry Mariyam Varghese, \*\* Neethu Mercy James

## Abstract

Minimally invasive surgery provides a wide range of brand new possibilities for periodontal surgery with improved therapeutic and cosmetic results. These techniques have proven to be advantageous over conventional therapy due to their approaches with minimized incisions and trauma to soft tissues.

**Keywords:** Minimally invasive, periodontal surgery

KDJ 2017 | Vol. 40 | No. 4 | Pg 225-229

## ► Introduction

Till 1890s morbidity and mortality were considered as unavoidable consequences of therapeutic process. But now less invasive treatment modalities, minimally invasive surgery have proved to produce much fewer complications. Microsurgery was defined by Daniel R.K in 1979.<sup>1</sup> Serafin defined periodontal microsurgery in 1980 as a methodology, a modification or refinement of existing surgical technique that uses magnification to improve visualization and has implications for and applicability to all specialities. Belcher et al in 2001<sup>2</sup> described the key elements which form the microsurgical triad (illumination, magnification, instruments). Visual aid in microsurgery is provided by 3 types of loupes, fibreoptic endoscope (Fig. I<sup>3,4,5</sup>).

The term minimally invasive surgery was first coined by Wickham and Fitzpatrick (1990)<sup>6</sup>. The application of minimally invasive surgery for the treatment of periodontal disease was first described by Harrel et al<sup>7</sup>. Further modifications of this technique were proposed by Cortellini and Tonetti which included MIST and M-MIST. (Table I)

Adequate illumination and visibility is essential for such technique sensitive procedures, so, surgeons have utilized surgical loupes, fiberoptic endoscopes and surgical microscopes. Later Video scope Assisted Minimally Invasive Surgery (VMIS) were introduced<sup>8</sup>, which consists of a high-definition digital camera which is placed at the end of a flexible tube of 2.7 mm diameter featuring a carbon fiber retractor that may be rotated to aid in flap reflection and a gas-shield that prevents blood and other contaminants from obscuring the camera, allowing improved visualization of the defect once inserted into the surgical site.

## Applications of minimally invasive surgery in Periodontics

### 1. Pocket Therapy (Table II<sup>9</sup>)

Studies have reported the microscope with its high magnification and illumination to be effective to assess the treatment results in severe chronic periodontitis, or furcation areas. Endoscopic debridement ensures sub

gingival visualization of the root surface at magnifications ranging from 24X to 48X.

Laser assisted new attachment procedure (LANAP) was developed aiming treatment of moderate to severe periodontitis especially teeth with hopeless prognosis. It is carried out using the Nd:YAG laser. This procedure ensures removal of pocket lining, elimination of periodontal pathogens, achieves hemostasis and also carries out photo-bio modulation. Hence there is a significant improvement in treatment outcomes. Laser assisted comprehensive pocket treatment (LACPT) is a minimally invasive surgical procedure using Er:YAG laser for management of moderate to severe chronic periodontitis with deep vertical defects. A laser in minimally invasive periodontal and peri-implant therapy (LAPIP) incorporates the LANAP protocol to treat teeth for the treatment of ailing dental implants. Evidence proves that laser treatment has the potential to improve treatment outcomes.

### 2. Periodontal regeneration procedures for osseous defects: (Table III<sup>10-13</sup>)

### 3. Periodontal Plastic Surgery (Table IV<sup>14-15</sup>)

Early attempts at root coverage included lateral flaps, free gingival grafts, and coronally advanced flaps, but the

\* Professor and Head, \*\*Post Graduate Student, Department of Periodontics and Implantology, Pushpagiri College of Dental Sciences, Thiruvalla, Kerala. • Corresponding Author: Dr Thomas George V., Email: thomasgeorge@rediffmail.com

results of these methods were often unpredictable. The application of minimally invasive surgery presents a new frontier for predictable esthetic results.

Muthukumar et al (2015)<sup>16</sup> presented a case series on surgical augmentation of interdental papilla discussing two

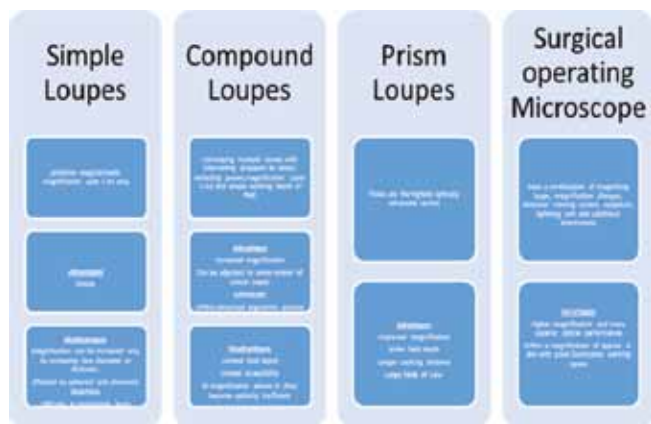


Figure 1

Table I: Procedure of MIST and M-MIST

MIST	M-MIST
<p>Two different techniques:</p> <ol style="list-style-type: none"> <li>1) elevation of tiny buccal flap as well as interdental papilla and palatal flap.</li> <li>2) techniques that are limited to elevation of buccal flap</li> </ol> <p>MIS flap is reflected only to the mucogingival junction.                      No vertical incisions are used                      MIS can be used for flap debridement or flap curettage procedures,                      but it is most often used for regenerative procedures in isolated sites.</p>	<p>Generally attempt access to defect only from buccal side.                      Triangular buccal flap is minimally elevated to expose residual buccal bone crest                      Does not involve the mucogingival line                      Interdental papilla is not detached from residual interdental bone crest and supra crestal fibers                      Palatal flap not elevated</p>

MIS-minimally invasive surgery, MIST-minimally invasive surgical technique.

Table II: Microsurgery assisted pocket therapy

Author and year	Diagnosis	Sample	Time	Method	Clinical parameters	Result	Conclusion
Peter Kotschy2010 <sup>9</sup>	Chronic generalized periodontitis	24	12 months	Periodontal pocket surgery assisted by optical microscope with a magnification power of 15× to 20× combined with kinetic glass bead blasting	PPD, BOP, CAL and plaque index	Significant reduction in PPD and CAL	Excellent result compared to conventional therapeutic approaches.

PPD-probing pocket depth, BOP-bleeding on probing, CAL-clinical attachment level

techniques. These included semilunar coronally repositioned papilla technique (as described by Han and Takei) and the other technique was by modification of Nordland’s microsurgical technique.. Complete reconstruction was achieved in all cases after 6 months.

**4. Piezocision- assisted orthodontic treatment**

It is a minimally invasive periodontally accelerated orthodontic tooth movement based on the regional acceleratory phenomenon (RAP). This procedure combines micro incision with selective tunneling that allows for hard and soft tissue grafting and the piezoelectric incision helps in rapid orthodontic tooth movement.

**5. Implant therapy**

All phases of implant treatment may be performed using a microscope. Increased visual acuity, improved ergonomics, and body posture are closely related to these improvements. Since surgical trauma is reduced hence it results in reduced pain and faster healing. Additionally dental implant drilling

**Table III:** Minimally invasive surgical techniques in management of osseous defects

Author and year	Study interval	Study design	sample	criteria	Methods	Clinical parameters	Outcome
Cortellini et al 2011 <sup>10</sup>	1 year	A randomized-controlled trial	45	With at least one isolated deep, predominantly inter-dental intra-bony defect	The M-MIST the regenerative material was applied	Pocket depth reduction, Attachment level gain, radiographic bone fill and patient-related outcomes.	Radiographic bone fill of the intra-bony component was 77 _ 19% in the M-MIST 71 _ 18% in the EMD and 78 _ 27% in the EMD+BMDX group.
Ribeiro et al 2013 <sup>11</sup>	12 months	Randomized, controlled trial	29	One single-rooted tooth with intrabony defect	MINST (minimally invasive nonsurgical technique) Vs MIST (minimally invasive surgical technique) and quantification of Aa, Tf and Pg	Probing depth, position of gingival margin and relative clinical attachment level	Clinical outcome: both groups significant PD reductions, RCAL gains, and no change in the PGM. Microbiological outcomes: significant reduction in Pg and Tf.
Elyan Al Machot et al 2014	12 months	RCT	38	Single intrabony defect with more than 2mm radiographic width and at least 4mm depth	MIST + EMD Vs MIST + Nano crystalline hydroxyapatite	PD, REC, PI	Significant bone fill, reduction of PPD, CAL after 6 and 12 months.
Harrel et al 2014 <sup>12</sup>	12 months	Prospective cohort	30 patients	Residual PPD ≥ 5 mm, CAL ≥ 2 mm, and radiographic evidence of bone loss	Videoscope-assisted minimally invasive surgery (V-MIS)	PPD, CAL and soft tissue height	Statistically significant improvement in mean PPD and CAL in 1, 2, and 3 wall defects. Mean post-surgical increase in soft tissue height with a decrease in recession.
Harrel et al 2017 <sup>13</sup>	36-58 months	Masked prospective cohort clinical outcomes study	14 patients	Sites with residual PPD at least 5 mm and 2 mm of clinical attachment level (CAL) loss	Direct video scope observation debridement and placement of EMD + FDBA	PPD, CAL, recession, soft tissue height	Statistically significant improvement mean PPD and CAL in all surgical sites Also mean Improvement in soft tissue height.

EMD-enamel matrix derivative, M-MIST-modified minimally invasive surgical technique, PD-pocket depth, MIST- minimally invasive surgical technique, PGM-position of the gingival margin, RCAL-relative clinical attachment level, SFA- single flap approach, GTR/HA- guided tissue regeneration (GTR) combined with a hydroxyapatite (HA), REC- limited gingival recession, MIS- minimally invasive surgery, RAL-relative attachment level, RGR-relative gingival recession, BMDX - bone mineral derived xenograft, MINST-minimally invasive non-surgical technique, Aa-Aggregatibacter Actinomycetemcomitans, Tf- Tannerella forsythia, Pg-Porphyrromonas gingivalis, PI-plaque index, FDBA- freeze dried demineralized human cortical bone.

precision is improved. Microscopes allow immediate detection of subtle changes in drill position. The implant drill angle can be accurately oriented to root surface angulations using 3-4 mm of root anatomy exposed between CEJ and osseous crest.

**Ridge augmentation:**

Microsurgery and minimally invasive surgery can increase the predictability of various ridge augmentation techniques. In addition to establishing adequate vertical height, sufficient soft tissue thickness must be created to provide an emergence profile for pontics or dental implant prosthesis. Minimally invasive horizontal ridge augmentation (MIHRA), by subperiosteal tunneling was first described by Kent et al.

Kim et al 2016<sup>17</sup> conducted a retrospective study on MIHRA with variable bone graft materials using subperiosteal tunneling technique followed by immediate or delayed implant surgery. After an average of 2.8 months, the prosthesis

was connected and functioned. The clinical prognosis was recorded by observation of the peri-implant tissue at every visit and he concluded that the bone graft material retained within a pouch formed using U-shaped incision and tunneling technique resulted with a few complications, and the prognosis of the implants placed above the alveolar bone was adequate.

**6. Sinus augmentation**

Atrophic posterior maxilla is challenging for implant placement. As compared to conventional surgical techniques minimally invasive sinus floor augmentation procedures have comparatively improved the clinical outcome. Stephanie Gonzalez et al 2013<sup>18</sup> did a crestal approach for maxillary sinus augmentation in patients with ≥4 mm of residual alveolar bone, concluded that the residual alveolar bone height did not increase crestal bone loss or reduce the success rate of the implants and associated prostheses.

**Table IV** Minimally invasive surgical techniques in root coverage procedures

Author	Study interval	design	sample	criteria	Methods	parameters	result
Nevins M et al 2014 <sup>14</sup>	9 months	Single-center, prospective study	8	With advanced periodontitis	Full-mouth LANAP therapy	Clinical attachment level (CAL), probing depth (PD), and recession,	Significant reduction in mean PPD and CAL
Jindal U et al 2015	6 months	Randomized split mouth study	30	Miller’s Class I and II recession	Sub-epithelial connective tissue graft from the palate. Group A-graft placed with unaided eye. Group B-with surgical microscope.	Plaque index, gingival index, vertical recession, probing depth, clinical attachment level, width of attached gingiva, papilla height and width, malalignment index and esthetic appearance.	Both the techniques demonstrated predictable Mean root coverage. CAL gain was slightly better in Group B patients
Ucak O et al 2017 <sup>15</sup>	6 months	Randomized Controlled Clinical Trial	50	Miller Class III isolated recession type defects in incisors and canines	Laterally moved coronally advanced flap (LMCAF) technique with magnified vision	Complete root coverage and mean root coverage were assessed.	Patient satisfaction with esthetics and postoperative morbidity were better in the LMCAF-M group

LANAP- Laser-Assisted New Attachment Procedure, LMCAF-M- Laterally moved coronally advanced flap technique with magnified vision.



Kim et al (2017)<sup>19</sup> evaluated the clinical outcomes of patients undergoing sinus membrane elevation by a minimally invasive crestal approach using a novel drilling system with immediate implant placement. There was no sinus perforation or osseointegration failure. The implant survival rate was 100% and concluded that sinus membrane elevation by the crestal approach using special reamers is advantageous because of the noticeable reduction in the risk of perforation and the ability to perform the surgery rapidly

### Future perspective

#### Robotic microsurgery

The da Vinci robotic surgical system is the only commercially available robotic surgical system approved by the Food and Drug Administration (FDA). The first da Vinci system was launched in 1999. The latest system (Si system) has one camera arm and three instrument arms and provides a three-dimension (3D) high-definition view in the surgeon console. The da Vinci surgical system includes three components: a surgeon console, patient cart (the robotic arms), and an imaging tower.

#### HDTV Single Camera 3D System

This comprises of a three dimensional High Definition Television attached to a stereoscopic microscope. This empowers 3D visualization and documentation of microsurgery and endoscopic surgery. Mochizuki et al (1994) presented HDTV single camera 3D system and its application in Microsurgery

#### TOMS-Three Dimensional On-Screen Microsurgery System

Garcia et al (1994) published an article on True-stemoscopic video from monoscopic sources: The deep VisionR system for minimal invasive surgery. The assembly of the three dimensional on-screen microsurgery system comprises of two single chip video cameras (Sony XC-999) mounted on custom fit eyepiece adapters, a dual camera-controller, a view/record image processor, a VCR for optional recording, digital monitor to enable viewing, synchronizing signal emitter and 120 MHz shutter glasses (stereo eye wear).

### ► Conclusion

Minimally invasive surgery provides a wide range of brand new possibilities for periodontal surgery with improved therapeutic and cosmetic results. Adequate visualization of the root surface and the periodontal defect is mandatory for the success of the increasingly smaller surgical access openings that are used in current minimally invasive techniques. Periodontics in future will see much more use of magnification in all areas of practice.

### ► References

1. Daniel RK. Microsurgery: Through the looking glass *Engl J Med* 1979; 300:1251–1257.
2. Belcher JM, A Perspective on Periodontal Microsurgery. *Int J Periodontics Restorative Dent* 2001; 21:191–6.
3. Shanelec DA. Optical principles of loupes. *Calif Dent Assoc J* 1992; 20:25–32.
4. Hedon P, Wineman M, Winston RNI. Loupes or microscope for tubal ligation anastomosis. *Fertil Steril* 1980; 34:264–268.
5. Rock JA, Bergquist CA, Kimball AW Jr, Zacur HA, King TM. Comparison of the operating microscope and loupes for microsurgical tubal anastomosis: A randomized clinical trial. *Fertil Steril* 1984; 41:229–232
6. Fitzpatrick JM, Wickham JE. Minimally invasive surgery (editorial). *Br J Surg* 1990; 77:721–722.
7. Harrel SK, Rees TD. Granulation tissue removal in routine and minimally invasive procedures. *Compend Contin Educ Dent* 1995; 16:960, 962- 964.
8. Harrel SK, Wilson TG Jr, Rivera-Hidalgo F. A videoscope for use in minimally invasive periodontal surgery. *J Clin Periodontol* 2013; 40: 868–874 J
9. Kotschy P. Optimal root cleaning andmicroinvasive periodontal pocketsurgery with microscope controlled glass bead blasting. *Int J Microdent* 2010; 2:48–55.
10. Cortellini P, Tonetti MS. Clinical and radiographic Outcomes of the modified minimally invasive surgical technique with and without regenerative materials: A randomized-controlled trial in intrabony defects. *J Clin Periodontol* 2011; 38:365-373.
11. Ribeiro, FV, Casarin, RC, Palma, M.A.G Clinical and microbiological changes after minimally invasive therapeutic approaches in intrabony defects: a 12-month follow-up. *Clin Oral Invest* (2013) 17: 1635-1644
12. Harrel SK, Abraham CM, Rivera-Hidalgo F, Shulman J, Nunn M. Videoscope-assisted minimally invasive periodontal surgery (V-MIS) *J Clin Periodontol*2014;41:900-7.
13. Harrel SK, Nunn ME, Abraham CM, Rivera-Hidalgo F, Shulman JD, Tunnell JC. Videoscope Assisted Minimally Invasive Surgery (VMIS): 36-Month Results. *J Periodontol*. 2017 Jun; 88(6):528-535.
14. Nevins M, Kim SW, Camelo M, Martin IS, Kim D. A prospective 9-month human clinical evaluation of LaserAssisted New Attachment Procedure (LANAP) therapy. *Int J Periodontics Restorative Dent* 2014; 34: 21–27
15. Ucak O, Ozcan M, Seydaoglu G, Haytac M C Microsurgical Instruments in Laterally Moved, Coronally Advanced Flap for Miller Class III Isolated Recession Defects: A Randomized Controlled Clinical Trial. *Int J Periodontics Restorative Dent* 2017;37:109–115
16. Muthukumar S, Rangarao S. Surgical augmentation of interdental papilla - A case series. *Contemp Clin Dent* 2015; 6, Suppl S2:294-8.
17. Kim HS, Kim YK, Yun PW. Minimal invasive horizontal ridge augmentation using subperiosteal tunneling technique, *Maxillofac Plast Reconstr Surg*. 2016 Dec; 38(1): 41
18. Gonzalez S, Tuan MC, Ahn, KM, Nowzari H. Crestal Approach for Maxillary Sinus Augmentation in Patients with 24 mm of Residual Alveolar Bone. *Clinical Implant Dentistry and Related Research*, 2014; 16(6):827-835
19. Kim YK, Lee JY, Park JW, Kim SG, Oh JS. Sinus Membrane Elevation by the Crestal Approach Using a Novel Drilling System. *Implant Dent* 2017 Jun; 26(3):351-356..

# A novel costeffective device for chairside preparation of PRF membrane

\* Joshy P Abraham, \*Jaysa J.J., \*Sreelakshmi S., \*\*Kurien Varghese

## Abstract

Platelet rich fibrin (PRF) is a second generation platelet concentrate widely used to accelerate soft and hard tissue healing. PRF membranes are used to protect and stabilize the graft material. The membrane act as fibrin bandage and thus accelerates the healing process.

The choukroun PRF box was devised to produce membrane of constant thickness from platelet rich fibrin clot which is compressed and shaped to fill the surgical site.

This article intent to put forth a chairside alternative device for fabrication of PRF membrane

**Keywords:** PRF Membrane, AKJ Device

KDJ 2017 | Vol. 40 | No. 4 | Pg 230-231

## ► Introduction

Plasma Rich Fibrin (PRF) is an autologous fibrin matrix containing platelet and leukocyte cytokines in large quantities. PRF forms a source of growth factors that facilitate tissue repair and regeneration. Growth factor concentrate in PRF is widely used to accelerate soft and hard tissue healing. Fibrinogen to fibrin conversion in plasma rich protein (PRP) improves the handling efficiency, the retention at application

sites, and the release of growth factors. This conversion is preferentially achieved by adding calcium or thrombin to PRP<sup>1</sup>

Choukroun et al in 2001 introduced a simple method to prepare plasma fibrin gel without addition of exogenous supplements. This fibrin gel is designated as PRF and is widely recognized as a new generation of PRP<sup>2</sup>. Advantages of PRF over PRP include its strict autologous nature, ease of preparation and minimal expense<sup>3</sup>.

## Significance of PRF in wound healing

Several studies have shown that wound healing and bone regeneration may be enhanced by addition of specific growth factors<sup>4</sup>. Ross et al were the first to describe growth factors from platelets.

Platelet activation in response to tissue damage and vascular exposure results in the formation of a platelet plug and blood clot as well as the secretion of biologically active proteins that stimulate mitogenic response in bone periosteum during healing<sup>5</sup>. Platelet alpha ( $\alpha$ ) granules form an intracellular storage pool of growth factors (GF) including platelet-derived growth factor (PDGF), transforming growth factor  $\beta$  (TGF- $\beta$ , including  $\beta$ -1 and  $\beta$ -2-isomers), vascular endothelial growth factor (VEGF), and epidermal growth factor (EGF). Insulin-like growth factor-1 (IGF-1), which is present in plasma, can exert chemotactic effects towards human osteoblasts<sup>6</sup>. Fibrin also provides a matrix for the migration of fibroblasts and endothelial cells that are involved in angiogenesis and responsible for remodelling of new tissue.



Fig. 1 Compression of clot using moist gauze.



Fig. 2 Choukroun Box



Fig. 3,4 AKJ Box

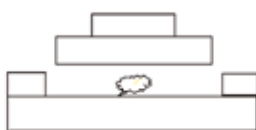


Fig. 5 Design of compressor and presser plate



Fig. 6,7 Sterile gauze placed between plates to prevent surface tension

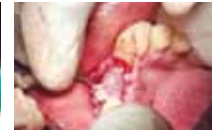

Fig. 8 Prf membrane fabricated using AKJ box been placed at the surgical site

\*Postgraduate student, \*\*Professor and HOD, Department of Prosthodontics, Azeezia College of Dental Sciences and Research. Meeyannoor, Kollam • Corresponding Author: Dr Joshy P Abraham, E-mail: joshkylm@gmail.com

### Method of preparing PRF

Human blood clot comprises of 95% red blood cells (RBCs), 5% platelets, less than 1% white blood cells (WBCs), and numerous amounts of fibrin strands, whereas, a PRP blood clot contains 4% RBCs, 95% platelets, and 1% WBCs<sup>7</sup>.

PRP preparation protocol requires blood sample that is collected without an anticoagulant in 10-mL tubes. It is immediately centrifuged at 3,000 rpm (800 g) for 10 min. Activation of platelets within the sample trigger coagulation cascade within few minutes. Initially fibrinogen is concentrated at the upper part of the tube. Action of thrombin then transforms fibrinogen to fibrin network. Resulting is fibrin clot containing the platelets located in the middle of the tube, acellular plasma at the top and the red blood cell layer at the bottom. This clot is removed from the tube and the attached red blood cells scraped off.<sup>8</sup>

PRF clot is then compressed to form a membrane that can be adapted to the surgical site. Various techniques have been adopted PRF membrane fabrication. Conventionally compression of clot using moist gauze is used (fig 1). However, there has been concern whether this compression may damage the platelets and exude significant quantities of valuable growth factors.

The Choukron's PRF Box was devised to produce membranes of constant thickness that remain hydrated for several hours and to recover the serum exudate expressed from the fibrin clots which is rich in the proteins vitronectin and fibronectin. The exudate collected at the bottom of the box may be used to hydrate graft materials, rinse the surgical site, and store autologous grafts (fig 2).

### “AKJ PRF box”

AKJ box is a novel and economic device for preparing PRF membrane (fig 3,4). The device function in such a way that the platelets and growth factors should be retained with minimal damage for activation of healing process. The AKJ box helps to form a thin fibrin membrane from PRF clot which forms a scaffold over the grafted area after implant placement which prevent graft escape and promotes healing of the site.

AKJ PRF box is a PRF compression device made of 1 inch thick glass slab. Base of the device with confined edges receives the PRF clot. A pressor plate with a handle is provided. PRF clot can be compressed easily using the pressor plate against the base (Fig 5). A sterile gauze can be placed between two plates so as to prevent surface tension between plates and to ensure easy removal of the pressor plate (fig 6,7). This device ensure that the PRF membrane is confined with device with minimal loss of exudate (fig 8).

### ► Conclusion

It is very important to perform the highest level of quality control on the PRF preparations prior to their application in a clinical setting. PRF preparations as a grafting material for tissue regeneration, should be enriched with platelets and growth factors. In this regard, our novel compression device would be effective and useful for preparation of biologically active PRF; the author found it very useful for the preparation of chair side PRF membrane.

### ► References

1. Nagata M, Hoshina H, Li M, Arasawa M, Uematsu K, Ogawa S, et al. A clinical study of alveolar bone tissue engineering with cultured autogenous periosteal cells: coordinated activation of bone formation and resorption. *Bone* 2012; 50:112
2. Choukroun J, Adda F, Schoeffler C, Vervelle A. Uneopportunit enparodontologie: le PRF. *Implantodontie* 2001; 42:55-62
3. Michael Toffler, Nicholas Toscano, Dan Holtzclaw, Marco Del Corso, David Dohan Ehrenfest; Introducing Choukroun's Platelet Rich Fibrin (PRF) to the Reconstructive Surgery Milieu. *The Journal of Implant & Advanced Clinical Dentistry*; Vol. 1, No. 6, September 2009.
4. Jung RE, Glauser R, Scharer P, Hammerle CH, Sailer HF, Weber FE. Effect of rh-BMP-2 on guided bone regeneration in humans. *Clin Oral Implants Research* 2003; 14:556-568.
5. Ross R, Glomset J, Kariya B, Harker L. A platelet-dependent serum factor that stimulates the proliferation of arterial smooth muscle cells in vitro. *Proc Natl AcadSci U S A*. 1974;71:1207-10.
6. Soffer E, Ouhayoun JP, Anagnostou F. Fibrin sealants and platelet preparations in bone and periodontal healing. *Oral Surg Oral Med Oral Pathol Oral RadiolEndod*. 2003;95:521-8.
7. Nevins M, Giannobile WV, McGuire MK, Kao RT, Mellonig JT, Hinrichs JE, et al. Platelet-derived growth factor stimulates bone fill and rate of attachment level gain: Results of a large multicenter randomized controlled trial. *J Periodontol*. 2005;76:2205-15
8. Dohan DM, Choukroun J, Diss A, Dohan SL, Dohan AJ, Mouhyi J, Gogly B. Platelet-rich fibrin (PRF): a second-generation platelet concentrate. Part II: platelet-related biologic features. *Oral Surg Oral Med Oral Pathol Oral RadiolEndod* 2006; 101:e45-50.

# Prosthetic rehabilitation of missing anterior tooth using ever stick C&B bridge

\* Reshmi Raghuvaran, \* Sreelekshmy R., \* Sameera S.A., \*\* Joy Kurian

## Abstract

A variety of therapeutic modalities, from conventional Maryland bridges to implants, can be used for the replacement of missing anterior tooth. Fiber-reinforced composite (FRC) bridges can be a good alternative to conventional prosthetic techniques. The purpose of this case report is to present a clinical case of a single tooth replacement in a thirteen year old female patient with a history of fracture of root canal treated upper left central incisor by means of a ever Stick C&B Bridge. The technique provides positive aesthetic and functional results that may reflect on self-esteem and social inclusion especially in cases of young patients where implant therapy is not usually indicated.

**Key words:** fibre- reinforced composite, anterior tooth replacement, aesthetics

KDJ 2017 | Vol. 40 | No. 4 | Pg 232-234

## ► Introduction

In today's cosmetically conscious world, well contoured and well aligned white teeth is one of the criteria that determine the standard of beauty. An important component of idealized physical appearance is a radiant smile displaying teeth that are attractive in shape and colour. Hence, other than pain, esthetic concern has become one of the main reasons for seeking

dental care. The anterior teeth – both primary and permanent - dominate the physical appearance and hence their destruction apart from a compromise in esthetics, may also lead to parafunctional habits such as tongue thrusting, speech problems, psychological problems etc.

Prosthetic rehabilitation of edentulous space in anterior maxilla always presents an esthetic challenge to clinician and especially when it happens in a young patient, it poses a unique problem to the practitioner<sup>1</sup>. In adults, removable partial dentures, conventional fixed partial dentures or implants have been used for the replacement of missing anterior teeth. But the treatment options are limited in children, in whom the growth has not been completed. The conventional fixed partial dentures require tooth reduction which violates the current concept of minimally invasive dentistry, since these teeth rarely have caries or restorations<sup>2</sup>. Most young patients therefore, have missing anterior teeth replaced by removable appliances. Although these appliances are conservative, they can cause tissue inflammation and damage to the supporting structures of the teeth<sup>3</sup>.

The new composite resin systems, in combination with acid-etch procedure, have offered a wide range of esthetic solutions for anterior teeth problems<sup>4</sup>.

A minimally invasive and permanent method of replacing missing anterior teeth with little or no tooth structure removal is by using ever Stick C&B bridges. This clinical report presents the treatment for an adolescent girl, who had edentulous space in anterior maxilla by the replacement of fiber reinforced composite bridge.

## ► Case report

A thirteen year old female patient visited the Department of Pedodontics and Preventive Dentistry, Sri Sankara Dental College, Varkala, with the complaint of broken front tooth of upper jaw. One year back, she had a history of fall from a cycle and had an Ellis class III fracture of her upper left central incisor. She consulted a dentist and had root canal treatment done on the concerned tooth. The tooth was asymptomatic until a subsequent fall one year later which resulted in fracture of the same tooth. The medical history was non-contributory.

On clinical examination, the crown of 21 showed yellowish discoloration with Ellis class VI fracture and the fractured portion of the root was seen protruding through the labial gingiva (Fig 1). Radiographic examination revealed vertical fracture of 21.

Extraction of 21 was planned due to poor prognosis. Considering the age of

\* Post Graduate student, \*\* Professor and Head of the Department, Dept of Pedodontics and Preventive Dentistry, Sri Sankara Dental College, Varkala, Trivandrum • Corresponding Author: Dr. Reshmi Raghuvaran, E-mail: reshmiraghu147@gmail.com

the patient, a removable temporary prosthesis was suggested. The patient was not interested in conventional removable partial denture and insisted on having a fixed prosthesis. So applying the principles of minimally invasive dentistry, an anterior bridge using fiber reinforced composite – ever Stick C&B bridge, was planned, as it is a conservative method with no tooth preparation. The patient and her parents were informed about the usage of fiber reinforced composite bridges and they accepted this treatment plan option.

The patient was recalled after the healing of extraction site in relation to 21. First, the area to be bonded i.e., the lingual aspects of 11 and 22, was cleaned with pumice and water mix, rinsed with water and air-dried. Then the surfaces of teeth in the bonding areas, was etched with 35% phosphoric acid for 45 seconds. After rinsing with water and air drying the areas, bonding agent was applied and light cured. The fibre should cover approximately two-thirds of the width of the supporting tooth's crown. The required amount of fibre together with its silicone

bedding was cut. Then a thin layer of flowable composite – GC genial composite was applied to the bonded teeth surfaces. The fibre was placed on the tooth on top of the uncured flowable composite and light cured. The fibre was spread wider on the teeth to create a more extensive bonding area and was not kept close to gingival areas to keep the cleaning areas, uncovered. Then a transverse fibre was placed on the occlusal side to support the composite pontic (Fig. 2).

After the initial light-curing, the entire fibre frame was covered with a thin layer of composite. The fibre frame was light cured for 40 seconds, one unit at a time. The fibres were covered entirely with composite, including the interproximal areas. The pontic was layered using composite according to the manufacturer's instructions. A plastic strip was used as a moisture barrier against the gingiva. The pontic region next to the gingiva had a light point contact and was self-cleaning. Finally the bridge was finished and adjusted into occlusion (Fig. 3, 4).

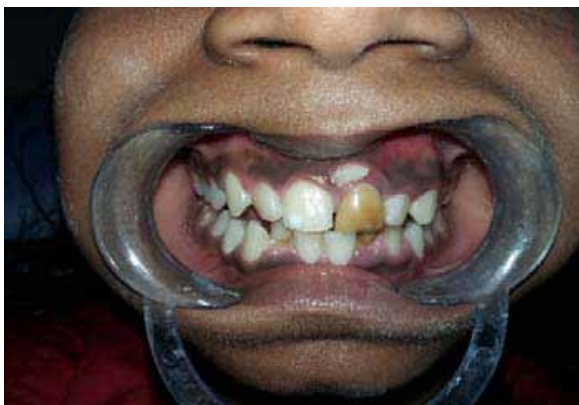

Fig 1 Pretreatment frontal view

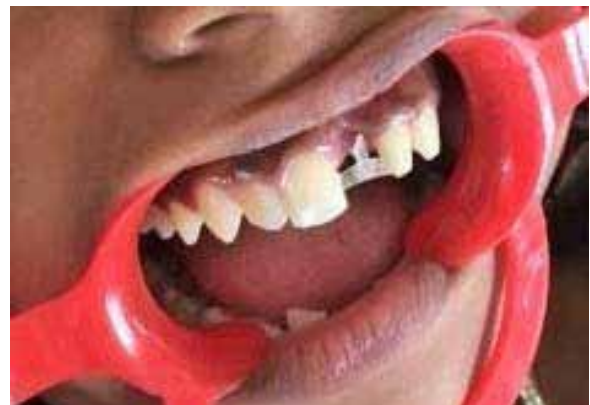

Fig 2 Transverse fibre to support pontic

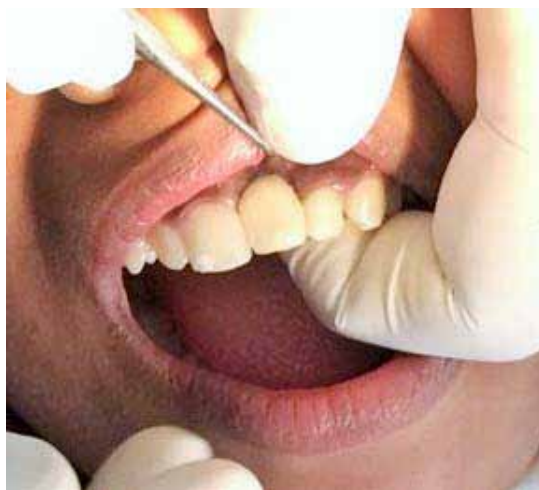

Fig 3: The composite pontic replacing 21

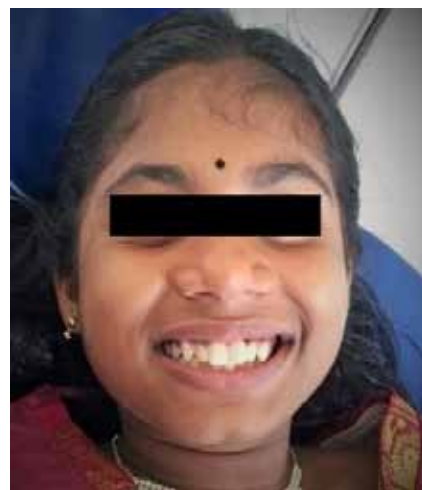

Fig 4: post treatment view

## ► Discussion

Congenital hypodontia or trauma is a frequent cause of loss of teeth in children. The absence of teeth leads to loss of function and lack of normal alveolar growth, along with unpleasant esthetics that affect the psychosocial development of the young child<sup>5</sup>. Traditionally, the management of single tooth loss in the young child is done by conservative means. The presence of large pulp chambers in immature teeth of children predisposes the pulp to loss of vitality in cases of complete coverage restorations. Hence, partial coverage prosthesis such as Maryland Bridge, resin-bonded restorations or removable prosthesis is opted in cases of multiple missing teeth. But none of these methods of treatment are completely satisfactory.

Partial dentures are dependent on the child's compliance. It can increase the rate of decay and cause gingival disease leading to bone resorption. There is also the need to refabricate a new prosthesis from time to time to compensate for craniofacial growth.

In comparison with conventional removable partial denture, fiber reinforced bridges are more esthetic, saves time, eliminates second visit, allow chair side fabrication and provide natural looking results<sup>6</sup>. Etched metal fixed partial denture requires some degree of tooth preparation. Also it is difficult to remove Maryland Bridge without damage to the prostheses or abutment tooth<sup>7</sup>.

In this case, no tooth preparation is required, providing the patient with more treatment options in the future. In 2000, Vallitu and Sevelius conducted a clinical study on the performance of 31 glass fiber-reinforced composite fixed partial dentures (FRC FPD). Two prostheses debonded during the follow-up period; 1 debonding was related to improper occlusal adjustment and the other to unknown reasons. They concluded that fiber-reinforced FPDs may be an alternative for resin-bonded FPDs with a cast metal framework<sup>8</sup>. The desire expressed by many patients for esthetic and metal free restorations has led to development of better performing composite resins. Use of fibers as reinforcement for composite resins has provided appropriate mechanical strength for composite resin to be used in replacing missing teeth<sup>9</sup>. In 2002, Freilich et al evaluated the clinical performance of fixed bridges and concluded that FRC bridges can be used successfully in a period of 5 to 10 years<sup>10</sup>. Glass fibers are most often used in FRC bridges because of their ability to withstand tensile stress and to prevent crack propagation in resin composite materials, and their esthetic character<sup>11</sup>. Each bundle consists of about 4000 glass fibers, embedded in a porous PMMA matrix. Glass-fiber reinforcements were manually impregnated with BisGMA-TEGDMA based light

polymerizing monomer resin (Stick Tech Ltd., Finland) to form a PMMA-dimethacrylate semi-inter polymer network (IPN)<sup>12,13</sup>. Low fiber volume fraction of a manually impregnated composite may result in insufficient strength of the material. Therefore, it is required to apply more than one fiber bundle in the framework, additional reinforcement at the pontic area, and to provide sufficient volume of composite at the retainer and connector sites.

## ► Conclusion

Fibre reinforced composite (FRC) bridges can show good long term and esthetic results with appropriate case selection, design and adhesion conditions. Considering the tissue saving characteristics, relatively low costs and tooth colored material, these kinds of restorations are an interesting semi permanent solution. It can be a good alternative, especially in cases of young patients where implant therapy is not usually indicated.

## ► References

1. Aydin MY. Glass fiber reinforced composite in management of avulsed central incisor: a case report. *J Dent Child* 2004; 71:66-68.
2. Gerald E.Denehy. Cast anterior bridges utilizing composite resin. *Pediatric dentistry*. 1982.
3. Heyman HO. The Carolina Bridge: a novel interim all porcelain bonded prostheses. *J EsthetRestor Dent*. 2006.18:81-92.
4. Howe, Donald F, Denehy, Gerald E. Anterior fixed partial dentures utilizing the acid etch technique and a cast metal framework. *J Prosthet Dent*.1977.28-37.
5. Agarwal N, Kumar D, Anand A, Bahetwar SK. Dental implants in children: A multidisciplinary perspective for long-term success. *Natl J MaxillofacSurg* 2016; 7:122-6.
6. Ayna E, Celenk S. Use of an alternative pontic foundation technique for a fiber reinforced composite fixed partial denture: a clinical report. *J Prosthet Dent*.2005; 93:412-415.
7. HeymanHO. The Carolina Bridge: a novel interim all porcelain bonded prostheses. *J EsthetRestor Dent*.2006; 18:81-92.
8. Vallitu PK,SeveliusC. Resin bonded glass fiber reinforced composite fixed partial denture: a clinical study. *J Prosthet Dent*.2000; 84:413-418.
9. Mete JJ, Dange SP, Khalikar AN, Vaidya SP (2011) Rehabilitation of anterior edentulous space by glass fiber reinforced composite removable partial denture during preadolescent period: a case report. *J Indian ProsthodontSoc* 11(3):195-198.
10. Freilich MA, Meiers JC, Duncan JP, Eckrote KA, Goldberg AJ. Clinical evaluation of fiber reinforced fixed bridges. *J Am Dent Assoc*.2012; 133:1524-1534.
11. Van Heumen CC, van Dijken JW, Tanner J, Pikaar R, Lassila LV, Creugers NH, Vallittu PK, Kreulen CM (2009) Five-year survival of 3-unit fiber-reinforced composite fixed partial dentures in the anterior area. *Dent Mater* 25:820-827.
12. Lastumäki TM, Lassila LVJ, Vallittu PK. The semi-interpenetrating polymer network matrix of fiber-reinforced composite and its effect on the surface adhesive properties. *J Mater Sci: Mater Med* 2003; 14: 803-9.
13. Vallittu PK. Interpenetrating polymer networks (IPNs) in dental polymers and composites. *J AdhesSciTechnol* 2009; 23:961-72.

# A novel technique for the fabrication of a lightweight maxillary hollow denture

\*Himanath K., \*\*Sudeep S., \*\*\*Dinesh N, \*\*\*Sapna Bhaskar

## Abstract

A major problem in dentistry is the prosthetic rehabilitation of deficient edentulous ridges. Although the resorption process is generally a more serious clinical problem in the mandibular arch, significant loss of alveolar bone in the maxilla can also equally problematic. In the large maxillofacial defects and in severely resorbed edentulous ridges, there is a decreased denture bearing area for support, retention and stability. Increase interridge space compounds this problem. The consequent weight of the processed complete denture can compromise them further. To decrease the leverage forces, reduction in the weight of the prosthesis was recommended. This article describes a new procedure in fabrication of hollow maxillary denture.

KDJ 2017 | Vol. 40 | No. 4 | Pg 235-238

## ► Introduction

A major problem in dentistry is the prosthetic rehabilitation of deficient edentulous ridges. Although the resorption process is generally a more serious clinical problem in the mandibular arch, significant loss of alveolar bone in the maxillae can also equally problematic. Some patients have an atrophic maxillary arch that requires

wearing a heavy maxillary denture that may consistently lose its peripheral seal. Retention, stability and support are the basic principles on which the success of a complete denture relies on. The skill lies in applying these principles efficiently in critical situations. In the large maxillofacial defects and in severely resorbed edentulous ridges, there is a decreased denture bearing area for support, retention and stability. Increase interridge space compounds this problem. The consequent weight of the processed complete denture only compromises them further. To decrease the leverage forces, reduction in the weight of the prosthesis was recommended and was also found to be beneficial. Different weight reduction approaches have been achieved using a solid 3 dimensional spacer, including dental stone, cellophane wrapped asbestos, silicone putty or modeling clay have been used during laboratory processes to exclude denture base material from the planned hollow cavity of the prosthesis. The advantage of a hollow maxillary or mandibular denture is the reduction of excessive weight of acrylic resin, which normally replaces lost alveolar ridge in the interridge space of the denture wearer. This article describes a new technique for the fabrication of a lightweight hollow denture that can be used for selected patients with advanced atrophy of the maxillae

## ► Review of literature

The double-flask technique described by Chalian and Barnett is well-known for the fabrication of the hollow bulb portion of an obturator prosthesis. Such a technique can be applied to the fabrication of a lightweight maxillary denture where there is excessive maxillary resorption and adequate interocclusal distance. This technique is useful for patients who have significant resorption of both the anterior maxillae and the mandible or at least the posterior mandible.

Holt et al. processed a shim of indexed acrylic resin over the residual ridge and used a spacer, which was then removed and the two halves luted with autopolymerized acrylic resin. The primary disadvantage of such technique is that the junction between the two previously polymerized portions of the denture occurs at the border of the denture, which increases risk of seepage of fluid into the denture cavity. Another disadvantage is that it is difficult to gauge resin thickness in the cope area.

O'Sullivan et al. described a modified method for fabricating a hollow maxillary denture. A clear matrix of trail denture base was made. The trail denture base was then invested in conventional manner till the wax elimination. A 2-mm heat polymerized acrylic resin shim was

\* PG Resident, \*\* Professor & HOD, \*\*\* Professor, Dept. of Prosthodontics, PMS College of Dental Sciences and Research, Vattappara, Trivandrum • Corresponding Author: Dr. Himanath K., E-mail: himanathekm@gmail.com

made on the master cast using a second flask. Silicone putty was placed over the shim and its thickness was estimated using the clear template. The original flask with the teeth was then placed over the putty and shim and the processing was done. The putty was later removed from the distal end of the denture and the opening was sealed with auto polymerizing resin. This case reports describes three techniques for fabrication of a hollow maxillary complete denture in a patient with resorbed maxillary and mandibular ridges and increased interridge distance.

Fattore et al. used a variation of the double flask technique for obturator fabrication by adding heat polymerizing acrylic resin over the definitive cast and processing a minimal thickness of acrylic resin around the teeth using a different drag. Both portions were attached using a heat polymerized resin.

► **Case report**

A 65-year-old male patient reported to the Department of Prosthetic Dentistry of PMS College of Dental sciences, Kerala for prosthetic rehabilitation of maxillary and mandibular edentulous ridges (FIG 1). Patient medical history was not significant. Past dental history revealed that patient was a denture wearer for 5 years, and the maxillary denture was loose.

Intraoral examination revealed severely resorbed maxillary and mandibular edentulous ridges with increased interridge distance. Hence, hollow maxillary complete denture and conventional mandibular denture was planned for this patient.

► **Technique**

- 1) Maxillary and mandibular primary impressions were recorded with impression compound. (fig 2)
- 2) Secondary impression of maxillary and mandibular ridge recorded with greenstick and ZOE paste. (fig 3)
- 3) Jaw relation recorded with combination of niswonger and phonetic method and articulated.(fig 4 & fig 5)
- 4) After teeth setting an index of the maxillary denture were made with biostar machine.
- 5) Maxillary and mandibular cast were de articulated and investing and de waxing done (fig 9)
- 6) After de waxing on the maxillary cast wax adapted and it is again invested with the top of another flask (double flask method) (fig 10 & 11)

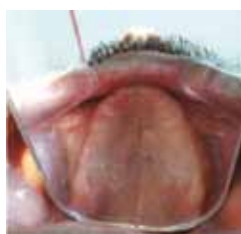

Fig 1 Intra oral view

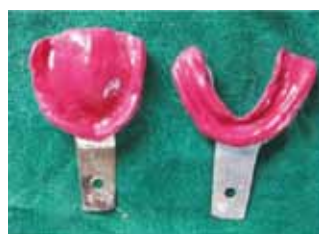
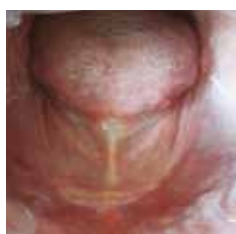
Fig 2 Primary impression

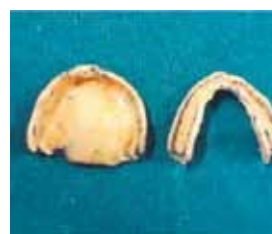

Fig 3 Secondary impression



Fig 4 Jaw relation



Fig 5 Jaw relation



Fig 6 Teeth setting

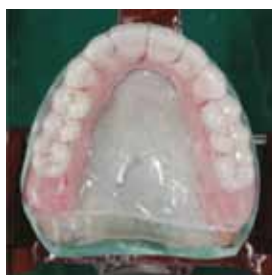

Fig 7: index made on maxillary setting

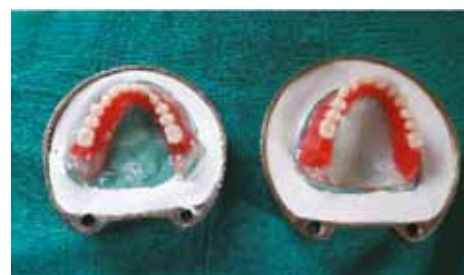

Fig 8 Investing done

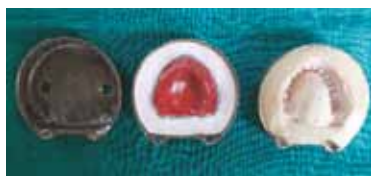

Fig 9 Dewaxing maxillary cast

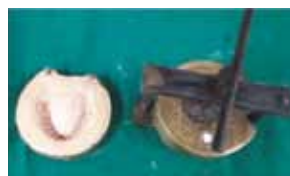

Fig 10: Permanent denture base fabrication

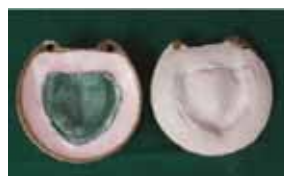

Fig 11 Dewaxing



Fig 12 Permanent denture base



- 7) After de waxing the newly invested flask (fig 12) it is packed with heat cure acrylic resin and curing done and hence a new maxillary permanent denture base is formed. (fig 13)
- 8) The index made were placed over the denture base to determine the areas which can be made into hollow spaces. (fig 14 & 15)
- 9) Putty material molded around an arch wire corresponding to the hollow regions of the denture. Arch wire is allowed to extend beyond the denture base. (fig 16)
- 10) Index is again placed back to re-check the hollow regions (fig 17)
- 11) The dewaxed part of flask with teeth along with permanent denture base part of flask is packed with heat cure resin and cured (fig 18 & 19)
- 12) A small opening was made using straight fissure bur give a space for putty to come out while pulling the wire. (fig 20)
- 13) After removing the putty hollow space is exposed. (fig 21)
- 14) Opening is again closed with self-cure acrylic resin (fig 22)
- 15) Denture floating in water (fig 23)
- 16) Denture is finished and polished and inserted into patients mouth (fig 24)

► **Discussion**

The method described has advantages over previously described techniques for hollow denture fabrication. Heat-polymerizing 1 portion of the denture against polymerized resin may reduce leakage at the junction of the 2 portions of



Fig 13& 14 Index placed to determine hollow regions

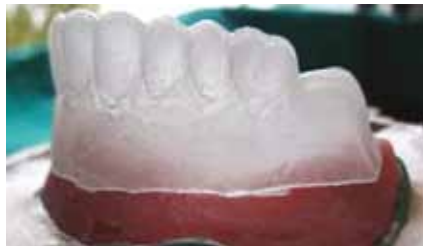

Fig 15 Putty material molded around arch wire in hollow spaces

Fig 16 Re check hollow regions by placing index

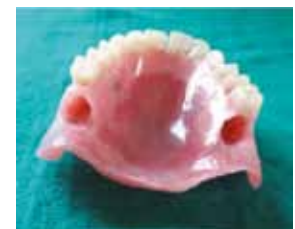
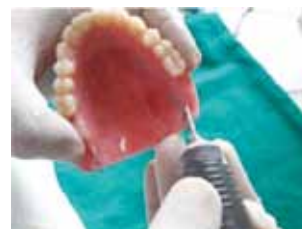
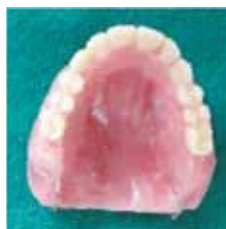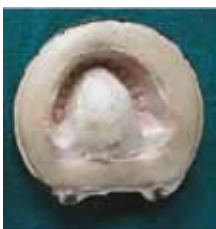Fig 17 & 18 Packing & acrylization

Fig 19 Small opening made for removing putty

Fig 20 Hollow denture

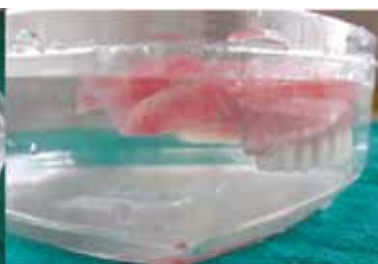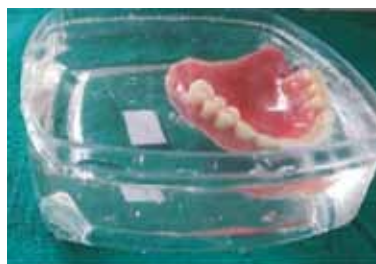

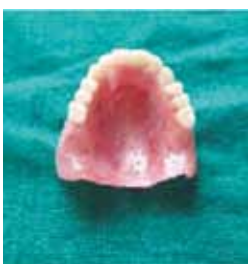
Fig 21 Opening closed with self cure acrylic resin

Fig 22: Denture floating in water

Fig 23 Post insertion

the denture. The thickness of resin can be controlled using the putty and clear matrix, ensuring an even depth of resin to prevent seepage and prevent deformation under pressure of flask closure. Silicone putty is used as a spacer because of previously described advantages, including its stability, its ability to be carved, and the fact that it does not adhere to acrylic resin. The cyanoacrylate bond between the resin and the putty may be easily removed. However, traces of putty will remain if a probe is used to remove the silicone putty. In this technique the difficulty in removing putty spacer is overcome using an arch wire which helps to pull the putty easily out of the denture.

► **Conclusion**

Hollow maxillary complete denture considerably reduces the weight of the prosthesis, which in turn prevents transmission of the detrimental forces, which would otherwise be transmitted from a conventional heavy prosthesis to the underlying tissue and bone. Thus, it helps to preserve underlying tissue and bone along with increasing retention of the denture.

► **References**

- 1) Chalian VA, Drane JB, Standish SM. Intraoral prosthetics. In: Chalian VA, Drane JB, Standish SM, editors. Maxillofacial Prosthetics: multidisciplinary Practice. Baltimore: Williams and Wilkins; 1971. p. 133-57.
- 2) Fattore LD, Fine L, Edmonds DC. The hollow denture: An alternative treatment for atrophic maxillae. J Prosthet Dent 1988;59:514-6.
- 3) Holt RA Jr. A hollow complete lower denture. J Prosthet Dent 1981;45:452-4
- 4) O’Sullivan M, Hansen N, Cronin RJ, Cagna DR. The hollow maxillary complete denture: A modified technique. J Prosthet Dent 2004;91:591-4
- 5) Ohkubo C, Hosoi T. Effect of weight change of mandibular completedentures on chewing and stability: a pilot study. J Prosthet Dent 1999;82: 636-42.
- 6) Jacobson TE, Krol AJ. A contemporary review of the factors involved incomplete denture retention, stability, and support. Part I: retention. J Prosthet Dent 1983;49:5-15.
- 7) Wormley JH, Brunton DA. Weighted mandibular dentures. J Prosthet Dent1974;32:101-2.

**A revolutionary new diagnostic liquid could serve as an alternative to drilling.**

The days of the dreaded dental drill-and-fill as the standard solution for tooth decay may be numbered if a discovery by a Creighton University School of Dentistry professor continues to advance. Douglas Benn, D.D.S., Ph.D., has created a simple diagnostic liquid solution that can be applied to the surface of a patient’s teeth prior to a dental X-ray and which will help show dentists whether a tooth has cavitated decay or is pre-cavity. The diagnostic liquid will help dentists to more readily see cavitated decay on a standard X-ray and will also allow the dentist to use recently developed topical products to arrest tooth decay at an early stage, thereby preserving healthy tooth structure and utilizing a simple, pain-free method of detection and treatment, without anesthesia or drilling.

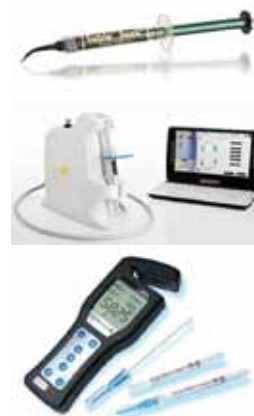**Caries Detection Systems**



Finding caries early leads to the best possible outcome for your patients, but in some cases you might not be able to identify smaller lesions on an x-ray or by using an explorer. There are now a variety of products available designed to help dentists detect caries at the earliest stage possible, leading to less invasive treatment and happier patients.

**What Types of Caries Detection Systems Are Available**

There are a range of new approaches dentists can invest in for early caries detection. They include dyes designed to visibly mark possibly carious lesions, software applications that automate the review of intraoral x-rays, specialized technology and equipment designed to use transillumination, laser-scanning, or fluorescence to spot carious lesions, as well as caries susceptibility tests that can help identify which patients are most at risk for future caries.



# Understanding angular cheilitis: a review of its etiopathogenesis and therapeutic approach

\* Shalini Nair, \*\* Hari S., \*\*\*Anoop Kumar, \*\*\*\* Ipe Varghese, \*\*\*\*\* Shifana

## Abstract

Angular cheilitis (perleche/angular stomatitis) is a non-specific term used to refer to the presence of inflammation, maceration and fissuring of the oral commissures. It is most often chronic, seen in the older individuals, and due to infective causes in concurrence with other factors. The purpose of this review is to reexamine the relative importance of various factors in the pathogenesis of angular cheilitis and to give an insight on the therapeutic aspects of the disease.

KDJ 2017 | Vol. 40 | No. 4 | Pg 239-241

## ► Introduction

Angular cheilitis is a relatively common condition, accounting for between 0.7-3% of oral mucosal lesions in adults and between 0.2-15% in children, though overall it occurs most commonly in adults in the third to sixth decades of life<sup>1</sup>. Both oral commissures are typically affected. Early lesions are small, grey-white thickened areas bordered by mild mucosal erythema. More established lesions exhibit a blue-white hue and are associated with scaling, erythematous patches on surrounding skin. Maceration, fissuring and crusting of the oral commissures are common late findings.<sup>2</sup>

Angular cheilitis often represents an opportunistic infection of fungi and/or bacteria, with multiple local and systemic predisposing factors involved in the initiation and persistence of the lesion.<sup>2</sup> Such factors include nutritional deficiencies, over closure of the mouth, dry mouth, a lip-licking habit, drooling, and immunosuppression<sup>3,4,5</sup>. Treatment for angular cheilitis is based on the exact causes of the condition in each case, but often an antifungal cream is used among other measures.

## ► Pathophysiology

The etiology of angular cheilitis is multifactorial and may involve interplay of physical conditions promoting a moist environment at the oral commissures and infectious agents. A higher incidence of *Candida albicans* in affected individuals versus unaffected control patients and observed improvement of the condition with anti-candidal treatment is indicative of involvement of *Candida* in the etiology of angular cheilitis. Other pathogens implicated in angular cheilitis include methicillin-sensitive *Staphylococcus aureus*, *Streptococcus* spp. and gram negative bacteria<sup>6</sup>.

## ► Etiology

The various etiological factors have been identified:

1. Mechanical/chemical trauma:

Local mechanical or chemical irritation during dental appointments, allergic dermatitis classically to toothpaste or metals used in dental or orthodontic appliances.

2. Decrease in vertical dimension: This seems to be the most common etiologic factor. Over-closure of the jaws will produce occlusive folds at the angles of the mouth in which saliva tends to collect and the skin subsequently becomes macerated, fissured and secondarily infected and colonized. The most common cause is ill fitting dentures, wearing away of the occlusal surface of dentures due to prolonged use. Also age related loss of vertical dimension leads to folds in the angles of mouth.

3. Anemia with or without iron deficiency: Angular cheilitis will be of long standing duration with intervals of remission and relapse.

4. Vitamin B complex deficiency: Angular cheilitis represents a riboflavin deficiency with a super imposed fungal or bacterial infection. Many of these cases get cured by the administration of the vitamin B complex<sup>7</sup>

5. Diabetes mellitus

6. Miscellaneous: Risk factors for development of this condition

\*Reader, \*\*Prof. & HOD, \*\*\* Reader, \*\*\*\* Professor, \*\*\*\*\* Intern, Dept. of Oral Pathology, PSM College of Dental Science and Research, Akkikavu, Thrissur. • Corresponding Author: Dr. Shalini Nair, E-mail: shalini\_haridas@yahoo.com

include lip licking, drooling, xerostomia (such as occurs in Sjögren's syndrome and terminal malignancy), malocclusion, Down syndrome, orthodontic treatment, denture use, hypervitaminosis A, atopic dermatitis, HIV, primary immunodeficiency syndromes, conditions requiring pharmaceutical immunosuppression, and diabetes mellitus. Angular cheilitis occurs in children frequently because of lack of nutrition. Bacterial infection and mechanical factor often occur in children with bad habits such as licking the corner of the lip and sucking finger. These will accumulate the saliva on the corner of the mouth and unwittingly provide perfect environment for infectious agents in causing angular cheilitis.

### ► Clinical manifestation

Angular cheilitis lesions generally begin at the mucocutaneous junctions of the lips and extend outward on the skin. The lesions are more commonly symmetrically present

on both sides of the mouth but sometimes only one side may be affected. Around rhagade at the corner of the mouth involving adjacent skin is usually the most frequent presentation among dentate patients, whereas among denture wearers a deep lesion following the labial marginal sulcus was frequently observed. Signs of angular cheilitis include erythema (redness), cracking, fissures, scaling, crusting, bleeding, and ulceration at the labial commissures. Generally lesions are accompanied by symptoms that include pain (ranging from asymptomatic to severe discomfort), burning, irritation, pruritus, and dry lips (Figure 2). Angular cheilitis is frequently associated with oral candidiasis, which may present as white patches and erythema on the tongue and/or oral mucosa. In the case of angular cheilitis associated with pernicious anemia (itself due to a form of vitamin B12 deficiency), oral manifestations include mucosal pallor; atrophic, painful mucosa, and reddened mucosa; mucosal ulceration; loss of papillae on the dorsum of the tongue; and burning and painful tongue.

### ► Investigations

In most cases the clinical examination along with the case history should be adequate to make the proper diagnosis. A detailed history should be taken, including the patient's dental status, oral hygiene practices and occupation.<sup>8</sup>

It is important to question patients about medical illness, such as anemia, immunodeficiency, smoking, the use of chewing tobacco; alcohol consumption; cutaneous disorders (atopic dermatitis, psoriasis, lichen planus), allergic disorders (asthma, eczema); and the use of any medications. It is generally believed that those who wear oral prosthesis (dentures and appliances) are more likely to have candida species colonized in their oral flora. On the other hand, those who frequently wear facial masks are more prone to *S.aureus* colonization.

Although most cases are easily identified, some lesions might mimic other common conditions. The differential diagnosis of angular cheilitis includes herpes labialis and erosive lichen planus, physical trauma, chemical injury, and allergic contact dermatitis (classically to toothpaste or metals used in

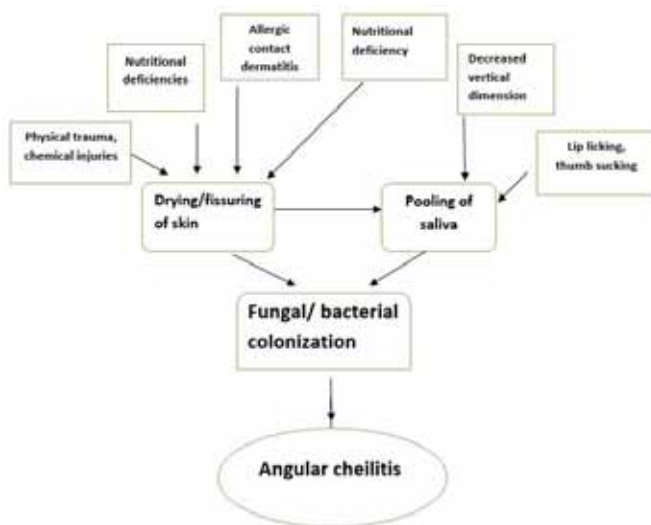


Fig. 1: Etiopathogenesis of angular cheilitis

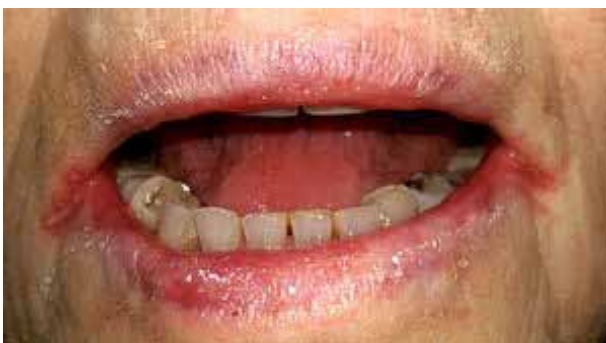
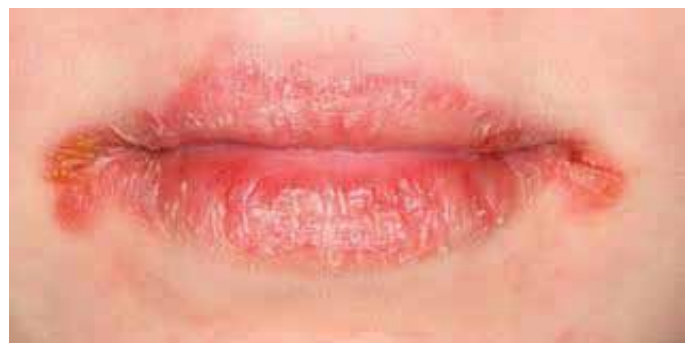
Fig. 2: Clinical picture showing redness, fissuring and crusting of the commissures of lips.



dental or orthodontic appliances). Individuals with nutritional deficiencies, impaired immunity, including those with HIV, primary immunodeficiency or diabetes mellitus (DM), are at increased risk for angular cheilitis. Laboratory screening to rule out undiagnosed underlying systemic disorders and patch testing to rule out allergic contact dermatitis should be considered on an individual patient basis. Microbiologic investigation by swabbing both angles of the mouth and the anterior nares can be helpful.<sup>9</sup>

### ► Management

The therapeutic approach towards angular cheilitis includes remediation of predisposing factors in conjunction with elimination of primary or secondary infection plus inflammation. In severe cases swabs and smears from the lesion are recommended for bacteriological culture and antibiotic sensitivity test.

In case of staphylococcal infection a topical preparation like fucidic acid may be used thrice daily. Antifungal agents like Nystatin or Amphotericin B ointments applied topically can be used for control of the fungal infection. For patients with oropharyngeal candidiasis, systemic therapy might need to be prescribed.

Since angular cheilitis is a polymicrobial infection involving staphylococci and candida, a combination of antibiotics and antifungal drugs may be used. 2% miconazole cream is indicated as this is effective both against candida and gram positive cocci.

For idiopathic causes of angular cheilitis, treatment can be as simple as applying petroleum jelly to the affected areas.

In angular cheilitis related to denture-wearing, dental treatment requires adjustment of the denture to eliminate trauma and prescribing of antifungal drugs to treat Candida infection.

Recurrence of the condition has been observed in many cases. Patients with cutaneous disorders associated with dry skin or intraoral leukoplakia had an increased incidence

of recrudescence. For patients not responding to simple therapeutic measures, the next appropriate step is to arrange full hematological screening with assessment of Hb, MCV, vitamin B2, vitamin B6, vitamin B12, serum iron, ferritin, transferrin and FBS.<sup>7</sup>

### ► Conclusion

Angular cheilitis is a common inflammatory condition affecting the oral commissures. It manifests as lesions with deep fissures, affecting the angles of mouth with an ulcerated appearance and is associated with a variety of nutritional, systemic, and drug-related factors that may act exclusively or in combination with local factors. A two-step approach for management includes elimination of the underlying factors and treatment of the infectious component.

### ► References

1. Park, KK; Brodell, RT, Helms, SE (June 2011). "Angular cheilitis, part 1: local etiologies." *Cutis; cutaneous medicine for the practitioner* 87 (6): 289-95. PMID 21838086.
2. Scully, Crispian (2008). *Oral and maxillofacial medicine: the basis of diagnosis and treatment* (2nd ed.). Edinburgh: Churchill Livingstone. pp. 147-149. ISBN 9780443068188.
3. Park, KK; Brodell RT; Helms SE. "Angular cheilitis, part 2: nutritional, systemic, and drug-related causes and treatment." *Cutis*. 2011 Jul; 88(1): 27-32. 88 (1): 27-32. ISBN 21877503.
4. Tyldesley WR, Field A, Longman L (2003). *Tyldesley's Oral medicine* (5th ed.). Oxford: Oxford University Press. pp. 37, 40, 46, 63-67. ISBN 0192631470.
5. Neville BW, Damm DD, Allen CA, Bouquot JE. *Oral & maxillofacial pathology* (2nd Ed.). Philadelphia: W.B. Saunders. pp. 100, 192, 196, 266. ISBN 0721690033, 2002
6. David L. Cross and Laura J. Short, Glasgow University, Glasgow, UK, Angular cheilitis occurring during orthodontic treatment. *Acase series, Journal of Orthodontics*, 2008; 35: 29-23.
7. Warnakulasuriya KA, samaranayake LP, Peiris JS, angular cheilitis in a group of Sri lankan adults, a clinical and microbiologic study. *J Oral Pathol Med* 1991;20(4):172-5
8. Lamey PJ, Lewis MA. Oral medicine in practice: angular cheilitis. *Br Dent J* 1989;167(1):15-8
9. Ohman SC, Dahlen G, Moler A, Ohman A, Angular Cheilitis, a clinical and microbial study. *J Oral Patho* 1986;15(4):213-7
10. Eric T. Stoopler, DMD, FDS RCSEd; Christine Nadeau, DMD; Thomas P. Sollecito, DMD, FDS RCSEd, Angular Cheilitis, *J Can Dent Assoc* 2013; 79: d68.
11. Sharon V, Fazel N. Oral candidiasis and angular cheilitis. *Dermatol Ther*. 2010;23(3):230-42.

# Presurgical nasoalveolar molding

\* Anna Oommen

## Abstract

The naso alveolar molding appliance (NAM) consists of an intraoral molding plate with nasal stents to mold the alveolar ridge and nasal cartilage concurrently. The objective of the pre-surgical naso alveolar molding (PNAM) is to reduce the severity of the original cleft deformity and thereby enable the surgeon to achieve better repair of the alveolus, lip and nose. The nasoalveolar molding technique has been shown to significantly improve the surgical outcome of the primary repair in cleft lip and palate patients.

KDJ 2017 | Vol. 40 | No. 4 | Pg 242-244

## ► Introduction

Cleft lip and palate the commonest orofacial congenital deformity can present with considerable variation in severity and form. Generally, the wider more extensive clefts are associated with more significant nasolabial deformity and present a significant surgical challenge.<sup>1</sup> Most surgeons would agree that their chance of achieving a finer surgical scar, and more symmetrical and precisely defined nasolabial complex would be better in an infant who presents with a minor cleft deformity. Pre-surgical infant orthopaedics has been used for centuries to manage cleft lip and palate but many studies have shown no significant advantage in the long-term outcome of cleft treatment. Dr Barry Grayson and Dr Court Cutting combined the

molding technics used in orthodontic work and modified the surgical technics to develop NAM<sup>2</sup>. NAM is a non-surgical method of reshaping the alveolus, lips and nostrils before cleft lip and palate surgery, thus lessening the severity of the cleft<sup>3</sup>. NAM takes advantage of the flexibility of the cartilaginous septum in the first few weeks after birth (caused by high levels of hyaluronic acid found circulating in infants)<sup>4</sup>. During this period it is relatively easy to apply external traction and by means of controlled forces rotate the lower part of the premaxilla to a more surgically advantageous position. The first phase of NAM -alveolar molding is done at 1-2 weeks. The nasal molding is done after approximation of the alveolar segments around 12-16 weeks. Tapes that actively bring the lip segments together are used in conjunction with the molding plate and nasal stent. Taping the lips together helps to make the inclined columella upright along the midsagittal plane. The alar rim, which was initially stretched over a wide alveolar cleft deformity, shows some laxity, which enables it to be elevated into a symmetrical and convex form. Grayson has listed four benefits of P NAM:

1. P NAM enables surgeon to perform a gingivo-periosteoplasty;
2. Pre-surgical alignment and correction of deformity in nasal cartilage minimize the extent of primary nasal surgery required;

3. In bilateral cleft deformity, nonsurgical columella elongation
4. P NAM used in conjugation with a modified surgical approach, allows for a single initial surgical procedure to address lip-nose alveolar complex and its deformity.

## Description of molding plate and nasal stent

A conventional molding plate is fabricated on a maxillary cast with clear acrylic resin, with retention arms projecting at the location of the cleft at the junction of upper and lower lips at rest. (Fig 1) The appliance is secured extra-orally to the cheeks and bilaterally by surgical tapes, which have an orthodontic elastic band at one end. The elastics loop over a retention arm extending from the anterior flange of the plate achieve proper activation and to prevent unseating of the appliance from the palate. (Fig 2) When the retention arms are engaged by the tape-elastic system, the elastics (inner diameter 0.25 inch, wall thickness heavy) should be stretched approximately two times the resting diameter for proper activation force (2 oz)<sup>4</sup>. Retraction of the premaxilla requires greater elastic traction force than is required for closure of a unilateral alveolar gap.

At the third visit, the parents are instructed to place tapes to approximate the cleft lip segments. The tape should be applied at the base of the nose (nasolabial angle).

\* Senior Lecturer, Department of Orthodontics and Dentofacial Orthopaedics, Sree Mookambika Institute of Dental Sciences, Kulasekaram, Tamilnadu • Corresponding Author: Dr. Anna Oommen, E-mail: dranuoo@gmail.com

**Appliance adjustments**

The baby is seen weekly to adjust the molding plate to bring the alveolar segments together by selectively removing the hard acrylic and adding the soft denture base material to the molding plate. No more than 1 mm of modification of the moulding plate should be made at one visit. The alveolar segments should be directed to its final and optimal position.

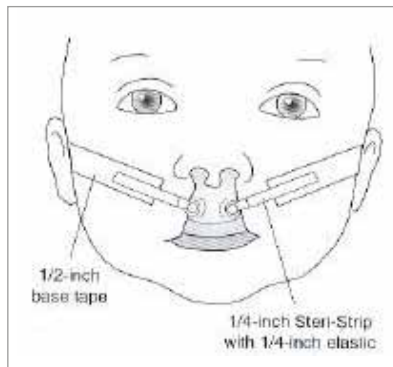
When the cleft alveolus is reduced to 5 mm or less, the nasal stent is added. The stent is made of 0.036-gauge round stainless steel wire attached to the labial flange of the molding plate, near the base of the retention arm (Fig 3,4) It extends forward and then curves backward (in the form of a swan neck), entering 3 to 4 mm past the nostril aperture. As the wire extends into the nostril, it is curved back on itself to create a small loop for retention of the intranasal portion of the nasal stent. This hard acrylic component is shaped into a bilobed form that resembles a kidney. A layer of soft denture liner is added to the hard acrylic for comfort. The upper lobe enters the nose and gently lifts the dome until a moderate amount of tissue blanching is evident. The lower lobe of the nasal stent lifts the nostril apex and defines the top of the

columella. By weekly manual modifications to the nasal stent, the shape of the alar cartilage and medial and lateral crus are successfully moulded<sup>5</sup>. In the patient with bilateral clefts, there is a need for two retention arms and nasal stents. After the nasal stents are added, attention is focused on nonsurgical lengthening of the columella by adding a horizontal band of soft denture material is added to join the left and right lower lobes of the nasal stents, spanning the base of the columella. Tape is adhered to the prolabium underneath the horizontal lip tape and stretches downward to engage the retention arms with elastics. Taping downward on the prolabium helps to lengthen the columella and vertically lengthens the often small prolabium. The horizontal lip tape is added after the vertical prolabial tape is in place (Fig. 5)

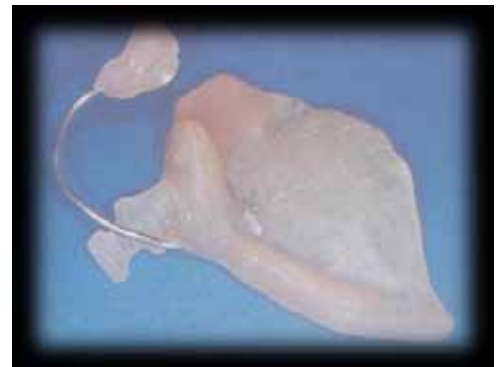The objectives of NAM therapy is accomplished before the primary surgical repair around 3–4 months of age. Bilateral cleft patients tend to take one to two additional months to achieve pre-surgical clinical objectives. Because the alveolar segments are in approximation, a gingivoperiosteoplasty (GPP) is simple for the surgeon to perform, avoiding extensive dissection. and not affecting growth of the midface.



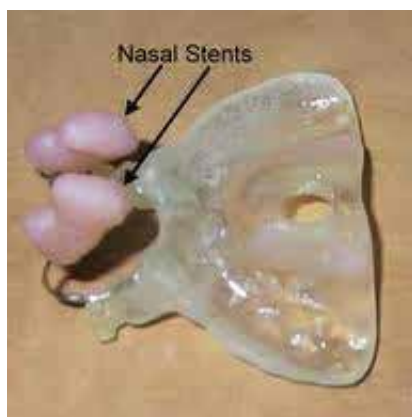
**Fig. 1:** Feeding plate with retention arms



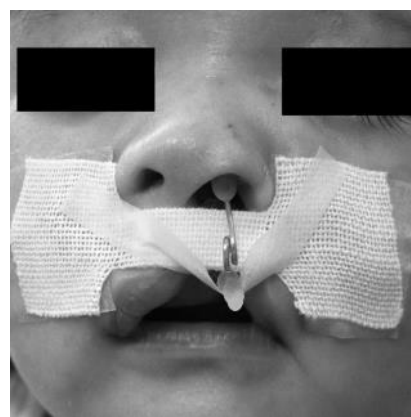
**Fig. 2:** Surgical taping with elastic



**Fig. 3:** Nasal attached to feeding plate



**Fig. 4:** Nasal stent for bilateral clefts



**Fig. 5:** Taping to lengthen the columella

### Benefits of NAM

In the short term, the tissues are well aligned before primary lip and nose repair, which enables the surgeon to achieve a better and more predictable outcome with less scar tissue formation.

In the long term, studies indicate that the change in nasal shape is stable with less scar tissue and better lip and nasal form.

With the alveolar segments in a better position and increased bone bridges across the cleft, the adult teeth have a better chance of erupting in a good position with adequate periodontal support.

Studies have also demonstrated that 60% of patients who underwent NAM and gingivoperiosteoplasty did not require secondary bone grafting<sup>6</sup>.

Fewer surgeries also result in substantial cost savings for families and insurance companies<sup>7</sup>.

### Complications associated with NAM.

The most common is irritation of the oral mucosal or gingival tissue. The infant should be checked at each visit, and the molding plate should be properly relieved in all areas that are exerting excessive pressure.

The intranasal lining of the nasal tip can become inflamed if too much force is applied by the upper lobe of the nasal stent. Notching along the alar rim can occur if the lower lobe is not positioned or shaped correctly.

A skin barrier such as DuoDerm or Tegaderm can be used as a base on which the tape-elastic retraction system can be attached to prevent skin irritation on cheeks.

There is a risk that the molding plate will become dislodged and obstruct the airway. The hole, centrally located on the palatal portion of the molding plate, will in most instances allow adequate airflow

### ► Conclusion

Naso-alveolar molding has evolved over the past decade into its present form through contributions made by practising clinicians and parents. Since the initiation of

NAM and the associated changes in the surgical technique there has been significant improvement in the outcome of primary surgical cleft repair. Following PNAM, the primary surgical repair of the nose and lip heals under minimal tension, thereby reducing scar formation and improving the esthetic result.

### ► References

1. Deirdre J. Maull et al, Long term effects on naso alveolar molding on 3- dimensional shape in unilateral clefts.. Cleft Palate Craniofac J, Sept 1999;36(5);391-7
2. Grayson. B.H, Maull.D. Nasoalveolar Molding for Infants Born with Clefts of the Lip, Alveolus, and Palate. Seminars in plastic surgery, 2005;19(4):294-301.
3. Habel A, Sell D. Management of cleft lip and palate, Archives of diseases in childhood 1996;74:360-4.
4. Matsuo K. Repair of cleft lip with nonsurgical correction of nasal deformity in the early neonatal period. Plast Reconst Surg 1989;83:25-31.
5. Grayson. B.H, Shetye.P.R. Presurgical nasoalveolar moulding treatment in cleft lip and palate patients. Indian J Plast Surg 2009;42(3):56-61.
6. Iino Mitsuyoshi, Wako Masahiko, Fukuda Masayuki Simple modified preoperative nasoalveolar moulding in infants with unilateral cleft lip and palate. British Journal of Oral and Maxillofacial Surgery (2004) 42, 578–580
7. Tracy M. Pfeifer, Barry H. Grayson, Court B. Cutting. Nasoalveolar molding and gingivoperiosteoplasty versus alveolar bone graft: An outcome analysis of costs in the treatment of unilateral cleft alveolus. Cleft Palate Craniofac J, January 2002;39(1):26-9.

## OBITUARY



**Dr. Anitha Susil**

With profound grief IDA, Kerala State inform the sad demise of Dr. Anitha Susil (Senior Lecturer in Sri Sankara Dental College, Akathumuri). She took BDS from Dr. R Ahmed Dental College, Kolkotta. She was a member in IDA Attingal branch. We all pray for the departed soul.



# Cheek plumper prosthesis using button attachment

\*Layana Theodore, \*Abha Nair, \*\* Sudeep S., \*\*\* Dinesh N., \*\*\* Sapna Bhaskar

## Abstract

Increasing demand of esthetics makes dentistry more than just the rehabilitation of lost parts. Esthetics and function goes hand in hand now a days. This article describes a simple non invasive procedure for complete denture patient to reduce on their age by using a cheek plumper. The delicate plumper prosthesis using push buttons attachment improves support for sunken cheeks.

**Keywords:** push button attachment, cheek plumper, hollow cheeks, detachable attachment, complete denture

KDJ 2017 | Vol. 40 | No. 4 | Pg 245-247

## ► Introduction

Esthetics is one of the important factor in treatment planning and has an inevitable role in ones social and professional life. And thus cheeks plays an important role in esthetics and materializing facial expressions because of its extreme visibility.<sup>1</sup> The cheeks gains its main support from the tooth,gingiva,alveolar bone and the musculature. Factors like extraction of molars, thinning of tissues due to aging, or weight loss may lead to concavities or hollowing of the cheeks.<sup>2</sup> Thereby gives a more elderly look that can psychologically have a negative impact.

Prosthodontists play an important role in restoring the lost tooth and facial esthetics.<sup>3</sup> The contours of the face should be restored along with tooth and this can be achieved by proper extensions and contour of dental flange. Extra support should be provided for patients with hollow cheeks. Cheek plumpers or cheek lifting appliance can be used where extra support is needed as in case of hollow cheeks. There are several documents on the use of plumper prosthesis in maxillofacial prosthodontics as well.<sup>4-6</sup> The patients find difficulty in using the conventional cheek plumper because of its increased weight which causes discomfort and decreased retention.

This article describes case report of a patient with hollow cheeks where in cheek plumpers are attached to conventional complete denture using easily available button attachment which are detachable and can be used for patients with hollow cheeks.

## ► Case report

A 65 years old male patient had reported to the department of prosthodontics requesting replacement of missing teeth. On examination, completely edentulous upper and lower arches were found. Patient was edentulous since past 3 years and had lost his teeth due to periodontal problems.

Hollow cheeks were one of the major extraoral findings and patient desired for fuller and healthier cheeks. While formulating treatment plan complete denture with detachable cheek plumpers were decided keeping in mind about patients desires.

Maxillary and mandibular preliminary impression were made using impression compound (aslte impression compound) and was poured using dental plaster (type II)(fig. 1 and 2). Primary cast was retrieved and custom trays were made using autopolymerising acrylic resin. Border molding was done using low fusing impression compound (Aslate, Asian Acrylates, Mumbai) and wash impressions were made with light body addition silicone impression material. Jaw relations were recorded and cheek plumpers were made in modeling wax (Hindusthan) after marking the antero-posterior position and attached to the maxillary denture. Functional moulding was done using regular outward downward and inward as well as anterior and posterior motion of the cheeks till the wax plumpers were hardened. Patient was checked for retention, stability, support, phonetics and esthetics,advised to use it for 2-3 hours and then evaluated to give patient a more fuller appearance (fig 3). For the try in appointment waxed denture with cheek plumper attached to maxillary

\* PG Student, \*\* Professor and HOD, \*\*\*Professor, Dept. of Prosthodontics, Pms College of Dental Science and Research, Vattappara, Trivandrum • Corresponding Author: Dr. Layana Theodore, E-mail: t.layana@gmail.com

denture were tried for occlusion and esthetics as well as functional movements were reevaluated. The waxed plumper was separated from the waxed denture. The maxillary denture and the cheek plumpers were fabricated with heat-polymerised acrylic resin. After finishing and polishing, cheek plumpers were positioned on to the maxillary denture on the patient using stick wax and its anterior as well as posterior position was marked on the denture. Push buttons were placed in the center of the plumper as well as in between the marked areas on the denture and it was sealed using autopolymerising resin (fig 4 and 5). Patient was instructed on use of the plumpers and dentures were delivered after evaluating them for fit and esthetics (fig 6). On the recall after 48h and then 7 days patient did not possess any problems with speech or mastication. Patient was satisfied with the prosthesis.

► **Discussion**

The term ‘esthetics’ coined in 1750 is a blend of knowledge to give beauty, in contrast to the science of logic for the truth<sup>7</sup>. According to GPT, denture esthetics is defined as the effect produced by a dental prosthesis that affects the beauty and attractiveness of the person.<sup>8</sup> Due to the aging process which is inevitable a drastic change including tissue atrophy, exaggeration of folds and creases of face occurs in the facial esthetics. This happens in particular because of loss of support by the alveolar bone and teeth leading to collapse of the lower third of the face and shifting of malar fat pad and reduction of fat which makes cheeks appear hollow.<sup>9</sup> This results in deepening of the nasolabial fold, drooping of the corner of the mouth, loss of the vermilion border and depression of

the lips with exaggerated wrinkling as well.<sup>10</sup> Adjustment of the occlusal rim should be precise for anterior and posterior placement of the teeth and esthetics should be evaluated at rest and function. To restore physiological muscle length and to eliminate pseudoprognathic appearance, proper and correct vertical dimension is necessary.<sup>11</sup>

The patient was informed about the procedure and the materials used, and verbal consent was procured. The patient also accepted the need for frequent review calls after insertion of the prostheses. Undetachable cheek plumper have limitations like: Excessive weight which could hamper retention of the maxillary complete denture., Can result in muscles fatigue, Can destabilize the maxillary denture, Could interfere with Masseter and Buccinator muscle function and coronoid process of the mandible, Difficult to insert the denture due to excessive weight and Can’t be used in patients with limited mouth opening.<sup>12</sup>

In this case a detachable plumper prosthesis were planned to overcome these difficulties in final prosthesis and to allow ease in placement of the prosthesis. Detachable plumpers enabled the patient to remove the plumpers and use the denture if required. In the past, magnet retained plumper prosthesis have been used but they exhibit poor corrosion resistance and loss of magnetic property over a period of time.<sup>13</sup> To form a detachable unit, attachments were used as they provide an easy, cost effective and reliable means. Push buttons are easily available and are more cost effective and can be used for various purposes.



Fig 1&2 Primary and secondary impression

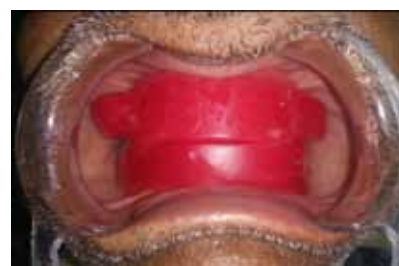
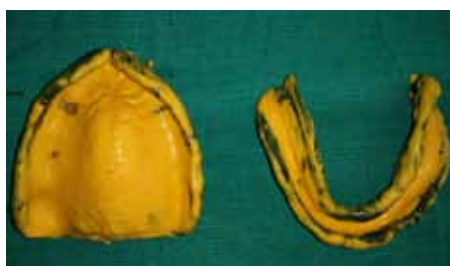
Fig 3 Tentative jaw relation with cheek plumpers

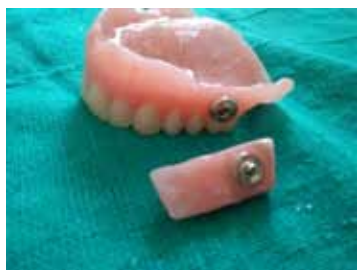

Fig 4 Final prosthesis with cheek plumper

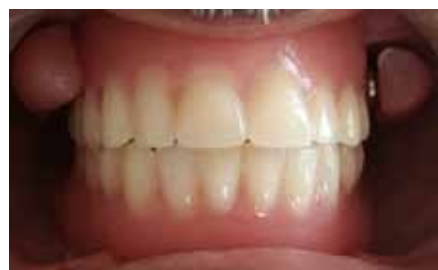

Fig 5 Final prosthesis intraoral view

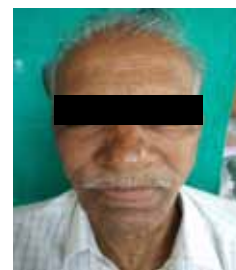
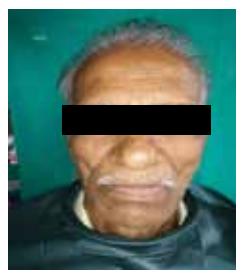
Fig 6 Pre-operative and post-operative picture

Many of the authors have suggested sealing of the attachment while fabrication of the denture itself but then the positioning of the plumper may not be in precise location. Repositioning the plumper after acrylisation and then sealing it with autopolymerising resin after marking its position would help to produce an accurate prosthesis.

### ► Conclusion

A simple and non-invasive treatment modality to enhance the facial esthetics of a patient with hollow cheeks has been described in this article. An effort was made to improve patient's appearance by providing better support to the cheeks. The push button attachments retained the cheek plumper prosthesis successfully and restored the contour of cheek improving esthetics as well as psychological wellbeing of the patient.

### ► References

1. Suryakant Chhagan Deogade. Magnet Retained Cheek Plumper in Complete Denture Esthetics: A Case Report. *Journal of Dentistry, Iran* January 2014; Vol. 11, No. 1
2. Bains JW, Elia JP (1994) The role of facial skeletal augmentation and dental restoration in facial rejuvenation. *Aesthet Plast Surg* 18(3):243-246.
3. Martone AL. Effects of complete dentures on facial esthetics. *J Prosthet Dent.* 1964 Apr;14:231-55.
4. Lazzari JB (1955) Intraoral splint for support of lips in Bells palsy. *J Prosthet Dent* 5(4):579- 581
5. Larzen SJ, Cartern JF, Abrahamian HA (1976) Prosthetic support for unilateral facial paralysis. *J Prosthet Dent* 35(2):192-201
6. Hitoshi M, Chiaki K, Takashi O, Hisashi T (2004) Lip plumper prosthesis for a patient with a marginal mandibulectomy: a clinical report. *J Prosthet Dent* 92(1):23-26
7. Young HA. Denture esthetics. *J Prosthet Dent.* 1956;6(6):748-55
8. Glossary of prosthodontic terms. *J Prosthet Dent.* 2005 Jul;94(1):10-92
9. M. Kaur et al (2015) Analysis of facial soft tissue changes with aging and their effects on facial morphology: A forensic perspective. *Egyptian Journal of Forensic Sciences* (2015) 5, 46-56
10. Tautin FS. Denture esthetics is more than teeth selection.. *J Prosthet Dent.* 1978 Aug;40(2):127-30.
11. Lombardi RE. The principle of visual perception and their clinical application to denture esthetics. *J Prosthet Dent.* 1973 Apr;29(4):358-82.
12. Dr. Baisakhi et al Magnet Retained Cheek Plumpers to Enhance Denture Esthetics - A Case Report. *IOSR Journal of Dental and Medical Sciences* (14) 7 Ver. I (July. 2015), PP 23-27
13. Nandita N. Keni • Meena A. Aras • Vidya Chitre. Customised Attachments Retained Cheek Plumper Prosthesis: A Case Report. *J Indian Prosthodont Soc* (July-Sept 2012) 12(3):198-200.

## Gum disease linked to highly deadly cancer

The discovery could help practitioners diagnose the often-fatal disease much earlier.

In recent months, gum disease has been linked to increasing number of major health problems – and researchers have now discovered another illness to add to the list. Researchers from the University of Louisville School of Dentistry examined the relationship between *Porphyromonas gingivalis*, a bacterial species that causes gum disease, and esophageal cancer. In a study of 130 patients, (100 with esophageal squamous cell carcinoma [ESCC] who had undergone esophagectomy surgery and 30 normal controls) researchers discovered that 61 percent of patients with ESCC had the bacteria. *P. gingivalis* only presented in 12 percent of noncancerous tissue adjacent to cancerous cells, and was entirely undetected in normal tissue.

# Digital Smile Designing

\* Soumya Mohan B, \* Ebinu A., \*\*Allen Jim Hines, \*\*\*T Sreelal, \*\*\*\*Aparna Mohan, \*\*\*\*Giri Chandramohan

## Abstract

Digital Smile Designing (DSD) allows for the careful analysis of a patient's dental & facial characteristics to assist Prosthetic teams & to evaluate the risk factors & limitations. DSD improves communication between the interdisciplinary dental team & allows them to identify & highlight the hard or soft tissue morphological discrepancies.

KDJ 2017 | Vol. 40 | No. 4 | Pg 248-250

## ► Introduction

The Digital Smile Design (DSD) is a multi-use conceptual tool that can strengthen diagnostic vision, improve communication, and enhance predictability throughout treatment<sup>1</sup>. The DSD allows for careful analysis of the patient's facial and dental characteristics along with any critical factors that may have been overlooked during clinical, photographic, or diagnostic cast-based evaluation procedures<sup>1</sup>.

## ► Aims of DSD

It improves the esthetic planning & smile design & also improves the communication between specialists involved in the case & with that of the patient<sup>12</sup>.

## Advantages of DSD

The DSD protocol offers advantages in the following areas:-

- Esthetic diagnosis
- Communication
- Feedback
- Patient management
- Education

## Necessities of DSD

### The various tools used in DSD are:

Softwares:

Keynote software  
Adobe Photoshop<sup>12</sup>

Photographs:

- 1) full face with a wide smile and the teeth apart
- 2) full face at rest
- 3) retracted view of maxillary arch with teeth apart<sup>12</sup> (Fig 2)

Videos:

The video should capture all possible dental and smile positions, including 45-degree and profile views (Fig 1)

### DSD Workflow

The DSD workflow proceeds as follows:

- 1) The Cross.
- 2) Digital Face-bow
- 3) Smile Analysis.
- 4) Smile Simulation.
- 5) Transferring the cross to intra oral images.
- 6) Measuring tooth preparation
- 7) Tooth Outline.

- 8) White & Pink Esthetic Evaluation.
- 9) Digital Ruler Calibration.
- 10) Transferring the cross to the cast<sup>12</sup>.

The Cross:

Two lines must be placed on the center of the slide, forming a cross. The facial photograph with teeth apart should be positioned behind these lines<sup>3</sup> (Fig3).

Digital Facebow:

Relating the full-face smile image to horizontal reference line is the most important step in smile design process. The interpupillary line should be the first reference line to establish horizontal plane. After determining horizontal reference line, facial midline is outlined according to facial features such as glabella, nose & chin<sup>3</sup>.

Smile analysis:

Dragging horizontal line over the mouth will allow for initial evaluation of relationship of facial lines with smile. Midline, occlusal plane shifting and canting can be easily detected<sup>3</sup>.

### Smile simulation:

Simulations can be performed to fix the incisal edge position, canting, shifting, tooth proportions, and soft tissue outline<sup>3</sup>.

\*PG Students, \*\*Senior Lecturer, \*\*\*Professor & Head of the Department, \*\*\*\*Reader, Dept of Prosthodontics, Sree Mookambika Institute of Dental Sciences, Kulasekharam, Kanyakumari, Tamil Nadu.

• Corresponding Author: Dr Soumya Mohan B, Email: dr.soumyajayakrishnan@gmail.com

**Transferring the cross to intraoral images:-**

To analyze the intraoral photographs in accordance with facial references, the cross must be transferred to the retracted view using three transferring lines drawn over the smile view. It is necessary to calibrate four features on the photograph: size, canting, incisal edge position and midline position<sup>3</sup> (Fig 4, 5)

**Measuring tooth proportion: -**

For measuring the width/length proportion a rectangle is

placed over the edges of both central incisors. The proportions of the patient's central incisors can be compared to the ideal proportions described in the literature<sup>4</sup> (Fig 6, 7)

**Tooth outline:-**

All drawings may be performed depending on what needs to be visualized or communicated for each specific case. Tooth outlines can be drawn over the photograph, or premade tooth outlines can be copied and pasted<sup>4</sup> (Fig 8,9,10)



Fig 1 Videos



Fig 2 Photographs

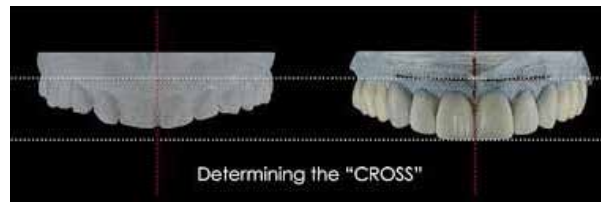

Fig 3 Cross determined



Fig 4 Transferring the cross

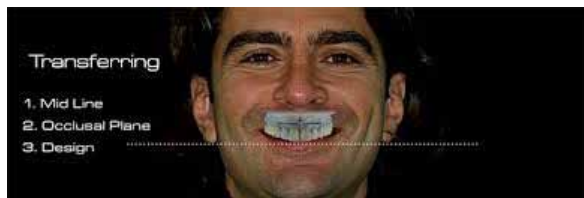

Fig 5 Transferring the cross

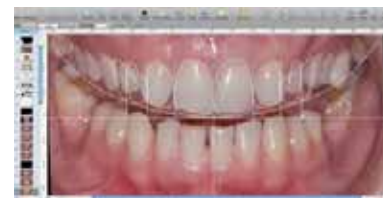

Fig 6 Measuring tooth proportions

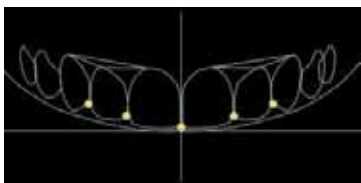


Fig 7 Measuring tooth proportions

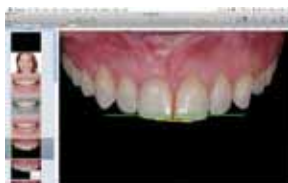

Fig 8 Tooth outline

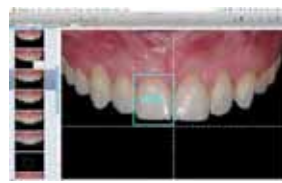

Fig 9 Tooth outline

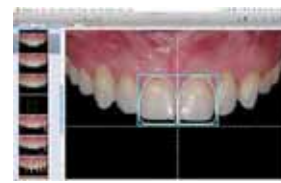

Fig 10 Tooth outline

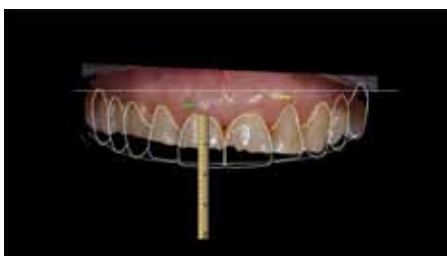

Fig 11 White & pink evaluation

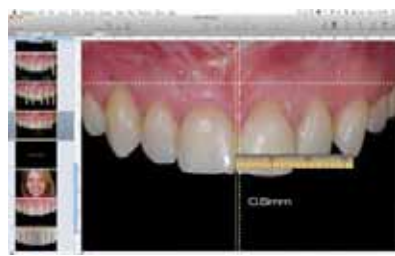


Fig 12 White & pink evaluation

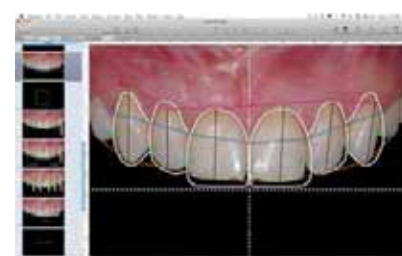


Fig 13 White & pink esthetic evaluation



Fig 14. Digital ruler calibration

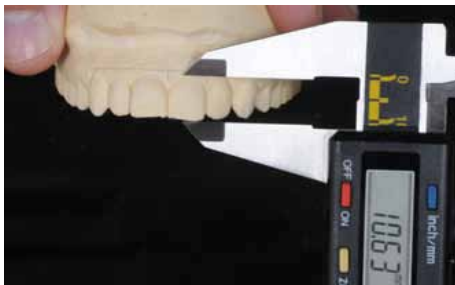

Fig 15 Digital ruler calibration

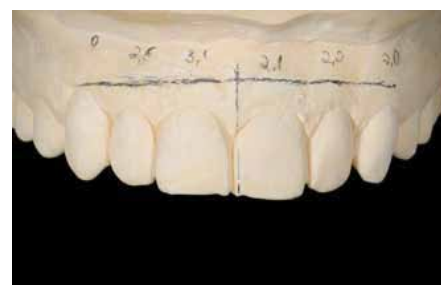

Fig 16 Transferring the cross to the cast.

### White and pink esthetic evaluation: -

Some esthetic issues involved are in tooth proportions, interdental relationship, soft tissue disharmony, relationship between soft tissues & teeth, papillae height, gingival margin levels, incisal edge design and tooth axis<sup>4</sup>. (Fig 11,12 13).

### Digital ruler calibration: -

The digital ruler can be calibrated over the intraoral photograph by measuring length of one of the central incisors on the cast and transferring this measurement to the computer<sup>3,4</sup> Fig (14,15).

### Transferring the cross to the cast: -

After digital ruler calibration measurements & reference lines are transferred to the cast with the aid of caliper<sup>34</sup> (Fig 16)

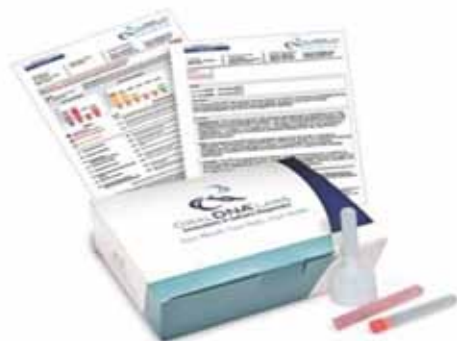### ► Conclusion

DSD is based on better visual communication in daily treatment planning, better integration of interdisciplinary teams & better interaction with the patient. We as dentists, can create different smile designs each one with a specific character. The key is in discovering what is the design that will harmonize with the morphopsychological aspect of the patient.

### ► References

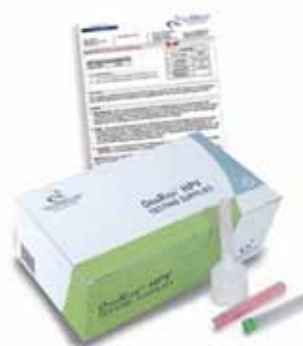1. Coachman C, Van Dooren E, Gürel G, Landsberg CJ, Calamita MA, Bichacho N. Smile design: From digital treatment planning to clinical reality.
2. In: Cohen M (ed). Interdisciplinary Treatment Planning. Vol 2: Comprehensive Case Studies. Chicago: Quintessence 2012:119–174.
3. Goldstein RE. Esthetics in Dentistry. Vol 1: Principles, Communication, Treatment Methods, ed 2. Ontario: BC Decker, 1998.
4. Dawson PE. Functional Occlusion: From TMJ to Smile Design. St Louis: Mosby, 2007.

## MyPerioID® PST® Salivary Diagnostic Test from OralDNA Labs Inc.



The MyPerioID® PST® salivary diagnostic test identifies individual genetic susceptibility to periodontal disease and enables the clinician to establish which patients are at increased risk for more severe periodontal infections due to an exaggerated immune response.

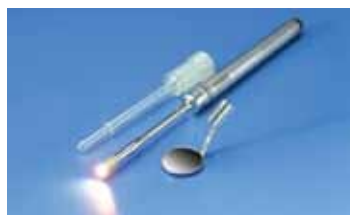## OraRisk® HPV Salivary Diagnostic Test from OralDNA Labs Inc.



The OraRisk® HPV test is a non-invasive screening tool to identify the type(s) of oral HPV, a mucosal viral infection that could potentially lead to oral cancer. OraRisk® HPV enables the clinician to establish increased risk for oral cancer and determine appropriate referral and monitoring conditions.

## Intenso-Point Precision Dental Light from Hager Worldwide, Inc.

The Intenso-Point is a very strong penlight with an intense point-form light source at the end, used to diagnose secondary caries or cracks in teeth. It measures 22 cm (8.7 inches) long and is lightweight at 45 g (1.5 ounces). The set includes 2 batteries, lightbulb and clip-on mouth mirror.



# Management of excessive gingival display

\* Remya Karingattil Sasidharan, \*\*Tessa Paul, \*\*\*Angel Jacob

## Abstract

Excessive gingival display is considered to be a major reason for an unesthetic smile and can create psychological problems to the patients. A disproportionate exposure of gum can result from an under/over developed jaw or high lip position. Gingival hyperplasia, altered passive eruption, vertical maxillary excess, and upper-lip hypermobility can also be reasons for excessive gingival display. Gingivectomy, crown lengthening, and orthognathic surgery are various treatment modalities for this. Lip repositioning surgery (LRS) is another new treatment approach which gained popularity due to its simple surgical technique which can be performed under local anesthesia in dental office with minimal post operative complications and satisfactory results.

KDJ 2017 | Vol. 40 | No. 4 | Pg 251-253

## ► Introduction

An ideal smile depends on the symmetry and balance of the dental and facial features. The lips give the frame of smile and it defines the esthetic pleasing zone. Its level during smiling determines the amount of gingival display.

Excessive gingival display (EGD) commonly named gummy smile, is used when there is an increased exposure of the maxillary gingiva during a smile<sup>1</sup>. In most cases, increase in the gingival tissues displayed during smile, more unesthetic the smile appears<sup>2</sup>.

Thorough examination and correct diagnosis is the key to proper treatment planning and are mandatory in achieving satisfactory results. Satisfying the expectations of the patient turn out to be a major challenge in treating patients with EGD. Vertical Maxillary Excess (VME) can often be treated alone by midface surgery. A Le Fort I procedure separates the maxilla, allowing for segmentalization and three-dimensional repositioning of the dento-alveolar complex<sup>3</sup>. Most patients who undergo this procedure needs hospital stay and another few days to normalize. In some cases of gummy smile, a multidisciplinary approach with either orthognathic surgery, orthodontic treatment, periodontal treatment or restorative dentistry is required<sup>1</sup>. Recently, the injection of botulinum toxin type A has been introduced for treatment of hyperactive upper lip<sup>4</sup>, but it provide only temporary benefits. The financial constrains and duration of treatment are major limitations of these treatments.

Under the right circumstances, lip lowering plastic surgery/ lip repositioning surgery/ mucosal coronally positioned flap (MCPF) and vestibular depth reduction can achieve dramatic results with a much less invasive surgery. Proper case selection is critical for the success of the treatment.

According to Garber et al<sup>5</sup> Vertical Maxillary Excess and its treatment modalities is classified as follows

## ► Case description

A 20 year old female patient reported to the department of Periodontics,

Amrita School of Dentistry complaining of gummy smile. The patient had Grade 3 fluorosed teeth and had fractured upper incisors. Patient was clinically examined and was advised to take OPG, lateral cephalogram and IOPAR of maxillary incisors. Her periodontal health was satisfactory and had no extruded teeth. She was a typical case of vertical maxillary excess with hyperactive mobile upper lip.

The patient was suggested to undergo orthodontic treatment and orthognathic surgery but was unwilling to take up the treatment due to financial problems and wanted a faster result with the treatment. So she was given the option of lip repositioning surgery. Chances for relapse was explained and documented consent was signed by patient. The past medical and dental history were recorded and routine blood investigations were done. The patient's photographs were taken and the treatment plan was decided.

## ► Surgical technique

The surgery was performed in 3 stages.

- Stage I - Presurgical trial (reverse trial technique)
- Stage II - Mucosal coronally positioned Flap (vestibular depth reduction)
- Stage III - Gingivectomy

The area was anesthetized using 2% lignocaine with 1: 80000 adrenaline after

\* Assistant Professor, Dept of Periodontics, Al Azhar Dental College, Muvattupuzha; \*\*Assistant Professor, Dept of Dentistry, Government Medical College, Ernakulam; \*\*\*Professor, Dept. of Periodontics, Amrita Institute of Medical Sciences • Corresponding Author: Dr. Remya K.S, E-mail: remyasurabhi@gmail.com

patch test. The infraorbital block was used to avoid thickening of the lip and tissues which may adversely affect the appearance after presurgical trial.

After achieving adequate anesthesia, the superior and inferior borders of the surgical site were marked using ball electrode of electrocautery unit. Markings were placed every 4 to 5 mm surrounding the proposed site of tissue excision. The inferior border of this was defined by the mucogingival junction from the mesial aspect of the first molars bilaterally. The superior border was best described as moustache-shaped; slightly inferior in the area of the labial frenum, cresting in the region of canine and tapering toward the posterior. As a general rule, it has been suggested that the distance between the superior and inferior borders be twice the length of repositioning desired in the smile<sup>8</sup> (Fig 3).

After marking the superior and inferior borders temporary sutures were placed using resorbable 3-0 sutures (Vicryl) (Fig 4).

Photographs were taken and the patient and bystander were asked to evaluate the result. Patient was also advised to view the result using a mirror. They were encouraged to point out any concerns and given time to affirm their desire for definitive treatment.

The patient was satisfied with the result and was willing to go for definitive surgery. The epithelium along with some connective tissue bounded by these incisions was removed beginning from 26 to 16 region (Fig 5). The approximate tissue thickness was 1 mm. Tissue tags were removed and the area was thoroughly irrigated using normal saline. Bleeding was controlled and the mucosal flap was coronally advanced and

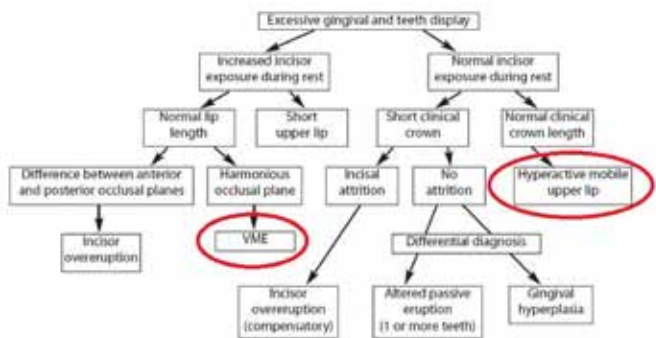


Fig. 1 Flow chart showing the correct etiology of excessive gingival display

Degree	Gingival and mucosal display (mm)	Treatment modalities
I	2-4	Orthodontic intrusion Orthodontics and periodontics Periodontal and restorative therapy
II	4-8	Periodontal and restorative therapy Orthognathic surgery (Le Fort I osteotomy)
III	≥ 8	Orthognathic surgery with or without adjunctive periodontal and restorative therapy

Fig. 2 Classification of Vertical Maxillary Excess and its treatment modalities by Garber et al.

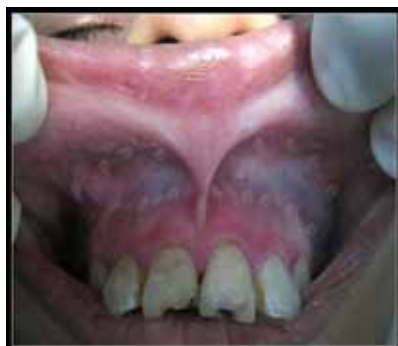

Fig. 3 Presurgical trial - Surgical site marked with electrocautery unit

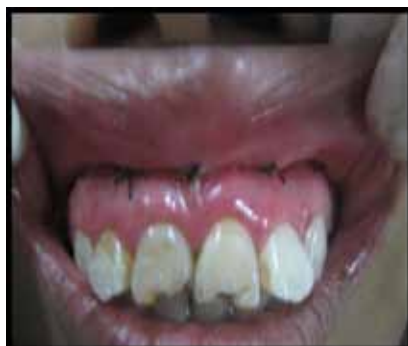

Fig. 4 Temporary sutures placed using resorbable 3-0 sutures

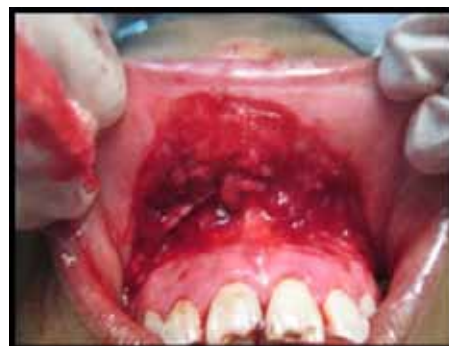

Fig. 5 Vestibule following mucosal resection

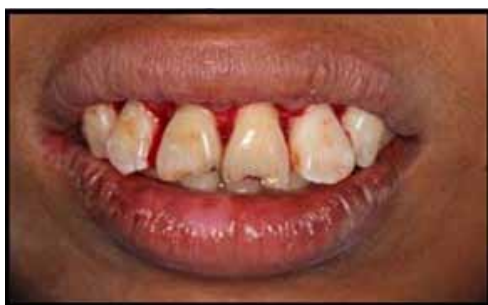

Fig. 6 After Gingivectomy procedure

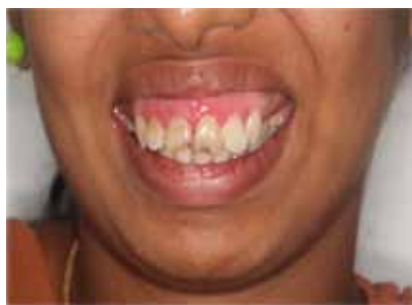

Fig. 7 Preoperative

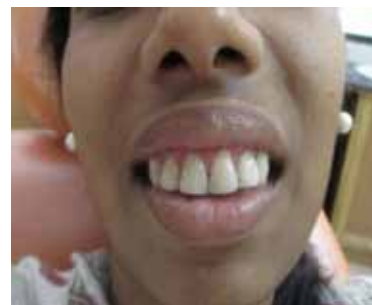

Fig. 8 Postoperative



sutured at the mucogingival junction. Midline tissues were first approximated continuing to both ends using simple continuous sutures (3-0 vicryl).

A soft diet was recommended for 24 hours. Patient was asked to avoid high smiling for one week, Antibiotics, non-steroidal anti-inflammatory drugs and serratiopeptidase were recommended to reduce the inflammation and pain control. She was also asked to use cold packs intermittently for the first 24 hours following surgery.

The patient was reviewed after one week and she reported that the post operative period was uneventful except for the slight pain and swelling for the first 2 days. Slight erythema and scar formation at the mucogingival junction were noticed.

The patient was advised to maintain proper oral hygiene and to limit the lip movements and to review after one month for gingivectomy of maxillary anteriors. We proceeded with the gingivectomy procedure maintaining the biological width and a periodontal pack was placed (Fig 6).

After one week she was referred to the endodontist who did intentional root canal treatment of 11 and 21 and veneering for the maxillary anterior teeth.

After the completion of procedure we could obtain a satisfactory result (Fig 7&8). The patient reported that for the first time she was confident when smiling in public. This case is a combination of periodontal and restorative treatment to improve dentofacial esthetics; above all, it guarantees patient satisfaction.

### ► Discussion

Lip lowering periodontal plastic surgery is a very cost effective and minimally invasive procedure to treat excessive gingival display. The lip lowering procedure is essentially a reverse frenectomy procedure. The purpose of this technique is to reduce the vestibular length or shorten the fold between the lip and gum thereby reducing the amount of movement of lip.

Successful treatments with variations of lip repositioning surgery (LRS) were first described in the medical literature in 1973 by Rubinstein and Kostianovsky<sup>6</sup>. In 1979, Litton and Fournier described gummy smile correction with LRS, including elevator muscle detachment in cases with a short upper lip<sup>7</sup>. Miskinyar in 1983, reported little success with LRS, but saw no relapse in 27 patients treated with myectomy and partial resection of either one or both of the levator

labii superioris muscles bilaterally<sup>8</sup>. Ellenbogen and Swara reported success in limiting lip elevation on smiling (maximum correction of 6 mm) by partially transecting the lip elevator muscles and implanting a silicone spacer<sup>9</sup>. Ezquerra et al presented a successful treatment for EGD using a combination of crown lengthening and subperiosteal dissection<sup>10</sup>. No side effects due to LRS, other than mild discomfort for 24 to 48 hours, were found in a case series by Jacobs et al<sup>11</sup>. Miskinyar noted one patient with 2.5 months unilateral paresthesia, and Rosenblatt reported another patient with a mucocele that resolved without treatment<sup>8</sup>. Relapse over a period of the long term cannot be ruled out, and future research should aim to evaluate stability of the result.

### ► Conclusion

Lip repositioning is an excellent alternative to the more costly and time-consuming treatments available for excessive gingival display for patients desiring a less invasive alternative to orthognathic surgery, the MCPF is an appropriate alternative. Reversible presurgical procedure prior to definitive surgery, is currently the best way for both the patient and doctor to preview the intended result before moving forward with elective surgery. The psychosocial benefits of repositioning of lip, and its minimal risk are the main advantages. Future studies with longer follow-ups to evaluate its efficacy and stability are warranted.

### ► References

1. Allen EP. Use of mucogingival surgical procedures to enhance esthetics. *Dent Clin North Am* 1988;32:307-330.
2. Isiksal E, Hazar S, Akyalcin S. Smile esthetics: Perception and comparison of treated and untreated smiles. *Am J Orthod Dentofacial Orthop* 2006; 129:8-16.
3. Booth PW, Schendel SA, Hausamen J. *Maxillofacial Surgery*, vol. 2. St. Louis: Churchill Livingstone; 2009:1275-1288.
4. Polo M. Botulinum toxin type A (Botox) for the neuromuscular correction of excessive gingival display on smiling (gummy smile). *Am J Orthod Dentofacial Orthop* 2008;133:195-203.
5. Garber DA, Salama MA. The aesthetic smile: Diagnosis and treatment. *Periodontol* 2000 1996;11:18-28.
6. Rubinstein A, Kostianovsky A. Cirugia estetica de la malformacion de la sonrisa. *Pren Med Argent* 1973;60:952.
7. Litton C, Fournier P. Simple surgical correction of the gummy smile. *Plast Reconstr Surg* 1979;63:372-373.
8. Miskinyar S. A new method for correcting a gummy smile. *Plast Reconstr Surg* 1983;72:397-400.
9. Ellenbogen R, Swara N. The improvement of the gummy smile using the implant spacer technique. *Ann Plast Surg* 1984;12:16-24.
10. Ezquerra F, Berrazueta M, Ruiz-Capillas A, Arregui J. New approach to the gummy smile. *Plast Reconstr Surg* 1999;104:1143-1150.
11. Jacobs PJ, Jacobs BP. Lip Repositioning with Reversible Trial for the Management of Excessive Gingival Display: A Case Series. *Int J Periodontics Restorative Dent* 2013;33:169-175.

# Noonan Syndrome

\* Jaseena PM., \*\* Rita Zarina, \*\*\* Digesh Balachandran, \*\*\*\* Lubna M., \*\*\*\*\* Veena S. Ravi,

## Abstract

Noonan syndrome [NS] is an autosomal dominant inherited condition that can be passed down through families. Noonan syndrome was first recognized as a unique entity in 1963 by Noonan and Ehmke. It affects both females and males, and has an estimated incidence of 1 per 1,000-2,500 live births. The general features of Noonan syndrome include unusual facies (i.e., hypertelorism, down-slanting eyes, and low set ears), congenital heart disease, short stature, and chest deformity. Dental features include a high arched palate, malocclusion, micrognathia etc.

**Keywords:** Noonan Syndrome, Hypertelorism, Congenital Heart Disease

KDJ 2017 | Vol. 40 | No. 4 | Pg 254-255

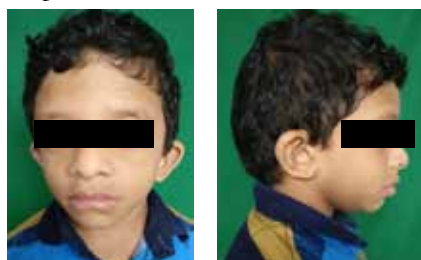## Introduction

Noonan syndrome was first described as a multisystem disorder by Noonan and Ehmke in 1963. They defined a specific group of nine patients with pulmonary stenosis, short stature, mild mental retardation, hypertelorism, low-set ears and unusual but similar faces.<sup>1</sup> Other general aspects reported in literature are: broad or webbed neck, a peculiar chest deformity – pectus carinatum superiorly and pectus excavatum inferiorly, congenital heart diseases, swallowing difficulties, mental retardation, poor coordination, learning disabilities, speech delays, joint or muscle pain and coagulation deficiencies.<sup>2-5</sup> Skeletal, neurologic, genitourinary, lymphatic, eye, and skin findings may be present to varying degrees.<sup>6</sup>

The pathophysiology of Noonan syndrome is not fully understood but is associated with mutations in genes that are part of the RAS/RAF/MEK/ERK signal transduction pathway, an important regulator of cell growth.<sup>7-8</sup>

## Case History

An 8 year old boy, referred by a general physician reported to the Department of Pedodontics with his

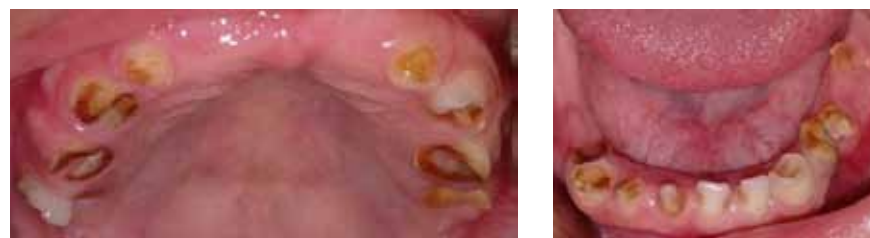

**Fig. 1** Facial aspects of the child showing facial asymmetry, hypertelorism, depressed nasal bridge, low set ears with auricular tags, broad philtrum and short neck

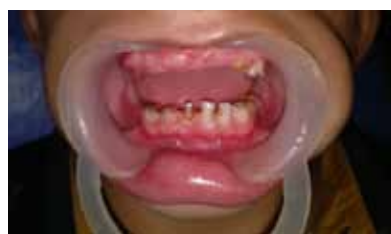parents. The child had multiple decayed teeth in both upper and lower arch.

General examination revealed a relatively short stature (height: 104 cm, weight: 14 kg). Facial features were hypertelorism, down slanting palpebral fissures, depressed nasal bridge, low set ears with auricular tags, broad philtrum and short neck. He had a mild facial asymmetry with a relatively large nose and thick lips. Oral examination revealed the primary dentition with extensive and multiple carious lesions. The upper primary central incisors were exfoliated. The patient presented a high-arched palate with prominent rugae.

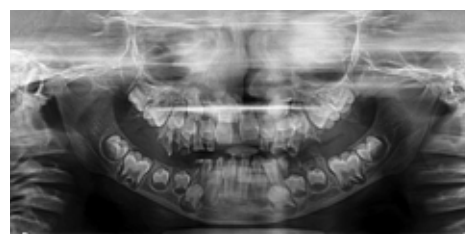Orthopantomography shows slightly delayed dental age. All the permanent teeth except third molars were present in the radiograph.



**Fig. 2** Intra-oral view



**Fig. 3** Intra-oral view



**Fig. 4** Orthopantomography

\*PG student, \*\* Professor and Head, \*\*\*Asst. Professor, \*\*\*\* P.G. student, Dept. of Pedodontics and Preventive Dentistry, Govt. Dental College, Kottayam, Kerala. • Corresponding Author: Dr. Jaseena PM., E-mail: drjesy@gmail.com

A detailed medical and dental history obtained from his mother. The child's medical reports showed that the child had Noonan syndrome diagnosed at the age of 6 years when they consulted for short stature. It was confirmed by DNA test for mutation analysis. Cardiac anomalies were detected at the age of 2 months – ventricular Septal Defect, Sub aortic, moderate and mild Pulmonary Stenosis, which got resolved by its own at the age of 6 years. All the milestones were delayed. The child had speech difficulties also. Extractions of all grossly decayed teeth were planned after clearance from the Cardiologist.

### ► Discussion

Noonan syndrome (NS) is a common, clinically and genetically heterogeneous condition characterized by distinctive facial features, short stature, chest deformity and congenital heart disease. It is an autosomal dominant disorder with complete penetrance but variable expressivity. Until recently, diagnosis was based solely on clinical findings, but genetic mutations are identifiable in approximately 61% of the patients. Facial and musculoskeletal features most often lead to the diagnosis of NS. The facial appearance is most characteristic in infancy and early-to middle childhood and becomes more subtle in adulthood.<sup>9</sup>

The characteristic features of Noonan syndrome includes: Eyes are wide-set and down-slanting with droopy lids. Irises are pale blue or green. Ears are low-set and rotated backward. Nose is depressed at the top, with a wide base and bulbous tip. The face may appear droopy and expressionless. Head may appear large with a prominent forehead and a low hairline on the back of the head. Approximately 50% to 70% of individuals with NS have short stature.

The most common congenital heart defect is pulmonary valve stenosis with dysplastic leaflets (50%–62%). Characteristic chest deformities consist of pectus carinatum superiorly and pectus excavatum inferiorly.

Oral findings in patients with NS include a high arched palate (55%–100%), dental malocclusion (50%–67%), articulation difficulties (72%), and micrognathia (33%–43%).<sup>10</sup> Some individuals with NS develop mandibular cysts, which can mimic cherubism.<sup>12</sup>

Missense mutations in the protein tyrosine phosphatase non-receptor type 11 gene (PTPN11) has been recently identified as the first molecular causes of NS. Defects in these genes cause the production of proteins that are continually active. Because these genes play a role in the formation of many tissues throughout the body, this constant activation of proteins disrupts the normal process of cell growth and division. The failure to identify a PTPN11 mutation does not rule out Noonan syndrome.

In the present case, though the patient had cardiac defects diagnosed at the age of 2 months, the syndrome identified only at 6 years when they consulted the physician for short stature. Currently he is under hormonal therapy, closely monitored by an endocrinologist. The child is below average in school and has speech difficulty. Extraction of primary anterior teeth (71, 81) was done under local anaesthesia after obtaining consent from parents. The frequency of control visits scheduled at 3 months and the eruption needs to be evaluated.

### ► Conclusion

As patients with Noonan syndrome exhibits many health issues, a multidisciplinary approach involving Pedodontist, Orthodontist, and Endocrinologist should be planned. Optimal health care should be provided not only during childhood but throughout adulthood. As a Pediatric dentist we should be more alert in treating such patients because before planning a comprehensive treatment plan patient's medical history should be thoroughly evaluated. Often a Pediatric dentist may be the first person to identify such patients with syndromes and may address the various needs for improving the quality of such patients.

### ► References

1. Noonan JA, Ehmke DA (1963). Associated noncardiac malformation in children with congenital heart disease. *J Pediatr* 63, 468-470.
2. Jamieson CR, van der Burgt I, Brady AF, van Reen M, Elswawi MM, Hol F, Jeffery S, Patton MA, Mari-man E (1994). Mapping a gene for Noonan syndrome to the long arm of chromosome 12. *Nat Genet* 8, 357-360.
3. Noonan JA (1999). Noonan syndrome revisited. *J Pediatr* 135, 667-668.
4. Sharland M, Burch M, McKenna WM, Paton MA (1992). A clinical study of Noonan syndrome. *Arch Dis Child* 67, 178-183.
5. Judith E Allanson (1987). Noonan Syndrome, *Journal Of Medical Genetics*, 24, 9-13.
6. Romano AA, Allanson JE, Dahlgren J, et al. Noonan syndrome: clinical features, diagnosis, and management guidelines. *Pediatrics*. 2010 Oct. 126(4):746-59.
7. Razzaque MA, Nishizawa T, Komoike Y, et al. Germline gain-of-function mutations in RAF1 cause Noonan syndrome. *Nat Genet*. 2007;39(8):1013-1017
8. Roberts AE, Araki T, Swanson KD, et al. Germline gain-of-function mutations in SOS1 cause Noonan syndrome. *Nat Genet*. 2007; 39(1):70-74.
9. Allanson JE, Hall JG, Hughes HE, Preus M, Witt RD. Noonan syndrome: the changing phenotype. *Am J Med Genet*. 1985; 21(3): 507-514.
10. Shaw AC, Kalidas K, Crosby AH, Jeffery S, Patton MA. The natural history of Noonan syndrome: a long-term follow-up study. *Arch Dis Child*. 2007; 92(2):128-132.
11. Nora JJ, Nora AH, Sinha AK, Spangler RD, Lubs HA. The Ullrich-Noonan syndrome (Turner phenotype). *Am J Dis Child*. 1974; 127(1):48-55.
12. Jafarov T, Ferimazova N, Reichenberger E. Noonan-like syndrome mutations in PTPN11 in patients diagnosed with cherubism. *Clin Genet*. 2005; 68(2): 190-191

# Nager syndrome (Preaxial acrofacial dysostosis)

\* Lubna M., \*\* Rita Zarina A., \*\*\* Digesh Balachandran, \*\*\*\*Veena S. Ravi, \*\*\*\*\*Jaseena P.M.

## Abstract

Nager's acrofacial dysostosis is a rare congenital anomaly in which mandibulofacial dysostosis is seen in combination with limb deformities, particularly hypoplasia of the radial aspect of the hand. Craniofacial findings include micrognathia, malar hypoplasia, downslanting palpebral fissures, cleft palate, and ear anomalies. Radial defects include hypoplastic thumb, short forearm, and proximal radioulnar synostosis. Nager syndrome is an extremely rare congenital defect with only around 100 cases reported in the medical literature. This case report describes the dental management of an 8 year old girl diagnosed with Nager syndrome.

**Keywords:** Nager syndrome, craniofacial anomaly, mandibular hypoplasia.

KDJ 2017 | Vol. 40 | No. 4 | Pg 256-257

## ► Introduction

Nager syndrome was first recognised as a specific entity by Nager and de Reynier (1948), but was probably first reported by Slingenberg (1908).<sup>1</sup>

Nager syndrome belongs to a group of disorders collectively known as acrofacial dysostoses or AFDs. These disorders are characterized by craniofacial and limb abnormalities. AFDs are generally broken down into preaxial and postaxial types. Nager syndrome is a preaxial form; the term preaxial refers to the bones of the arms

and legs that are on the thumb and big toe sides of the body.

The craniofacial deformities seen in Nager acrofacial dysostosis include downward slanting palpebral fissures, malar hypoplasia, high nasal bridge, micrognathia and external ear defects. Lateral extension of scalp hair onto the cheeks, reduced number of eyelashes and lower lid colobomas occur less frequently; while conductive hearing loss is seen frequently.<sup>1</sup> Predominant oral findings include cleft palate and an absent soft palate. Typical upper limb abnormalities include absent radii, radioulnar synostosis and hypoplastic or absent thumbs. Lower limb anomalies also seen are absent tibia/fibula, talipes equinovarus and dislocated hips.<sup>2</sup> Although speech development may be delayed due to hearing impairment, Nager syndrome does not affect a child's intelligence. Other structural malformations seen less frequently are tetralogy of Fallot, diaphragmatic hernia, spina bifida, scoliosis, renal agenesis or malposition, duplicated calyces, bicornuate uterus. A few patients also exhibit microcephaly, hydrocephalus and mental retardation.<sup>3</sup>

Most cases appears to be sporadic, however, autosomal dominant or autosomal recessive inheritance has been mentioned.<sup>4</sup> The occurrence of affected siblings with normal parents suggests genetic heterogeneity and an additional autosomal recessive form. Thus the pattern of inheritance remains

unclear.<sup>2</sup> In 2012, Canadian researchers demonstrated Nager syndrome to be caused by haploin sufficiency of the spliceosomal factor SF3B4. Some case reports have documented drug exposure during the first trimester; however, there is no conclusive proof of teratogenic potential.<sup>5</sup> Diagnosis is made based on the clinical features, patient history, and genetic testing of the child and parents.

## ► Case Report

An 8 year old girl was referred to the Department of Pediatric and Preventive Dentistry with an abscess associated with upper right posterior carious tooth. A general assessment showed evidence of malformations in other areas. She was born to a healthy mother via C section, the birth body weight was 2140 g. There was no family history of congenital abnormalities or consanguinity.

Her craniofacial examination revealed malar hypoplasia, severe mandibular hypoplasia, downward slanted palpebral fissures, deviated nasal septum, a high narrow hard palate, small retroplaced tongue and dysplastic low set ears. There was marked restriction of jaw movement (trismus).

Besides her unusual facial appearance, the patient also had anomalies in both hands with hypoplastic thumb and fingers fixed in a bent position (camptodactyly). The arms were short and elbow articulation had motion limitations in extension and flexion.

\* Post graduate student, \*\* Professor and Head, \*\*\* Assistant Professor, \*\*\*\* Post graduate student, Department of Pedodontics and Preventive Dentistry, Government Dental College, Kottayam, Kerala.  
• Corresponding Author: Dr. Lubna M., E-mail: itzlubnamooliyathodi@gmail.com

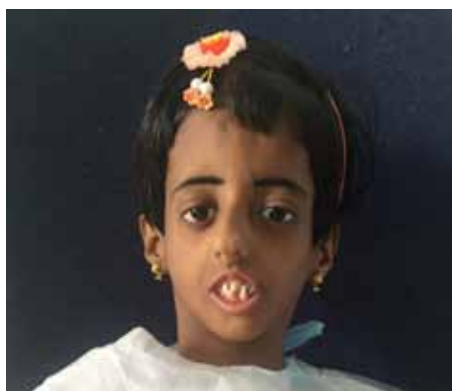In the lower limbs there was genu varum (bowing of legs). There was no evidence of mental retardation. The patient had undergone surgery twice for diaphragmatic hernia, a rare feature associated with Nager syndrome. Based on the patient's craniofacial characteristics and the coexisting upper limb preaxial anomalies, a diagnosis of Nager syndrome was confirmed during infancy.

Oral examination revealed grossly decayed deciduous molars with periapical abscess in relation to upper right posterior carious tooth, acute gingivitis with poor oral hygiene, narrow V shaped arches with upper and lower anterior crowding, abnormal overjet and overbite, and incompetent lips. OPG revealed severe tooth size arch space discrepancy.

Treatment started with patient and parent counselling, education and motivation being the first priority. Brushing techniques were demonstrated and she was advised to take low sugar diet to prevent further caries progression. Grossly decayed deciduous molars and retained deciduous primary incisors were extracted. The patient is currently under follow up and development of occlusion is being monitored. Surgical intervention is planned in near future for mandibular mobilization, as well as to improve her total facial appearance.

## ► Discussion

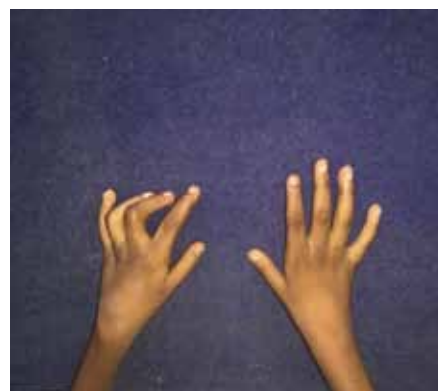Nager syndrome is a rare disorder resulting from developmental abnormalities of the first and second branchial arches<sup>6</sup> and is linked to five other similar syndromes: Miller syndrome, Treacher-Collins, Pierre-Robin, Genee Wiedemann, and Franceschetti-Zwahlen Klein. The facial features of Nager syndrome grossly resemble those of Treacher-Collins syndrome<sup>7</sup>; however, differentiation between the two can be made. Patients with Treacher-Collins syndrome have more severe forms of hypoplastic zygoma, downward slanting palpebral fissures, lower lid colobomata, and hypoplastic maxilla.<sup>8</sup> In general, these particular characteristics are less severe in Nager syndrome. Typical of Nager syndrome is a more extreme degree of mandibular hypoplasia, a greater frequency of palate abnormalities, and limb anomalies.<sup>9</sup> The pathogenesis of Nager syndrome may be attributed to disturbances in development of the proximal aspects of the maxillary and mandibular prominences of the first branchial arch and the apical ectodermal ridges of the limb buds.<sup>10</sup> While the patient had a severe degree of mandibular hypoplasia and limitation of mandibular motion with severe trismus, her limb anomalies were not unusually severe. The craniofacial characteristics and coexisting upper limb preaxial anomalies of Nager syndrome are listed in table along with the positive findings in this case.



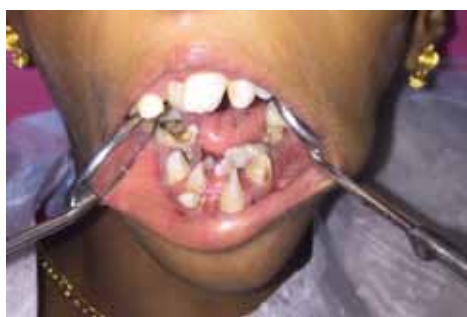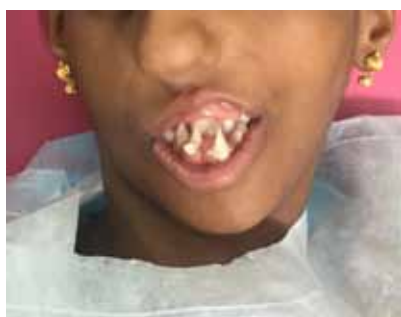**Fig. 1** Malar hypoplasia, downward slant of orbit, reduced number of eyelashes on the lower eyelid



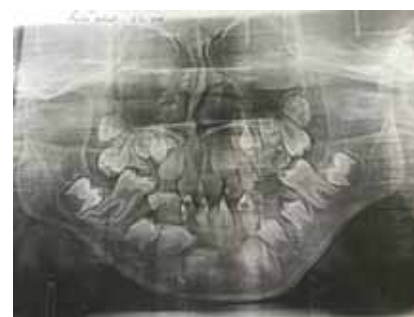**Fig. 2** Dysplastic low set ears



**Fig. 3** Hypoplastic thumbs and camptodactyly of left fingers



**Fig. 4 and 5** Crowded upper and lower arches, abnormal overjet and overbite, grossly decayed primary molars



**Fig. 6** OPG showing severe crowding, deviated nasal septum

Clinical and radiographic features commonly encountered in preaxial acrofacial dysostosis (Nager syndrome) along with the positive findings in this case.<sup>11</sup>

Common features	Present case
<b>Maxillofacial area</b>	
• Zygomatic hypoplasia	+
• Downslanting palpebral fissures	+
• Mandibular hypoplasia	+
• Lower eyelid colobomas	
• Cleft palate	
<b>Ear involvement</b>	
• External ear malformation	+
<b>Limbs</b>	
• Thumb aplasia or hypoplasia	+
• Radial defects	+
<b>Others</b>	
• Genitourinary abnormalities	
• Reduced stature	

Many of the previous cases of Nager syndrome reported were identified when the children were newborn, therefore their intellectual capability could not be assessed. It seems that mental retardation and developmental problems in Nager syndrome are secondary to hearing dysfunction, which was not observed in this case. Ear deformities have been described in 88% of the patients reported.<sup>9</sup> Hearing levels should be assessed during early infancy using electrophysiologic testing such as measurement of auditory brainstem responses and later confirmed using behavioral audiometry. Speech difficulties can also arise from impaired hearing, as well as from velopharyngeal insufficiency. Cleft palate is common in Nager syndrome, but was not observed in this case.

Due to very limited jaw opening in some cases and coexisting limb abnormalities, maintenance of adequate oral hygiene may represent a major problem, and self-care may be impossible. It is important that their parents are counselled regarding the deleterious effects of the foods containing refined carbohydrates on the dental health. Anomalies of the distal upper limb have been reported in 100% of patients with Nager syndrome with a notable inclusion of the thumbs. A variety of toothbrush modifications are now available that require minimal manual dexterity.

In this case, multidisciplinary management by a craniofacial team is needed. Early intervention, new surgical techniques, and an emphasis on coordinated care have improved the quality of life for this patient with Nager syndrome. Cooperation between pediatrics, otolaryngology, head and neck surgery, plastic surgery, dentistry, orthopedic surgery, genetics, developmental psychology, developmental pediatrics, audiology and speech/language pathology is needed to optimize the treatment strategy.<sup>11</sup>

### ► Conclusion

Although Nager syndrome is not encountered routinely in the dental clinic, this case illustrates the importance of dentists being acquainted with such rare conditions. Such cases if properly followed up definitely restore not only dental health, but also assist in maintaining the general health of these patients as long as they survive.<sup>12</sup>

### ► References

1. Silveira A, Joshi A S, Shahani M. Preaxialacrofacialdysostosis (Nager syndrome): a case report. *Journal of Disability and Oral Health* (2007) 8/2 91–94
2. McDonald MT, Gorski JL: Nager acrofacialdysostosis. *J Med Genet* 1993; 30: 779–782.
3. Giugliani R, Pereira CH. Nager'sacrofacialdysostosis with thumb duplication: report of a case. *Clin Genet* 1984; 26: 228–230.
4. Kavadia S, Kaklamanos E, Antoniadis K, Lafazanis K, Tramma, D. Nager syndrome (preaxialacrofacialdysostosis): a case report. *Oral Surg Oral Med Oral Pathol Oral Radio Endo* 2004; 97: 732–738.
5. Halal F, Hermann J, Pallister PD, Opitz JM, Desgranges MF, Greenier G. Differential diagnosis of Nager acrofacialdysostosis syndrome: Report of four patients with Nager syndrome and discussion of other related syndromes. *Am J Med Genet* 1983; 14: 209–224.
6. Vargervik K. Mandibular malformations: Growth characteristics and management in hemifacialmicrosomia and Nager syndrome. *Acta Odontol Scand* 1998; 56: 331–8.
7. Burton BK, Nadler HN. Nager acrofacialdysostosis, report of a case. *J Pediatr* 1977; 91(1): 84–6.
8. Hecht J T, Immken LL, Harris LF, Malini S, Scott IS. Brief clinical report: The Nager syndrome. *Am J Med Genet* 1987; 27: 965–9.
9. Danziger I, Brodsky L, Perry R, Nusbaum S, Bemat J, Robinson L. Nager'sacrofacialdysostosis. Case report and review of the literature. *Int J PedOtorhinolaryngol* 1990; 20: 225–40.
10. Sulik KK, Dehart DB. Retinoic-acid-induced limb malformations resulting from apical ectodermal ridge cell death. *Teratology* 1988; 37: 527–37
11. Fakhim S, Shahidi N, Mousaviagdas M.A Case Report: Nager AcrofacialDysostosis *Iranian Journal of Otorhinolaryngology* No.1, Vol.24, Serial No.66, Winter-2012
12. S.Thomas, S.Tandon.Hurler syndrome:a case report *J ClinPediatr Dent* 24(4):335–338, 2000

# Dentigerous cyst involving maxillary sinus

\* Remya K.C., \*\*Rita Zarina. \*\*\* Digesh Balachandran, \*\*\*\*Lubna M, \*\*\*\* Veena S. Ravi,

## Abstract

Dentigerous cysts are the most common developmental cysts of the jaw and the second most common type of odontogenic cysts after radicular cysts. It involves the crown of unerupted, impacted or embedded teeth. It is often asymptomatic and can be found incidentally on dental radiography with delayed eruption of teeth. However, it can be large and cause symptoms related to expansion and impingement on contiguous structures. This case report describes dentigerous cyst associated with left maxillary second premolar in a nine year old boy which had extended the entire maxillary sinus with premolar tooth bud being pushed into the sinus.

**Keywords:** dentigerous cyst, maxillary sinus, maxillary premolar

KDJ 2017 | Vol. 40 | No. 4 | Pg 259-261

## ► Introduction

The dentigerous cyst is a common developmental odontogenic cyst of the oral cavity. It accounts for the second most common cyst of the jaws comprising 14–20 per cent of all jaw cysts, with higher predilection for males.<sup>1</sup> Dentigerous cysts are benign odontogenic lesions resulting from accumulation of fluid between the enamel crown and enamel epithelium and cystic proliferation of reduced enamel epithelium after the formation of tooth crown.<sup>2</sup>

The cyst cavity is lined with reduced enamel epithelium derived from the

tooth-forming organ. The clinical findings are cortical bone expansion, adjacent permanent tooth bud displacement, and root dilacerations.<sup>3</sup> Such cysts remain initially completely asymptomatic unless when infected and can be discovered only on routine radiographic examination.<sup>4</sup> The dentigerous cyst can produce asymmetries, nerve alterations by compression, move teeth and even become malignant ameloblastoma, mucoepidermoid, or epidermoid carcinoma. For this reason, the therapeutic approach becomes important.<sup>5</sup>

## ► Case report

A Nine year old boy Presented with a chief complaint of delayed eruption of anterior teeth reported to the Department of Pedodontics and Preventive Dentistry in Govt Dental College, Kottayam. The patient was apparently healthy on general examination. The past medical history was not significant. Assessment of eruption status with Orthopantomogram revealed a lesion. Patient was totally asymptomatic. (Fig: 1)

On Intra oral examination Oral mucosa was found to be apparently normal with no signs of inflammation. Swelling & tenderness was absent. Grade I mobility in relation to 65 noted. (Fig:2) Orthopantomogram revealed a well defined radio opacity in left maxillary sinus region with second premolar tooth bud pushed into the sinus.(Fig:3) Coronal, sagittal and axial views of cone beam computer tomography images of

maxillary left premolar region revealed a well circumscribed hypo intense lesion with tooth in situ, suggestive of dentigerous cyst involving maxillary sinus. (Fig. 4) Fine needle aspiration Cytological smear revealed cholesterol crystals, RBCs, acute inflammatory cells and chronic inflammatory cells.(Fig. 5)

Enucleation of the cyst was done under general anaesthesia via Caldwell Luc approach after carrying out routine investigations which were within normal limits. (Fig. 6) A mucoperiosteal flap was raised from left maxillary lateral incisor to first permanent molar region and the cystic lining along with the ectopic tooth was detached from cavity walls carefully. (Fig. 7) First premolar tooth bud was extracted as the bony walls were destroyed. Primary closure was done after achieving haemostasis. The enucleated tissue was sent for histopathological examination.

The gross specimen consisted of a reddish brown cystic mass measuring approximately  $3.5 \times 3.0 \times 1.5$  cms containing the developing premolar tooth bud within it.(fig:7) The histological examination showed a benign cyst lined by hyperplastic odontogenic epithelium and elongated rete pegs. Stroma was infiltrated with chronic inflammatory cells chiefly lymphocytes juxta epithelically. Moderate inflammatory infiltrate and vascularity of tissue also noted. The microscopic study was consistent with the diagnosis of the dentigerous cyst.

No complications occurred intraoperatively. Antimicrobial and

\*Senior Lecturer, \*\* Professor and Head, \*\*\*Assistant Professor, \*\*\*\* Post graduate student, Department of Pedodontics and Preventive Dentistry, Government Dental College, Kottayam, Kerala  
• Corresponding Author: Dr. Remya K.C., E-mail: remyakc2010@gmail.com

anti-inflammatory drugs were prescribed for the 1st post-operative week. The patient presented a good healing and reduced inflammation at the control appointment.(fig:9)

► **Discussion**

The dentigerous cysts were described by Paget in 1863. They are most frequently found in individuals in the age group between 20 and 40 and generally appear during tooth development in young patients. Single dentigerous cysts are very common odontogenic cysts after radicular cysts.<sup>5</sup>

The pathogenesis of dentigerous cyst is by the accumulation of fluid either between the reduced enamel epithelium and the enamel or between the layers of the enamel organ. This fluid accumulation might be a result of pressure exerted by a potentially erupting tooth on the follicle, which obstructs

the venous outflow and induces serum transudation across the capillary wall.<sup>6</sup>

There are 2 types of dentigerous cysts. The first is developmental in origin and occurs in mature teeth, usually as a result of impaction. These cysts usually occur in the late second and third decades and predominantly involve mandibular third molars. The second type is inflammatory and occurs in immature teeth as a result of inflammation from a nonvital primary tooth or other source, subsequently spreading to the tooth follicle<sup>7</sup>. These are often diagnosed in the first and early part of the second decade of life, and predominantly involve mandibular premolars. The case presented might be classified as inflammatory, due to the lesions related with the carious primary mandibular left second molar and the patient's age.

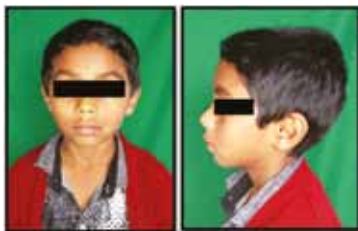

Fig. 1 Extraoral view

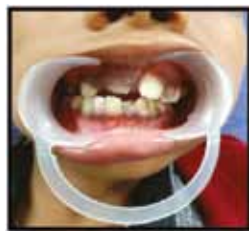

Fig. 2 Intraoral view

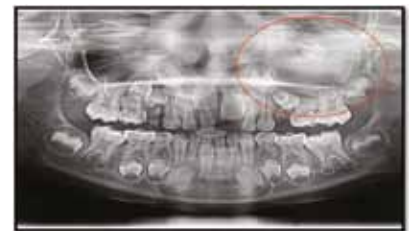
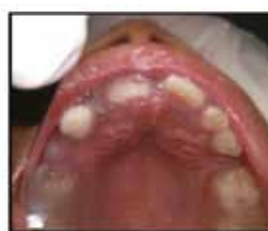
Fig. 3 Orthopantomogram showing radiopacity in relation to left maxillary sinus with second premolar bud being pushed into sinus

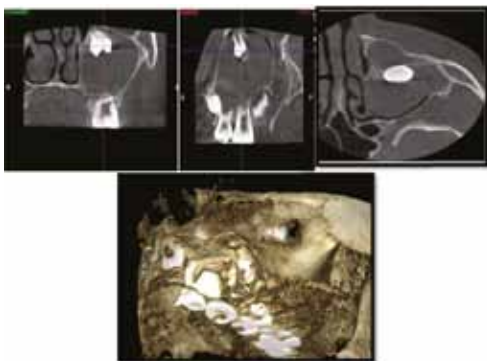


Fig. 4 CBCT images



Fig. 5 FNAC aspiration

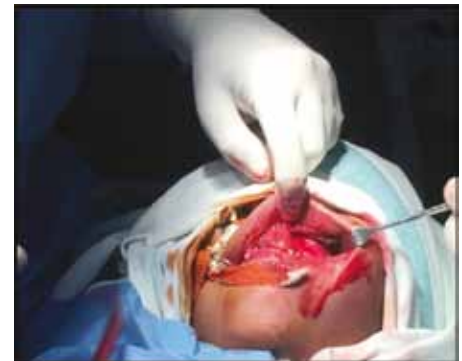

Fig. 6 Mucoperiosteal flap elevation following GA

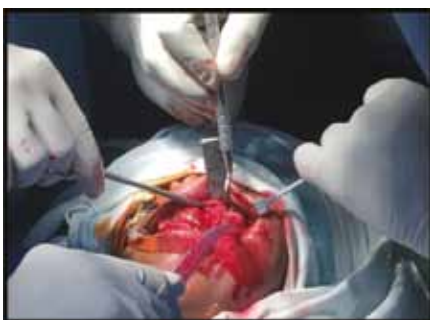

Fig. 7 Bone removal and cyst enucleation

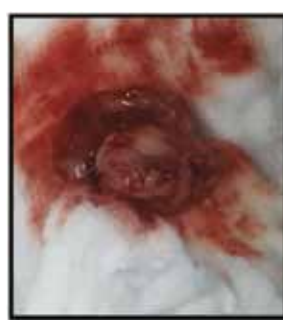

Fig. 8 Enucleated cyst along with extracted premolar tooth bud

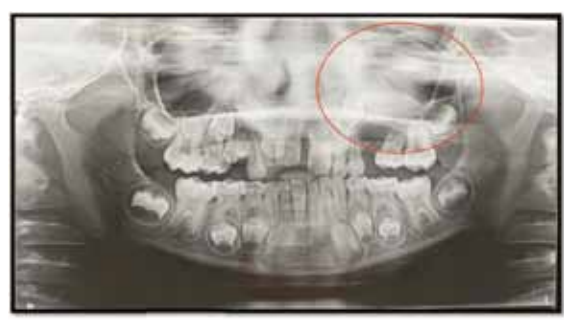

Fig. 9 Post operative Orthopantomogram after 3months



Dentigerous cysts are mostly associated with the crowns of unerupted tooth and may displace the teeth into ectopic positions such as the maxillary sinus. In this case a dentigerous cyst involving 2nd premolar was pushed inside left maxillary antrum.<sup>8</sup>

The treatment of dentigerous teeth is based on the age, size, location, and stage of root development, angulations and location of involved tooth and relation of the lesion to the adjacent tooth and vital structures. Although in young patients marsupialisation and decompression are preferred over enucleation, in large lesions with impacted tooth in unfavourable position with no chance of eruption, enucleation remains the gold standard of treatment.<sup>1</sup> In the present case, as the tooth was displaced up to the roof of the maxillary sinus far from the alveolar arch with a questionable viability, enucleation with the removal of the displaced tooth was favoured.

### ► Conclusion

Dentigerous cyst involving maxillary sinus may demand a more definitive treatment rather than a conservative one. A thorough knowledge of the lesion along with a good clinical history and proper diagnosis with conventional radiography supplemented with cone beam computed tomography, fine needle aspiration cytology can help the clinician to arrive

at the correct therapeutic choice of approach. Pedodontist should consider the long term follow-up of patients and the transitional treatment like space management to aid in the definitive treatment options like removable or fixed partial denture and dental implants in future.

### ► References

1. Duhan R, Tandon S, Vasudeva S, Sharma MIO: SR Journal of Dental and Medical Sciences (IOSR-JDMS) august 2015: 14(8), 84-88
2. Girish G, Mahesh Kumar R, Umashankar DN, Rashi Sharma, Veeresh M, Bhandari A. Dentigerous cyst in maxillary sinus: a rare occurrence. Int J Oral Maxillofac Pathol 2011;2(2):20-3.
3. Bhardwaj B, Sharma S, Chitlangia P, Agarwal P, Bhamboo A, Rastogi K. Mandibular Dentigerous Cyst in a 10-Year-Old Child. Int J Clin Pediatr Dent 2016;9(3): 281-284
4. Anderson DW, Evans D. Dentigerous cyst of mandible presenting as sepsis. Am J Emerg Med 2014;32:1561.e3-4.
5. Reyes JMV, Bermúdez JAE, Ruisánchez YEG. Dentigerous cysts: Case report. J Adv Oral Res 2016;7(1):41-45.
6. Bhardwaj B, Sharma S, Chitlangia P, Agarwal P, Bhamboo A, Rastogi K. Mandibular Dentigerous Cyst in a 10-Year-Old Child. Int J Clin Pediatr Dent 2016;9(3): 281-284.
7. Rehman F, Goyal A, Gauba K: Management of dentigerous cyst in a young child- a case report International Journal of Enhanced Research in Medicines & Dental Care, March 2015:2(3), 39-43.
8. Sogur E, Özden M, Günbay T, Tugsel Z. Cone beam computed tomography findings of ectopic tooth in the maxillary sinus associated with dentigerous cyst: A report of two cases and review of the literature. J Oral Maxillofac Radiol 2015;3:70-5.

## OBITUARY



**Dr. Joaquim Kunju**  
(1938-2017)

A man who stood tall, among us & with us. He had a long tenure in the health services and a longer one in IDA and it's a moment to genuflect and salute.

He died on Oct 29 in Calicut. He was 79 & passed away from age related illnesses. He hailed from Arthunkal, Chertala. The general feeling is that IDA coursed his veins -and his thoughts shaped our ideas. Thus, we are all left a little blanched. He pioneered changes and brought in self-belief in the association. It was from this vision that the worthy protection and security schemes evolved.

Thus, a tall oak is felled. The whole forest echoes with its fall, but a hundred acorns are sown in silence by an unnoticed breeze (Thomas Carlyle). His ideas and ideals live on and we will try to live up to them. He was from the first batch at Trivandrum passing out in '64.

His classmates recall a dashing, swashbuckling young man who was into 'co-curricular' activities, as a student. It was a time of churning and they too wondered on 'employability', (there being few openings in the government sector) back then, as we are wont to do now, for entirely different reasons.

He joined the health services, rose in its ranks and retired. He had served long stints in

Perinthalmanna and Manjeri. In IDA he was at the crease, the longest -Neither did he retire or tire. It was heartbreaking for him when the State conference he was to have presided over, in Calicut, had to be abandoned, due to political violence. He was a regular at state executive meetings but strangely, never moved to the national arena. He wasn't after the 'office', per se.

He leaves behind his wife Stella, who is afflicted by dementia. Neena, Anil, Sunil are their children.

His voice has been stilled but there were values he instilled in our working as a group. We just marked a milestone and when I look at the rear view I see a giant receding in the bright light.

May his ilk fill the ranks of IDA.

May we recall our forebears and may their ideals continue to guide specially when we hit crossroads.

A patriarch is laid to rest and we recall fondly his determination to forge a strong association. The legacy is the benevolent scheme for which he was the foremost proponent. He was also a poet, very often deftly splicing his talk with Malayalam poetry. He will be missed.

# The referral process-concerns and considerations in referring a patient to a periodontist

\* K. Harikumar, \*\*K. Nandakumar, \*\*\*Nisha K.

## ► Introduction

The practice of dentistry is agglomerated with multiple specialities that need to be resorted for various treatment needs prevailing in the patients mouth. Most of the times the art of Judiciously selecting the required speciality care for the patient is bestowed upon the general practitioners in dentistry. It is in this contest “the referral process” gains significance. Periodontists, as they are considered as the “guardians of the dentition” has a key role in maintaining the health of supporting tissues of the teeth.

Disease free periodontium is essential for the long term maintenance of healthy dentition. Prompt diagnosis and treatment of periodontal disease is the standard of good dental care. We dentists have both a moral and legal obligation to their patients to inform them when a disease is present and to explain what can be done to treat the problem.

Patients differ widely in their understanding and appreciation of speciality dental care. Some prefer all care to be provided by general practitioner; others will accept either care in the general dentists office or referral to a specialist. A third group may actively seek referral to a specialist.

In this article we make an attempt to throw light on the key aspects to be considered by a general practitioner when referring a patient to a Periodontist for

specialist care. This knowledge in the referral process will help the general practitioner, the patient and the Periodontist to interact effectively.

## When and how to refer;

Before making a reference the general practitioner should have a fair idea in the diagnosis and stage of the periodontal problem of the patient. Following this they should also know which all cases they can treat themselves and which all cases require referral to the Periodontist.

Once periodontal disease is identified, a general practitioner may have many question to be clarified. Some of them are listed below with suggested answers.

### Q. Which periodontal condition should I treat myself?

- Marginal gingivitis and early periodontitis can be treated initially by a general practitioner unless it is systemically complicated or Refractory. These states usually responds to non surgical therapy.

### Q. For what condition should I consider referring a patient to a Periodontist?

- Deep pockets (>5mm) especially on multirooted teeth, where thorough non-surgical root planning is not possible and radiographs showing advanced bone loss.

- Progressively advancing pocket depth or gingival inflammation not responding inspite of your preliminary treatment efforts.
- Requires or requests Dental implants. Here periodontist and oral surgeon have got major role.
- Requires special periodontal therapy like crown lengthening, periodontal plastic surgical procedures etc. before restorative treatment or a as part of Aesthetic periodontal treatment.
- Atypical forms of periodontitis Eg; Aggressive periodontitis (Rapidly progressing periodontitis)
- Gingival enlargements- Drug induced or idiopathic
- Patients expressing concern about a continuing periodontal problem.
- Patients expressing interest in periodontal referral.

The last two reasons may be significant from a medicolegal standpoint, even if a general dentist believes that he can deliver proper care.

### Q. At what state in the treatment plan should I make referral ?

- Refer the patient early in the treatment sequence, before restorative plan is final. A periodontist can help you to decide on the prognosis of the individual teeth, their suitability for restoration and the type of restoration that would be best.

\* Additional Professor in Periodontics, Govt Dental College, Kozhikode; \*\*Dean, Azeezia College of Dental Sciences and Research Centre, Meeyyannoor, Kollam, \*\*\*Intern, Govt Dental College, Kozhikode, Corresponding Author: Dr. K. Harikumar, Email: harisindhu@hotmail.com

► **Q. To what periodontist should I refer? Should I refer to one office or give the patient two or three names ?**

- Refer your patient to a single periodontist or periodontal group practice with which general dentist has established a working relationship. Given more than one name generates confusion in your patient. Base your selection of a Periodontist on
- whether the doctor has a treatment philosophy similar to yours.
- provides a superior level of care
- has maintained a good relation with you
- has good patient rapport, and
- is conveniently located for your patients

**Q. How should I make the referral ?What words should I use?**

- Describe and demonstrate patients condition such as pockets, mobility, bleeding with diagrams, models or best of all in the patients mouth. Explain the patient that the periodontal treatment should be done by a specialist with special care.
- Mention that the periodontist will work with you to save and retain the affected teeth as long as possible. It is best not attempt to guess which type of surgery (speciality care) is needed or which area need surgery.
- Tell your patient about the periodontist training. Mention any academic appointment the periodontist may have in the dental hospital or dental school. Reassure the patient that all necessary information of the treatment including the cost will be discussed before treatment by the periodontist.
- Whether or not the patient accept referral, be sure to make an entry in the chart including the date and referral.

**Q. Should I attempt to prepare the patient for what will happen at the Periodontist's office?**

- Only in general way. Some Periodontists will provide you with a referral slip or leaflet that tells the patient what to expect

This leaflet from your periodontist can be given to your patient for his information.

**Q. What information should I give to the periodontist?**

- Send the most recent diagnostic-quality radiograph and any earlier films that may prove useful in assessing the rate of progression of the disease.
- Tell the periodontist, either by phone, or in a note that the patient brings to the periodontal office
  - ❖ The areas in the mouth that needs special attention.
  - ❖ What periodontal or restorative treatment has been already done

- ❖ The course of the disease
- ❖ Relevant medical history
- ❖ Anticipated restorative/prosthetic therapy

► **Q. What should I expect from the periodontist?**

- You should expect open, frank and continuing communication concerning care of the patient.

The exchange should include

- ❖ Acknowledgement – Thanks for the referral
- ❖ A written report of findings, proposed treatment plan and suggestions for restorative care.
- ❖ A final report after completing active treatment.
- ❖ Notice when the patient has been referred back to your office for restorative care.
- ❖ A discussion of recall schedule and
- ❖ Additional communications verbal or written as needed.

**Q. How should maintenance care be arranged ?Should recall be alternated between my general practice office and the periodontist's?**

- This depends on your own style of practice, whether you have a dental hygienist, how severe the patient's problem was, etc.
- Even if all periodontal maintenance care is done in the Periodontist's office, the patient should return to the general practitioner atleast once a year for an examination and other necessary treatment.

**Q. Should I refer my patient who need implants to a Periodontist or oral surgeon?**

- Both groups of specialists perform the surgical phases of implant therapy. Periodontists continue to see the patients for implant maintenance care on regular basis after completion of surgery. In addition periodontists usually work closely with the general practitioner or prosthodontists to plan the periodontal implant and restorative needs of partially edentulous patient.

► **Conclusions**

Several periodontal problems are prevailing in dental patients, most of which could be treated with proper intervention by the periodontists. Referring cases to the hands of appropriate specialists will help the general practitioner and dental patients to built good relationship and will provide ample chances for healthy practice with in dental profession.

► **Reference:**

Textbook of Periodontology; Carranza; 11th edition

# Diagnose

\*Jacob John, \*\*Dhanya Prakash, \*\*\*M S Deepa, \*\*\*\*Preeja Premkumar

A sixteen year old patient complaints of painless asymptomatic swelling in the chin noticed since 3- 4 months, it was slowly increasing in size. No relevant medical or dental history. On examination diffuse swelling in the submental region, firm to hard palpable nodule about 2.5 x 2cm. it is enlarged, non tender, mobile and not fixed to the underlying tissue or to the overlying skin. Swelling does not move with deglutition. No history of dental caries or any other signs of infection in oral cavity.

Provisional diagnosis: cervical lymphadenopathy  
Differential diagnosis: Lymphoma, Tubercular Lymphadenitis  
USG scan report was enlarged submental lymph node with normal vasculature. Chest Xray and routine blood values & TFT were within normal limits and Mantoux test was negative.

Treatment done: Excision biopsy of the mass done under GA.

Histopathology report showed increase in size and number lymphoid follicles and tangible body macrophages suggesting the features of reactive lymphadenitis

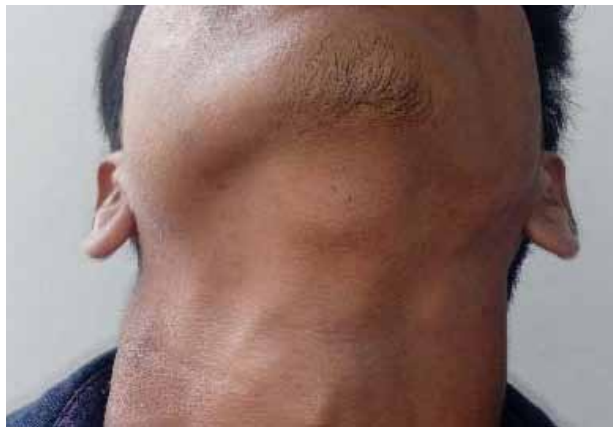
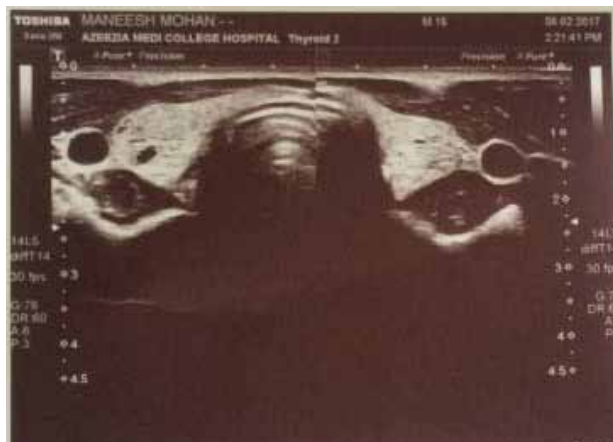
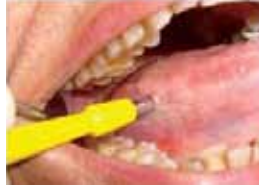Fig 1. Swelling the submental region

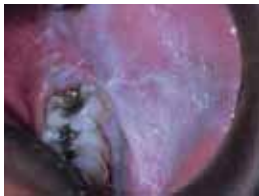\*Professor, \*\*PG Student, Dept of Oral and Maxillofacial Surgery, \*\*\* Prof & Head, Dept of Oral Medicine & Radiology, \*\*\*\*Senior Lecturer, Dept of Oral Medicine & Radiology Azeezia College of Dental Sciences & Research, Meyannor, Kollam.

\* Jayanthi, \*\* Varun B.R.

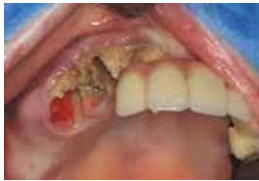1. Identify the type of procedure shown in the picture.
  - a. Incisional biopsy
  - b. Excisional biopsy
  - c. Punch biopsy
  - d. Exfoliative cytology



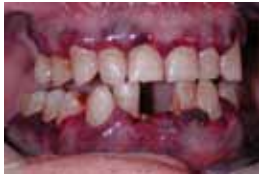2. Which of the following is not an oral potentially malignant disorder?
  - a. Oral submucous fibrosis
  - b. Leukoplakia
  - c. Tobacco pouch keratosis
  - d. Leukedema



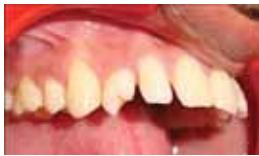3. Osteonecrosis of the jaw can occur due to administration of
  - a. Zoledronic acid
  - b. Oestrogen
  - c. Progesterone
  - d. Atorvastatin



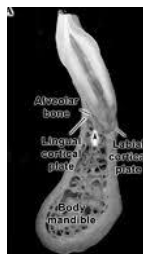
4. A 12 year old patient had episodes of haemarthrosis and gingival hemorrhage. His bleeding time and platelet count are normal. The diagnosis is
  - a. Hemophilia
  - b. Thrombocytopenia
  - c. Von Willebrand disease
  - d. Thrombocytosis



5. Transposition of teeth refers to
  - a. Bucco rotation of 1200
  - b. Partial hypodontia
  - c. Teeth erupted in unusual positions
  - d. Inverted supernumerary tooth

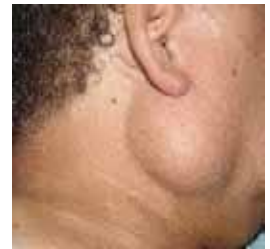

6. Which radiograph gives three dimensional view of the alveolar bony defects?
  - a. Intra oral radiograph
  - b. Digital intra oral radiograph
  - c. Orthopantomograph
  - d. Computed tomography

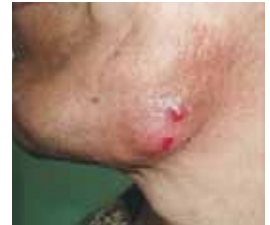

7. In patients allergic to amoxicillin, the drug given prior to dental procedures to prevent subacute bacterial endocarditis
  - a. Methicillin
  - b. Tetracycline
  - c. Pencillin G
  - d. Azithromycin

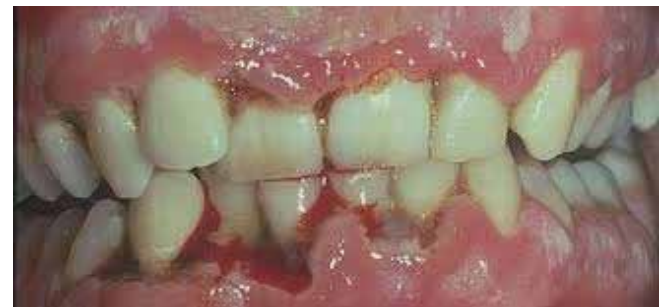8. Which of the following results from injury to auriculotemporal nerve during removal of a parotid tumor?
  - a. Facial palsy
  - b. Orolingual parasthesia
  - c. Gustatory sweating
  - d. Glossopharangeal neuralgia



9. A 40 year old patient presented with multiple extra oral sinuses with yellowish discharge and with a history of intermittent remission after antibiotic treatment two months ago. The most probable diagnosis is
  - a. Tuberculous osteomyelitis
  - b. Actinomycosis
  - c. Garre's osteomyelitis
  - d. Dissecting subperiosteal abscess



10. At 6 years age interdental papillary necrosis, ulceration, pain, bleeding and pseudomembrane formation is seen in
  - a. Herpetic gingivostomatitis
  - b. ANUG
  - c. Erythema multiforme
  - d. Streptococcal gingivostomatitis



Answers: 1. c, 2. d, 3. a, 4. a, 5. c, 6. d, 7. d, 8. c, 9. b, 10. b

\* Professor, Dept. of Oral & Maxillofacial Pathology, Azezia Dental College, Kollam; \*\*Associate Professor, Dept of Oral & Maxillofacial Pathology, PMS Dental College, Trivandrum  
E-mail: drjayanthip@gmail.com

## CDE Report



**Dr. Anil Thunoli**  
Chairman CDE

Dear Colleagues,  
With a couple of months to go we are almost in the fag end of another IDA year. As the CDE Chairman of IDA Kerala State I must admit that all branches have taken tremendous efforts in conducting CDE programs. Altogether around 190 CDE programs have been conducted so far. And I appreciate all the local branch office

bearers for their efforts.

The seventh State CDE Program was held on 27th August at Hotel Wyte Portico, Adoor. It was hosted by IDA Pathanamthitta, Kottarakkara and Thiruvalla branches. Dr Rajesh V, CDH Chairman IDA KSB Inaugurated the programme. The faculty of the CDE program was Dr Febel Huda who spoke on the topic CROWN & BRIDGES.... MILLI METERS MAKE THE DIFFERENCE...

The eighth State CDE Program was held on 22nd October at Hotel Paramount Tower, Kozhikode. Faculty Dr Prashanth Dhanapal and Dr Sunil Muhammed spoke on the topic PEDODONTIC MANAGEMENT. Dr Ramakrishnan, Former principal of Pariyaram Dental College was the chief guest of

the day. The program was hosted by IDA Malabar, Malappuram, Wayanad and Vada kara branches. It was well attended with 220 participants

The ninth State CDE program was held on 29th October at Hotel Surya Residency, Kannur. Dr M Raveendranath, CDE Chairman, IDA Head Office inaugurated the CDE programme. Dr Mohan Kumar spoke on the topic A 2 Z ABOUT COMPLETE DENTURES and it was hosted by IDA North Malabar and Telicherry branches.

The ninth State CDE will be held on 19th November at Travancore Hall Park Centre, Technopark, Thiruvananthapuram on the Topic ENHANCING ESTHETICS WITH LAMINATES AND VENEERS The program will be hosted by IDA Attingal and Trivandrum branches.

With great pride and pleasure IDA Kerala state branch will host the FDI IDA CDE program on 11th and 12th November where world renowned faculties would be elaborating on different aspects of Dento facial aesthetics. IDA President Dr Vishwas Puranik will inaugurate the function in the esteemed presence of Dr Ashok Dhoble, Hon. Gen Secretary IDA and Dr Deepak Makhijani, President elect IDA Head Office. We are expecting it to be a mega event of CDE with participation of more than 600 participants.



## CDH Report



**Dr. Rajesh V.**  
Chairman CDH

Dear colleagues,  
As we reach the fag end of this IDA year I feel really satisfied with the activities that have been organized so far under CDH wing. We could conduct all the state level CDH programmes well, a few of them being exceptionally good. It is quite heartening to see that all the local branches are competing each other conducting quality programmes. Branches are giving

great importance to CDH programmes and it is quite evident in their activity reports in KDJ.

Only two state level programmes are left to be conducted now, namely the observance of National Cancer day, to be hosted by IDA Coastal Malabar branch on 7th November and National Dentist Day on 24th December. Observance of Cancer

Day will be held at Cheemeni Open Jail, which will be presided over by the president of IDA Kerala State Dr. Sabu Kurian. Programmes like an awareness documentary video show, oral cancer awareness talk and screening camp will be held for the prisoners as part of the day observance. I have great faith in the organizing skills of the office bearers of the branch and I am sure that they will come up with an excellent programme and the make the state office proud.

IDA Kerala State is going with great guns blazing launching a number of welfare programmes for the members as well as conducting prestigious programmes like FDI CDE. Hope the state branch could conclude the activities in an excellent note.

Yours in IDA,  
Dr. Rajesh V,  
Chairman, CDH

## IDA Hope Report

**Dr. Joseph C.C.**  
Hon. Secretary



### Report 2017

As the new year 2018 dawns, Let me first greet you all with my heartiest best wishes. My three year term is coming to an end this Dec. I express my heartfelt gratitude to all the members.

As the secretary of IDA Hope I have put in every effort for betterment of the IDA hope scheme, After taking over we have completed digitization of all records and also encouraged digital payment of renewal fees.

During this term we introduced IDA HOPE MEDI insurance, a Platinum Benefit scheme and a new IDA Hope Assure for professional indemnity policy is under final consideration of managing committee. We are also planning a fire & burglary policy along with this. All details regarding IDA HOPE assure will be communicated to all members shortly.

This year our SSS founder Chairman Dr. Joaquim Kunju of Malabar Br. and Dr. Binu M P of Alapuzha Br. left us.

HOPE MEDI: 2015-16; Started IDA Hope Medi insurance. A scheme which offers Health insurance cover for Members and their family including Parents irrespective of age and medical condition. From an initial membership strength of 972 a couple of years ago, today we stand with 1066 members covering more than 4000 individuals as one big family.

2017-18: Policy No: 1009042817P110373884 renewed from 03.10.2017 to 02.10.2018.

Total Hope Medi members	- 1066
No. of Spouse	- 863
No. of Children	- 1438
No. of Parents	- 1087
Total lives covered	- 4454

in the above list 176 members with 487 dependents (totaling 663 lives) newly joined.

in the above list 62 existing members have newly added their dependents.

\*Amendments to Rules and Regulations of HOPE Schemes.\*

The EOGM of IDA HOPE held on 23rd April 2017 at Calicut made the following amendments to HOPE Schemes.

### 1. AMENDMENTS TO PROFESSIONAL PROTECTION SCHEME:

a) PROFESSIONAL INDEMNITY: The indemnity cover is increased from 2 lakhs to 4 lakhs. For claims of more than the 2 Lakhs there will be a co-sharing of 25% of the amount by the member. \*As of now Orthodontic Aligners have been excluded from this cover.\*

### 2. AMENDMENTS TO SOCIAL SECURITY SCHEME:

a) FRATERNITY BENEFIT The Fraternity benefit given to a members family in the event of a death of a member will be paid upto the age 70 and has been made dynamic, with the payment calculated as Rs.400/- X Number of Members (M) on that date when the death occurs. As of today the amount will be Rs. 400 X 2874 Members = 11.496 Lakhs. For every Rs 500 collected per death Rs.100 will be allocated to the Corpus Fund. The age at 70 is calculated as of April 1st of every year and the First installment of Survival benefit will be paid on September 30th of every year commencing from April/Sept 2018. The member is eligible for the Fraternity benefit till September 30th.

b) PLATINUM BENEFIT SCHEME At the age of 70, a HOPE member is converted to a Platinum Member who ceases to be eligible for SSS but will be paid a Survival Benefit of Rs 3 Lakhs which is to be paid in instalments of Rs 60000/- annually for 5 years. In the event of the demise of a Platinum Member during this period his family will be paid the remainder of his Survival Benefit as a lump sum amount. A Platinum Member is eligible for Hope Medi and PPS except Fraternity Death Benefit. Platinum Members only needs to pay a Hope Renewal amount of Rs.500/- year thereafter.

3. SUBSCRIPTION CHANGES: In view of the increasing number of legal cases and to facilitate the Platinum Benefit scheme with minimum effect on the Corpus Fund the following changes have been effected. Members' contribution is increased by Rs 200/- for founder Members only to make the amount uniform while retaining the existing provision of inclusion of 2 Fraternity payments for Founder Members. A contribution of Rs.800 from all members annually for facilitating payments under the Platinum Benefit Scheme by each member above the age of 30 has also been envisaged. These were the main decisions taken while a separate optional facility to provide increased indemnity cover under a group professional indemnity policy on the similar companies.

Constant updation and transformation is essential for smooth running of any scheme. Timely tweaking has ensured that all dentists in ida both young and old, has been taken into confidence and their needs have been catered to. It shall continue.

With the completion of this ida year, the hope office will also witness a change of guard. Best wishes to the new team to take ida hope to greater heights. The untiring efforts of the current team is also hereby acknowledged.



**Dr. Mercy Joji**  
Chairperson

## WDC Report



**Dr. Sapna Sreekumar**  
Secretary



The state programme of Women's Dental Council hosted by IDA Quilon branch was conducted on 14th June'17 from 9.30 am to 1.00 pm at PHC Eravipuram. The highlights of the programme were Hepatitis B vaccination for 150 -200 people , Gynec. Cancer detection by RCC TVM, Blood glucose test, Anemia test, H1 N1 & Dengue fever class by DMOH & Tele film presentations on Oral cancer, Hepatitis, H1 NI & Dengue fever. The meeting had the esteemed presence of Dr Sabu Kurian, the President of IDA Kerala State and Mrs. Dr. Sabu Kurian, Dr Biju Kumar S D -VP IDA Kerala State & Dr Mercy Joji-Chairperson WDC Kerala State. The chief guest of the programme was Dr R. Sandhya-Deputy DMO, Kollam.

Addresses by the branch president-Dr Nizamudeen M, Dr.Ciju.P.Chериан, Secretary IDA Kollam, Dr V.S Sasilekha-RMO-PHC Eravipuram followed this and the meeting concluded with a vote of thanks by Dr Deepthi Nair. Dr.Anney George was the chief coordinator. The programme was attended by more than 300 people.



## ▶ Trivandrum Branch

### 1. CDH Activities

a. Dental health awareness Programme: A Dental Awareness Program was conducted on Sept.24, 2017@10AM at the Community Hall of Puthenthope, Fishermen Believers Church Group, Mariyanadu for the local residents and church members. After the inaugural function by Sri. Ravindran, Panchayat Ward Member, a talk was conducted detailing on the importance of oral health and hygiene.

b. Dental Treatments & Dental Screening camp for the “Santhwanam Free Denture Project” of IDA Trivandrum

On 26th September 2017, the CDH wing of IDA Trivandrum Branch piloted a chain of Dental screening camps and Awareness talks at 5 Institutions of the Social Justice Department of the Govt. of Kerala at Poojapura on a single day. These were conducted in association with the Govt. Dental College Trivandrum Mobile Unit Team from 10am to 1pm. Extractions, fillings and scalings were done after required consent was obtained. Oral hygiene instructions and brochures were imparted.

c. Oral health awareness talk: A CDH Awareness discourse was conducted on the topic “Understanding Oral Health And You” for the students and parents at the National Institute of Speech and Hearing (NISH), Trivandrum by Dr. Tharun Jacob (Assoc. Prof., Dept. Of Maxillofacial Pathology,SSDC,Varkala / CDH Convener) from 11.30am to 12.30pm on 28th of September 2107.

### 2. Clinical Clubs

a. The fourth Clinical Club meeting of IDA Trivandrum was held on Tuesday, July 11th at IDA Hall, Innu apartments @8pm. Topic: “Young Permanent teeth-Paradigms to Preservation” by Dr. Sheen Ann Alex M.D.S The meeting was followed by dinner. 28 members attended the meeting.

b. The fifth Clinical Club meeting of IDA Trivandrum was held on Tuesday, August 8th @IDA Hall, Innu apartments @8pm.

Topic: “Clinical flaws in FPD” by Dr. Afsal M.D.S

The meeting was followed by dinner. 30 members attended the meeting.

c. The sixth Clinical Club meeting of IDA Trivandrum was held on Tuesday, September 12th @Mini Hall, Sri Mulam Club @8pm.

Topic: “Demystifying an enigma-Temporo Mandibular disorders” by Dr. T. Mohan Kumar M.D.S

The meeting was followed by dinner. 40 members attended the meeting.

### 3. CDE Programmes

The 5th CDE Programme of IDA Trivandrum branch “ALL 4 AESTHETICS” was held on Sunday, July 23rd @Hotel SP Grand Days-Trivandrum by Dr. Santhosh Ravindran from 9am-5pm.

Topics: \*Fixed tooth replacement in 30 minutes

\*Eliminating errors for a successful practise in aesthetic dentistry

\*Post endodontic restorations. KDC allotted 6 points for this programme and

61 members attended the programme.

### 4. Executive Committee Meetings

a. The fifth Executive committee meeting of IDA Trivandrum branch was held on July 25th in IDA Hall, Innu apartments @8pm. 19 members attended the meeting.

b. The sixth Executive committee meeting of IDA Trivandrum branch was held on August 10th in Hotel Residency Tower, Trivandrum @8pm.

29 members attended the meeting which was followed by dinner and release of our Journal & the brochure for the family meet of IDA Trivandrum branch “Aakosham 2017”.

c. The seventh Executive committee meeting of IDA Trivandrum branch was held on September 20th in IDA Hall, Innu apartments @8pm. 20 members attended the meeting.

### 5. Family meet-“AAKOSHAM 2017”

The family meet “AAKOSHAM 2017” of IDA Trivandrum was held on Saturday, September 2nd at Golf Club, Kowdiar, Trivandrum from 6pm-10pm. Nearly 200 members including family attended the programme.

### 6. Workshop on skincare organised by the Women’s Wing of IDA Trivandrum branch

An exclusive programme for the lady members of IDA Trivandrum was organised by the Women’s wing of IDA Trivandrum on Sunday, August 27th from 4pm-5.30pm @ IDA Hall, Innu apartments.

Topic: “Recent trends in skin and hair treatments”

By Dr. Asha Biju M.D (Cosmetologist)

The programme was followed by high tea. 32 members attended the programme.

### 7. IDA TRIVANDRUM JOURNAL

The Journal of IDA Trivandrum was released by IDA Kerala State Secretary, Dr. Suresh Kumar on August 10th in our Executive committee meeting held in Hotel Residency Tower.



## ▶ Kasargod Branch

1. Executive committee meeting was held on 28th April 2017, at IMA hall Kasargod. Issues and programmes to be conducted in the year were discussed. And also Advertisements by a Non IDA Member.

2. State CDE on Fixed Prosthodontics Was attended by 20 Kasargod Branch members conducted in Raj Residency Kanhagad.

3. 3rd CDE programme was conducted on 7th May on the topic “Layers of Beautification” by Dr Ratan Salecha. Total of 40 Members Participated in the programme.

4. August 1st –Oral Hygiene day was celebrated in the branch.

5. CDE programme on “Minor Oral Surgical Procedures “ was conducted on 8th September in Cosmos Hall Kasargod. 20 members participated in the programme.

6. CDH programme was conducted for mentally and physically challenged children in BUD s School, Perla, Kasargod. Video presentation of the use of powered tooth brush was done. 30 special children were given dental hygiene kit which included powered tooth brush, paste and mouthwash.





## Wayanad Branch

### CDH ACTIVITIES:

**FREE DENTURE DISTRIBUTION:** "Snehasparsham": As part of social commitment IDA Wayanad Branch organized a programme called Snehasparsham. Through this programme we decided to distribute 80 free dentures to the poor and needy patients. Three camps were organized in different places (Kalpetta, Bathery, Mananthawady) in Wayanad to select the needy patients. These patients were sent to our members clinic and the dentures were fabricated. The estimated amount for this project was 8 lakhs of rupees. The free denture distribution programme of IDA Wayanad was conducted on 6th August 2017 at Hotel Wynd Valley Resort, Kalpetta. Shri. Suhas IAS, Wayanad District Collector was our chief guest for this function.

**ONAM CELEBRATION:** IDA Wayanad Onam Celebration, cultural fest and family get-together was conducted on 17th September 2017 at Hotel Mount Avenue, Ambalavayal. There were musical programmes, dance programmes and fulfilled games and competitions followed by "Onasadhya" were organized.

**FAMILY TOUR:** This year's our 2nd family tour destination was to the ANDAMAN and NICOBAR Islands. We visited the Cellular jail, Ross Island, Museum & Havelock Island.

### CDE PROGRAMMES

**5th CDE PROGRAMME:** The 5th CDE programme of IDA Wayanad

was conducted on 9th July 2017 at Hotel Wynd Valley Resort, Kalpetta by Dr. S Radhakrishnan, Dept of Paediatric Dentistry, Govt Dental College, Thrissur.

**6th CDE PROGRAMME:** The 6th CDE programme of IDA Wayanad was conducted on 9th July 2017 at Hotel Wynd Valley Resort, Kalpetta by Dr. Ashith M V, Dept of Orthodontics, Manipal College of Dental sciences, Mangalore.

**7th CDE PROGRAMME:** The 7th CDE programme of IDA Wayanad was conducted on 6th August 2017 at Hotel Wynd Valley Resort, Kalpetta by Dr. S Jithendranath.

**8th CDE PROGRAMME: STATE CDE PROGRAMME:** The 8th CDE programme of IDA Wayanad was conducted as State CDE Programme on 22nd October 2017 at Hotel Paramount Tower, Calicut, Hosted by Malabar, Wayanad, Malappuram & Vadakara, by Dr. Prasanth Dhanapal, Prof, Dept of Cons & Endodontics, Anoor. Dental College and Dr Sunil Mohammed, MDS, Prof. Dept of Pedodontics, Educare Malappuram.

**SEVENTH EXECUTIVE COMMITTEE MEETING:** The seventh EC meeting was on 16th August 2017 at Hotel Maanasa Saras, Mananthavady.

**EIGHTH EXECUTIVE COMMITTEE MEETING:** The eighth EC meeting was on 13th September 2017 at Hotel Rest Inn, Kenichira.



## Malappuram Branch

IDA MALAPPURAM BRANCH conducted 3 CDE programmes

1. BASIC LIFE SUPPORT on 9th July 2017 at aster MIMS Kottakkal. 32 members attended the cde and hands on

2. The cde and hands on workshop a-z of endodontics by dr Anoop Samuel at Surya regency malappuram on 20th August 2017

3. The CDE TIPS AND TRICKS TO ACHIEVE HIGH QUALITY DENTAL PROSTHESIS By Mr Tarek Frank Feissali on 24 august 2017 at hotel Samman Tirur

### STATE ORAL HYGIENE DAY CELEBRATION

IDA MALAPPURAM in association with IDA KODUNGALLOR celebrated state oral hygiene day on 1st August 2017 at Malabar dental college Edappal on July 31 conducted various competitions for school children and for dental college students at Malabar dental college. On 1st August oral hygiene awareness rally was flag off by the IDA KSB state president Dr Sabu Kurian the rally started from the college and participants also went to Edappal town to spread the message of oral hygiene day. The official inauguration of oral hygiene day was conducted at old age home Tavanoor. The MLA Mr Abid Hussain Thangal was the chief guest for the function. Oral hygiene day pamphlets were released by IDA KSB state branch vice president Dr. Subash Madhavan. Oral hygiene day message was given by IDA KSB state convener for CDH Dr Rajesh. After the official inauguration Dr Civy V Pulayath took oral hygiene awareness class for the participants the programme was well attended by the members

IDA MALAPPURAM BRANCH CDH WING conducted a diagnosis

and treatment camp on 1 st August 2017 for the inmates old age home Tavanoor in association with Malabar Dental College, Edappal. 40 patients were examined and given medicines and treatments. IDA MALAPPURAM Branch conducted a screening camp on 13 -8-2017 in association with Santhigram residents association Manjeri

**MIDA ONAM BAKRID FEST 2017:** IDA MALAPPURAM Branch conducted Onam Bakrid fest Kalikkalam and family get together at Cosmo club Manjeri on 17 September 2017. The past president Dr Suresh PN inaugurated the fest. Various games for childrens and family are the highlights of the day. Shuttle badminton and carams also conducted for members.

**ZONAL LEVEL CRICKET:** IDA MALAPPURAM BRANCH participated in the zonal level cricket match held at Kannur on August 27. WON the trophy by beating the existing champions Malabar branch under the captiancy of Dr Ragesh Ganghadharan.



## Vatakara Branch

Installation of office bearers of year 2017 was done on 15th January. Mr. M.K. Pushkaran I.P.S. Superintendent of Police (Rural) inaugurated the function. IDA President Dr. Mohammed Sameer P.T, Hon. Secretary Dr. Sureshkumar G., Dr. Thomas. K.C (IPP, IDA KSB), Dr. Sanal O.V (Past Sec. IDA KSB) Spoke on the occasion.

A week longer Anti cancer awareness programmes were conducted at different Govt. Hospitals. Inauguration was done at District Govt. Hospital Vatakara on 4th Feb 2017 by Sri. C.K Nanu M.L.A, Nearly 5000 anti cancer awareness leaflets were distributed through clinics run by IDA members, Medical shops, PHC's, Labs and clinics. Dentist day was celebrated on 5/3/2017 by conducting Dental screening camp at Samskrithi Public School, Purameri. Awareness class on Cervix & breast cancer by Dr. Jeena Baburaj, Gynaecologist at Lions club by WDC. Family meet at IMA Hall Vatakara, around 60 members participated. Two Dental check up camps were conducted on 21/05/2017 at Ayancheri and

Thiruvallur in association with Lions club and Palliative clinic respectively. No tobacco day was conducted on 31/05/2017 at New Bus stand Vatakara Sri. P. Chandran DYSP Vatakara (Narcotics) inaugurated. Awareness posters were placed and nearly 2000 leaflets distributed. Pledge was taken by IDA members and public. Grand Iftar meet was conducted on 16th June at Govt. Guest house Nadapuram. 90 members participated. Executive meeting was held on 18-7-2017, 14-8-2017 and 15-9-2017. Team of WDC visited Ashanikethan and handed over the amount collected for ONAM Celebration from members. Much awaited IDA Hall inauguration was done by Sri. T.P. Ramakrishnan (Hon. Minister, Excise and Labour), on 10-9-2017. Dr. Saji Paul (President) presided Dr. Mohammed Sameer P.T. (IPP), Dr. Subhash Madhavan (Vice- President KSB), Dr. Suresh Kumar. G (Hon. Secretary IDA KSB) spoke on the occasion. Onasadya and Various Cultural Programmes followed.



## Thiruvalla Branch

**CDH PROGRAMME:** This year we were able to conduct mega Cdh program | SPARSHAM on 17 september. It is a dialysis project. We plan to do 365 dialysis for the poor and needy that is one dialysis per day. The project was inaugurated by Veena George M.L.A. It was very well attended. The first installment was handed over to Dr. Prathiba from Taluk hospital Kozhencherry. The program was very well attended. Dr Saji Kurian, Mrs Veena George, Dr Samuel. K. Ninan, Dr K.N. Thomas, Dr Maya Mathai and Dr. Simon George spoke on the occasion.

**CDE PROGRAMME:** We conducted a State Cde along with Pathanamthitta and Kottarakara branch on August 27. Topic was Millimeters make the difference, Faculty Dr. Fabel Huda. More than 110 members attended the Cde.

**ONAM CELEBRATIONS:** This years Onam Celebration was held on September 17 at Tharangam mission action Centre Arattupuzha. There were a lot of activities on that day. Magic show, Onam Games, Saree dressing by men, and vegetable cutting by women. It was followed by a sumptuous dinner. 75 members attended the function.



## Pathanamthitta Branch

1. The 4th Executive committee meeting on 24th June 2017 held at Hotel Hills park, Kumbazha.
2. The 5th executive committee meeting on 6th October 2017 held at Hotel Hills Park, Kumbazha.

Report of Oral Hygiene day Observance 2017

Observance program was held from 1:30 p.m. onwards at CMS LP School Mallassery on 1st August. President Dr Hema Rajesh presided over the function and Mrs Jessy Thomas. Headmistress of the school welcomed the gathering. Dr Johnny Kutty Jacob inaugurated the meeting. Dr Shann Thomas led the oral

hygiene awareness class. Oral health kits were distributed among the students and teachers. Incoming president Dr Sujith, Dr Dhanya and Secretary Dr Ralu Varghese attended the meeting. The CDH representative Dr Rincy Eugene expressed vote of thanks.

**Onam Celebration:** Onam celebration took place at green palace Alappuzha. Almost 60 members took part in the celebration. The celebration got over by 5pm. The programme was much appreciated by our members

**Family tour:** We conducted an international tour to Thailand. Almost 45 families took part in the tour. It was a 4 day tour. All the credit goes to our tour coordinator Dr Giboy Kurien for conducting such a wonderful memorable tour.



## ► Coastal Malabar Branch

**Cde programmes:** 1. 6Th cde programme: conducted the 6th cde programme on 9th July 2017 at Hotel KBC green park on the topic general practice in 3d perspective from 9.30 Am to 4.00 Pm. The faculty was dr. Shiva Prasad. S, Prof, dept of Oral Medicine & Radiology, Bapuji Dental College.

2. 7th cde programme: conducted the 7th cde programme on 23rd august 2017 at hotel Vyshak international on the topic catch them young and watch them grow – a talk on Interceptive and Myofunctional appliances from 7.30 Pm to 10.00 Pm. The faculty was dr. Joby peter, prof& hod, Dept or Pedodontics, Malabar Dental College, malappuram.

3. 8th cde programme: conducted the 8th cde programme on 25th september 2017 at hotel J.K International, cheruvathur on the topic perio esthetics from 7.30 Pm to 10.00 Pm. The faculty were dr. Dr anil melath, principal, prof& hod, dept of Periodontics, Mahe institute of dental sciences and Dr Subair, reader, dept of Periodontics, Mahe institute of dental sciences.

4. 9th cde programme: conducted the 9th cde programme on 22nd october 2017 at hotel juju international, Payyannur on the topic oral surgery for general practitioners from 9.30 Am to 4.00 pm. The faculty was Dr Saju. N.S, mds oral and maxillofacial surgeon, general hospital, Thalassery.

**Executive committee meeting:** fifth executive committee meeting was held on 8th september 2017 friday at hotel vyshak international, payyannur.

**Release of 3rd issue of journal 'mirror':** Released the third quarterly issue of journal 'mirror' on 23rd august 2017 at hotel vyshak international, payyannur. By ida national vice president dr Santhosh Sreedhar by handing over first copy to dr. Joby peter, prof& hod, dept or pedodontics, malabar dental college, malappuram.

**IDA Kerala state cricket tournament:** Our branch team participated in the ida north zone cricket tournament held at kap battalion grounds, mangattuparamba on 27th august 2017 sunday and lost the match in the quarter finals against ida enrad branch. Captain of team was dr a v sreekumar.

**CDH activities:** 1. 14th CDH activity: conducted a dental check up camp

and awareness class on 16th july 2017 at kanhangad in association with hindu economic forum.

2. 15th cdh activity: oral hygiene day celebrations 2017

Celebrated oral hygiene day 2017 at p.E.S vidyalaya, payyannur and buds special school, madayi on 1st august 2017. Various competitions for students included best smile, healthy teeth, elocution competition, essay writing competition and was followed by dental health check up for school children and awareness class for parents. All students were given free oral hygiene kit consisting of tooth paste, tooth brush and mouth wash.

3. 16th cdh activity: conducted a free check up and treatment camp on 24th september 2017 for the inmates of akhasaparavakkal old age home at kanhangad.

4. 17th cdh activity: conducted a dental check up camp and awareness class on 27th september 2017 wednesday at st marys school, punchakkad, payyanur in association with rotary club of payyannur midtown.

**Onam celebration:** Our branch conducted a family gettogether and onam celebrations on 17th september 2017 sunday at oyster opera, paddanne. 63 Members attended the program with their families. The programme was filled with lots of fun and entertainment. The entertainments included a house boat ride, yakaying, music with a delicious lunch.

**Women's wing activities:** 1. Friendship day celebrations: women's wing celebrated the friendship day on 6th august 2017 sunday at kbc green park hotel payyannur. Chairperson dr ria abraham inaugurated the function and around 30 women members of our branch with children participated in the friendship day zumba fitness party.

2. Ladies trip 2017: conducted one day ladies trip on 15th october 2017 sunday to malabar ocean spa and resorts, nileshtar. Around 35 women members of our branch with children participated in the trip lead by chairperson dr ria abraham.

**Achievements:** bagged the 2nd best prize from the indian society of periodontology for the oral hygiene day celebrations conducted by our branch at the national level.



## ► Tellicherry Branch

**Executive committee meeting:** On 7th july 2017, 4th executive committee meeting was held at hotel olive garden at 8:00pm, 20members attended.

**General body meeting & eid celebration:** On 28th july 2017 conducted a family get together and EID celebration at lions hall Thalassery. A class was conducted on "An option for tax free returns for your hand earned money" at 8:00pm by LIC MUTUAL FUNDS.

**IDA ZONE CRICKET MATCH:** Our branch participated in IDA zonal Cricket match on 13th august 2017 at Mangat parambu K.A.P stadium. Members who participated were Dr. Arshad Ali, Dr. Mithun Vinod, Dr. Pramith, Dr. Libin Chandra, Dr. Mansoor, Dr. Nabeel, Dr. Kabeer Dr. Arun, Dr. Jibin, Dr. Thomas Kutty And Dr. Abhinav Dr Purushothaman Was The Team Official.

**CDH:** IDA Dental Camp Was Conducted By Dr Sunith On 10th August 2017 At Anandoth L.P School, Kodyyeri. Examined around 75 patients.

On 24th August 2017 conducted a screening camp by Dr. Arun at Chalil School and examined 85 patients.

**ONAM CELEBRATION:** Onam Celebration And Family Get Together: On 17th Sept 2017 Conducted Onam Celebration And Family Get Together At Anchor Resort. Around 80 members participated in the celebration. Variety of entertainment programmes were organized along with Maveli. Variety programme includes floral arrangement-onapookalm by Dr. Bulna, Thiruvathira dance by ida womans wing members, Dr. Prathima Sumal, Dr. Lathajohny Dr. Namitha Vijesh, Dr.Sayana, Dr. Prayaga,Dr. Sharika, Dr. Anusree And Nikitha were participated and fun games, along with grand onam sadhya were organized.

**CDE PROGRAMME:** 3RD CDE programme was organized at Hotel pearlview regency on 11th oct. with Eminent faculty Dr.FAIZAL CP on the topic 'ENHANCE YOUR PEDODONTIC PRACTICE'. It was attended by 20 members.



## ▶ Attingal Branch

### JULY

IDA Attingal branch conducted a CDE programme on July 9th. Topic was "LAYERS OF BEAUTIFICATION" by Dr Ratan Salecha at Travancore hall, Technopark.

One of our branch member Dr Gijo Eldred is bedridden, we collected Rs 2,00,000/- from our branch members and handed over the money to him.

### AUGUST

First General Body meeting was conducted on August 6th at Lions Club Hall. 39 members attended. On the same day, after the GB a CDE programme was conducted. Topic "IDEAL RADIOGRAPHS In Dental Office". The faculty for the programme was our branch member Dr Rahul R.

Womens wing of IDA Attingal branch conducted a free dental camp for cancer patients in connection with ORAL HYGIENE DAY at Palode.

Free samples of medicines distributed.

### SEPTEMBER

Onam celebration of our branch was arranged at "Snehatheeram", Mitirmala near Karette on 17th September. Snehatheeram is an orphanage for mentally

challenged women, run by a unit of 'Sisters of Mercy'. 83 inmates are there, of different ages. Different types of games, dance, orchestra are arranged. Inmates of "Snehatheeram" actively participated in each programme and enjoyed. We have had our lunch along with the inmates. We provided dresses, groceries, books and eatables to them. On 24th September another CDE programme along with handson was conducted. Topic "Workshop On Advanced Endodontics" by Dr Digesh Burfiwala at Hotel Dobloon, Kallambalam. No additional charge was collected from participants for handson.

One executive committee meeting was conducted in August.



## ▶ Central Kerala Kottayam Branch

Executive committee meetings: Two executive committee meeting was held during this period. Sixth executive meeting at River valley club, Pala on 14/07/2017 and Seventh executive meeting at Garden manor club, Mundakayam on 9/9/2017.

CDE Programmes: Three CDE were conducted.

Second branch CDE was held on July 2nd by Dr. Eapen Thomas on Sterilization and disinfections at Thrishangu haven, kuttikanam. Third branch CDE was held on July 9th by R.S Mohan on Direct and indirect veneers on anterior tooth with hands-on at hotel Arcadia, Kottayam. Fourth branch CDE was held on September 17th by Dr. Byju Paul Kurian on All Ceramic Restorations at Hotel Arcadia Kottayam.

### CDH Programmes:

IDA CKK has conducted a Dental Treatment camp associating with Rotary club of Kanjirappally and Govt. Dental College, Kottayam at Nalla Samarayan Ashramom, Thampalakad, Kanjirappally on 14th July 2017 which is an institution for mentally ill Female orphans.

Another Dental Treatment Camp by IDA CKK had been conducted on 28th July, in association with Rotary club of Kanjirappally and Govt. Dental College, Kottayam at Penuel-Emmanuel Ashramom, Thampalakad, Kanjirappally, which is an institution for mentally ill male orphans.

IDA CKK celebrated Oral Hygiene Day on August 1st at Sathirithya Special school, Villooni, Kottayam... Oral Screening was done, Oral Hygiene kits were distributed.. Children exhibited their talents by singing solo and groups. 4 Dentists participated... Camp started at 1 pm and got finished at 3pm.. About 40 children got benefitted from this camp.

IDA CKK has conducted an oral awareness and screening camp on Aug 7th at PGM college of management... awareness talks were conducted in the beginning followed by Dental screening

Another Oral Awareness and Screening camp was conducted by IDA CKK on October 8th at Mar Baselious Orthodox Church, Noorumav. 4 dentists participated... Dental hygiene kits were distributed... camp started at 10.30am

Family gettogether: Two family gettogether was conducted during the month of july and september. Monsoon gettogether was at Thrishangu Havens, kuttikanam on July 1st and 2nd. Onam celebrations was held at Mango Medows, Kaduthuruthy on September 24th.

SPORTS: IDA- CKK bagged the central zone cricket championship held on August 27th at Thripunithara cricket club for the third consecutive year under the captaincy of Dr. Robin Theruvil. Dr. Anoop Mathew, Dr. Bibins Mathew and Dr. Faiz Ansari were awarded man of the match in respective games.

IDA-CKK also won the IDA keral state cricket championship held on October 15th at Calicut under the captaincy of Dr. Robin theruvil. Dr. Robin Theruvil and Dr. Aji K Mathew were awarded Man of the match in respective match and Dr. Bibins Mathew was awarded the Man of the series.

**Free Dental Clinic:** Dr. Raju Mathew (IDA CKK member), in association with IDA & Rotary club of koothatukulam has sponsored a dental chair unit to Pratheeksha bhavan, an institution for mentally challenged people... all basic dental treatments will be carried out for the inmates on a regular basis.. Any willing dentist can also go and do the service..

IDA-CKK conducted a treatment camp at Snehatheeram, psycho-social rehilitation centre in Koothrapally near Karukachal. 28 inmates were given free treatments with the help of mobile dental unit from GDC kottayam.

IDA CKK conducted Oral hygiene awareness class for the students and teachers of Navodya Vidyalaya, Vadavathoor, Kottayam and oral screening was done for students. More than 500 students were benefitted.

**CDE Programme:** Fifth branch CDE was held on October 29th by Ajay Kakkur on Laser in Dentistry a practical approach with hands-on at hotel Arcadia, kottayam. 63 participants attended the CDE programme with hands-on.

SPADIKAM State sports tournament;

21 members from IDA- CKK participated in the state sports events held at irringalakuda on 29th October. We came 2nd in overall points.



## ► Kodungallur Branch

Hosted the IDA State sports meet SPADIKAM 2 on 29/10/2017 at Christ Vidyanikethan, Irinjalkua. A total of 14 branches of IDA took part. IDA Malabar won the overall championship, followed by IDA Central Kerala and

IDA Kodungallur. President elect Dr. Siju Paulose and Vice Present Dr. Subash Madavan also graced the event.



## ► Malabar Branch

1. SIXTH CDE OF IDA MALABAR BRANCH “CERAMEASE” WITH LIVE DEMO: The sixth CDE of IDA Malabar branch was held on 30/07/2017 at Hotel Maharani Kozhikode. The topic of CDE was Ceramease. The Faculty was Dr. Burzin Khan MDS.

2. SEVENTH CDE - TWO SHORT LECTURES: The Seventh CDE of IDA Malabar branch was held on 13/08/2017 at Hotel Maharani Kozhikode with two lectures. The topic of CDE was Oral Surgery for General Practitioners & Medical Emergencies in Dental Clinics. The Faculty was Prof.(Dr.)Ravindran Nair KS. MDS and Dr. Saju N.S. MDS.

3. EIGHTH CDE OF IDA MALABAR ON “LASERS IN DENTISTRY”: The Eighth CDE of IDA Malabar branch was conducted in association with Department of Periodontics KMCT Dental College Calicut and was held on 27/08/2017 at KMCT Dental College Manassery, Kozhikode. The topic of CDE was Laser in Dentistry. The Faculty was Dr. M.S. Saravanakumar MDS.

4. NINTH CDE OF IDA MALABAR “NEXT GEN-ENDODONTICS): The Ninth CDE of IDA Malabar branch was held on 24/09/2017 at Hotel Maharani Kozhikode. The topic of CDE was Next Gen-Endodontics, How long will your RCT Last?? A programme on Rotary Endodontics. The Faculty was Dr. M. Abarajithan Mohan.

5. CDH NO.12- ORAL HYGIENE DAY OBSERVATION: IDA Malabar Branch in association with KMCT Dental College observed World Oral Hygiene day on August 1st 2017 at Pratheeksha Special School Mukam Kozhikode. Around 100 students along with their parents participated the camp.

6. FOLLOW UP VISIT TO HOME OF LOVE: IDA Malabar branch members visited adopted old age home HOME OF LOVE at Kottooly Kozhikode and done various dental procedures including dental extractions and complete dentures to the needy inmates.

7. CDH NO.13 – DENTAL CHECKUP CAMP & AWARENESS CLASS AT BALUSSERY: IDA Malabar conducted Dental Checkup Camp and Awareness class at Balussery. Around 120 patients were examined. On behalf IDA Malabar branch Dr. Riyas M, Dr. Jaffer, Dr. Ashila, Dr. Prajul and Dr. Prajith participated and Dr. Riyas took the awareness class.

### 8. INDEPENDENCE DAY CELEBRATIONS

FLAG HOISTING: 70th Independence day was celebrated in IDA hall. Flag hoisting was done by Dr. Binu Purushothaman, President IDA Malabar branch at 8.00 am followed by the National Anthem. Many senior and junior members witnessed the ceremony. Sweets and Payasam were distributed.

9. A TALK ON ANYTHING AND EVERYTHING ABOUT GST: A talk was conducted on anything and everything by Adv. Sindhu Mangat. All the doubts regarding GST were cleared by the Speaker. Meeting adjourned for Dinner.

9. BRANCH LEVEL SHUTTLE TOURNAMENT: IDA Malabar branch shuttle Tournament was conducted on 09/07/15 at Indoor stadium Kozhikode. The Tournament were categorized into four as Singles, Doubles, Veterans and Ladies. 30 members participated. Dr. Kunhamma Thomas Retd Principal KMCT Dental College and Dr. Rajesh Manuel distributed trophies for winners.

10. PARTICIPATION IN ZONAL CRICKET TOURNAMENT: IDA Malabar branch participated in the Zonal Cricket tournament held on 27/08/2017 at KAP ground Kannur and qualified into the state cricket final to be held on Calicut.

11. SARGAM 2017 – ONAM CELEBRATIONS, CULTURAL & FAMILY FEST: IDA Malabar branch conducted SARGAM 2017 Cultural & Family Fest on 10/09/2017 at Hotel Paramount Tower. The programme started at 5.30 PM with Varna Pookallam. Many colourful cultural programmes including dances, songs, and skit by our members were performed on stage. Kids participated in various fun games and win many prizes. A grand Sadhya was also arranged. 120 members including many Senior and Junior Members participated.

14. INAUGURATION OF MDS NEET ENTRANCE COACHING CENTRE: IDA Malabar branch in association with Focus – The Future dentistry started a unique classroom MDS coaching facility at IDA hall Kozhikode from 2nd July. The first session of classes started with 40 participants. Classes will be conducted on Saturdays and Sundays.

15. FIRST COC MEETING OF 51ST KSDC: First COC meeting of 51st KSDC was held on July 2nd 2017, 07.00 PM at IDA Hall Ashokapuram Kozhikode. Dr. Mohammed Sameer Chairman 51st KSDC and Dr. Suresh Kumar Hon Secretary IDA Kerala State inaugurated the function by lightning the lamp.

16. THIRD EXECUTIVE MEETING OF IDA MALABAR: Third executive meeting of IDA Malabar was held on 08/08/17 7.30pm at Marina Residency Kozhikode. Report of activities, forthcoming programmes and new projects were discussed. 32 members participated.

17. RELEASE OF SECOND EDITION OF MALABAR DENTIST: Second Edition of Malabar Dentist, Journal of IDA Malabar was released by Prof.(Dr.) Ravindran Nair KS on 13/08/17 at Hotel Maharani Kozhikode in the presence of Dr. Binu Purushothaman President and Dr. Sameera G Nath Editor IDA Malabar.



## ▶ Alappuzha Branch

The third quarter of IDA Alappuzha began with an executive meeting on 17.07.2017 at Ramavarma club Alappuzha. The IVth State Executive meeting at IMA House Kaloor was attended by Dr Mili James (Hon Sec) and Dr (Capt) Sivaprasad.

The Fourth one day CDE Program of IDA Alappuzha was conducted on 06.08.2017 at Hotel Royal Park on "Medical Emergencies in Dental Practice" with Dr Eapen Thomas, Prof& HOD, Dept of OMFS, Pushpshgiri College of Dental Sciences as faculty.

The South Zone cricket tournament was hosted by IDA Alappuzha on 13.08.2017 at T D Medical College ground, Alappuzha IDA Karunagappally and IDA Mavelikkara participated in the tournament.

There was a treatment camp organized by IDA Alappuzha at Ambedker School For Scheduled Tribe, Punnapra was conducted on 15.08.2017 in Association with the lions club of Punnapra. Independence day was celebrated and there were 200 students screened in the camp and 95 students were given treatments too. The doctors who participated in the camp included DR Rupesh, Dr Mili James, Dr Usha B Nair, Dr Renju, Dr Sarath Kumar R, Dr Sarath S K, Dr Sarin, Dr Alex & Dr Divya.

The Vth executive meeting of IDA Alappuzha was conducted 31.08.2017 at Ramavarma Club, Alappuzha.

5th State executive meeting at Calicut

The 5th state executive meeting was attended by Dr Rupesh (President), Dr Prasanth Cherian, Dr Aji Sarasan (President Elect)

Sixth Executive Meeting of IDA Alappuzha was conducted at the residence of Dr Rupesh, President IDA Alappuzha.



## ▶ Palakkad Branch

### CDH ACTIVITIES:

- ◆ Oral Hygiene Day -1/8/2017- demonstrated correct brushing techniques to school students in school assembly.
- ◆ IDA palakkad branch joined hands with Junior Chamber International and conducted dental check up camp at Lions School on 10/09/2017.
- ◆ ORAL CANCER AWARENESS DAY - 21/09/2017: IDA Palakkad conducted science quiz competition, Extempore and science exhibition competition



### CDE ACTIVITIES:

- ◆ IDA palakkad conducted branch CDE on pedodontics at Sayoojyam residency on 23/07/2017 Dr Sunil Mohamad M.D.S
- ◆ Branch level CDE program on Periodontics at Sayoojyam residency on 27/08/2017 Dr Joann Poulina George M.D.S.
- ◆ FAMILY TOUR - 29 & 30/7/2017 to Idukki
- ◆ 5th branch executive meeting was held at Sayoojyam residency on 04/08/2017
- ◆ IDA palakkad celebrated onam and eid along with our families at KPM residency on 17/09/2017.
- ◆ 6th branch executive committee meeting was held at KPM residency on 26/09/2017.



## ► Quilon Branch

3rd CDE: The third CDE programme of IDA, Quilon branch was short CDE of one hour and forty five minutes on “Practice Management & Handling of Patient” by Dr Sunil K.A. on 29th April’17 at Crowther Masonic Hall from 7.30 pm.

5TH CDH PROGRAMME: IDA Quilon organised a dental and medical camp in relation to world health day at Govt old age home Inchavilla perinad Kollam on 5th May 2017.

Dental camp and a dental awareness talk, motivational class for adolescents shelter home inmates by Mr Shaharudeen Jci India trainer

ASAP NEW BATCH INAUGURATION: The inauguration of the ASAP dental assistant course 4th batch was done on 7th May 2017 at Mangad government high school. The president chaired the function and the new branch coordinator Dr Christofer Gonsalves briefed the details.

4th State CDE programme on “Composite resin-Perfectly misunderstood: Lessons from a bad carpenter” was jointly hosted by IDA Quilon and IDA Karunagapally branches on 14th May at Hotel Sea Palace from 9.30 am to 3.30 pm. The faculty for the programme was Dr Yohan Chacko. It is to be highlighted that the state officials of IDA came up with the brilliant plan of keeping it eco-friendly by using cloth banners and eco friendly pens instead of the regular plastic.

6th CDH PROGRAMME: World No Tobacco Day Programme: The “WORLD NO TOBACCO DAY” observation programme of IDA Kerala State was conducted on 31st May 2017 as a state wide in association with Indian Railways at Kollam Railway station.” IDA state president Dr Sabu Kurien presided the function and the IDA National Hon: General secretary Dr Ashok Dhoble was the chief guest.

Fifth CDE Programme: The fifth CDE Programme of IDA Quilon branch was a “one day programme with Lecture & Demo” accredited with 6 KDC points on “Oral Surgery Simplified -A General practitioner’s perspective” by Dr Joseph Edward, HOD-OMFS, Azeezia College of Dental Sciences at Crowther Masonic Hall on 25th June’17.

The Women’s Dental Council of IDA Quilon branch conducted an awareness class with video projection on “Substance Abuse” in relevance to World No Tobacco Day for the NSS Students of TKM Arts & Science on 6th June ‘17 at TKM Arts & Science Seminar hall.

WDC STATE PROGRAMME: The state programme of Women’s Dental Council hosted by IDA Quilon branch was conducted on 14th June’17 from 9.30 am to 1.00 pm at PHC Eravipuram. The highlights of the programme were Hepatitis B vaccination for 150 -200 people, Gynec. Cancer detection by RCC TVM, Blood glucose test, Anemia test, H1 N1 & Dengue fever class by DMOH & Telefilm presentations on Oral cancer, Hepatitis, H1 NI & Dengue fever.

The meeting had the esteemed presence of Dr Sabu Kurien -the President of IDA Kerala State, Dr Biju Kumar S D -VP IDA Kerala State & Dr Merci Joji-Chairperson WDC Kerala State. The chief guest of the programme was Dr R. Sandhya-Deputy DMO, Kollam.

7th CDH programme: ORAL HYGIENE DAY-AUGUST 1ST

IDA Quilon CDH wing observed the ORAL HYGIENE Day for the students of Govt LP School Mundakkal West, Kollam. Oral hygiene awareness class, Smiling competition, Drawing competition & Dental health pack distribution done.

6th CDE Programme: Inter branch programme: of IDA Quilon branch, an “inter branch –one day programme accredited with six KDC points” had been conducted on 20th August at The Vaidhya Hotel from 9 am to 5 pm. The programme witnessed two brilliant lectures on two topics presented by two eminent faculties: “Dr PC Jacob, visiting professor VSPM Dental College, Nagpur, an expert in the field of Prosthodontics & Maxillofacial prosthetics, on Post and Core – All the way” and Dr Sandeep B Pillai, Consultant Surgical Oncologist, KIMS Cancer Centre, TVM on Oral Cancer Basics for Dentists.”

7th CDE Programme-Inter branch: The seventh CDE programme of IDA Quilon branch, an “Interbranch -One Day -Workshop on Basic life Support”, accredited by American Heart Association and with 6 KDC credit points “was held at Hotel Sea Palace on 24th September from 10 am to 6 pm.



## ► Tripunithura Branch

IDA Tripunithura conducted Awesome Auxiliaries a training programme for dental assistants, at Lovedale family club on July 16th. About 90 staffs attended the training.

On August 6th free dental check ups were done at Kanayanoor JB School. Again on October 17th free dental check ups was done at St. Little Theresa’s Girls H.S.S., Vaikom which was organized by Vaikom Town Rotary Club along with IDA Tripunithura.

On October 22nd we conducted a CDE on Medical Emergencies in Dental Clinic & the faculty was Dr. Thariq Thameem Mohammed of Sunrise Hospital. The afternoon session was about Practice Management by Dr. Binu Abraham. More than 90 dentists attended the CDE. Medical emergency kits were distributed to those who wanted.

We celebrated our Onam programme ‘Onanilavu’ at Lovedale Family

Club on September 17th. Almost 90 members along with family attended the celebration. Onasadhya was served.

IDA Tripunithura conducted the IDA State Central Zone Cricket Tournament on August 27th at Palace Oval Cricket ground.

The Women’s Wing of IDA Tripunithura conducted the following:

1. International Yoga Day on June 26th and 18 dentists attended the yoga session.
2. Celebrated Anti-plastic program along with onam celebration on September 17th.
3. Conducted free dental check up at Thuravoor on August 28th organized by Rotary Club.
4. Conducted a demo and hands on workshop on cupcakes on August 20th.