



# KDJ

Kerala Dental Journal

Vol 39 | No. 3  
July 2016

Quarterly Publication of Indian Dental Association, Kerala State Branch

- Forced eruption-a symbiotic approach
- Is genotyping the next frontier of orthodontic treatment?
- Rehabilitation of an anterior maxillary edentulous space with a delayed loaded implant using PRF for regeneration of bone
- Link between periodontitis and metabolic syndrome
- Is Azithromycin an effective adjunctive immunomodulator in periodontal therapy
- Paradigm shift in treatment of obstructive sleep apnea
- A Novel Approach in Management of Condylar Fractures
- Morphometric analysis of facial soft tissue in preschool children with flush terminal plane molar relation in Thiruvananthapuram
- Antibiotic Prophylaxis to prevent Infective Endocarditis – current dilemmas
- Current concepts in rotary endodontics and clinical use
- Access post overdenture system – an easy approach to overdentures
- Restoration of severely worn dentition – a multidisciplinary approach
- Ridge mapping – ‘a map to success’

SIS Index ID 833





**EDITOR**

**Dr. K. Nandakumar**

**ASST. EDITOR**

**Dr. R.M. Baiju**

**BUSINESS MANAGER**

**Dr. Mathew Jose**

**EDITORIAL CONSULTANTS**

**Dr. Santhosh Sreedhar**  
**Dr. K. Chandrasekharan Nair**  
**Dr. K. George Varghese**  
**Dr. Ipe Varghese**  
**Dr. Oommen Aju Jacob**  
**Dr. V.I. Paul**  
**Dr. Thomas Manjooran**  
**Dr. Sobha Kuriakose**  
**Dr. N.O. Varghese**  
**Dr. T. Sreeal**  
**Dr. Siby Xavier**

**EX-OFFICIO MEMBERS**

**Dr Mohammed Sameer P.T.**  
**Dr. Suresh Kumar G.**  
**Dr. Thomas KC**  
**Dr. Sabu Kurian**

**EDITORIAL BOARD**

**Dr. Dibyendu Mazumder**  
**Dr. Ashok Dhoble**  
**Dr. Jayakar Shetty**  
**Dr. K.T. Sreelatha**  
**Dr. Sunil Sunny**  
**Dr. Jayaprasad K.**  
**Dr. Ajay Kumar Haridas**  
**Dr. George Varghese**  
**Dr. Retnakumari**  
**Dr. Jolly Mary Varughese**  
**Dr. Romel Joseph**  
**Dr. Thomas Joseph**  
**Dr. Kunjamma K.M**  
**Dr. Vinod R.B.**  
**Dr. S. Karthiga Kannan**  
**Dr. P.G. Francis**  
**Dr. M. Sadique Hussain**  
**Dr. Saji P.**  
**Dr. N.O. Varghese**  
**Dr. Joji George**  
**Dr. Aby Mathew T.**  
**Dr. E. Anuradha Sunil Jagan**  
**Dr. Sobha Kuriakose**  
**Dr. P.C. Sunil**  
**Dr. Shamsuddin**  
**Dr. M.K. Mangalam**

**EDITORIAL OFFICE**

Neelambikam, Attukal, Manacaud  
Trivandrum, Kerala - 695 009  
Phone: 0471-2459235  
Mobile: 09447066100  
e-mail: editorkdj@gmail.com  
web: www.idakerala.com

**OFFICE BEARERS OF  
IDA KERALA STATE**

**PRESIDENT**

**Dr Mohammed Sameer P.T.**

**IMM. PAST PRESIDENT**

**Dr. Thomas KC**

**PRESIDENT ELECT**

**Dr Sabu Kurian**

**VICE PRESIDENTS**

**Dr. Ciju A. Poulouse**  
**Dr Eugene Varghese Joseph**  
**Dr Fazil V Hassan**

**HON. SECRETARY**

**Dr Suresh Kumar G**

**JOINT SECRETARY**

**Dr Binoy Stanly**

**ASST. SECRETARY**

**Dr. Krishna Kumar K S**

**TREASURER**

**Dr. Santhoshkumar P.U.**

**EDITOR**

**Dr. K. Nandakumar**

**CDE CONVENOR**

**Dr. Nirmal George Saibu**

**CDH CHAIRMAN**

**Dr. Subash K Madhavan**



## Oral disease a major public health burden

Oral disease is one of the most common public health issues worldwide with significant socio-economic impacts, and yet it is frequently neglected in public health policy. Oral diseases affect not only the health of the oral cavity and associated craniofacial structures, but can be detrimental to the overall health and well-being of individuals. Our challenges extend from the continued struggle against two of the most common infectious diseases – dental caries and periodontal diseases – to eliminating life-threatening oral and pharyngeal malignancies, craniofacial birth defects and developmental disorders, acute and chronic orofacial pain and other conditions that compromise oral health. Oral diseases affect the most basic human needs: the ability to eat and drink, swallow, maintain proper nutrition, smile, and communicate. Oral health and overall health and well-being are inextricably connected. For instance, accumulating evidence now points to a possible link between periodontal diseases and the incidence of premature, low-birth weight babies, cardiovascular disease, and pulmonary disease. Oral diseases and non-communicable diseases are closely interlinked through sharing common risk factors (e.g. excess sugar consumption and tobacco use) and underlying infection/inflammatory pathways.

Oral disease remains a major public health burden worldwide. It is of great importance to integrate oral health into global health agenda via the common risk factor approach. The long-term sustainable strategy for global oral health should focus on health promotion and disease prevention through effective multidisciplinary teamwork. The WHO Global Strategy for the prevention and control of noncommunicable diseases is a new approach to managing the prevention and control of oral diseases. Continuing surveillance of levels and patterns of risk factors is of fundamental importance to planning and evaluating community preventive activities and oral health promotion.



## Contents

Preisident's Message	178
Secretary's Report	179
Editorial	180
<b>Forced eruption-a symbiotic approach</b>	<b>181</b>
— Charudev J J	
<b>Is genotyping the next frontier of orthodontic treatment?</b>	<b>185</b>
— Binu Purushothaman	
<b>Rehabilitation of an anterior maxillary edentulous space with a delayed loaded implant using PRF for regeneration of bone</b>	<b>188</b>
— Muneet Kaur Marwah	
<b>Link between periodontitis and metabolic syndrome</b>	<b>191</b>
— Jaziya Bhanu	
<b>Is Azithromycin an effective adjunctive immunomodulator in periodontal therapy</b>	<b>195</b>
— Rosamma Joseph V	
<b>Paradigm shift in treatment of obstructive sleep apnea</b>	<b>199</b>
— Ashino John	
<b>A Novel Approach in Management of Condylar Fractures</b>	<b>202</b>
— Tripti Nair	
<b>Morphometric analysis of facial soft tissue in preschool children with flush terminal plane molar relation in Thiruvananthapuram</b>	<b>205</b>
— Sheela Sreedharan	
<b>Antibiotic Prophylaxis to prevent Infective Endocarditis – current dilemmas</b>	<b>209</b>
— Mathew Tharakan	
<b>Current concepts in rotary endodontics and clinical use</b>	<b>213</b>
— Rethi Mahesh	
<b>Access post overdenture system – an easy approach to overdentures</b>	<b>218</b>
— A. V. Sreekumar	
<b>Restoration of severely worn dentition – a multidisciplinary approach</b>	<b>221</b>
— A. V. Sreekumar	
<b>Ridge mapping- 'a map to success'</b>	<b>224</b>
— Vivek B. Chandran	
<b>Quiz</b>	<b>227</b>
* Jayanthi	
<b>Association News</b>	<b>231</b>

# President's Message

---



**Dr Mohamad Sameer P T**

Dear friends and colleagues.

Greetings from the President's desk....

The satisfaction of completing the first half of the IDA year successfully is doubled due to the fact that my backbone is an excellent team. Together we have been able to highlight the decreasing quality of dental education in our state and plead our case with Hon. health minister. She assured that the ministry will study the issues faced by our profession and will be meeting us in the month of August.

The diphtheria “scare” in the northern districts of our state has galvanised us in to providing vaccines free of cost to our members. We have achieved the task efficiently. The Malayalam newsletter “DHANTHAROGYAM” is in pipeline and should be ready for publication soon.

The CDE wing of almost all branches are in full swing and deserve a special mention for the outstanding quality of programmes. IDA's social commitment is proved once again on the No-tobacco day. The wide variety of programs showcased demonstrates the talent that the IDA has.

I take this opportunity to personally thank each and every member of my team of office bearers.

Wishing you all a fun filled and Prosperous Onam !!!!

Yours sincerely

**Dr Mohamad Sameer P T**  
President, IDA Kerala State

# Secretary's Report

---



**Dr. Suresh Kumar G**

Dear Doctor,

Greetings to you from IDA Kerala State Office.

As we are reaching midway through the term, warm wishes to all our members. The office is very pleased to note the activity of all its branches especially with regard to CDE and CDH activities. IDA has always been actively involved in charitable activities as a part of its commitment to the social cause. We extend our sincere appreciation to one of our youngest branches who have supported a family by gifting a house. There has been a substantial membership growth during the first term with all round efforts from all the branches. With regard to the activities of the office we are in the process digitising the office and as a part you can access the revamped website by the time this journal reaches you.

With the new Government keen to take up the Clinical establishment bill and formulate a Health Policy, IDA is doing its part to see that Oral Health is given due importance. The denial of permission of DCI for Govt. Dental College, Alappuzha should be seen as a pointer towards the abysmal quality of Dental education and do hope the DCI also acts appropriately against the erring institutions in the private sector too.

The State office requests its members to send in their feedback and suggestions on all related matters at [www.idakerala.com](http://www.idakerala.com).

My sincere thanks to all office bearers for their team effort. With the active participation of Local Branches and members lets move ahead to realising our dream for a better future.

Thanking you with best wishes for a festive season ahead.

**Dr. Suresh Kumar G.**

Hon. Secretary, IDA Kerala State



Dr. K. Nandakumar

## Quality care in dentistry

Dental care facilities available in India are either on par with international standards or even surpasses in select areas. Number of dental colleges in India has reached astronomical figures with most of the colleges producing hundred dentists an year. Specialization facilities are available in all the colleges and corporate clinics provide massive treatment avenues. Dental education is losing its sheen as a successful business model, a status which was enjoyed five years ago. Now the profession should progress to deliver skilled and thoughtful care. Quality assessment is the only way to progress and it should be implemented through a self-assessment protocol. What are the factors to be measured?

1. We should be able to provide **safe** dentistry to our people. Selecting materials and techniques should be evaluated based on scientific evidence so that our people can be assured of safe and sure treatment.
2. Are we providing **timely** treatment? Early administration of a treatment as well as delaying of appropriate treatment cannot be considered as assurance of quality. Treatment of caries in an anterior tooth with a crown, while a composite resin restoration would have been sufficient, is a classic example of rushing the treatment at an early stage.
3. Quality is assured when service is provided based on scientific evidence and not on compulsions and demands. The operator should know the **effectiveness** of the treatment.
4. Wastage in any form should be avoided - equipment, supplies and energy. Then the service will become **efficient**.
5. The service we provide should be on an **equitable basis**. No variation should be made in providing service based on gender, socio economic status or ethnicity.
6. Ultimately for whom is the treatment given; it is the patient. Never forget that treatment should be **patient centered** to assure quality.

While selecting a treatment, we should be sure of one fact that the public should receive the benefit. Which can assure this? The quality. Who can assure this? We the dentists.

**Dr. K. Nandakumar**  
Editor, KDJ

# Forced eruption-a symbiotic approach

\* Charudev J.J, \*\* Anish Varkey John, \*\*\* S. Anilkumar, \*\*\*\* Baiju R.M

## Abstract

Dental aesthetics is the achievement of ideal relationship between tooth and gingiva. This harmonious interplay between white and pink contributes to the success of an aesthetic restoration. Crown lengthening by orthodontic extrusion is one such procedure done to achieve this goal. Crown lengthening is employed to correct gummy smiles, and to improve resistance and retention form of a dentition that is compromised by the presence of extensive caries, traumatic injuries or severe parafunctional habits. Achieving optimal aesthetics without compromising the biological width and gingival health requires an efficient and systematic multidisciplinary approach. This case report discusses the crown lengthening by forced eruption of crown root fracture of upper central incisor extending sub gingivally by a combined effort of endodontist, orthodontist, periodontist and prosthodontist to achieve an ideal harmonious gingiva tooth relationship in performing aesthetic restoration.

KDJ 2016 | Vol. 39 | No. 3 | Pg 181-184

## ► Introduction

Crown-root fracture is a type of dental trauma occurring below the gingival margin, usually resulting from horizontal impact, which involves enamel, dentin and cementum. Majority of dental injuries occur to males and in maxillary anterior teeth due to its

position in the arch.<sup>1,2</sup> Management of such injuries are challenging for clinicians as it demands good aesthetic results following rehabilitation of the lost teeth. Current treatment options available to manage a fracture at the level of the gingival margin include: (1) extraction of the remaining root and subsequent replacement with a fixed prosthesis or an implant supported crown (2) exposure of sound tooth structure by periodontal surgery (3) exposure of tooth structure by forced eruption (4) Immediate surgical extrusion (Benex root extraction system).<sup>3</sup> Although extraction followed by immediate implant placement yields a predictable result, the technique involved is invasive compared to other treatment modalities. Surgical crown lengthening have to be extended to adjacent teeth in order to blend the gingival and osseous contours that would result in sacrifice of supporting bone on several teeth, root sensitivity, and aesthetic deformities.<sup>4</sup> Surgical extrusion of teeth decreases treatment duration compared with forced eruption; however, such techniques have been associated with poor predictability and carries a high risk of root resorption.<sup>3</sup>

Forced eruption or orthodontic root extrusion, was first described by Heithersay in 1973 and since then clinical success of this technique has been well documented. Forced eruption is initiated after endodontic therapy is complete in order to reposition the root segment coronally. Exposure of sound tooth structure following extrusion aims at:

(1) to create 3-4mm of supra-crestal tooth structure (2) Placement of restorative margins on sound tooth structure (3) maintain biologic width (4) maintain at least 1:1 crown root ratio (5) and access for impression techniques. Indications for forced eruption include treatment of: (1) a subgingival or infra-osseous lesion (e.g., caries, oblique or horizontal fractures, perforations caused by a pin or post) (2) a restoration impinging on the biological width (3) angular bone defects and isolated periodontal pockets (4) pre-implant extraction or orthodontic extraction (atraumatic technique) (5) impacted teeth (canines). While it is contra-indicated to do forced eruption in (1) ankylosis or hypercementosis (2) vertical root fracture (3) tooth with short roots (crown-root ratio less than 1:1) (4) exposure of the furcation.<sup>5</sup>

The treatment of traumatic injuries is therefore complex and success is determined by the collective effort of an interdisciplinary team of endodontist, orthodontist, periodontist and a prosthodontist.

## ► Case report

A 29-year-old male patient reported to the Department of Prosthodontics at Government Dental College, Kottayam, Kerala with complaints of broken upper front tooth. He gave a history of trauma to upper anterior tooth following road traffic accident. He also gave a past dental history of endodontically treated #11, #21, restored with metal ceramic

\* Junior Resident, Department of Periodontics; \*\*Junior Resident, Department of Prosthodontics; \*\*\*Professor, Department of Prosthodontics; \*\*\*\*Associate Professor, Department of Periodontics, Govt. Dental College, Kottayam.  
• Corresponding Author: Dr. Charudev J.J. E-mail: charudevjj@gmail.com

restoration two years back. Clinical examination revealed an Ellis class III fracture of #21 (fig.1). Radiographic examination revealed an oblique fracture in relation to the crown of #21 extending subgingivally in the mesial and palatal aspect. The periapical radiograph revealed endodontically treated #11, #21 with sound obturation, without any periapical pathology or root fracture (fig.2).

Treatment options included: (1) extraction of the tooth and immediate implant placement, or (2) crown lengthening and subsequent restoration. In the current case to avoid an invasive surgical technique a more conservative treatment modality was chosen i.e. crown lengthening by forced eruption.

### ► Procedure

As the patient required post space creation for restorative purpose, a J- hook mechanism for forced eruption was planned.<sup>6</sup> Existing gutta percha cones were removed to at least half the depth of the root canal to create the post space in tooth #21. A round stainless steel orthodontic wire of 0.7 mm was bent to form a J-hook, with the desired length. The J hook was cemented in the post space with glass ionomer cement (Fuji I; GC America). Pre adjusted edge wise brackets (MBT brackets) were bonded to tooth #13, 12, 11, 22, 23. Since the arch was fairly aligned, 0.016 stainless steel (SS) wire was used. An elastic chain was placed from the J hook to the SS wire to orthodontically extrude the tooth (fig.3). 3mm extrusion was accomplished within a short span of 3 weeks. Supracrestal fiberotomy is done with No: 11 Bard Parker blade at 7-10 days interval during the forced extrusion period

(fig.4). Following extrusion, tooth was stabilised in position for 1 month (fig.5).<sup>7</sup>

At the end of the stabilisation phase, the tooth was clinically and radiographically evaluated for any pathology. The periapical radiograph confirmed the root extrusion of 3mm (fig.6). The temporary post (J Hook) was removed, post space was freshly prepared, and fibre reinforced resin post (Postec Plus; Ivoclar Vivadent AG) was cemented using self-adhesive resin cement (RelyX U200, 3M ESPE) (fig.7). Subsequently composite resin core build up was accomplished (Tetric N Ceram, Ivoclar vivadent) and subgingival shoulder margins were prepared (fig.8). Gingival retraction was done (Magic foam cord, Coltene Whaledent) and two phase-single stage vinyl poly siloxane impression was made (Photosil, DPI India) following which temporisation was done (Cool temp, Bis-acrylic, Coltene). Definitive restoration was fabricated with a complete coverage Zirconia crown (Dentcare Zirconia Classic, India) and cemented using self-adhesive resin cement (RelyX U200, 3M ESPE) (fig.9).<sup>6</sup> Follow up was done at 1 week, and 3months. The patient was satisfied with the esthetic and functional outcome (fig.10).

### ► Discussion

Traumatic injuries to teeth and their supporting tissues usually occur in young people and damage may vary from enamel fracture to avulsion, with or without pulpal involvement or bone fracture. Epidemiological statistics revealed that crown-root fractures represent 5% of dental injuries.<sup>8,9</sup> Several alternative treatments for teeth with subgingival fractures

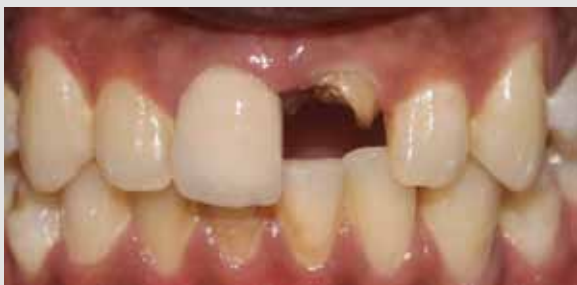

Fig 1 Initial case presentation

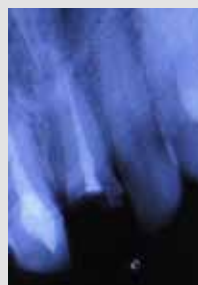

Fig 2 Pre op IOPA.

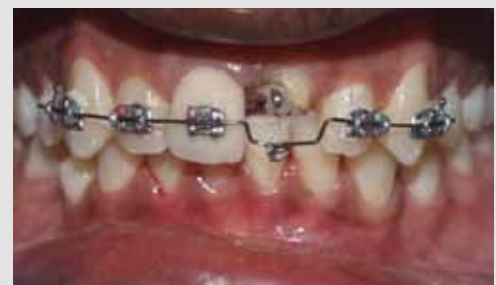

Fig 3 J Hook engaged with elastic chain.

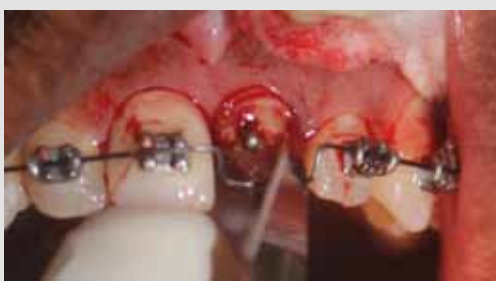

Fig 4 Supracrestal fiberotomy.

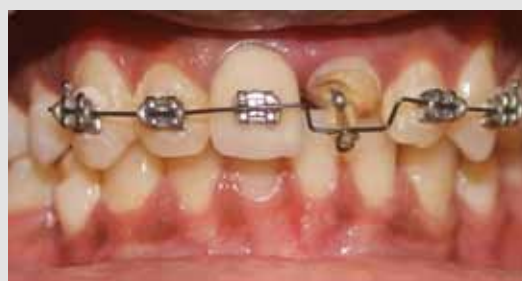

Fig 5 Stabilisation after achieving 3mm extrusion.

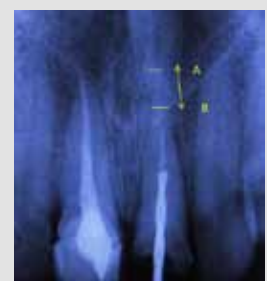


Fig 6 Final post space preparation.



have been proposed. The main objective of the treatment consists in exposing the fracture margin to a supragingival level, so that clinical restoration procedures can be conducted without contamination with blood and saliva. In the current case of a crown root fracture, extending subgingivally, forced orthodontic tooth eruption with supracrestal fiberotomy was employed. Forced eruption done without supracrestal fiberotomy will move the entire attachment apparatus in unison with the tooth.<sup>4</sup> This results in an increase in attached gingiva which is increased through eversion of the sulcular epithelium, appearing first as immature non keratinized tissue.<sup>5</sup> When forced eruption is done with supracrestal fiberotomy the crestal bone and gingival margin are retained at their pre-treatment levels. Supracrestal fiberotomy severs the supracrestal fibres preventing the crestal bone from following the root in a coronal direction. Following extrusion it is imperative to maintain an appropriate crown-root ratio (at least 1:1 after extrusion) and biologic width.

**Extrusion and Orthodontics**

According to Simon et al, occlusal movement of the root

along with its gingiva seems to be a function of how rapidly the root is extruded and how much force is used.<sup>10</sup> In case of rapid extrusion of the tooth, the periodontal fibres stretch and readjust, but the bone does not have time to remodel because of rapid movement. It is imperative that constant force be maintained between the extrusion and hyalinization phases; otherwise, the desired orthodontic movement will not take place.<sup>5</sup> Also the force must be applied along the tooth axis to prevent any undesirable tilting. Extrusion can be achieved with use of 1) orthodontic brackets and wires, 2) attaching a rigid wire to the adjacent teeth and engaging an elastic chain to it, 3) band and soldered springs, 4) a removable Hawley device and an anchoring tip cemented to the buccal aspect.<sup>11,12</sup>

**Extrusion and Periodontics**

Extrusion should be achieved to such extent that the biologic width is maintained following restoration of the extruded tooth. The average biologic width is 2.04; it comprises gingival connective tissue and epithelial attachment in the form of functional epithelium.<sup>13</sup> It is of prime importance when considering the restoration of the tooth whose gingival

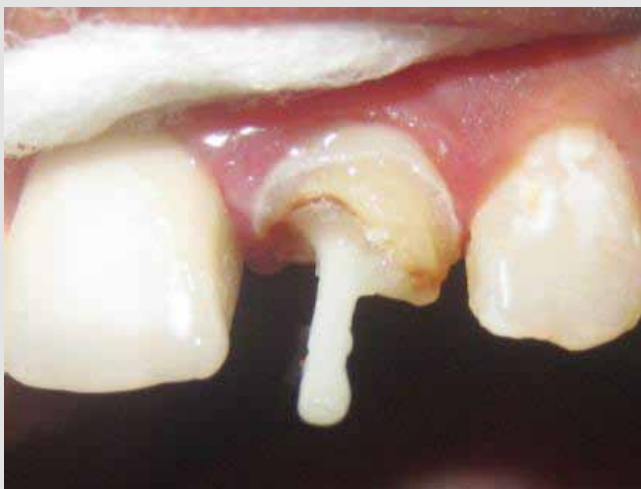

Fig 7 Fibre post luted with self adhesive resin cement

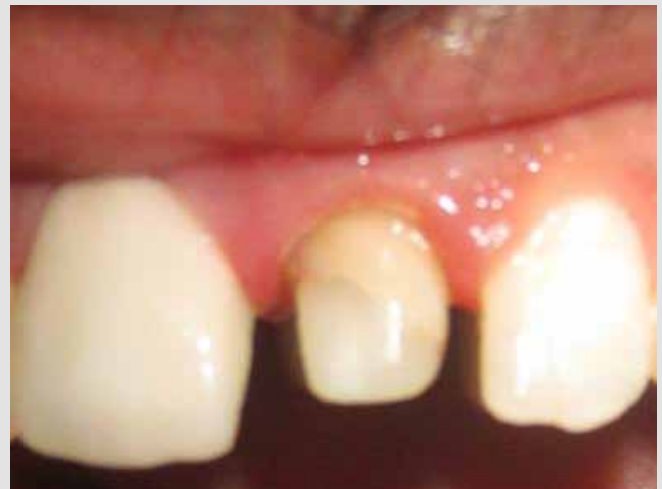

Fig 8 Composite resin core build up.

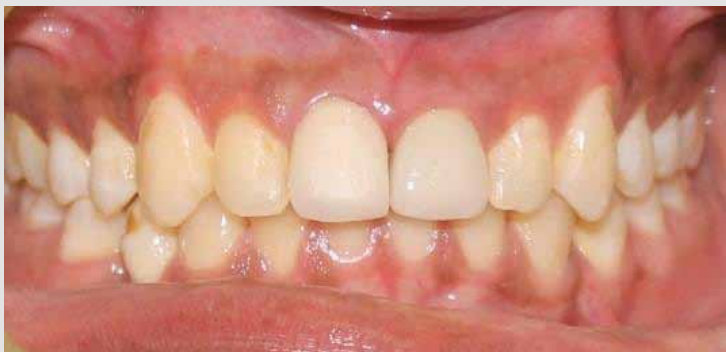

Fig 9 Definitive zirconia complete coverage restoration.

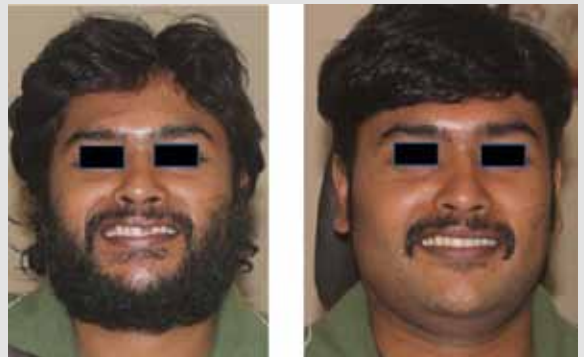

Fig 10 Comparison of treatment outcome

margin is at the level or below the alveolar crest. The distance from the alveolar crest to the tooth structure should be 3-4 mm to prevent the restorative margin to encroach into the biologic width.<sup>14</sup>

### Extrusion and Endodontics

Most of the cases of crown root fracture require endodontic treatment to prevent periapical pathology following trauma. But in situations where a canal that cannot be adequately treated (because of subgingival fracture and lack of an adequate operative field) can be filled with calcium hydroxide before extrusion and subsequent treatment.<sup>5</sup> However, when the tooth must be extracted and the purpose of extrusion is to obtain an optimal ridge (e.g., in cases of pre-implant extraction), pulpectomy may be sufficient.<sup>5</sup> During rapid extrusion, a pseudo-apical lesion (an apical radiolucency) appears which must be differentiated from a true lesion of endodontic origin.

### Extrusion and Prosthodontics

The mesiodistal diameter of the root, which is already constricted at the cemento enamel junction of single-rooted teeth, is further reduced with progression of the extrusion (especially in the case of conical roots), which involves expansion of interproximal gingival embrasures. The contour shape of the crowns must not be exaggerated to compensate for this reduction in diameter. Similarly, embrasures should not be filled to prevent an overcontour, which could adversely affect the marginal periodontium.<sup>5,15</sup>

Fibre reinforced resin post adds to the retention of the crown at the same time possess the virtue of sharing similar flexural properties with dentin, minimising the risk of root fracture which are common with cast metal post. The self-adhesive resin cement minimises the problem of debonding associated with fibre posts by the dual curing mode (ensure complete polymerisation of cement in post space) and improved bond strength through chemomechanical bonding with dentin. Zirconia crown in the esthetic zone not only fulfils the esthetic demands but also caters to the functional requirements.

### ► Conclusion

In this modern era of dentistry a multidisciplinary approach is recognised to treat most of the common dental problems. In the current case one such common dental problem was managed by a symbiotic approach of orthodontist, periodontist,

endodontist and prosthodontist. Unarguably it is this combined effort that helped to deliver a successful treatment for the patient in terms of function and aesthetics. Regular follow up and good oral hygiene maintenance regimen will yield a good long term prognosis.

### ► References

1. Hamilton FA, Hill FJ, Holloway PJ. An investigation of dento-alveolar trauma and its treatment in an adolescent population. Part 1: The prevalence and incidence of injuries and the extent and adequacy of treatment received. *Br Dent J. ENGLAND*; 1997 Feb;182(3):91-5.
2. Dietschi D, Jacoby T, Dietschi JM, Schatz JP. Treatment of traumatic injuries in the front teeth: restorative aspects in crown fractures. *Pract Periodontics Aesthet Dent. United States*; 2000 Oct;12(8):751-8.
3. Kelly RD, Rcsed M, Addison O, Rest FDS, Rcseng D, Tomson PL, et al. Atraumatic surgical extrusion to improve tooth restorability: A clinical report. *J Prosthet Dent [Internet]. Editorial Council for the Journal of Prosthetic Dentistry*; 1-5. Available from: <http://dx.doi.org/10.1016/j.prosdent.2015.09.028>
4. Ingber. Forced Eruption : Part II. A Method of Treating Nonrestorable Teeth — Periodontal and Restorative Considerations \*. *J Periodontol.* 1975;203-16.
5. Bach N, Baylard J, Perio D. Orthodontic Extrusion: Periodontal Considerations and Applications. 2004;775-80.
6. Ré J, Orthlieb J. Rapid orthodontic extrusion of a subgingivally fractured incisor. *J Prosthet Dent [Internet]. Editorial Council for the Journal of Prosthetic Dentistry*; 2016;1-3. Available from: <http://dx.doi.org/10.1016/j.prosdent.2016.01.026>
7. Munir B, Khan AM, Zaib F. MANAGEMENT OF CROWN-ROOT FRACTURE — A CASE REPORT. 2011;31(1):2-5.
8. Olsburgh S, Jacoby T, Krejci I. Crown fractures in the permanent dentition: pulpal and restorative considerations. *Dent Traumatol. Denmark*; 2002 Jun;18(3):103-15.
9. Fidel SR, Fidel-junior RAS, Sassone LM, Antonio R, Fidel S. Clinical Management of a Complicated Crown-Root Fracture: A Case Report. 2011;22:258-62.
10. Simon JH. Root extrusion. Rationale and techniques. *Dent Clin North Am. UNITED STATES*; 1984 Oct;28(4):909-21.
11. Addy LD, Durning P, Thomas MBM, McLaughlin WS. Orthodontic extrusion: an interdisciplinary approach to patient management. *Dent Update. England*; 2009 May;36(4):212-4,217-8.
12. Reyes E, Barrow S, McLeod DE. Crown lengthening with removable orthodontics: a combined approach for ideal esthetics. *Gen Dent. United States*; 2011;59(5):362-6.
13. Govila S, Govila V, Rajkumar B. Multidisciplinary approach for treatment of sub gingival crown fracture. 2011;(2):2011-4.
14. Cohen DW. Crown Lengthening. *Atlas of cosmetic and reconstructive periodontal surgery.* Third edition.pg:249-258 In 2004.
15. Cronin RJ, Wardle WL. Prosthodontic management of vertical root extrusion. *J Prosthet Dent. UNITED STATES*; 1981 Nov;46(5):498-504.



JOIN

**IDA-HOPE** (Help Offered to Professionals in Emergencies).  
Members are requested to contact their respective IDA local branch  
HOPE representative to receive original application forms

# Is genotyping the next frontier of orthodontic treatment?

\*Binu Purushothaman, \*\*Rasool Karim Nizaro Siyo, \*\*\*Deepa Menon, \*\*\*Rahul C.S, \*\*\*Bijoy N.V

## Abstract

The relative influence of genetics and environmental factors in the etiology of malocclusion has been a matter for discussion, debate and controversy in the orthodontic literature. The term 'personalized medicine' give emphasis to human genome, which helps to provide treatment based on individual variation versus population trends. The views presented here are based on the central dogma that applying genetic knowledge to the field of orthodontics will undoubtedly change the way clinicians choose therapeutic modalities in the future. Currently there is increasing focus on gene therapy to treat wide variety of inherited and acquired diseases. If we can successfully sort patients based on their genotypes, we can start to propose targeted clinical treatment (i.e. personalized medicine in orthodontics). The clinician will be more aware of the unique genetic signatures of orthodontic patients enabling them to devise better treatment modalities customized according to the individual. This paper reviews the literature and summarizes the evidence for the influence of genetics in dental anomalies, malocclusion and emerging future trends in orthodontics.

KDJ 2016 | Vol. 39 | No. 3 | Pg 185-187

*"We used to think our fate was in stars. Now we know, in large measure, our fate is in genes"- James Watson*

## ► Introduction

Every person has a unique variation of the human genome. An individual's health stems from genetic variations and influences from the environment.

Advances in genome technologies have fueled expectations for this proactive healthcare approach.

Personalized medicine is a medical model that separates patients into different groups with medical decisions, practices, interventions or products being tailored to the individual patient based on their predicted response or risk of disease. "Personalized medicine" is based initially on pharmacogenetics and now exploding as genome-wide association studies are undertaken. The same may be projected for the future of orthodontics. The understanding of the combination and interaction of nature (environment) and nurture (genetics) together that influence the treatment response of our patients is fundamental to the evidence-based practice of orthodontics.<sup>1</sup>

## Is genotyping the next frontier of orthodontic treatment?

Multiple factors and processes contribute to the response to orthodontic treatment. Genome-wide association studies are necessary to further the evidence base for the practice of orthodontics. Currently the diagnosis and treatment of most types of malocclusion is fraught with inconsistencies concerning the timing, duration and type of treatment. Therefore, the first and most critical step in the application of genetics to clinical orthodontics must be to develop a phenotypic categorization, which can subsequently be correlated with genotyping experiments.

The significance of genetics in malocclusion has been known for centuries and has always been a topic

of great debate and a little controversy. Lundstrom and others examined the question of 'nature versus nurture' and found that both influenced the development of malocclusion to some extent, with genetics accounting for up to 50% of malocclusion.<sup>2</sup>

## Inheritance of malocclusion

Malocclusion may be defined as a significant deviation from what is defined as normal or 'ideal' occlusion. The term 'normal occlusion' occurs in only 30–40 per cent of the population. There is dental anthropological evidence that population groups that are genetically homogeneous tend to have normal occlusion. In pure racial stocks, such as the Melanesians of the Philippine islands, malocclusion is almost non-existent.

Dental crowding is a problem for both adolescents and adults in modern society. Some studies suggests an association for the genes EDA and XEDAR in dental crowding. EDA (ectodysplasin) was shown to act in a morphogenetic role in teeth and other ectodermal organs. Mutations results in differential gene expression which causes large tooth phenotype. This ultimately results in crowding.<sup>3</sup>

Class II division 2 malocclusion is a distinct clinical entity and is considered as a 'syndrome' than the other malocclusion types. Familial occurrence of class II div 2 has been documented in several published reports including twin and triple studies by Kloeppel in 1953 and Markovic in 1992. Twin studies have shown 100% concordance rate for monozygotic twins and 90% discordance rate for dizygotic

\* Professor and Head, \*\* Professor, \*\*\* P.G. student, Department of Orthodontics, KMCT Dental College, Calicut  
• Corresponding Author: Dr Binu Purushothaman, E-mail: drbinuortho@gmail.com

twins. This suggests strong evidence for genetics as the main etiological factor for class II div 2 malocclusion.<sup>4</sup>

Skeletal Class III malocclusion clearly has a significant genetic component. Familial studies of mandibular prognathism are suggestive of heredity in the etiology of this condition and several inheritance models have been proposed. The inheritance of phenotypic features in mandibular prognathism was first reported by Strohmayr and then by Wolff et al in their analysis of the pedigree of Hapsburg family.<sup>5,6</sup> Studies have documented numerous genes, growth factors and local mediators are involved in the phenotypic expression of mandible. The variable expression of such factors can lead to prognathic or retrognathic mandible.

Studies have also pointed that genes and the variation in their expression can be a factor in development of Class III malocclusion. Vascular endothelial growth factor (VEGF), insulin like growth factor-1 (IGF-1) and HOX 3 are few such genes. On a sub-molecular level, chromosomal loci (1p36, 12q23) harbor genes which increase the susceptibility towards mandibular prognathism. Rabie et al indicated that forward positioning of the mandible triggered the expression of *Ihh* and *Pthlh*, and these proteins act as mediators to promote increased growth of the condylar cartilage. An increase in transcription factors like sex-determining region Y and *Runx2* was noted during mechanical loading of mandible. These factors induce differentiation of chondrocytes.<sup>5</sup>

#### Heritability of local occlusal variables

Lundstrom studied 50 pairs of monozygotic and 50 pairs of dizygotic twins and concluded that heredity played a significant role in determining width and length of the dental arch, crowding, spacing and degree of overbite. Vastard in 1996, demonstrated that a mutation in *MSX* gene, caused familial tooth agenesis. Genetic linkage analysis in a family has identified a causative locus on chromosome 4p where the *Msx-1* gene resides. Supernumerary teeth are most frequently seen in the premaxillary region (mesiodens) and with a male sex predilection also appear to be genetically determined.

#### Patterning of dentition: Odontogenic homeobox code

In 1998, Thomas and Sharpe proposed that the patterning of dentition was determined by the complex and specific distribution of homeobox genes ("odontogenic homeobox code") prior to the initiation of tooth formation. Various odontogenic homeobox genes identified were, *MSX* genes, *DLX* genes, *BARX* genes. Each specific region of the homeodomain expresses a unique combination of homeobox genes, which monitor the development of specific teeth. *Msx1* knockout in mice caused clefting, aberration in tooth development, missing teeth and deficiency of alveolar bones. The combination *Msx1* and 2 knock out cause severe skeletal deficiencies in calvaria, teeth and alveolar bone.<sup>7</sup>

#### Genetic factors in external apical root resorption during orthodontic treatment

There is a significant variability for EARR susceptibility among individuals. EARR is a complex disease, with multiple genetic and environmental factors contributing to its occurrence and severity. There is an evidence of linkage between EARR of maxillary central incisors and a polymorphic marker D18S64. This polymorphic marker lies close to the *TNFRSF11A* gene suggesting that this locus or a closely linked one contributes to the susceptibility to EARR. The *TNFRSF11A* gene codes for *RANKL*, an essential signaling molecule in osteoclasts differentiation and function<sup>8</sup>.

However, due to the multifactorial nature of root resorption, it has been difficult to predict root resorption in specific orthodontic patients. Research is underway to identify biomarkers of orthodontic root resorption and these will enable clinicians to predict a patient's susceptibility and therefore possibly alter the treatment undertaken.

#### Association of sella turcica bridging with dental transposition and palatal canine impaction

An association between tooth transposition and bridging of the sella turcica, give the evidence of common embryonic origins associated with these structures. The presence of intracranial clinical calcifications in addition to those affecting the dentition is highly suggestive of genetic etiology underlying both tooth anomalies and those in a broader area of the orofacial field.<sup>9,10</sup> The increased frequency of complete and partial bridging of the sella turcica in subjects with palatally impacted canine provides further evidence of a genetic basis to this condition. As calcification and bridging of this region can present during early childhood, it may act as a useful diagnostic predictor of susceptibility to local dental problems.

#### Dermatoglyphics and malocclusion

The genetic expression is the basis for craniofacial development and is known to be responsible for skeletal malocclusions. Dermal ridges and craniofacial structures are both formed during second trimester of intra-uterine life, in around 6-8 weeks. It is hypothesized that hereditary and environmental factors leading to malocclusions may also set off in fingerprint patterns.

As genetic or chromosomal abnormalities might be reflected as alterations in dermal ridges, they can be used as an easily accessible tool in the study of genetically influenced diseases. The dermatoglyphic findings revealed that the arches were found at a higher frequency percentage in class I and class II div I malocclusions. The presence of twinned loops in class II Division 2 on digit 2, is a significant finding as compared to that in ideal cases. A decreased frequency of radial loops, twinned loops and central pocket loops was associated

with class III malocclusions.<sup>11</sup> As genetic or chromosomal abnormalities might be reflected as alterations in dermal ridges, they can be used as an easily accessible tool in the study of genetically influenced diseases.

### Tissue engineering in orthodontics

Stem cells biology has become an important field of knowledge as a means to understand the tissue regeneration process. The orthodontic implications of stem cell therapy include the repair of the alveolar bone in cleft palate patients, distraction osteogenesis, regeneration and repair of temporomandibular joint defects, external apical root resorption and periodontal diseases.

In alveolar cleft osteoplasty mesenchymal stem cells were used instead of bone grafts<sup>12</sup>. In distraction osteogenesis stem cells may prove to be a potential method to accelerate bone regeneration in the distraction gap and enhance consolidation. The recent advances in stem cell technology assure the construction of bioengineered TMJ replacement. Cells from various sources including articular cartilage cells, fibroblasts, human umbilical cord matrix cells and mesenchymal stem cells have been used in efforts to reconstruct the TMJ. In external apical root resorption during orthodontic treatment stem cells can be used prior to the treatment, to prevent root resorption or post treatment to repair the damage.

Periodontal complications are one of the most common side effects linked to orthodontics. They occur in various forms from gingivitis to periodontitis, dehiscence, fenestrations, interdental fold, gingival recession or overgrowth and black triangles. Periodontal ligament stem cells (PDSCs) can be used to regenerate and repair periodontal tissues.

### Recent advances: Gene therapy in orthodontics

Local RANKL gene transfer to the periodontal tissue accelerates orthodontic tooth movement and local OPG gene transfer inhibits tooth movement. In future similar procedures may be used by orthodontist to reduce treatment time and improve results.<sup>13</sup> Local OPG gene transfer to periodontal tissues could inhibit relapse after orthodontic tooth movement, through the inhibition of osteoclastogenesis.

Mutations in genes such as TREACLE may be responsible for the milder cases of mandibular retrognathism commonly seen in orthodontic practice. Mandibular prognathism has recently been mapped to regions on chromosomes 1, 6, and 19. The orthodontists can use software that detects mutations in a patient's genomic sequence and provides a genetic growth prediction based on these variations. The understanding of the genes responsible for mandibular growth and safe methods of transducing genes into tissues, gene therapy may become the standard care for the treatment of mandibular-deficient malocclusions. In cases of craniosynostosis involving mutations in FGFR2, temporarily blocking FGFR2 signaling in the

preosteoblasts would allow normal sutural growth without surgical intervention.<sup>14</sup>

### ► Conclusion

The analysis of the human genome signal the inception of a new era of gene-based medicine. Keys to successful treatment outcomes include knowing how different patients respond to various treatment modalities, and how the natural history of many skeletal and connective tissue disorders impact short and long-term orthodontic treatment outcomes. In the more distant future, linkage studies that lead to the identification of specific genetic mutations responsible for certain malocclusion will form the basis for specific drug targets to correct discrepancies in facial growth. If we can successfully categorize individuals based on subtypes, then we can start to propose clinical trials to identify appropriately targeted clinical treatment (i.e, personalized medicine in orthodontics).

### ► References

- Hartsfield James K, Personalized Orthodontics, The Future Of Genetics In Practice, Semin Orthod, 2008, Volume 14 (2): 166 –171.
- Lundstrom A, Nature Vs Nurture In Dentofacial Variation, Eur J Orthod, 1984;6:77-91.
- Ting TY, Wong RW, Rabie AB, Analysis Of Genetic Polymorphisms In Skeletal Class I Crowding, Am J Orthod Dentofacial Orthop, 2011 Jul;140(1):9-15.
- P.A. Mossey, The Heritability Of Malocclusion: Part 2. The Influence Of Genetics In Malocclusion, British Journal Of Orthodontics, September 1999, Volume 26,(3):195-203.
- S. Chaturvedia, P. Kamathb, Class III Malocclusion, Role Of Nature And Nurture, Virtual Journal Of Orthodontics, March 2011.
- Cruz Et Al, Major Gene And Multifactorial Inheritance Of Mandibular Prognathism, Am J Med Genet. 2008 Jan 1;146A (1):71-7.
- Olivier Duverger And Maria I. Morasso, Role Of Homeobox Genes In The Patterning, Specification And Differentiation Of Ectodermal Appendages In Mammals, J Cell Physiol, 2008 Aug; 216(2): 337–346.
- Al-Qawasm1, J.K. Hartsfield, Jr., Genetic Predisposition To External Apical Root Resorption In Orthodontic Patients: Linkage Of Chromosome-18 Marker, J Dent Res, 2003 82(5):356-360.
- Rosalia Leonardi, Mauro Farella, Martyn T. Cobourne, An Association Between Sella Turcica Bridging And Dental Transposition, European Journal Of Orthodontics, Vol 33, (4):461-65.
- Pirinen et al, An Association Between Sella Turcica Bridging And Dental Transposition, Eur J Orthod August 1, 2011 33:461-465.
- Boggula Rama Mohan Reddy, Gowri Sankar, Journal Of Clinical And Diagnostic Research, December 2013; 7(12): 3060–65.
- Waite PD, Bone Grafting For The Alveolar Cleft Defect, Semin Orthod. 1996; 2:192–6.
- Vagish Kumar L S Gene Therapy: Principles And Applications In Dentistry, Research And Reviews: Journal Of Dental Sciences, January - March, 2014, Volume 2 (1).
- Havens B, Wadhwa S, Nanda R, Orthodontics In The Year 2047: Genetically Driven Treatment Plans, J Clin Orthod. 2007 Sep;41 (9):549-56.
- Carlson, David S. "Evolving concepts of heredity and genetics in orthodontics." American Journal of Orthodontics and Dentofacial Orthopedics, 2015 148(6): 922-938.

# Rehabilitation of an anterior maxillary edentulous space with a delayed loaded implant using PRF for regeneration of bone

\* Muneet Kaur Marwah, \*\*K. Harshakumar, \*\*\*S. Lylajam, \*\*\*\*Kala S.

## Abstract

Loss of single tooth in aesthetic zone is the most distressing experience for the patient and a big challenge for the dentist. Surgical trauma can lead to recession in peri-implant tissues so maintenance of hard and soft tissue architecture in anterior maxillary esthetic zone is a prime concern to the surgeon.

PRF which is a platelet concentrate, is used to stimulate the healing process by providing all concentrated growth factors at the surgical site. PRF has a robust stimulating effect on various aspects of healing of soft and hard tissues including angiogenesis, immune control, harnessing circulatory stem cells. In this case report "PRF" was used with the graft material and implant was well osseointegrated.

KDJ 2016 | Vol. 39 | No. 3 | Pg 188-190

## ► Introduction

The absence of a single tooth in the anterior aesthetic zone is a distressing experience for the patient and a challenging job for a clinician as it requires both hard and soft tissue architecture maintenance<sup>1</sup>. Tooth loss either due to trauma or a pathology can result in a compromised bone volume and anatomy making it difficult for a functional and aesthetic implant

placement. Various techniques have been developed to overcome this problem like guided bone regeneration, osteoconduction, osteoinduction, re-vascularized bone grafts etc. Recently studies have emphasized the viability of platelet concentrates on healing of soft and osseous tissues and PRF is one of the recent development amongst them<sup>2,3</sup>. It has an invigorating effect on various aspects of healing like immune control, harnessing circulating stem cells, angiogenesis<sup>4,6</sup>. However outcome of placement of PRF following implant placement has not been well documented and requires more research work. In this article PRF was used to augment the osseous structure of bone and to facilitate implant placement in bone deficient sites.

## ► Case report

A 30 year old male patient presented with a complaint of unaesthetic appearance due to loss of anterior maxillary tooth. The left central incisor was lost due to failed endodontic treatment and patient desired to have a fixed restoration. His medical history was unremarkable and he had no history of smoking. He had undergone root canal treatment for right central, lateral and canine as well but was not interested to go for crown placement in spite of being motivated. The clinical examination

indicated a buccal bony defect and also in preoperative radiograph and OPG, a vertical bone loss was seen indicating an insufficient bone volume. (Fig 1 & Fig 2).

## Surgical phase

After giving local anesthesia, a mid-crescental incision was given in region of 11 and a full thickness mucoperiosteal flap was raised. (Fig 3). No vertical releasing incisions were made. Osteotomy site preparation was done through sequential drilling. A 3.75 mm by 13 mm implant (Adin Dental Implant System, Israel) was placed in the osteotomy site and torqued to 35 Ncm. (Fig 4).

## PRF preparation and placement

The PRF was freshly prepared by centrifuging 10 ml of blood drawn from antecubital vein which was transferred to a test tube without an anticoagulant. Centrifugation was done at 3000 rpm for 10 to 12 minutes after which the fibrin clot was taken and mixed with the bone graft. (Fig 5 & Fig 6). This mixture was placed over the surgical site and after placing the cover screw, flap was sutured. (Fig 7).

Post operative healing was uneventful and after 7 days suture removal was done. The patient returned after three months with no complications. At this time implant was surgically exposed and

\* PG student, \*\* Professor and Head, \*\*\*Professor, \*\*\*\*Assistant Professor, Department of Prosthodontics, Govt. Dental College, Trivandrum • Corresponding Author: Dr. Muneet Kaur Marwah, E- mail: muneet\_marwah@yahoo.in

healing cap was placed. No pain or movement was seen and there was evidence of new bone formation around the implant. After two weeks an open tray impression was made, Fig 8 and the implant was subsequently restored with a cement retained metal ceramic crown successfully (Fig 8 & Fig 9). The patient was satisfied with the esthetic result of implant restoration (Fig 10).

► **Discussion**

PRF is a biomaterial prepared from the patient’s own blood and it actively promotes soft and hard tissue wound healing. Blood is drawn from the patient and collected in a glass or silica coated plastic test tubes without anticoagulant and centrifuged allowing RBC to separate from platelets. This permits the activation of platelets when blood is centrifuged and triggers the coagulation cascade. The fibrin clot thus formed traps 95% of the platelets allowing the release of various growth factors from the platelet granules at the surgical site. These growth factors include PDGF (platelet derived growth factors), transforming growth factors  $\beta 1$  and  $\beta 2$  (TGF  $\beta 1$ ,  $\beta 2$ ), platelet derived endothelial growth factors, vascular endothelial growth factors (VEGF), epidermal growth

factor (EGF), Interleukin 1&2, basic fibroblast growth factor ( $\beta$ -FGF) and platelet activating factor 4 (PAF-4)<sup>7</sup>. All these factors play a role in resurfacing of wound, restoring vascular integrity and replacing lost tissue.

Recent clinical and histological results imply that the use of platelet concentrate may enhance bone regeneration when used in conjunction with bone grafts<sup>8</sup>. The platelet derived growth factor (PDGF) and transforming growth factor (TGF) beta is seen as an available and practical tool for the enhancement of the rate of bone formation and the final quality of bone formed<sup>9</sup>. PRF has quite a lot of advantages over platelet rich plasma (PRP). It eliminates the need to neutralize and unnecessary process of adding anticoagulant as well as<sup>10</sup>. Studies suggest that it increases the rate of clinical graft consolidation, and PRF- enhanced grafts produce dense bone and more mature than grafts without PRF. In combination with bone grafts, it offers several advantages including bone growth and maturation, graft stabilization, promotes wound healing and hemostasis. But like PRP there is a lack of long term controlled trials for the use of PRF and further research in this area is required to take full advantage of this material.

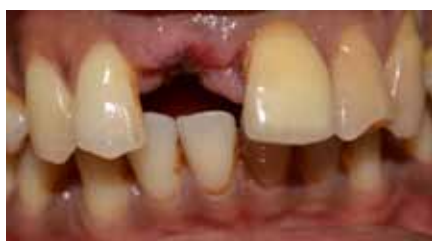

Fig. 1: Preoperative intraoral photograph

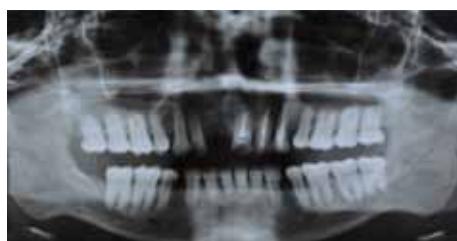

Fig. 2: Preoperative orthopantomogram

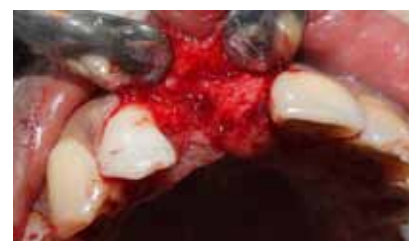

Fig. 3: Flap reflection

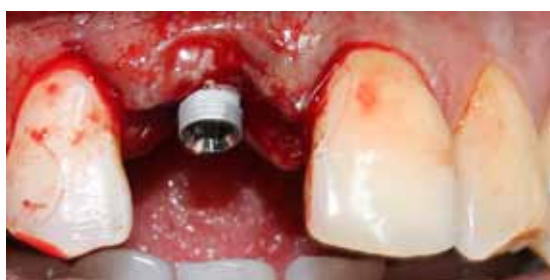

Fig. 4: Implant placement after osteotomy



Fig. 5: Preparation of PRF



Fig. 6: PRF mixed with graft

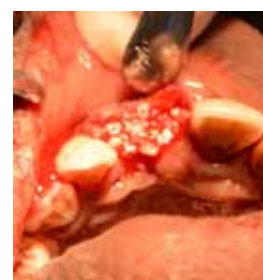

Fig. 7: PRF placement at the surgical site

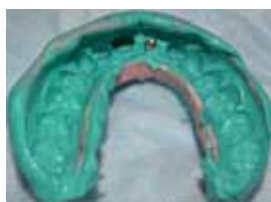

Fig. 8: Impression

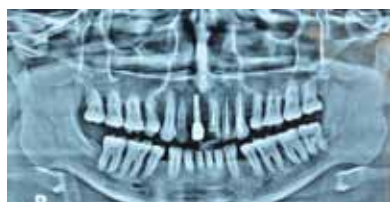

Fig. 9: Post operative orthopantomogram

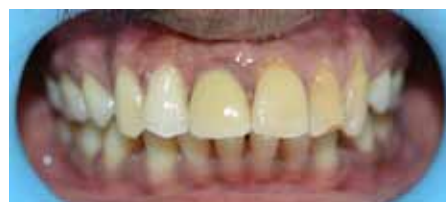

Fig. 10: Post operative orthopantomogram



Fig. 11: Post-operative patient photograph

### ► Conclusion

The present case report reveals the synergistic effect of PRF on bone formation around the implant placed in the anterior maxillary central incisor region. The results obtained could be because of biological properties of the material and its ability to promote healing. The biomaterial appears to be quite promising and further research is required to explore its full potential.

### ► References

1. Barber HD, Seckinger RJ, Silverstein K, Abughazaleh K. Comparison of soft tissue healing and osseointegration of implants placed in one-stage and two-stage techniques: a pilot study. *Implant Dent.* 1996;5(1):11-14.
2. Choukroun J, Diss A, Simonpieri A, Girard MO, Schoeffler C, Dohan SL, et al. Platelet rich fibrin: a second generation platelet concentrate. Part IV: clinical effects on tissue healing *Oral Surg Oral Med Oral Pathol Oral Endod.* 2006;101(3):56-60.
3. Dohan DM, Choukroun J, Diss A, Dohan SL, Dohan AJ, Mouhyi J, et al. Platelet rich fibrin: A second generation platelet concentrate. Part II: platelet related biologic feature. *Oral Surg Oral Med Oral Pathol Oral Endod.* 2006;101(3):45-50.
4. Jang ES, Park JW, Kweon H, Lee KG, Kang SW, Baek DH, et al. Restoration of peri-implant defects in immediate implant installations by Choukroun platelet-rich fibrin and silk fibroin powder combination graft. *Oral Surg Oral Med Oral Pathol Oral Radiol Endod.* 2010;109(6):831-36.
5. Peck MT, Marne wick J, Stephan LX, Singh A, Patel N, Majeed A. The use of leukocyte and platelet rich fibrin(L-PRF) to facilitate implant placement in bone deficient: a report of two cases. *SADJ.* 2012;67(2):54-49.
6. Lee JW, Kim SG, Kim JY, Lee YC, Choi JY, Draços R, et al. Restoration of a perimplant defect by platelet -rich fibrin.. *Oral Surg Oral Med Oral Pathol Oral Endod.* 2012;113(4):459-63.
7. Vijayalakshmi R, Rajmohan CS, Deepalakshmi D, Sivakami G. Use of platelet rich fibrin in a fenestration defect around an implant. *J Indian Soc periodontal.* 2012;16(1):108-12
8. Kassolis JD, Rosen PS, Reynolds MA. Alveolar ridge and sinus augmentation utilizing platelet rich plasma in combination with freeze dried bone allograft; case series. *J Periodontol.* 2000;71:1654-6.
9. Lynch SE, Genco RJ, Marx RE. *Quinte; Tissue engineering: Applications in maxillofacial surgery and periodontics.* London: Quintessence Publishing Co, Inc; 1999. pp. 71-82.
10. Toffler M, Toscano N, Holtzclaw D, Corso MD, Dohan Ehrenfest DM. Introducing Choukroun's platelet rich fibrin (PRF) to the reconstructive surgery milieu. *J Implant Adv Clin Dent.* 2009;1:21-30.



# Link between periodontitis and metabolic syndrome

\* Jaziya Bhanu, \*\*Rosamma Joseph V, \*\*\* Jerry Mammen

## Abstract

Metabolic syndrome is defined by a collection of interconnected physiological, biochemical, clinical, and metabolic factors that increase the risk of cardiovascular disease and type 2 diabetes mellitus. Insulin resistance, visceral adiposity, atherogenic dyslipidemia, endothelial dysfunction, genetic susceptibility, elevated blood pressure, hypercoagulable state, and chronic stress are the several factors which constitute the syndrome. Metabolic syndrome can influence the pathogenesis of periodontitis. In obese subjects, adipose tissue produces cytokines (IL-1, IL-6 and TNF- $\alpha$ ), adipokines (leptin, adiponectin, resistin and plasminogen activator inhibitors-1) and prostaglandins, which play an important role in tissue destruction during periodontal disease. Dyslipidemia and hyperglycemia associated with metabolic syndrome can also affect the immunoinflammatory status. This review addresses the link between metabolic syndrome and periodontitis.

KDJ 2016 | Vol. 39 | No. 3 | Pg 191-194

## ► Introduction

Metabolic syndrome (MS) is a complex pathologic condition that combines multiple risk factors for cardiovascular disease. It is defined by the presence of visceral obesity, elevated triglycerides, decreased high density lipoprotein (HDL), elevated blood pressure and blood glucose. The presence of atleast three of these factors

characterizes the syndrome. Metabolic Syndrome (MS) is the term proposed by the World Health Organization<sup>1</sup> (WHO), which outlines a set of risk factors for cardiovascular diseases (CVDs).

## ► Criteria for diagnosis

MS definition is performed through biochemical, anthropometric and hemodynamic indicators. WHO and the National Cholesterol Education Program's Adult Treatment Panel III (NCEP – ATP – III, 2001) includes different international organizations formulating criteria for MS definition. The definition by WHO asserts the evaluation of the insulin resistance, whereas the definition by NCEP-ATP III does not demand the measurement of the insulin resistance, which makes it more acceptable for epidemiological studies<sup>1,2</sup>. The International Diabetes Federation (IDF) conducted a consensus conference on MS definition, in which the ethnic differences were included in the criteria of diagnosis, and it emphasized the focus on the visceral obesity as the main component<sup>3</sup>.

## I. International diabetes federation Criteria<sup>3</sup>. (IDF 2006)

MS is diagnosed if there is Central obesity (BMI>30kg/m<sup>2</sup>, waist circumference> 90 cm for men or >80 cm for women) and any two of the following:

Raised triglycerides >150mg/dl (1.7mmol/l), reduced HDL cholesterol <40mg/dl (1.03mmol/l) for men and <50mg/dl (1.29mmol/l) for women, raised blood pressure: systolic BP>130

mmHg or Diastolic BP>85 mmHg, a raised fasting blood glucose >100mg/dl.

## II. World Health Organization Criteria<sup>1</sup>. (WHO1999)

The WHO criterion requires the presence of Diabetes mellitus, impaired glucose tolerance insulin resistance and any two of the following:

Blood pressure  $\geq$  140/90 mmHg, Dyslipidemia- triglyceride  $\geq$  1.7mmol/l, high density lipoprotein cholesterol  $\leq$  0.9mmol/l for men and  $\geq$  1.0mmol/l for women, central obesity (BMI >30kg/m<sup>2</sup>, waist to hip ratio >0.90 for men, 0.85 for women)

## III. European Group for the study of insulin Resistance<sup>4</sup>. (EGIR1999)

The European group for the study of insulin resistance requires insulin resistance and any two or more of the following: Central obesity - waist circumference > 94cm for men and  $\geq$  80cm for women. Dyslipidemia-TG  $\geq$  2.0 mmol/l and HDLC <1.0 mmol/l. Hypertension BP  $\geq$  140/90mmHg and a fasting blood glucose  $\geq$  6.1mmol/l

## IV. National Cholesterol Education Program Adult Treatment Panel III<sup>2</sup>. (NCEP-ATP-III, 2002)

At present, a clinical diagnosis of MS is made by fulfillment of 3 of the following 5 criteria:

1. Increased waist circumference: population and country specific definition can be used. WC  $\geq$  102cm in men or  $\geq$  88cm in women (for Indian population)

\*Junior Resident, \*\*Professor and HOD, \*\*\*Senior Resident, Dept of Periodontics, Govt Dental College, Calicut  
• Corresponding Author: Dr. Rosamma Joseph V, Email: drrosammajoseph@gmail.com

2. Elevated triglycerides (drug treatment for elevated triglycerides is an alternate indicator):  $\geq 150$  mg/dL (1.7mmol/L).
3. Reduced HDLC (drug treatment for reduced HDLC is an alternate indicator):  $< 40$  mg/dL (1.0mmol/L) in males and  $< 50$  mg/dL (1.0mmol/L) in females.
4. Elevated blood pressure (antihypertensive drug treatment in a patient with a history of hypertension is an alternate indicator): systolic  $\geq 130$  mmHg and/or diastolic  $\geq 85$  mmHg.
5. Elevated fasting glucose (drug treatment of elevated glucose is an alternate indicator):  $\geq 100$  mg/dL.

### Pathogenesis

The insulin resistance and proinflammatory states play a key role in the MS pathogenesis. Metabolic syndrome is a complex collection of components that are thought to arise from a visceral fat-type obesity involving hypertension, abnormal glucose and lipid metabolism<sup>5</sup>. The adipose tissues are a large reservoir of biologically active mediators of inflammation such as TNF- $\alpha$ , IL-6, and adipokines (leptin, resistin and adiponectin). Leptin causes fat to deposit primarily in adipocytes and its deficiency in obesity leads to tissue deposition of fat. This ectopic distribution of fat, particularly its visceral or central component, causes insulin resistance. Tumour necrosis factor- $\alpha$  and interleukin-6 may also increase insulin resistance. Visceral adipocytes are metabolically more active and excess adipose tissue lipolysis leads to increased plasma concentrations of free fatty acids. Excess free fatty acids are diverted to the liver, which alters lipoprotein production in liver, thereby causing an increase in triglyceride levels and decrease in HDL level<sup>6</sup>. Increased plasma free fatty acid level also leads to impaired insulin secretion by  $\beta$ cells resulting in hyperglycemia. Leptin also stimulates the sympathetic nervous system, leading to angiotensinogen release in to blood, which causes vasoconstrictive effects on blood vessels, contributing to hypertension<sup>7</sup>. Numerous studies have linked cardiovascular disease<sup>8</sup>, cerebro vascular disease<sup>9</sup> and periodontal disease<sup>10</sup> with risk factors for MS (TYPE 2 DM, obesity and elevated blood pressure levels).

### Link between periodontitis and components of metabolic syndrome

Periodontitis is an immunoinflammatory disease affecting the supporting tissues of the teeth resulting from a complex interplay between specific gram-negative microorganisms, their by-products and the host-tissue response. This results in progressive destruction of the periodontal ligament, alveolar bone, cementum and gingiva. It is now recognized that the periodontopathic gram-negative bacteria and bacterial products, such as lipopolysaccharides, activate the host immune response significantly and their actions have consequences beyond

periodontal tissues. Pro-inflammatory cytokines, such as IL-1, IL-6, C-reactive protein, TNF- $\alpha$  and MMP's are significantly elevated during the destructive phase of periodontitis and it has an impact on the general health status, including systemic low-grade inflammation<sup>11</sup>. These inflammatory mediators may have a profound influence in the pathogenesis of many systemic diseases. It acts as a risk factor for a variety of systemic diseases/conditions, including coronary artery disease, atherosclerosis, stroke, diabetes mellitus and metabolic syndrome etc<sup>12</sup>.

### Diabetes and Periodontal Disease

Löe et al reported periodontitis as the sixth complication of diabetes<sup>13</sup>. Diabetic patients are more susceptible to develop periodontal disease because of the polymorphonuclear leukocytes and alterations in the collagen metabolism. The formation of AGEs affects the collagen stability and the vascular integrity. AGEs aggregate macrophage and monocyte receptors and they may also stimulate the releasing of interleukin-1 and TNF- $\alpha$ , which provokes an increase of the susceptibility to periodontal disease<sup>14</sup>. The increased production of inflammatory cytokines in periodontitis induces the insulin resistance.

### Obesity and periodontitis

The obesity, defined by the body mass index (BMI) greater than 30.0 kg/m<sup>2</sup>. The fat tissue, especially the visceral type, acts as an important endocrine organ secreting several bioactive substances, such as adipocytokines- tumor necrosis factor-alpha, leptin, adiponectin and resistin. Leptin controls the appetite, regulates the immune response and the production of inflammatory cytokines. The obesity is associated with the reduction of the sensitivity to the effects of the leptin which stimulates the immunological system<sup>15</sup>. In periodontitis there is a negative correlation among the levels of leptin in the gingival crevicular fluid. Adipocytes secreting proinflammatory cytokines may be the molecules linking obesity to the pathogenesis of periodontal infection. In periodontitis, the release of the tumor necrosis factor-alpha both by the liver and the periodontal tissues in response to LPS, endotoxins of gram negative periodontal pathogens, would contribute to the insulin resistance.

### Dyslipidemia and Periodontal disease

Factors mainly involved in increase of the lipid levels in the blood are: the genetics, diet rich in fat, the metabolic disturbance and the lack of the physical exercises. Hyperlipidemia has a dysregulating effect on the immune-system cells and tissue healing, increasing the susceptibility to infections, such as periodontitis. The alteration in the phenotype of immune cells because of the lipids and the serum elevation of proinflammatory cytokines, such as TNF- $\alpha$  and IL-1 $\beta$  from

**Table 1:** Studies showing association between MS and periodontitis

Author, year and reference	Study design	Sample size	Parameters	Results
Shimazaki et al 2007 <sup>10</sup>	Cross sectional	584	BMI, TC, HDL, BP, FPG, PD, CAL	↑CAL & PD in MS subjects
Yousuf Khader et al 2008 <sup>18</sup>	Case control	156	PI, GI, PD, CAL	≥3mm PD, CAL in MS as compared to controls
Peng Li et al 2009 <sup>19</sup>	Case control	152	BOPI, CAL	↑BOPI, CAL in MS
Kushiyama et al 2009 <sup>20</sup>	Cross sectional	1070	BMI, HT, HDL, TG, CPI	↑BP and ↓HDL in CPI code 4, ↑comp of MS=↑CPI code
Morita et al 2010 <sup>21</sup>	Longitudinal study	1023	BP, TG, HDL, PD	Periodontal pockets associated with positive conversion of MS components.
Andriankaja et al 2010 <sup>22</sup>	Cross sectional	7431	BMI, TG, HDL, HT, CPI, PD	MS associated with periodontitis

chronic periodontitis evidenced the bidirectional relationship between the two conditions<sup>16</sup>.

### Hypertension and periodontitis

Hypertension is a highly prevalent multifactorial disease and is one of the main causes of cardiovascular mortality and morbidity. The periodontal disease may stimulate the systemic inflammation linked to CVDs. Moreover, the chronic inflammation and the inflammatory cytokines may cause endothelial dysfunction, establishing a connection between inflammation and risk for CVDs<sup>17</sup>. This connection could be mediated by alterations in the vascular resistance and blood pressure.

Studies have shown a positive association between MS and periodontitis and table 1 outlines the major findings in each study.

### Triangular relationship between periodontitis, diabetes and obesity.

Robert J Genco et al in 2005<sup>23</sup> reported that inflammation generates a triangular interaction between obesity, diabetes and periodontal disease: Obesity is a risk factor for both type 2


diabetes and periodontal infection, and diabetes also increases the risk for periodontal disease and obesity. Proinflammatory cytokines links all these conditions through the pathway of inflammation (fig. 1). This points to a possible three-way relationship between adiposity, diabetes and periodontal disease with each condition influencing the others and inflammation provides the two-way channel between each of them.

### ► Conclusion

The association between periodontal disease and metabolic syndrome is compatible with the hypothesis that the chronic inflammation is an important factor in the physiopathology underlying to these conditions. The local and systemic alterations initiated by the periodontal disease may contribute to a chronic inflammatory state, increasing the probability of developing metabolic syndrome and cardiovascular disease. The complex interaction of the inflammatory response of the host to the periodontal infections, obesity and to the alterations of the lipid levels may be responsible for the state of insulin resistance reported in individuals with periodontal disease. Such understanding may explain the association among periodontal diseases, metabolic syndrome and increase of the future risk of CVDs and diabetes.

### ► References

1. Alberti KGMM, Zimmet Pf. Definition, diagnosis and classification of diabetes mellitus and its complications. Part 1: diagnosis and classification of diabetes mellitus. Provisional report of a WHO consultation. *Diabetic medicine* 1998;15:539-553.
2. Expert Panel on D, Evaluation, and Treatment of High Blood Cholesterol in A. Executive summary of the third report of the national cholesterol education program (ncep) expert panel on detection, evaluation, and treatment of high blood cholesterol in adults (adult treatment panel iii). *JAMA* 2001;285:2486-2497.
3. Zimmet P, Alberti K, Shaw J. International Diabetes Federation: the IDF consensus worldwide definition of the metabolic syndrome. *Diabetes voice* 2005;50:31-33.
4. Balkau B, Charles M-A. Comment on the provisional report from the WHO consultation. *Diabetic medicine* 1999;16:442-443.



**Fig. 1:** Schematic representation of Triangular relationship between obesity, diabetes and periodontitis

5. Matsuzawa Y, Funahashi T, Nakamura T. The concept of metabolic syndrome: contribution of visceral fat accumulation and its molecular mechanism. *Journal of atherosclerosis and thrombosis* 2011;18:629-639.
6. Sheehan MT, Jensen MD. Metabolic complications of obesity: Pathophysiologic considerations. *Medical Clinics of North America* 2000;84:363-385.
7. Shankar P, Sundarka M. Metabolic syndrome: Its pathogenesis and management. *J Indian Acad Clin Med* 2003;4:275-281.
8. Mottillo S, Filion KB, Genest J, et al. The metabolic syndrome and cardiovascular risk: a systematic review and meta-analysis. *Journal of the American College of Cardiology* 2010;56:1113-1132.
9. Aygencel G, Karamercan A, Akinci E, Demircan A, Keles A. Metabolic syndrome and its association with ischemic cerebrovascular disease. *Advances in therapy* 2006;23:495-501.
10. Shimazaki Y, Saito T, Yonemoto K, Kiyohara Y, Iida M, Yamashita Y. Relationship of metabolic syndrome to periodontal disease in Japanese women: the Hisayama Study. *Journal of dental research* 2007;86:271-275.
11. Bustos DA, Grenón MS, Benitez M, Boccardo Gd, Pavan JV, Gendelman H. Human papillomavirus infection in cyclosporin-induced gingival overgrowth in renal allograft recipients. *Journal of periodontology* 2001;72:741-744.
12. Akar H, Akar GC, Carrero JJ, Stenvinkel P, Lindholm B. Systemic consequences of poor oral health in chronic kidney disease patients. *Clinical Journal of the American Society of Nephrology* 2011;6:218-226.
13. Loe H. Periodontal disease: the sixth complication of diabetes mellitus. *Diabetes care* 1993;16:329-334.
14. Janket S-J, Jones JA, Meurman JH, Baird AE, Van Dyke TE. Oral infection, hyperglycemia, and endothelial dysfunction. *Oral Surgery, Oral Medicine, Oral Pathology, Oral Radiology, and Endodontology* 2008;105:173-179.
15. Pischon N, Heng N, Bernimoulin J-P, Kleber B-M, Willich S, Pischon T. Obesity, inflammation, and periodontal disease. *Journal of dental research* 2007;86:400-409.
16. Fentoğlu Ö, Köroğlu BK, Hiçyılmaz H, et al. Pro-inflammatory cytokine levels in association between periodontal disease and hyperlipidaemia. *Journal of clinical periodontology* 2011;38:8-16.
17. Odili AN, Staessen JA. Periodontal disease and hypertension: a chicken and egg story? *Journal of hypertension* 2010;28:2382-2383.
18. Khader Y, Khassawneh B, Obeidat B, et al. Periodontal status of patients with metabolic syndrome compared to those without metabolic syndrome. *Journal of periodontology* 2008;79:2048-2053.
19. Li P, He L, Sha Y-q, Luan Q-x. Relationship of metabolic syndrome to chronic periodontitis. *Journal of periodontology* 2009;80:541-549.
20. Kushiya M, Shimazaki Y, Yamashita Y. Relationship between metabolic syndrome and periodontal disease in Japanese adults. *Journal of periodontology* 2009;80:1610-1615.
21. Morita T, Yamazaki Y, Mita A, et al. A cohort study on the association between periodontal disease and the development of metabolic syndrome. *Journal of periodontology* 2010;81:512-519.
22. Andriankaja O, Sreenivasa S, Dunford R, DeNardin E. Association between metabolic syndrome and periodontal disease. *Australian dental journal* 2010;55:252-259.
23. Genco RJ, Grossi SG, Ho A, Nishimura F, Murayama Y. A proposed model linking inflammation to obesity, diabetes, and periodontal infections. *Journal of periodontology* 2005;76:2075-2084.

# Is Azithromycin an effective adjunctive immunomodulator in periodontal therapy

\* Rosamma Joseph V, \*\*Meera S, \*\*\*Harikumar Menon

## Abstract

Periodontitis is an inflammatory disease involving the periodontium, resulting from bacterial infection and subsequent host response. Use of systemic antibiotics as adjuvant to conventional periodontal therapy results in improvement of clinical parameters such as probing depth and periodontal attachment. Amoxicillin, metronidazole and tetracycline used in periodontitis have longer dosage regimen which increases the chances of noncompliance. Since periodontitis is an immunoinflammatory disease, antibiotics with additional immunomodulating property would be beneficial in periodontal therapy. Azithromycin (AZM), a macrolide antibiotic have enhanced in vivo potency (against gram-negative bacteria), greater tissue penetration, longer half-life and significant immunomodulatory /anti-inflammatory properties. This paper reviews the role of AZM when used as adjuvant to non-surgical therapy for periodontitis, and in resolving drug-related gingival overgrowth. Despite for its advantages AZM can alter the electrical activity of heart, it should be used cautiously in patients who have high baseline risk of cardiovascular disease.

KDJ 2016 | Vol. 39 | No. 3 | Pg 195-198

## ► Introduction

Periodontitis is an inflammatory diseases involving the periodontium, resulting from bacterial infection and subsequent host response. Three

hypothesis non specific, specific and multiple pathogen hypothesis, corroborate that periodontitis is initiated by periodontopathogens found in the supra or subgingival biofilm. Sequelae of periodontitis include periodontal attachment loss, loss of alveolar bone and in severe cases, tooth exfoliation. Large number of epidemiologic studies have revealed the association between periodontal diseases and systemic diseases, such as cardiovascular disease and stroke. Certain periodontal pathogens have also been detected from affected regions of atherosclerosis, abdominal aortic aneurysms, and buerger disease, suggesting that local infection by periodontopathic bacteria and transient bacteremia may play a role in the pathogenesis of these systemic diseases.

Conventional therapy for periodontitis is based on suppression of subgingival infectious foci by mechanical debridement of supra and subgingival biofilm by scaling and root planing combined with adequate periodontal supportive therapy. However, certain sites continue to deteriorate despite conventional periodontal therapy and periodontopathogens may occasionally invade periodontal tissues and dental canaliculi from where they cannot be completely removed. A number of studies substantiate the use of systemic antibiotics as adjuvant treatment resulting in improvement of clinical parameters such as probing depth and periodontal attachment in both aggressive and chronic periodontitis. However the

targeted bacterial populations within the periodontal pocket represent part of complex biofilm communities, which makes them more virulent and less susceptible and impermeable to antimicrobials than bacteria in planktonic populations. It is therefore well established that biofilm-associated periodontal diseases cannot be treated by chemical agents (such as antibiotics) alone. Hence initial mechanical disruption of the biofilm is of paramount importance to improve the efficacy of the antibiotic therapy<sup>1</sup>.

Since most periodontopathogens are Gram-negative, a combination of amoxicillin & metronidazole and tetracycline specifically targeting Gram-negative bacteria have been used in periodontitis. However, regardless of their clinical benefits, longer dosage regimen (7–14 days) with 3–4 doses per day increases the chances of noncompliance. In addition, their use has been associated with a range of side effects and with bacterial resistance<sup>2</sup>. Since periodontitis is an immunoinflammatory disease, antibiotics with additional host modulating property would be beneficial in periodontal therapy.

Azithromycin (AZM) first synthesized in 1980 have enhanced in vivo potency against gram-negative bacteria, greater tissue penetration, longer half-life and significant immunomodulatory /anti-inflammatory properties<sup>3</sup>. Therefore macrolides, including azithromycin, are

\* Professor and HOD, \*\*Junior Resident, \*\*\*Associate Professor, Dept. of Periodontics, Govt Dental College, Calicut  
• Corresponding Author: Dr. Rosamma Joseph V, Email: drrosammajoseph@gmail.com

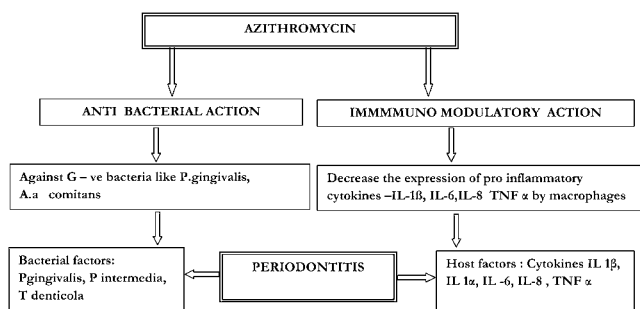


Fig 1: Model showing the adjunctive use of Azithromycin in periodontal therapy

being used to treat wide spectrum of diseases ranging from infectious (respiratory tract infection, periodontitis), drug-induced gingival overgrowth and non infectious disease such as severe asthma, chronic obstructive pulmonary diseases.

### Chemical structure, pharmacokinetics, dosage and side effects

Azithromycin (9-Deoxy-9a-aza-9a-methyl-9a-homoerythromycin) a 15-membered lactone macrolide ring compound, is derived from erythromycin by the addition of methylated nitrogen into the lactone ring. This structural modification results in significant changes in pharmacokinetics better acid stability, greater tissue penetration wider antibacterial spectrum, low toxicity and a long half-life of approximately 68 hours<sup>3</sup>. Thus once daily 500 mg tablet orally, one hour before food for 3 consecutive days is the most common dosage regime. Shorter course of administration and low incidence of side effects results in better patient compliance. Adverse drug reactions are seen in approximately 5% of subjects, ranging from nausea, abdominal pain and diarrhea to rare, serious, allergic reactions, including angioedema and anaphylaxis. Eventhough drug reactions are uncommon, a study in the New England Journal of Medicine in 2012 reported that there was an increase in cardiovascular death among patients receiving azithromycin; this increase was most pronounced among patients with a high baseline risk of cardiovascular disease<sup>4</sup>.

### Mechanism of action and antibacterial spectrum

Azithromycin, a reversible inhibitor of bacterial protein synthesis, binds to 50S ribosomal RNA and blocks the aminoacyl translocation reaction and formation of initiation complexes. It differs from other macrolides mainly in pharmacokinetic properties. A 500mg dose of azithromycin produces relatively low serum concentrations of approx 0.4 mcg/ml. However, azithromycin penetrates into most tissues and phagocytic cells extremely well, with tissue concentrations exceeding serum concentrations by 10 to 100 fold. Then released from tissues at much slower rate (tissue half-life of 2-4 days) to produce an elimination half life approaching 3 days, thus enabling azithromycin to combat bacterial infections at a lower dosage and shorter treatment regimes than other antibiotics. It has bacteriostatic effects against gram-positive

bacteria such as *Staphylococcus aureus* and *Streptococcus pyogenes*, and strong antibacterial activity against gram-negative anaerobic bacteria in comparison to erythromycin and clarithromycin<sup>5</sup>. It is effective against Endocarditis associated enteric pathogens and gram-negative bacilli such as *Escherichia coli*, *Salmonella enteritidis* and *Aggregatibacter actinomycetemcomitans* (involved in aggressive periodontitis). *Porphyromonas gingivalis*, a common periodontal pathogen is susceptible to low doses of azithromycin<sup>6</sup>.

### Immunomodulatory properties of azithromycin

The spectrum of action of macrolides extends from the reduction of inflammation, antibacterial, regulation of neutrophil and macrophage activity and production of cytokines, to altering fibroblast activity and host immunity (Fig 1). Intact epithelium represents a physical and immunologic barrier acting as primary defense line against infectious agents. Epithelial cells activated by pathogenic microbes produce several proinflammatory cytokines, such as IL-1, IL-6, IL-8, and TNF- $\alpha$ <sup>7</sup>. Therefore cells potentially participate in the initiation and development of inflammation and immune response. Azithromycin was found to increase the number of actively phagocytosing alveolar macrophages and to decrease the expression of proinflammatory cytokines [interleukin (IL)-1 $\beta$ , IL-6, IL-8 and tumour necrosis factor (TNF)- $\alpha$ ] in vitro<sup>8</sup>. IL-8 is a major proinflammatory cytokine responsible for activation and chemotaxis of neutrophils, T lymphocytes and dendritic cells to the inflammatory sites. Matsumura et. al. demonstrated inhibition of IL-8 production by AZM via down regulating levels of NF-kB/p659. Although the exact mechanism is yet not clear but AZM significantly inhibits LPS-induced Rac1 and NF-kB activation and IL-8 expression<sup>9</sup>. Thus AZM partially modify the innate immunity mechanism and has an anti-inflammatory effect on human oral epithelial cells. More recently, Ho et al reported that AZM decreases GCF volume and mediator contents, including IL-1 $\beta$ , IL-8, TNF- $\alpha$ , and vascular endothelial growth factor<sup>10</sup>.

Azithromycin shows extensive systemic distribution and gets readily concentrated within PMNs, macrophages and fibroblasts, with a high degree of retention following oral administration<sup>11</sup>. Azithromycin uptake continues for at least 24 hours. In contrast, the uptake of erythromycin completes within the first 30 min. Thus at 24 h, azithromycin was concentrated 10-fold higher than erythromycin. Large volume of fibroblasts in gingival connective tissue serves as reservoirs for azithromycin thus attaining 25-fold higher concentrations than the corresponding levels in blood. The ability of azithromycin to penetrate and concentrate in phagocytes may explain why azithromycin is effective against intracellular pathogens. Azithromycin also exhibits a prolonged post-antibiotic effect on inhibition of bacterial regrowth. It

can penetrate the biofilm surface and partially dissolve the biofilm<sup>12</sup>. Even though azithromycin gets concentrated more in PMNs and macrophages, it does not decrease phagocyte-mediated bactericidal activity or affect PMN or macrophage oxidative burst activity.

### Evidence for the role of azithromycin in periodontal disease

#### **AZM as adjuvant in treatment of chronic periodontitis:**

Smith 2002 reported that in chronic periodontitis patients, adjuvant treatment with AZM led to significant reduction in probing pocket depth when compared to control group<sup>13</sup>. Schmidt EF et al noticed radiographic evidence of significant bone growth when azithromycin was taken in conjunction with scaling and root planing in patients who had severe localized periodontal defects<sup>14</sup>. However Sampaio 2011 evaluated the clinical and microbiological parameters of 40 patients with chronic periodontitis and found no additional clinical benefits of AZM as adjuvant to conventional mechanical periodontal treatment<sup>15</sup>.

#### **AZM in the treatment of aggressive periodontitis:**

Haas et al 2008 in his study involving 24 patients diagnosed with aggressive periodontitis, administered AZM for 3 consecutive days (500 mg/day). Although periodontal attachment levels remained similar in treatment and control group for 3 months, but continued to improve in patients receiving AZM, at 6 and 12 months.<sup>16</sup>

#### **Topical administration of AZM:**

Pradeep et al 2008 used topical formulation of AZM (0.5%) and reported reduction in probing depth and improved periodontal attachment as compared to controls. It was corroborated that topical application facilitated the penetration of the drug into, the periodontal tissues, enhancing the bactericidal effect without systemic side effects or the development of bacterial resistance<sup>17</sup>.

**AZM in bacteremia:** The repeated entry of bacteria into the bloodstream during periodontal procedures, such as flossing, periodontal probing, subgingival irrigation, scaling and root planing, and dental extractions, could cause high levels of bacteremia. However Gomi et al 2007 and Morozumi et al, 2010 reported that AZM was effective in reducing bacteremia incidence by administration three days prior to mechanical periodontal therapy compared to the control group<sup>18,19</sup>.

**AZM in smokers:** Paulo Mascarenhas et al in a trial evaluated clinical and microbial effect of SRP alone or SRP + AZM among smokers with moderate to severe chronic periodontitis. It was found that AZM in combination with SRP improves the efficacy of non-surgical periodontal therapy by reducing probing depth and improving attachment levels in smokers<sup>20</sup>.

**Azithromycin and gingival overgrowth:** Wahlstrom E et al 1995 prescribed Azithromycin to treat chest infections in two patients with substantial inflammatory gingival overgrowth related to cyclosporine A. They reported that gingival bleeding resolved over a period of 3–4 months and gingival overgrowth resolved in one patient and regressed in the other, without periodontal intervention or reduction in the dose of cyclosporine A<sup>21</sup>. Similar results were reported by Nowicki M et al, where AZM improved the symptoms of cyclosporine A-induced gingival overgrowth, by blocking the ability of cyclosporine A to induce cell proliferation and collagen production, and activated MMP2 in both healthy and gingival overgrowth fibroblasts<sup>22</sup>. It is perplexing that, this property of azithromycin remains largely unknown in periodontal therapy. Thus definitive clinical studies are further needed to determine whether azithromycin alone, or as an adjunct to periodontal therapy, can enhance the management of gingival overgrowth related to cyclosporine A, calcium-channel blockers and phenytoin.

### ► Conclusion

The ultimate goal of periodontal therapy is restoration and maintenance of the periodontium in a state of health, function, and esthetics. Evidence from literature support the use of azithromycin in the treatment of periodontal infection because of its increased acid stability, increased distribution, decreased binding to plasma proteins, and rapid absorption. Other characteristics of the drug are its activity against periodontal pathogens, short treatment regimen and good patient compliance, low incidence of side effects, persisting antibiotic effects and increased concentration found in cells such as neutrophils, macrophages, fibroblasts, monocytes, and epithelial cells and its immunomodulatory property. Because of all these added benefits azithromycin can be considered as more than an antibiotic in management of periodontal disease. Future studies should confirm its ability to enhance the treatment of refractory forms of periodontitis and gingival overgrowth by antibacterial activity and host modulation. As this drug can alter the electrical activity of heart, this antibiotic should be used cautiously in patients who have high baseline risk of cardiovascular disease.

### ► References

1. Costerton JW, Lewandowski Z, Caldwell DE, Korber DR, Lappin-Scott HM. Microbial biofilms. *Annual Reviews in Microbiology* 1995;49:711-745.
2. Greenberg RN. Overview of patient compliance with medication dosing: a literature review. *Clinical therapeutics* 1983;6:592-599.
3. Gomi K, Yashima A, Iino F, et al. Drug concentration in inflamed periodontal tissues after systemically administered azithromycin. *Journal of periodontology* 2007;78:918-923.
4. Ray WA, Murray KT, Hall K, Arbogast PG, Stein CM. Azithromycin and the risk of cardiovascular death. *New England Journal of Medicine* 2012;366:1881-1890.
5. Kitzis M, Goldstein F, Mieg M, Acar J. In-vitro activity of azithromycin against various Gram-negative bacilli and anaerobic bacteria. *Journal of antimicrobial Chemotherapy* 1990;25:15-18.

6. Pajukanta R. In vitro antimicrobial susceptibility of *Porphyromonas gingivalis* to azithromycin, a novel macrolide. *Oral microbiology and immunology* 1993;8:325-326.
7. Eckmann L, Kagnoff M, Fierer J. Epithelial cells secrete the chemokine interleukin-8 in response to bacterial entry. *Infection and immunity* 1993;61:4569-4574.
8. Bosnar M, Bošnjak B, Čužić S, et al. Azithromycin and clarithromycin inhibit lipopolysaccharide-induced murine pulmonary neutrophilia mainly through effects on macrophage-derived granulocyte-macrophage colony-stimulating factor and interleukin-1 $\beta$ . *Journal of Pharmacology and Experimental Therapeutics* 2009;331:104-113.
9. Matsumura Y, Mitani A, Suga T, et al. Azithromycin may inhibit interleukin-8 through suppression of Rac1 and a nuclear factor-kappa B pathway in KB cells stimulated with lipopolysaccharide. *Journal of periodontology* 2011;82:1623-1631.
10. Ho W, Eubank T, Leblebicioglu B, Marsh C, Walters J. Azithromycin decreases crevicular fluid volume and mediator content. *Journal of dental research* 2010;89:831-835.
11. Gladue R, Bright G, Isaacson R, Newborg M. In vitro and in vivo uptake of azithromycin (CP-62,993) by phagocytic cells: possible mechanism of delivery and release at sites of infection. *Antimicrobial Agents and Chemotherapy* 1989;33:277-282.
12. Tamura A, Ara T, Imamura Y, Fujii T, Wang P. The effects of antibiotics on in vitro biofilm model of periodontal disease. *Eur J Med Res* 2008;13:439-445.
13. Smith S, Foyle D, Daniels J, et al. A double-blind placebo-controlled trial of azithromycin as an adjunct to non-surgical treatment of periodontitis in adults: clinical results. *Journal of Clinical Periodontology* 2002;29:54-61.
14. Schmidt E, Bretz W. Benefits of additional courses of systemic azithromycin in periodontal disease case report. *The New York state dental journal* 2006;73:40-45.
15. Sampaio E, Rocha M, Figueiredo LC, et al. Clinical and microbiological effects of azithromycin in the treatment of generalized chronic periodontitis: a randomized placebo-controlled clinical trial. *Journal of clinical periodontology* 2011;38:838-846.
16. Haas AN, De Castro GD, Moreno T, et al. Azithromycin as an adjunctive treatment of aggressive periodontitis: 12-months randomized clinical trial. *Journal of clinical periodontology* 2008;35:696-704.
17. Pradeep A, Sagar SV, Daisy H. Clinical and microbiologic effects of subgingivally delivered 0.5% azithromycin in the treatment of chronic periodontitis. *Journal of periodontology* 2008;79:2125-2135.
18. Gomi K, Yashima A, Nagano T, Kanazashi M, Maeda N, Arai T. Effects of full-mouth scaling and root planing in conjunction with systemically administered azithromycin. *Journal of periodontology* 2007;78:422-429.
19. Morozumi T, Kubota T, Abe D, Shimizu T, Komatsu Y, Yoshie H. Effects of irrigation with an antiseptic and oral administration of azithromycin on bacteremia caused by scaling and root planing. *Journal of periodontology* 2010;81:1555-1563.
20. Mascarenhas P, Gapski R, Al-Shammari K, et al. Clinical response of azithromycin as an adjunct to non-surgical periodontal therapy in smokers. *Journal of periodontology* 2005;76:426-436.
21. Wahlstrom E, Zamora JU, Teichman S. Improvement in cyclosporine-associated gingival hyperplasia with azithromycin therapy. *New England Journal of Medicine* 1995;332:753-754.
22. Nowicki M, Kokot F, Wiecek A. Partial regression of advanced cyclosporin-induced gingival hyperplasia after treatment with azithromycin. A case report. *Annals of transplantation: quarterly of the Polish Transplantation Society* 1997;3:25-27.



# Paradigm shift in treatment of obstructive sleep apnea

\* Ashino John, \*\* Eapen Thomas, \*\*\* Akhilesh Pratap, \*\*\* Vinesh U., \*\*\*\*Tripti Nair

## Abstract

Obstructive Sleep Apnea (OSA) is a life endangering sleep disorder which is characterized by partial or complete collapse of the upper airway during sleep. There are bouts of apnea-hypopnea during the sleep. This in turn results in episodes of sleep arousals, sleep fragmentation, hypoxemia, hypercapnia, changes in intrathoracic pressure and increased sympathetic activity. AHI (apnea-hypopnea index) assess the severity of the sleep apnea. Definitive clinical signs and symptoms are diagnostic of OSA, but the gold standard being Polysomnography. Multiple treatment modalities have been put forward by different specialties. This article reviews the available treatment modalities for OSA and emphasis upon the indication of using Maxillo Mandibular Advancement (MMA) in providing a permanent curative therapy for OSA.

KDJ 2016 | Vol. 39 | No. 3 | Pg 199-201

## ► Introduction

Burwell and co-workers<sup>1</sup> published the first description of the syndrome in 1956 from the Charles Dickens novel *The Posthumous Papers of the Pickwick Club* (1837) which had a character of an obese, somnolent, polycythaemia patient in a sleepy red-faced boy, Joe. Repeated apneas in pickwickian patients during sleep was demonstrated by Gastaut and associates<sup>2</sup> in 1966. Obstructive sleep apnea (OSA) is a sleep related disorder with episodes of apnea and hypopnea in between sleep. It is defined by American Academy of Sleep Medicine<sup>3</sup> as five or more apneas per hour

of sleep, each apnea being more than or equal to 10 sec duration. The prevalence of this disorder worldwide is estimated to be 0.3% to 5.1% in general population.<sup>4</sup> Studies among Indian population showed a male predilection with a prevalence of 4.4% to 13.7%.<sup>5</sup>

The causes of OSA is described in two categories. The most common being obstruction of the respiratory lumen either partially or completely by soft palate, tongue etc.<sup>6</sup> The other cause is a central dysfunction which control the pharyngeal muscles resulting in closure of airway during sleep.<sup>5</sup> Certain skeletal problems like retrognathia of maxilla and mandible, decreased lower facial height was found to be strongly related to OSA.<sup>7</sup> It is caused due to obstruction of the upper airway by tongue, enlarged tonsils or adenoids, retruded chin etc.

The site of Obstruction for was grouped as (Table I)

The most common being type II obstruction (soft palate and base of tongue).<sup>9</sup>

## ► Clinical features

Sleep apnea patients present with a variety of symptoms. The common one being tiredness, day time somnolence, morning head ache and nausea from the hypercarbia. They also give a history of loud snoring. Systemic hypertension is a common finding. A few patients may have cor pulmonale, polycythemia which may be life threatening. A major clinical feature of OSA is obesity.

Lowe et al<sup>10</sup> found several alterations in craniofacial form in subjects with OSA. These included a reduction in the upper

airway and impaired stability of upper airway. It showed posteriorly positioned maxilla and mandible, a large gonial angle, an anterior open bite, proclined incisors, a steep occlusal plane, over erupted maxillary and mandibular teeth, a steep mandibular plane, increased upper and lower facial heights, a posteriorly placed pharyngeal wall in association with a long tongue.

## ► Investigations

Polysomnography is the golden tool for assessing the condition. It comprises of EEG, EOG, EMG, and ECG. Respiratory distress index (RDI) can be calculated from the data in polysomnography. An RDI greater than 5 is abnormal and more than 20 is considered clinically significant.

A lateral cephalogram (Fig 1) is the basic and most helpful tool for a maxillofacial surgeon in assessing the retro palatal and retro glossal obstruction. Among the cephalometric analysis available, Delaire's analysis is preferred as it provides indication for surgical advancement if any required by analyzing the anteroposterior position of the face.<sup>11</sup> Computed tomography (CT) is an alternative to cephalometry as it provides a definitive quantitative analysis of the upper airway at various levels.

## ► Discussion

The various treatment modalities of OSA can be broadly classified into surgical and non-surgical. The use of CPAP (Continuous Positive Airway Pressure) is the most successful and widely used nonsurgical treatment in treating a broad range of OSA patient's today.<sup>12-14</sup> Among

\* PG student, \*\* Head of the Department, \*\*\*Reader, \*\*\*\* P.G. Student, Oral and Maxillofacial Surgery, Pushpagiri Dental College, Thiruvalla, Kerala • Corresponding Author: \* Dr. Ashino John E-mail: anjoashu@gmail.com

other medical management involves use of oral appliances like Herbst, Adjustable PM positioner, Elastic Mandibular Advancement etc. oral appliances are often unacceptable to the patients as it is cumbersome to wear them at night.

The surgical treatment methods include tracheostomy, nasal surgery, uvulopalatopharyngoplasty (UPPP), genial advancement, maxillomandibular advancement (MMA) and few other orthognathic surgeries. Uvulopalatopharyngoplasty was popularised among many of the surgeons as it corrected the most distressing complaint of snoring among patients. But it was later noticed that a permanent or transient velopharyngeal incompetence occurred in patients and it persisted post operatively for few months.

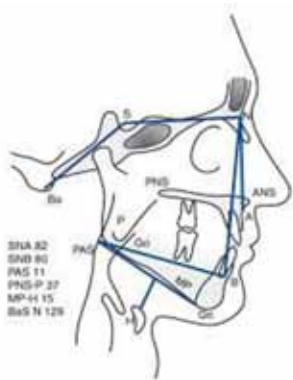
Total mandibular advancement was the first orthognathic surgical procedure used in the treatment of OSA. Kuo, Bear and Priest<sup>15-16</sup> reported complete reversal of sleep apnea symptoms in patients with horizontal mandibular deficiency treated by mandibular advancement. A bilateral sagittal ramus osteotomy is usually the procedure of choice for total mandibular advancement (Fig 2).

The other orthognathic surgery involves Genial advancement, this procedure advances the anterior belly of digastric muscle and pulls the hyoid forward improving airway. Here the outer table of the symphysis is removed and the inner table is secured with 2-mm screws. (Fig 3)

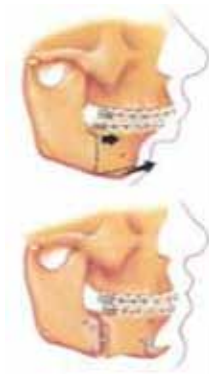
The paradigm shift in treatment of OSA is pointed out here as Maxillomandibular Advancement (Fig 4).

This procedure is the classic Lefort I osteotomy with bilateral sagittal split osteotomy advancing both maxilla and mandible and thereby increasing the posterior pharyngeal airway. According to studies conducted by Tiner and Peter<sup>17</sup>, patient selection for MMA was based on subjective symptoms of excessive daytime sleepiness, an RDI of greater than 20, and specific craniofacial characteristics determined cephalometrically. They performed surgery in 2 patients who were morbidly obese. The maxillomandibular advancement increased the airway space (Fig 5) in cephalometric radiograph and reduced the postoperative RDI values.

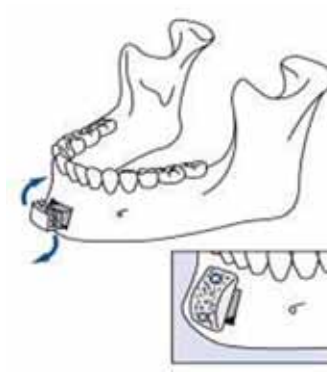
Lee et al<sup>17</sup> conducted a study where they made a three staged protocol for the treatment of OSA patients. Stage I was comprising of UPPP and inferior sagittal osteotomy with genioglossus muscle advancement or anterior mandibular osteotomy. MMA with rigid fixation was considered as stage II and was undertaken when stage I failed. A review of lateral cephalogram of OSAS patients who had undergone UPPP in his study typically showed short, thick soft palate. A comparative study on CPAP and MMA done by Vicini et al<sup>19</sup> showed that there was no significant difference in the effectiveness of the treatment methods and both showed successful outcome. In a case report Doff et al<sup>20</sup> stated MMA



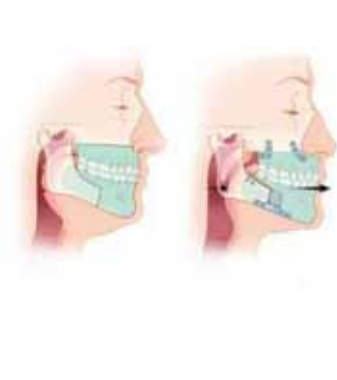
**Fig 1:** Cephalometric screening used for initial evaluation of patients with obstructive sleep apnea syndrome. (Courtesy: Tiner BD, Waite PD. Surgical and nonsurgical management of obstructive sleep apnea. In Peterson LJ, Indresano AT, Marciani RD, Roser SM, editors. Principles of Oral and Maxillofacial Surgery. Vol 3. Philadelphia: JB Lippincott; 1992; p. 1535.)



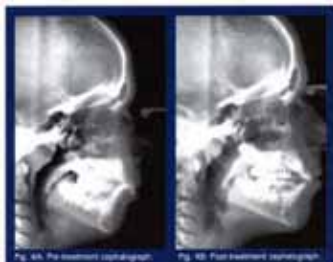**Fig 2:** Mandibular Advancement



**Fig 3:** Genial tubercle advancement.



**Fig 4:** Pre and Post Operative MMA movements (Courtesy: Tiner BD, Waite PD. Surgical and nonsurgical management of obstructive sleep apnea. In Peterson LJ, Indresano AT, Marciani RD, Roser SM, editors. Principles of Oral and Maxillofacial Surgery. Vol 3. Philadelphia: JB Lippincott; 1992; p. 1542.)



**Fig 5:** Pre and Post Operative dimension of airway space

Type I	Oropharynx
Type II	Oropharynx and Hypopharynx
Type III	Hypopharynx

**Table I:** Sites of obstruction

POSITIVE PREDICTORS OF SUCCESSFUL MMA SURGERY
BMI<30
AGE<50
NO PREVIOUS UPPER AIRWAY SURGERY
LESS SEVERE OBSTRUCTIVE SLEEP APNEA
1cm MINIMUM ANTERIOR MOVEMENT OF THE JAWS

**Table II** Positive predictors of successful MMA

as an alternative to CPAP in morbidly severe OSA. The potential complication of OSA included surgical relapse, non-union, bleeding, malocclusion, infection, unfavourable changes in the facial appearance, permanent or temporary sensory disturbances. A systemic review and meta-analysis on MMA as treatment for OSA by Holty and Guilleminault<sup>21</sup> concluded it as an efficacious and safe treatment for OSA.

### ► Conclusion

The treatment of OSA is different for individual patients based on their pathology. An ideal successful surgery is predictable in case with conditions as enumerated (Table II).

A well-tailored treatment plan is absolute essential for treating OSA. MMA has shown success in various studies and is a promising treatment entity when associated with a craniofacial deformity as well.

### ► Conflicts of interest

No conflicts of interest are raised by the authors.

### ► References

- Burwell CS, Rubin ED, Whaley RD, et al. Extreme obesity associated with alveolar hypoventilation: a pickwickian syndrome. *Am J Med* 1956;21:811.
- Gastaut H, Tassinari CA, Duron B. Polygraphic study of the episodic diurnal and nocturnal (hypnic and respiratory) manifestations of the pickwick syndrome. *Brain Res* 1966;2:167.
- Michelle TC, Christian G, Clete AK. Clinical features and evaluation of obstructive sleep apnea and upper airway resistance syndrome. In, Kryger MH, Roth T, Dement WC(ed). *Principles and Practice of Sleep Medicine*, 5 edition. St. Louis, Missouri, Elsevier, 2011; 1206- 18.
- McNicholas WT. Diagnostic criteria for sleep apnea syndrome: Time for consensus. *Eur Resp J* 1996; 9: 634-5.
- Young T, Peppard PE, Gottlieb DJ. Epidemiology of obstructive sleep apnea: a population health perspective. *Am J Respir Crit Care Med* 2002; 165:1217-39
- Zucconi M, Caprioglio A, Calori G, Ferrini-Strambi L, Oldani A, Castronovo C, Smirne S. Craniofacial modifications in children with habitual snoring and obstructive sleep apnoea: a case-control study. *Eur Respir J*. 1999 Feb;13(2):411-7.
- Riley R, Guilleminault C, Herrab J, Powell N. Cephalometric airway analyses and flow-volume loops in obstructive sleep apnea patients. *Sleep*. 1983;6(4):303-11.
- Caprioglio A, Zucconi M, Calori G, Troiani V. Habitual snoring, OSA and craniofacial modification. Orthodontic, clinical and diagnostic aspects in a case control study. *Minerva Stomatol*. 1999 Apr;48(4):125-37.
- Riley RW, Powell NB, Guilleminault C. Maxillary, mandibular, and hyoid advancement for treatment of obstructive sleep apnea: a review of 40 patients. *J Oral Maxillofac Surg* 1990;48:20.
- Lowe AA, Santamaria JD, Fleetham JA, Price C. Facial morphology and obstructive sleep apnea. *Am J Orthod* 1986; 90:484.
- Goodyday R: Treatment of obstructive sleep apnea by immediate lengthening of maxilla and mandible, in Bell WH, Guerro CA (eds): *Distraction Osteogenesis of facial skeleton*. Hamilton, ON, Canada, BC Decker, 2007, p444.
- Sullivan CE, Issa FG, Berthon-Jones M, et al. Home treatment of obstructive sleep apnea with continuous positive airway pressure applied through a nose-mask. *Bull Eur Physiopathol Respir* 1984;20:49. 53.
- Issa FG, Sullivan CE. The immediate effects of continuous positive airway pressure treatment on sleep pattern in patients with obstructive sleep apnea syndrome. *Electroencephalogr Clin Neurophysiol* 1986;63:10.
- Klein M, Reynolds LG. Relief of sleep-related oropharyngeal airway obstruction by continuous insufflation of the pharynx. *Lancet* 1986;1:935.
- Bear SE, Priest JH. Sleep apnea syndrome: correction with surgical advancement of the mandible. *J Oral Surg* 1980;38:543.
- Kuo PC, West RA, Bloomquist DS, et al. The effect of mandibular osteotomy in three patients with hypersomnia sleep apnea. *Oral Surg* 1979;48:385.
- B. D. Tiner, and Peter D. Waite, Surgical and non surgical management of obstructive sleep apnea. *Peterson's principles of oral and maxillofacial surgery*,3E, p1493-1509.
- Lee NR, Givens CD, Wilson J, Robins RB. Staged surgical treatment of obstructive sleep apnea syndrome: a review of 35 patients. *J Oral Maxillofac Surg* 1999;57:382-385.
- Vicini C, Dallan I, Campanini A, De Vito A, Barbanti F, Giorgiomarrano G, Bosi M, Plazzi G, Provini F, Lugaresi E. Surgery vs ventilation in adult severe obstructive sleep apnea syndrome. *Am J Otolaryngol*. 2010 Jan-Feb; 31(1):14-20.
- Doff MH, Jansma J, Schepers RH, Hoekema A. Maxillomandibular advancement surgery as alternative to continuous positive airway pressure in morbidly severe obstructive sleep apnea: a case report. *Cranio*. 2013;31:246-51.
- Holty JE, Guilleminault C. Maxillomandibular advancement for the treatment of obstructive sleep apnea: a systematic review and meta-analysis. *Sleep Med Rev*.2010;14:287-97.

# A Novel Approach in Management of Condylar Fractures

\* Tripti Nair, \*\*Eapen Thomas, \*\*\*Akhilesh Prathap, \*\*\*\*Ashino John

## Abstract

One of the most controversial issues in treatment of condylar fractures is regarding the option of open or closed reduction. Relative difficulty is encountered in management of these fractures and though there are various treatment modalities for the same, no consistent treatment of condylar fracture has gained universal acceptance. Several approaches to condylar fracture have become more popular in recent years, with related advantages as well as disadvantages for each. Few disadvantages like access difficulty, extensive soft tissue reflection, difficulty in plate adaptation, and plate placement makes some of these approaches less feasible. One approach which is found to be more feasible in terms of fewer disadvantages will be described with relevant literature reference supporting the findings.

KDJ 2016 | Vol. 39 | No. 3 | Pg 202-204

## ► Introduction

Condylar and sub condylar fractures comprise 26–40% of all mandible fractures<sup>1</sup> with much controversy regarding their management<sup>2</sup>. Closed reduction method has been very popular<sup>3,4</sup>. Open reduction and internal fixation (ORIF) has gained popularity because anatomical fracture reduction is more accurate with earlier return to normal function without the need for intermaxillary fixation<sup>5,6</sup>. The complication of potential facial

nerve injury with some approaches and possibility of postoperative scar has influenced the choice of surgical approach<sup>7</sup>. The transmasseteric anteroparotid approach has merits such as adequate access and visibility, minimal facial nerve morbidity, and better cosmetic and functional results. Only few documented studies are available in literature regarding the efficacy of this novel approach.

## ► Technique

The transmasseteric anteroparotid approach was used in management of a patient who sustained fracture of bilateral sub condyle and right mandibular body fractures. Arch bar fixation was done as pre-operative procedure and open reduction and internal fixation done under general anesthesia. The fracture sites were exposed via extra oral transmasseteric anteroparotid approach proposed by Wilson<sup>8</sup> and this approach was combined with preauricular approach. Pre-auricular incisions were placed with lazy S extension (Fig II). Dissection was performed through the skin, subcutaneous fat to reach the level of platysma muscle which was incised in the same plane as the skin. Raising of the flap was done in the sub dermal fat plane, above or superficial to the superficial musculoaponeurotic layer (Fig III). This plane allowed access to the masseter which lies adjacent to the

parotid gland at anteroinferior edge<sup>8</sup>. The masseter was dissected bluntly along the direction of its fibers in anterosuperior direction parallel to facial nerve branches to reach the periosteum over the ramus. The masseter muscle mass was retracted upwards subperiosteally to expose the fracture site (Fig IV). Open reduction and fixation of fractured segments was done using one 4 hole with gap 1.5mm titanium mini plate, one 2 hole with gap 1.5mm titanium mini plate and 6-8 mm monocortical screws (Fig V). The procedure of fracture exposure, reduction and fracture fixation using similar mini plates and screws was repeated in a similar manner on other side. The associated right mandibular body fracture was exposed using suitable approach, reduced and fixed with titanium miniplates and monocortical screws. Maxillomandibular fixation was released and checked for passive occlusion. Layered closure of soft tissue was done by using vicryl 3–0 for subcutaneous tissues and nylon 5–0 for skin after proper irrigation with antiseptic. Post-operative antibiotics and analgesics were prescribed.

Post operatively, clinical assessment of the patient was done for presence of infection at operative site, facial nerve palsy, post-operative scar, discrepancy in occlusion (Fig VI), fracture fragments stability, TMJ

\* P.G. Student, \*\* Professor and Head of the Department, \*\*\*Reader, \*\*\*\*P.G. student, Department of Oral and Maxillofacial Surgery, Pushpagiri College of Dental Sciences, Thiruvalla - 689 107 • Corresponding Author: Dr Tripti Nair E-mail: shikha\_nair1@yahoo.com

function by maximum mouth opening, lateral movements at intervals of one week, two weeks and three months. Post-operatively, radiographic assessment of fracture fragment approximation, plate fracture and screw loosening was evaluated using orthopantomograph (Fig VII) during each follow up interval. No complications were observed during follow ups in the postoperative period.

► **Discussion**

The most common complication occurring in all other approaches is facial nerve injury. With the submandibular and retro-mandibular approaches, studies show evidence of injury to marginal mandibular branch of facial nerve, while the temporal and zygomatic branches of facial nerve are at greater risk of injury in pre-auricular approach.

Wilson et al<sup>8</sup> conducted a study using extra oral transmasseteric antero-parotid approach for ORIF of condylar fracture. In the study 2 patients were treated using preauricular incision with retro mandibular extension and third patient with a lazy- s incision, using inferior extension in to the hairline.

In a study by Lutz et al<sup>9</sup>, based on 20 parotidomasseteric dissections from ten embalmed cadaveric heads, they concluded that the high sub-mandibular trans-masseteric approach provided greater exposure of facial nerve branches which lie on the masseter muscle, and as the incision is performed at a level between 10 and 20 mm above the mandibular base, the marginal mandibular branch is safe from injury with a safety margin of 4 mm.

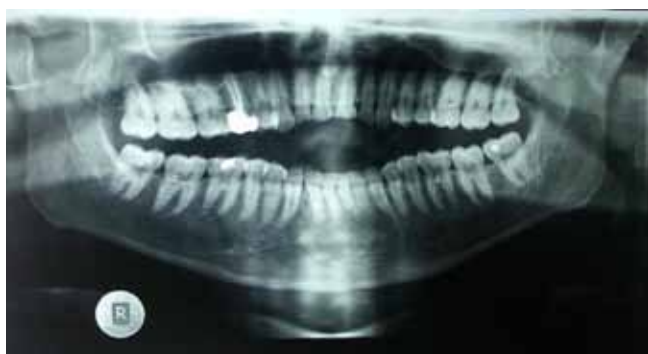

Fig. 1 Preoperative OPG

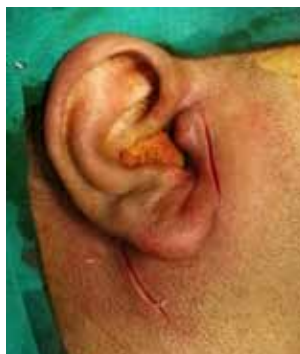

Fig. 2 Pre-auricular incision placed with lazy-S extension

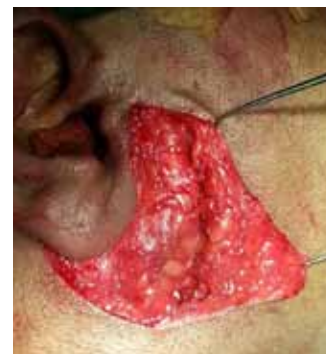

Fig. 3 Flap raised

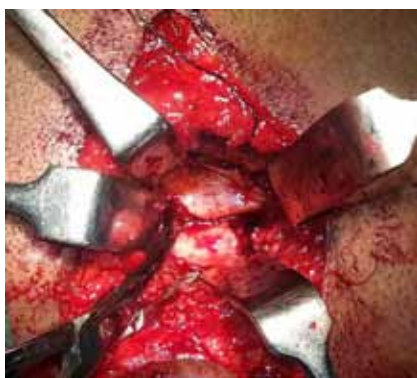

Fig. 4 Fracture site exposed

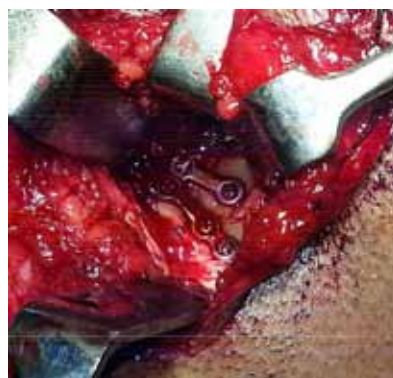

Fig. 5 Fracture reduced and fixed

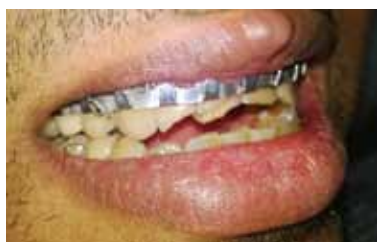

Fig. 6 Post operative occlusion

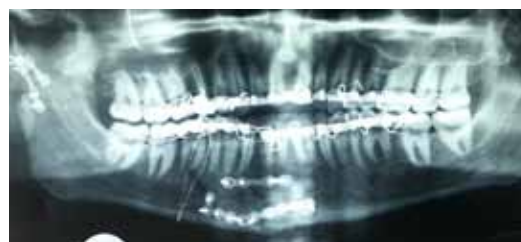
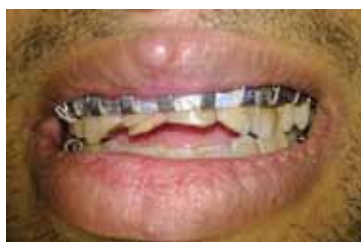

Fig. 7 Post operative OPG

In the present case, the extra oral transmasseteric antero-parotid approach was used for ORIF of the bilateral condylar fractures, using a pre-auricular incision with a lazy-S extension. The area of dissection selected is relatively free of branches. Only the buccal branch of facial nerve lies in close proximity and is seldom encountered with judicious dissection. Identification of this branch using nerve stimulator during the procedure can help to avoid this risk. Even though this approach used a longer incision, the scar is relatively imperceptible. Post operatively, excellent functional and cosmetic result was obtained with no evidence of weakness of facial nerve and also showed imperceptible scar in regular follow ups.

### ► Conclusion

We recommend this technique in managing sub condylar fractures of mandible as it provides swift access to the fracture site with relatively lesser incidence of complications like facial nerve injury, parotid sialocele, and minimal post-operative patient morbidity with excellent cosmetic and functional result.

### ► References

- 1) Ellis E 3rd, Dean J (1993) Rigid fixation of mandibular condyle fractures. *Oral Surg Oral Med Oral Pathol.* 76(1):6–15
- 2) Hyde N, Manisali M, Aghabeigi B, Sneddon K, Newman L (2002) The role of open reduction and internal fixation in uni-lateral fractures of the mandibular condyle: a prospective study. *Br J Oral Maxillofac Surg* 40(1):19–22
- 3) Blevins G, Gores RJ (1961) Fractures of the mandibular condyloid process: results of conservative treatment in 140 patients. *J Oral Surg Anesth Hosp Dent Serv* 19:28–30
- 4) Amaratunga NA (1987) A study of condylar fractures in Sri Lankan patients with special reference to the recent views on treatment, healing and sequelae. *Br J Oral Maxillofac Surg* 25(5):391–397
- 5) Zide MF, Kent JN (1983) Indications for open reduction of mandibular condyle fractures. *J Oral Maxillofac Surg* 41(2):89–98
- 6) Fernandez JA, Mathog RH (1987) Open treatment of condylar fractures with biphasic technique. *Arch Otolaryngol Head Neck Surg* 113(3):262–266
- 7) Sukhvinder Bindra et al Management of Mandibular Sub Condylar and Condylar Fractures Using Retro mandibular Approach and Assessment of Associated Surgical Complications *J. Maxillofac. Oral Surg.* (Sept-Dec 2010) 9(4):355–362
- 8) Wilson, Ethunandan, Brennan Transmasseteric Anteroparotid approach for open reduction and internal fixation of condylar fractures *British Journal of Oral and Maxillofacial Surgery* (2005) 43, 57-60
- 9) Lutz JC, Clavert P, Wolfram-Gabel R, Wilk A, Kahn JL (2010) Is the high submandibular transmasseteric approach to the mandibular condyle safe for the inferior buccal branch? *Surg Radiol Anat* 32(10):963–969

# Morphometric analysis of facial soft tissue in preschool children with flush terminal plane molar relation in Thiruvananthapuram

\*Sheela Sreedharan, \*\*Bhawna Gautam

## Abstract

**Aim:** The purpose of the study was to establish baseline normative data regarding facial soft tissue frontal measurements in preschool children of Thiruvananthapuram.

**Materials and Methods:** A cross-sectional study conducted in the Dept. of Pedodontics, Govt. Dental College, Thiruvananthapuram. 250 children of 3-5 years of age reporting to the Out Patient Dept. with complete primary dentition and Flush Terminal Plane molar relation satisfying the inclusion and exclusion criteria were the sampling unit. Their frontal facial soft tissue linear measurements were determined using a standardized photographic technique. The level of significance for the study was set as  $p < 0.05$ .

**Results:** Mean values of the study variable with Standard Deviation obtained with narrow range of 95% Confidence Interval indicated higher accuracy of the study. Bizygomatic Width, Bigonial Width, Middle and Lower One-thirds of the face, Upper and Lower Lip Lengths, Interlabial gap showed significant Gender difference. Correlation with Age was found to be significant for Bizygomatic Width, Bigonial Width, Facial Height, Middle and Lower One-Thirds of the face, Upper and Lower Lip Lengths.

**Conclusion:** The values obtained in the study can be used as a reference values for initial orthodontic evaluation of child beginning at 5 years of age. The study will help in predicting the direction of growth of dentofacial region and hence treatment plan can be modified accordingly. The study will also serve as the baseline study for further studies with molar relation other than FTP.

**Key Words:** Facial soft tissue analysis, FTP molar relation, pre-school children.

## ► Introduction

Facial appearance is an integral component of physical appearance of an individual. It has long been established that self-esteem is strongly influenced by facial appearance. The perception of an attractive face is largely subjective with ethnicity, age, gender, cultural and personality influencing facial features.<sup>1</sup> Facial analysis of face or morphometric analysis of craniofacial structures is one of the most important component of orthodontic diagnosis and treatment planning. Craniofacial morphology have been commonly studied in frontal and profile views. A number of methods have been used to evaluate these parameters including anthropometry<sup>2</sup>, photogrammetry<sup>3,4</sup>, cephalometry<sup>5,6</sup> and computer imaging<sup>7</sup>. Radiographic cephalometry and photographic systems are the most suitable and therefore most commonly used.

The recent surgent of facial photography has been brought about in parts due to concerns about radiation in children and in parts by imaging tools, which have made soft tissue imaging easier and eliminated worries about associated radiation exposure. Literature review revealed numerous studies dealing with soft tissue profiles in adolescence and adults, but very few studies in children under 6yrs of age<sup>8,9</sup>. The aim of the present study was to derive some objective measurements of selected linear soft tissue facial parameters of pre-school children by using a standardized photographic

technique. Measurements thus derived could then be used as a reference database for detailed assessment of normal growth in pediatrics, orthodontics and pediatric dentistry.

## ► Review of Literature

Angle<sup>10</sup> was one of the first to talk about facial harmony and the importance of soft tissue integumental profile. He believed that harmony and balance of the face and the form and the beauty of mouth depended on the occlusal relation of the teeth. Subtelny, in 1959, indicated that the correlation between hard- and soft tissue changes is not a strictly linear one. He measured horizontal and vertical relationships and found that not all parts of the soft-tissue profile directly follow the underlying skeletal structures<sup>11</sup>. Burstone agreed with Subtelny, stating that a close relationship of the soft tissue profile to the underlying skeletal pattern might not exist, because of the variation in the thickness of the soft tissue covering the skeletal face<sup>12</sup>.

Arnett and Bergman<sup>13,14</sup> defined their frontal and lateral analysis from the photographic records of young adult Caucasian taken in the natural head position (NHP). They used, the nasolabial angle and the angle of the contour of the maxillary and mandibular sulcus. They also described the facial profile in Class I (165–175 degrees), Class II (<165 degrees), and Class III profiles (>175 degrees) according to the angle of the facial convexity (G–Sn–Pg).

J D Subtelny<sup>15</sup> emphasized the importance of soft tissue profile analysis over the skeletal profile analysis for the improvement of facial esthetics. In his article titled, “The soft tissue profile, growth and treatment changes”, he has done an in depth study of changes of soft tissue profile and skeletal profile over the age of 3 years to 18 years using

lateral cephalographic tracings. According to Subtelny, it is very important to consider the growth changes within the soft tissue profile while formulating a treatment plan.

F R Dimaggio et al<sup>9</sup> evaluated soft tissue profile traits in 6 years old children using photogrammetric analysis. Several linear and angular measurements were evaluated. Results indicated that facial convexity was larger in boys than in girls, Sn-N-SI, and nasolabial and interlabial angles differed significantly (P<0.01) between the sexes. Girls had significantly less labial protrusion than boys. Facial height was significantly greater in children with dental Class II, without sex differences. All analysed angles were significantly influenced by dental class. The study concluded that the significant relationship between dental and cutaneous classes has important implications for orthodontic diagnosis and treatment.

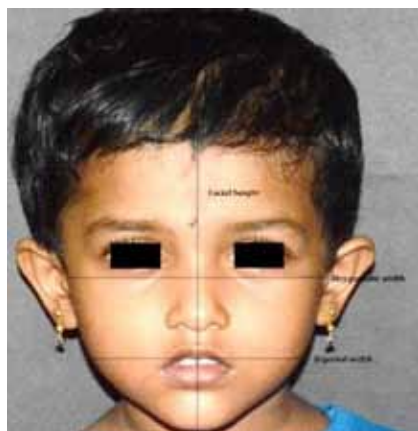Another photogrammetric analysis of facial soft tissue profile in 3 to 5 years old preschool children by K Delciet al<sup>8</sup> angular measurements on 1513 children with primary dentition. The study determined the mean values of total facial convexity angle (145.9<sup>0</sup>±4.2) and facial convexity angle (165.3<sup>0</sup> ±4.5). FCA and TFCA were significantly influenced by primary second molar terminal plane relationship. The study concluded that there is significant relationship between soft tissue profile and primary occlusion and is one of the important factors to be considered for orthodontic diagnosis and treatment of pediatric dental patients.

**Table 1** Mean Value of Study Variables

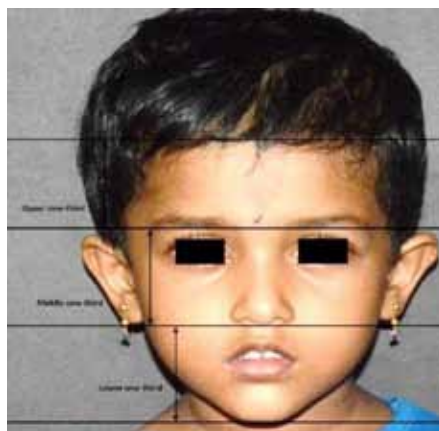Variables	Mean	Standard deviation	95% confidence interval
Bizygomatic Width (mm)	134.36	±8.10	133.34 - 135.36
Bigonial Width(mm)	108.321	±9.68	107.12 - 109.52
Facial Height(mm)	170.586	±16.14	168.58 - 172.60
Upper One-Third Face(mm)	58.852	±6.9	57.98 - 59.72
Middle One-Third Face (mm)	55.642	±6.2	54.86 - 56.42
Lower One-Third Face(mm)	55.184	±6.1	54.42 - 55.94
Upper Lip Length(mm)	18.505	±2.271	18.23 - 18.79
Lower Lip Length(mm)	36.774	±4.881	36.16 - 37.38
Lip Ratio(mm)	0.50	±6.531E-02	0.49 - 0.51
Incisor To Upper Lip Display(mm)	2.714	±1.418	2.44 - 2.98
Inter Labial Gap(mm)	3.601	±1.922	3.23 - 3.97

► **Methodology**

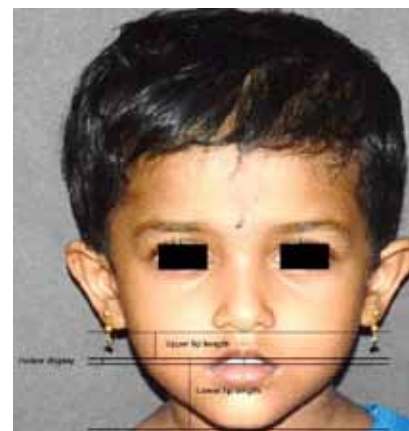The cross-sectional study was conducted in Department of Pedodontics and Preventive Dentistry, Government Dental College, Thiruvananthapuram. 250 Children of 3-5 years of age reporting to the Out Patient Dept. with complete primary dentition and Flush Terminal Plane molar relation were the sampling unit. Children with mixed dentition, with presence of proximal caries and any oral habit and maxillofacial trauma/pathology/developmental defects were excluded from the study.



**Fig. 1** Facial height, Bizygomatic and Bigonial width



**Fig. 2** Facial Thirds – Upper, Middle and Lower



**Fig. 3** Lip Lengths – Upper and Lower



Photographic Set up: Photographic set up consisted of a Nikon DSLR Camera with 18-55 mm macro lens having a primary flash. A Tripod stand was used as a levelling unit to maintain the correct horizontal positioning of the optical lens.  
 Record taking: the photographs were taken in Natural

Head Position. According to Lundström<sup>17</sup> the normal head posture is defined as the mean position of the head when the individual is standing in a relaxed position with the visual axis horizontal.

**Table 2** Mean values of study variables Genderwise

Variable	Gender	Mean	S D	p value
Bizygomatic Width	Male	135.666	7.747	S*
	Female	133.015	8.267	
Bigonial Width	Male	109.686	9.289	S*
	Female	106.945	9.917	
Facial Height	Male	172.258	18.476	NS**
	Female	168.899	13.260	
Upper One-Third Face	Male	58.697	6.872	NS**
	Female	59.009	7.081	
Middle One-Third Face	Male	56.690	4.440	S*
	Female	54.585	7.552	
Lower One-Third Face	Male	56.434	5.859	S*
	Female	53.923	0.170	
Upper Lip Length	Male	18.960	1.936	S*
	Female	18.046	2.489	
Lower Lip Length	Male	37.628	5.131	S*
	Female	35.914	4.473	
Lip Ratio	Male	0.5053	6.460E-02	NS**
	Female	0.5019	0.623E-02	
Incisor To Relaxed Upper Lip	Male	2.911	1.395	NS**
	Female	2.500	1.432	
Inter Labial Gap	Male	4.092	2.010	S*
	Female	3.069	1.692	

S\* - Significant, NS\*\* - Not Significant

**Table 3** Correlation of study variables with age

Relationship	Correlation	p value	Significance
Bizygomatic Width	0.500	0.000	S*
Bigonial Width	0.492	0.000	S*
Facial Height	0.409	0.000	S*
Upper One-Third Face	0.057	0.375	NS**
Middle One-Third Face	0.491	0.000	S*
Lower- One Third Face	0.524	0.000	S*
Upper Lip Length	0.389	0.000	S*
Lower Lip Length	0.484	0.000	S*
Lip Ratio	0.143	0.024	S*
Incisor To Relaxed Upper Lip	0.084	0.479	NS**
Interlabial Gap	0.002	0.987	NS**

S\* - Significant, NS\*\* - Not Significant

Following measurements were recorded:

1. Facial width:-
  - a. Bizygomatic Width: Zy-Zy, zygomatic arch to zygomatic arch (Fig 1)
  - b. Bigonial Width: Go - Go, Gonion to Gonion (Fig 1).
2. Facial height: H - Me, hairline to soft tissue menton (Fig 1).
3. Facial one-thirds:(Fig 2)
  - a. Upper third: H - Mb (hairline to midbrow).
  - b. Middle third: Mb-Sn (midbrow to subnasale).
  - c. Lower third: Sn-Me (subnasale to soft tissue menton).
4. Lip lengths: (Fig 3)
  - a. Upper lip length: Sn-ULI (subnasale to upper lip inferior).
  - b. Lower lip length: LLS-Me (lower lip superior to soft tissue menton).
5. Lip ratio: Sn-ULI/LLS-Me (upper lip length divided by lower lip length).
6. Upper incisor to relaxed upper lip: ULI-MxIE (upper lip inferior to maxillary incisor edge).
7. Interlabial gap: ULI-LLS, upper lip inferior to lower lip superior (Fig 3).

#### ► Results:

Mean values of the study variable with Standard Deviation obtained with narrow range of 95% Confidence Interval indicating higher accuracy of the study. In the present study, values for Bizygomatic width, Bigonial width and Facial height, which defines facial form of an individual were significantly higher for boys as compared to girls (Table 1). While facial upper third values did not show any significant gender difference, both middle and lower third values were higher for boys as compared to girls (Table 2). Upon evaluating lip lengths, upper lip length values were similar in boys and girls but lower lip length values were higher in boys than girls (Table 2). Lip ratio was found to be 0.5, (Table 2), corresponding to normal adult value<sup>13,14</sup>. Interlabial gap was also higher in boys as compared to girls (Table 2). Except upper facial third, interlabial gap and incisor to relaxed upper lip, all other values showed significant correlation with Age (Table 3).

#### ► Discussion and Conclusion

Pedodontists have the privilege to encounter a child de novo and so have a duty of comprehensive diagnosis and treatment planning which will go a long way. If not dealt properly may lead to further exacerbation of the dental / skeletal problem. Apt diagnosis would need in-depth understanding and clinical implications of dentofacial growth in terms of pattern and magnitude and their relation with timing of treatment available, which ultimately would affect facial morphometrics.

The present study provides a set of values of different facial dimensions which could be considered as ideal / normal for the given range of children age, the deviation from which would obviate preventive and interceptive treatment planning.

This study was a cross-sectional study. For accurate prediction of dentofacial growth and development, further longitudinal studies are required. The present study used a two dimensional photogrammetric method, hence was a two dimensional representation of three dimensional surfaces. The longitudinal study on the study population could be continued wherein the influence of genetic makeup, environmental exposures and other unmeasured characteristics that tend to persist over time can be evaluated. Longitudinal quantitative evaluation of soft tissue facial dimensions will also inform the clinician about the growth and treatment changes. In the present study, only flush terminal plane molar relationship of primary dentition was included, further studies involving mesial step and distal step terminal plane molar relation may be conducted for the comparative evaluation of facial morphometry on basis of molar relation.

#### ► References

1. Hershon LE, Giddon DB. Determinants of facial profile self-perception. *Am J Orthod* 1980; 78(3): 279-295.
2. Farkas LG. Anthropometry of the head and face in medicine. New York: Elsevier North Holland Inc. 1981.
3. Gavan JA, Washburn SL, Lewis PH. Photography: an anthropometric tool. *Am J PhysAnthrop* 1952; 10: 331-51.
4. Stoner MM. A photometric analysis of the facial profile. *Am J Orthod* 1955; 41: 453-69.
5. Anderson JP, Joondeph DR, Turpin DL. A cephalometric study of profile changes in Orthodontically treated cases ten years out of retention. *Angle Orthod* 1973; 43: 324-36.
6. Broadbent B H. A new X-ray technique and its application to orthodontia. *Angle Orthod* 1931; 1: 45-66.
7. Guess MB, Solzer WV. Computer treatment estimates in orthodontics and orthognathic surgery. *J ClinOrthod* 1989; 23: 262-8.
8. Dalci K, Ceteiner S. Soft tissue profiles of 3-5 years old pre-school children. *J ClinPaed Dent* 2011; 35 (3): 339-344.
9. Dimaggio FR, Ciusa V. Photographic soft tissue profile analysis in children at 6 years of age. *Am J Orthod*. 2007 Oct; 132(4): 47-480.
10. Angle EH. Malocclusion of the teeth, 7th edition. Philadelphia: S.S. White Dental MFG. Co., 1907.
11. Subtelny J D. A longitudinal study of soft tissue facial structures and their profile characteristics defined in relation to underlying skeletal structures. *Am J of Orthod* 1959; 45: 481-507.
12. Burstone C J. The integumental contour and extension patterns. *Angle orthod* 1959; 29: 93-104.
13. Arnett G W, Bergman R T. Facial keys to orthodontic diagnosis and treatment planning. 1993a Part I *Am J of Orthod and DentofacialOrthop*; 103: 299-312.
14. Arnett G W, Bergman R T. 1993b Facial keys to orthodontic diagnosis and treatment planning. Part II. *Am J of Orthod and DentofacialOrthop*; 103: 395-411.
15. Subtelny JD. The Soft Tissue Profile, Growth and Treatment Changes. *The Angle Orthodontist*: April 1961; 31(2): 105-122.

# Antibiotic prophylaxis to prevent infective endocarditis - current dilemmas

\*Mathew Tharakan, \*\* Saleem PA, \*\*\* G Harikrishnan, \*\*\*\* Ashok Kumar Menon

## Abstract

Treating a cardiac patient is always a matter of concern for the dentist. Most of the dental practitioners must have treated a handful of cardiac patients with or without awareness about the patients existing cardiac condition, sometimes even might have become aware about the issue after the completion of the treatment and have few sleepless nights. This article discusses the current dilemmas in giving antibiotic prophylaxis to prevent infective endocarditis for susceptible patients and how to overcome this

KDJ 2016 | Vol. 39 | No. 3 | Pg 209-212

## ► Introduction

The valves of the heart do not receive their own dedicated blood supply. This effectively means they are indefensible to an immune attack, as white blood cells cannot directly reach them. This lack of blood supply also impacts on treatment, since drugs cannot reach the affected areas either. Infective endocarditis is a devastating disease with high morbidity and mortality. It may arise following bacteraemia in a patient with a predisposing cardiac lesion. The idea that dental procedures, mostly invasive ones, could cause infective endocarditis was first suggested in 1923 (Lewis and Grant, 1923). Later with the advent of antibiotics, guidelines were suggested to use antibiotics before invasive dental procedures to prevent infective endocarditis in susceptible individuals. Since then various organisations have

formed their own guidelines of antibiotic prophylaxis for the prevention of infective endocarditis, until 2007 there were minor changes in the antibiotic doses but routinely all these organisations advised antibiotic prophylaxis for susceptible individuals. (the latest published antibiotic regime is given in the table below)

Fulvia Costantinides, et al; Antibiotic prophylaxis of infective endocarditis in dentistry; clinical approach and controversies, Oral health and preventive dentistry vol 12, no 4, 2014; 305-311

As science is basically evidence based study there were long-standing concerns about the efficacy of antibiotic prophylaxis and the adverse risk of drug reactions. As a result, the British Society for Antimicrobial Chemotherapy issued new guidance restricting antibiotic use to patients at highest risk of endocarditis. These were patients who had damaged heart valves from previous episodes of rheumatic fever or had replacement heart valves among other conditions. This action prompted (The National Institute for Clinical Excellence) NICE to undertake a review where they found little if any evidence to show antibiotic prophylaxis was of benefit in preventing infective endocarditis. NICE also weighed up the potential risk of adverse drug reactions with any benefit of preventing cases of infective endocarditis. They concluded it was not cost effective. This led to the publication

of guidance in 2008 recommending that antibiotic prophylaxis before invasive dental procedures should stop (NICE, 2008). Both mainland Europe and the USA have different views to NICE. As a result, currently the UK is the only place that does not recommend antibiotic prophylaxis for high-risk patients.

These new guidelines have been met with some nervousness among dentists, cardiologists and patients. The subject has become confusing because of different recommendations by different authorities worldwide. Later in May 2009 the Journal of Irish dental association has formulated a criteria for their dental practitioners to follow which recommends

Journal of Irish Dental association; practice management; Infective endocarditis prophylaxis, summary information for dentists; Vol 55(2); April/may 2009; 102

Antibiotic prophylaxis prior to invasive dental treatment should be given to patients with a history of:

- prosthetic cardiac valve;
- previous infective endocarditis;
- cardiac transplantation recipients who develop cardiac valvulopathy;
- congenital heart disease (CHD)\*;
  - un-repaired cyanotic CHD, including palliative shunts and conduits;

\* Consultant Maxillofacial Surgeon and Orthodontist, \*\* Consultant Oral and Maxillofacial Surgeon \*\*\* Consultant Implantologist and Periodontist, \*\*\*\* Consultant Periodontist • Corresponding Author: Dr. Mathew Tharakan, E-mail: drcamt@gmail.com

- completely repaired congenital heart defect with prosthetic material or device, whether placed by surgery or by catheter intervention, during the first six months after the procedure!
- or,
- repaired congenital heart defect with residual defect at the site or adjacent to the site of a prosthetic patch or a prosthetic device (which inhibit endothelialisation)

Except for the conditions listed above, antibiotic prophylaxis is no longer recommended for any other form of CHD.\*

Prophylaxis is recommended for the first six months because endothelialisation of prosthetic material occurs within six months after the

Procedure and then prophylaxis is unnecessary

Dental procedures for which endocarditis prophylaxis is recommended:

- All dental procedures that involve manipulation of gingival tissue or the periapical region of teeth or perforation

of the oral mucosa. Dental procedures for which endocarditis prophylaxis is not recommended.

The following procedures and events do not need prophylaxis:

- > Routine dental anaesthetic injections through non-infected tissue; taking dental radiographs;
- > Placement of removable prosthodontic or orthodontic appliances;
- > Adjustment of orthodontic appliances;
- > Placement of orthodontic brackets; shedding of deciduous teeth; and,
- > Bleeding from trauma to the lips or oral mucosa.

► **Discussion**

When dealing with the dilemma of the antibiotic prophylaxis for IE, we need to consider the factors which led NICE to advocate stoppage of the regime and the factors still favor to advocate the same

The factors pointed by NICE are

- There is no consistent association between having an interventional procedure, dental or non-dental, and the development of IE

Situation	American Heart Association Guidelines (2007)		British Society for Antimicrobial Therapy Guidelines (2006)	
	Agent	Regimen: single dose 30 to 60 min before procedure	Agent	Regimen
Oral	Amoxicillin	50 mg / kg	Amoxicillin	750 mg (< 5 years of age) 1.5 g (5 to 10 years of age) 3 g (> 10 years of age) 1 h before procedure
Unable to take oral medication	Ampicillin, Cefazolin or Ceftriaxone	50 mg / kg IM or IV	Amoxicillin	250 mg (< 5 years of age) 500 mg (5 to 10 years of age) 1 g (> 10 years of age) IV just before procedure or at induction of anaesthesia
Allergic to penicillin	Cephalexin * §	50 mg / kg	Clindamycin	150 mg (< 5 years of age) 300 mg (5 to 10 years of age) 600 mg (> 10 years of age) 1 h before procedure
	Clindamycin	20 mg / kg		
	Azithromycin or Clarithromycin	15 mg / kg		
Allergic to penicillin or ampicillin and unable to take oral medication	Cefazolin§ or Ceftriaxone	50 mg / kg IM or IV	Clindamycin	75 mg (< 5 years of age) 150 mg (5 to 10 years of age) 300 mg (> 10 years of age) IV given over at least 10 min
	Clindamycin	20 mg / kg IM or IV	Azithromycin	200 mg (< 5 years of age) 300 mg (5 to 10 years of age) 500 mg (> 10 years of age) Oral suspension for patients that cannot swallow capsules 1 h before procedure

\* or other first- or second-generation oral cephalosporin in equivalent adult or paediatric dosage. §Cephalosporins should not be used in patients with immediate hypersensitivity reaction to penicillin (urticaria, angioedema or anaphylaxis).

- Regular tooth brushing almost certainly presents a greater risk of IE than a single dental procedure because of repetitive exposure to bacteraemia with oral flora
- The clinical effectiveness of antibiotic prophylaxis is not proven
- Antibiotic prophylaxis against IE for dental procedures may lead to a greater number of deaths through fatal anaphylaxis than a strategy of no antibiotic prophylaxis, and is not cost-effective.

The factors which favor the antibiotic regime mainly include Latest research article from BDJ (British Dental Journal) in 2015 has found out an 88% fall in antibiotic prophylaxis prescribing in the five years following NICE guidelines.

They also discovered a highly significant increase in the incidence of infective endocarditis above what would be expected. The results of this study were published in the Lancet (Dayer et al, 2015).

The authors have admitted that this study is by no means conclusive but it has prompted NICE to announce a review of their guidelines.

► **Conclusion**

Since no randomized controlled studies are ever published in this aspect, science as of now is not in a position to authoritatively come to a definite conclusion. Studies have shown that maintenance of good oral hygiene has a significant role in reducing the incidence of infective endocarditis even in susceptible individuals. To deal

Situation	American Heart Association Guidelines (2007)		British Society for Antimicrobial Therapy Guidelines (2006)	
	Agent	Regimen: single dose 30 to 60 min before procedure	Agent	Regimen
Oral	Amoxicillin	2 g	Amoxicillin	3 g 1 h before procedure
Unable to take oral medication	Ampicillin	2 g IM or IV	Amoxicillin	1 g IV just before procedure or at induction of anaesthesia
	Cefazolin or Ceftriaxone	1 g IM or IV		
Allergic to penicillin	Cephalexin * §	2 g	Clindamycin	600 mg 1 h before procedure
	Clindamycin	600 mg		
	Azithromycin or Clarithromycin	500 mg		
Allergic to penicillin or ampicillin and unable to take oral medication	Cefazolin§ or Ceftriaxone	1 g IM or IV	Clindamycin	300 mg IV given over at least 10 min
	Clindamycin	600 mg IM or IV	Azithromycin	500 mg oral suspension for patients that cannot swallow capsules 1 h before procedure

\* or other first- or second-generation oral cephalosporin in equivalent adult or paediatric dosage. § Cephalosporins should not be used in patients with immediate hypersensitivity reaction to penicillin (urticaria, angioedema or anaphylaxis).

**Antibiotic prophylaxis for dental procedures**

Population	AGE			Timing of dose before procedure
	>10 years	5-10 years	< 5 years	
General	amoxicillin 3g po	amoxicillin 1.5g po	amoxicillin 750mg po	1h
Allergic to penicillin	clindamycin 600mg po	clindamycin 300mg po	clindamycin 150mg po	1h
Allergic to penicillin and unable to swallow capsules	azithromycin 500mg po	azithromycin 300mg po	azithromycin 200mg po	1h
Intravenous regimen expedient	amoxicillin 1g iv	amoxicillin 500mg iv	amoxicillin 250mg iv	just before the procedure or at induction of GA
Intravenous regimen expedient and allergic to penicillin	clindamycin 300mg iv*	clindamycin 150mg iv*	clindamycin 75mg iv*	just before the procedure or at induction of GA

\* Given over at least 10 min.

Where a course of treatment involves several visits, the antibiotic regimen should alternate between amoxicillin and clindamycin.

Pre-operative mouth rinse with chlorhexidine gluconate 0.2% (10 mL for 1 min).

with controversial issues like this it would be wiser from our side to be aware about the current developments in the same, then take decisions for each patient logically using personal expertise, specialist opinion and expert cardiac advice if found necessary.

► **References**

1. Thornhill MH, Lockhart PB, Prendergast B, Chambers JB, Shanson D. NICE and antibiotic prophylaxis to prevent endocarditis. Br Dent J 218(11): 619-621. doi:10.1038/sj.bdj.2015.392
2. Dayer MJ, Jones S, Prendergast B, Baddour LM, Lockhart PB, Thornhill MH (2015) Incidence of infective endocarditis in England, 2000-13: a secular trend, interrupted time-series analysis. Lancet 385: 1219-1228. doi: 10.1016/S0140-6736(14)62007-9
3. Journal of Irish Dental association; practice management; Infective endocarditis prophylaxis, summary information for dentists; Vol 55(2);April/may 2009; 102
4. D. Wray et al, Prophylaxis against infective endocarditis for dental procedures – summary of the NICE guidelines; BDJ Volume 204, No 10 May 24 2008; 555-557
5. Sarah McKernon; Antibiotic prophylaxis to prevent endocarditis; dental Nursing, Augustvol 11; No 8; 2015 482-483
6. FulviaCostantinides, et al; Antibiotic prophylaxis of infective endocarditis in dentistry; clinical approach and controversies, Oral health and preventive dentistry vol 12, no 4, 2014; 305-311
7. DayTer M J, Chambers J B, Prendergast B, Sandoe J A, hornhill M H. NICE guidance on antibiotic prophylaxis to prevent infective endocarditis: a survey of clinicians attitudes. CUM 2013; 106: 237-243.
8. Lockhart PB, Brennan MT, Sasser HC, Fox PC, Paster BJ, Bahrani-Mougeot FK (2008) Bacteremia associated with toothbrushing and dental extraction. Circulation 117: 3118-3125. 10.1161/CIRCULATIONAHA.107.758524
9. Bor DH, Woolhandler s, Nardin R, Brusck J, Himmelstein DU. Infective endocarditis in the U.S., 1998-2009: a nationwide study. PLoS One 2013;8(3): e60033.
10. National Institute for Health and Care Excellence (2008) Prophylaxis Against Infective Endocarditis: Antimicrobial Prophylaxis Against Infective Endocarditis in Adults and Children Undergoing Interventional Procedures. www.nice.org.uk/ guidance/cg64 (accessed July 13 2015)
11. Lewis T, Grant R. Observations relating to subacute infective endocarditis. Heart 1923; 10: 21-77.
12. Roberts GJ, Radford P, Holt R. Prophylaxis of dental bacteraemia with oral amoxycillin in children. Br Dent J 1987;162:179-182

*The Largest Dental Portal of Kerala*  
**Log on [www.idakerala.com](http://www.idakerala.com)**  
for IDA Activities, Reports, Publication etc...



# Current concepts in rotary endodontics and clinical use

\* Rethi Mahesh, \*\* Mahesh J.

## Abstract

With the introduction of various new techniques and instruments over the past decade, endodontic treatment modalities have undergone a tremendous transformation. Instruments made from nickel-titanium alloys in contrast to those made from stainless steel have proved to be very successful in cleaning and preserving the anatomy of the root canal. Past two decades have shown considerable progress in the design modifications, manufacturing and even in alloy processing. Shaping of the root canals and maintaining its original curvature has become the primary goal of designing of the newer generation of NiTi rotary file systems. To help in choosing an ideal rotary system it is necessary to have a proper understanding of the design, ease of operation and the results of the various clinical trials. This review is intended give an insight to the laboratory and clinical findings of the several rotary instruments as well as guidelines and parameters for usage.

**Key words:** NiTi, Shaping, Rotary, Endodontics, Root canal

KDJ 2016 | Vol. 39 | No. 3 | Pg 213-217

## ► Introduction

Shaping and cleaning of the root canal system has been recognized as the most crucial part of root canal treatment. Traditionally this has been achieved by meticulous and careful manipulation of hand instruments and also by strictly adhering to the biological and surgical principles which are essential for proper disinfection and subsequent healing. A continuously tapered funnel shaped root canal with an end point of the

smallest diameter is considered as the most appropriate shape for obturation. But a curved canal presents us with a problem for achieving the ideal shape. A conventional stainless steel instrument has a tendency to straighten the canal in relation to its original axis. Previously files and reamers were made of either carbon or stainless steel.

Nickel-titanium (Ni-Ti) was introduced to the speciality of Endodontics almost two decades back. It has succeeded in dramatically changing the way root canal is being performed. The most significant advantage is the predictability with which a desired shape can be achieved. Walia<sup>1</sup> et al in 1988 showed that files made of nickel titanium alloys had increased flexibility and resistance to torsional fracture when compared to stainless steel. Stainless steel started getting substituted with NiTi files with an added benefit of the ability to straighten the curved root canals. Further advantages of NiTi alloys were that it causes less straightening of the canal, lesser formation of ledges, canal transportations, zipping and perforations. Due to the varying degrees of complexity of the canals and the operators experience not all systems are suitable for all clinicians. Rotary instruments can unexpectedly break if reused. There are issues of corrosion and contamination too. Therefore a thorough knowledge of the metallurgy and clinical guidelines of NiTi rotary instruments is very important. This review summarizes the most recent trends of NiTi technology, its design and usage parameters.

## Generations of rotary systems<sup>2-3</sup>

### 1st Generation:

From middle to late of nineties the files had passive cutting radial lands and having tapers of 4-6% over the length of the active blades. The disadvantage of this generation was the need for numerous files for achieving an ideal preparation (Table 1).

### 2nd Generation:

Started becoming available by the year 2001. The major difference when compared to the previous generations was that it had active cutting edges and hence only fewer instruments were required for a complete canal preparation. In order to overcome the problem of screw effect and both the active and passive fixed tapers associated with the NiTi instruments several companies like BioRaCe by FKG Dentaire SA, Switzerland, Endo sequence by Brasseler US A provided alternating contact points in their file lines (Table 2).

### 3rd Generation:

In 2007 in order to reduce cyclic fatigue and to improve the safety and lessen breakage of NiTi instruments in curved canals several manufacturers started focusing on usage of cooling and heating methods. The phase-transition from martensite and austenite during this phase produced a better optimal metal clinically than NiTi which reduced cyclic fatigue significantly.

### 4th Generation:

Then came another advancement called reciprocation, which is the

\* Reader, Dept. of Conservative Dentistry & Endodontics; \*\* Professor & HOD, Dept. of Periodontics, Noorul Islam College of Dental Science, Neyyattinkara, Kerala, • Corresponding Author: Dr. Rethi Mahesh, Email: dr.maheshj@yahoo.co.in

repetitive up and down or the back and forth motion of the instrument. The fourth generation instruments lead to the hope for a single file technique (Table 4). The self adjusting file system was introduced by Re Dent Nova, Israel.

**5th Generation:**

The fifth and latest generations of files are designed in such a way that their center of mass or center of rotation or both is offset. These files with offset design produce a mechanical wave of motion which will travel along the active length of the file. Similar to the progressive design of the Pro Taper files this file design also minimizes the engagement between the dentin and the file (Table 5).

To overcome the various problems associated with the final quality of the shaped root canal like fracture of instruments due to cyclic fatigue, apical transportation, inadequate envelope of preparation preventing complete removal of debris in retreatment cases, lack of centricity in the preparation etc numerous modifications were made in the design of rotary instruments and systems.

The modifications that were made are

**a. To increase the cyclic fatigue resistance:**

NiTi instruments were subjected to thermo mechanical treatment because the mechanical performance of the alloys

was dependent on their microstructure and thermo mechanical treatment. The transition temperature of files made of NiTi alloys which will affect their fatigue resistance was altered using heat treatment or thermal processing. Thermomechanical proprietary processing technique was developed recently to produce SE NiTi wire blanks.

In 2007 Dentsply applied a series of heat treatments to NiTi wire blanks and introduced the M-Wire. The profile vortex, Profile GT series and X series and Vortex blue are examples of this system. Sybron Endo developed a new process of manufacturing for creating a NiTi file –Tf’s.

During the forward transformation from martensite to austenite on heating and from austenite to martensite on cooling an R–Phase is formed which is an intermediate phase with a rhombohedral structure (Fig. 1 a).

**b. CM wire:**

In 2010 Dental, Johnson City TN introduced CM wire which is a novel NiTi alloy with flexible properties. A special thermo chemical process to control the memory was used to manufacture CM NiTi files which make it different from conventional NiTi files. TY and Hyflex are examples. They were also found to be 300-800% more resistant to fatigue failure when compared to conventional files. The square shaped configuration of files made from CM wire had much longer

**Table 1:** First generation rotary instruments

Name of File	Year	Tip	Taper	Salient features
Profile	1993	Non cutting	Fixed taper of 2%, 4% and 6%	Negative rake angle Passive cutting blades
Quantec	1996	Noncutting tip	Constant taper	Semi active cutting blades
System GT	1998	Bullet nose tip	Constant rate of taper	Variable pitch reduce the screwing in effect
Hero 642	1999	Inactive tip	Constant taper	Triple helix geometry
Flex Master	2000	Non cutting	Constant taper	K type cutting blades provide high cutting efficiency, improved torsional resistance

**Table 2:** Second generation rotary files

Name of File	Year	Tip	Taper	Salient features
RaCe	1999	Non cutting safe tips	Varying taper	Reamer with alternate cutting edges
Protaper	2001	Modified guiding tip	Multiple taper	Multiple increasing /decreasing taper
K3	2001	Safe ended tip	Constant taper	Positive rake angle Crown down preparation
Hero shaper	2002	Inactive tip	Constant taper	Positive cutting angle Adapted pitch concept
Endosequence	2004	Non cutting precision tip	Constant taper	Constant taper Alternate contact point electropolish file Variable pitch
BioRaCe	2011	Non-cutting safety tip	Constant taper	Electrochemical surface treatment Alternating cutting edge.



fatigue life when compared to the triangular configuration of TYP M. This shows that the design of the instrument plays an important role in determining its fatigue life. NiTi files made from CM wire had smaller values of fracture area occupied by simple region than conventional files and also had better fatigue resistance.

#### c. M wire:

It was reported by Johnson et al that instruments made of M wire and with a profile design had 400% more of cyclic fatigue when compared to those made with SE wire of the same size.

#### d. R Phase:

A twisted file is a NiTi rotary file that has been manufactured from an R-Phase alloy using a twisting method and also has higher fatigue resistance when compared to ground files. It also exhibits superior elasticity and shape memory and its young's modulus is lower than that of austenite and hence makes it very flexible. It has a narrower stress hysteresis enabling more austenite transformation during the process of stress induced martensitic transformation leading to a higher fatigue resistance in comparison to conventional NiTi files (Fig.1 b).

#### e. Design of the tip:

A precision tip can be defined as a non cutting one which will become active right at the DI. There are various tip designs like active, partially active or passive designs. Mostly the files have a rounded tip to act as a guide within the root canal and are non aggressive. They usually ride on the canal and do not gouge it. There are also few modifications like the 60 degree safe cutting tip of the Quantec safe end files.

#### f. Centring ability of rotary instruments:

Various modifications like the three edge cross design of Hero shapers wide cross sectional radial lands of Quantec,

alternate contact points of Real World Endo Sequence and reverse flutes alternating with straight areas of RACE etc were made on various rotary systems to maintain their centring ability.

#### g. Apical transportation:

To minimize the apical transportation ie, moving of the canals normal anatomic foramen to a new location on the external surface of the root, modifications like the non cutting round guiding tips of Flexmaster, Hero Shaper, the radial lands and peripheral blade reliefs of K3, K3XF, different cross-sectional designs on the entire length of the working part of Wave One which is a one shape rotary system etc were made.

#### One shape single rotary file system<sup>4</sup>

One Shape is the one and only NiTi instrument with continuous rotation which allows easy instrumentation of curved canals. It has three different cross section zones. Primary zone has a variable three cutting edge design. Secondary zone has prior to the transition changes from a three to two cutting edge and the final zone has two cutting edges. The non working safety tip by avoiding obstructions ensures a complete and effective apical progression.

#### Pro Taper Next<sup>5</sup>

Compared to Pro Taper Universal files the Pro Taper Next offers an improved efficiency with fewer files. It has a rectangular off centre cross sectional design which gives it more strength. Its unique asymmetric rotary motion increases its efficiency of shaping the canal. Since its axis of rotation differs from the centre of mass only two points of the cross section will touch the canal wall at a given time.

#### REVO-S<sup>6</sup>

This is a unique, innovative system utilising only three instruments. It has an asymmetrical cross section and initiates a snake like movement in the canal. It has three cutting edges

**Table 3:** Third generation rotary files

Name of File	Year	Tip	Taper	Salient features
Twisted	2001	Safety tips	Constant taper	R-phase of NiTi alloy positive rake angle
Hyflex	2012	Safety tips	Constant taper	Controlled memory NiTi files
Wave one	2012	Modified tip	Variable taper	Reciprocating motion

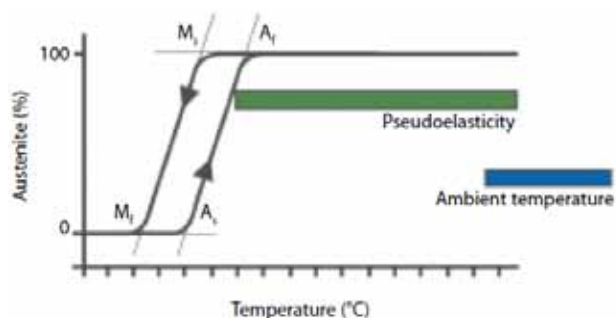
**Table 4:** Fourth generation rotary files

Name of File	Year	Tip	Taper	Salient features
Self Adjusting File (SAF)	2010	Pointed cylinder	Adapts to canal	Compressible open tube design Up & down, back & forth motion

located at three different radiuses, the R1, R2 and R3. The volume available for the upward removal of debris is increased due to its asymmetrical cross section.

### Self adjusting files (SAF)<sup>7</sup>

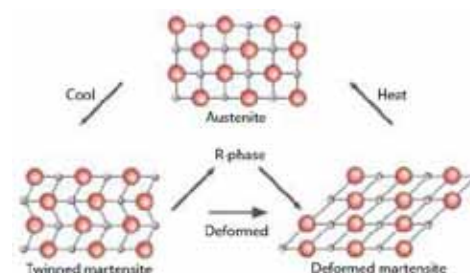
This is a hollow file which is designed as a compressible, thin-walled pointed cylinder which is 1.5 or 2.0 mm in diameter and having a thick Ni Ti lattice of 120 mm. This is also a self adjusting file that adapts to the three dimensional anatomy of the root canals. It results in uniform removal of the dentin and the remaining thickness of the wall. It is highly durable and prevents apical transportation.



**Fig 1a** Temperature-dependent transition from austenitic (brittle, hard) to martensitic (soft) crystalline lattices.

### Twisted files (TF)<sup>8</sup>

This is a NiTi engine file manufactured using a twisting method and is recently introduced by TF Sybron Endo. It overcomes many of the shortcomings of ground file technology and opens up new improved file design such as twisting. This is made with the R Phase of NiTi alloy. It has a crystalline structural modification which maximises the flexibility and gives higher fracture resistance when compared to ground files. It also has a different natural grain surface structure which runs in the longitudinal direction. Also there is an absence of the transverse running marks produced due to electro polishing which gives it a property of slower initiation of crack and propagation. Only a very few reports of the fatigue behaviour of twisted files are available in the literature.



**Fig 1b** Force- and temperature-dependent transitions from austenite to martensite, including the intermediary R-phase. The proportion of alloy that is in R-phase depends on heat treatment of the raw wire.

**Table 5:** Fifth generation rotary files

Name of File	Year	Tip	Taper	Salient features
Revo-S	2012	Inactive tip	Constant taper	It has 3 cutting edges, all located at 3 different radiuses, R1, R2 and R3
One Shape	2013	Safety tips	Constant taper	Variable cross section
ProTaper Next	2013	Modified tip	Variable taper	Unique Asymmetric Rotary M wire technology

**Table 6:** Do's and Dont's of usage of rotary instruments.

	Handling	Do's	Dont's
1	Case selection	Gradual curves, glide path confirmed with straight size no. 20 K-file	Acute coronal curves and other anatomical variations
2	Glide path	Confirm a patent canal to the level the rotary should follow	Unknown canal conditions ahead of the rotary instrument
3	Speed	Low (~ 250 rpm)	High (> 350)
4	Torque	Dependent on file; low for small-diameter taper; governed by motor or tactile feedback	Uniformly low or always high; reliance on torque-controlled motor
5	Hand movement	Pecking for radial-landed files, brushing for nonlanded files	Forcing the file apically

### Preparation quality with rotary instrument:

Various studies have shown that the use of NiTi instrument with rotary movements results in improved quality of preparation. Canals having oval or ribbon shaped cross sections are difficult to manage with rotary instruments. In those cases circumferential filing is recommended. A rotary instrument with radial land designs prepares the canal in a planning action and enlarges them safely and without any procedural errors. The non landed instruments prepare the canal in a cutting motion and allow the clinician to change the pathway of canal away from the furcations in the coronal and middle third of the root canals. Rotaries are designed with a variable pitch and helical angle to overcome the circumferential engagement of the canal walls leading to threading in effect. During shaping dentin is removed and this smear layer may protect the microorganisms from the disinfectants. To overcome this passive non cutting tip guiding the cutting planes is used to produce an evenly distribution of dentin removal. Due to the passive reaming action of radial landed instruments even if it extends beyond the apical foramen it will not create an apical zip formation. However care should be taken not to take the cutting instruments beyond the apical constriction to prevent canal transportation

### Usage of Ni-Ti instrument and prevention of fracture:

Torsional load and cyclic fatigue are the most common reasons for fracture of instruments. When the instrument undergoes friction against the canal torsional load is transferred to it and when it rotates in the canal cyclic fatigue occurs. These two factors work in tandem to weaken the instrument. Generally flexible instruments are not very resistant to torsional load but are resistant to cyclic fatigue. When the tip of the instrument is forced into a canal smaller than its diameter it will not follow the speed of the rotation and torsional overload occurs and will break. In such cases the coronal portions of the tip will show plastic deformation. Fracture of files has also been associated with instrument handling. Reuse of rotary instruments should be very closely monitored to help in avoiding the build up of fatigue and also sodium hypochlorite associated corrosion. Several clinicians recommend only a single patient usage for rotary instruments to avoid breakage. Some do's and don'ts of instrument handling are given below in Table 6.

### Clinical outcomes

Even though there are several in vitro studies in the literature very few clinical studies are available on the usage of rotary instruments. Pettiette et al<sup>9</sup> evaluated the success rate of endodontic treatment performed by students with stainless-steel K-files and nickel-titanium hand files and had found less canal transportation, lesser gross preparations like strip perforations when hand NiTi files were used. Radiographic analysis showed better healing too. Schafer et al<sup>10</sup> also had radiographically shown less canal straightening by Flex Master NiTi files in comparison to stainless steel files. Cheung and

Liu<sup>11</sup> have reported a higher level of apical healing rate for NiTi rotary instruments (up to 77%) when compared to K-File preparations (upto 60%). Spili et al<sup>12</sup> in their study on teeth with apical periodontitis with retained instrument fragment have shown 91.8% healing rate in comparison to control teeth with no complications. The results of the various studies show that the usage of NiTi instruments can reduce incidences of gross preparation errors and improve the clinical outcome even in the hands of clinicians with less expertise.

### ► Conclusion

The development of rotary instruments had been an exciting and valuable advancement in the field of endodontics. Shaping of the root canals and maintaining its original curvature has become the primary goal of designing of the newer generation of NiTi rotary file systems. The advent of NiTi instruments has revolutionized the traditional systems. It may be difficult for the clinician to select the most suitable file system and technique needed for an individual case. It will be appropriate if the clinician could go by his clinical experience, handling properties and safety of usage of a particular system rather than blindly following the dealers name or manual.

### ► Declaration of interest:

We the authors declare that we do not have any competing interests.

### ► References:

1. Adam Lloyd: Root canal instrumentation with Pro File instruments. *Endodontic Topics*; 10,151; 2005.
2. Ruddle C. The shaping movement 5th generation technology. *Dent Today* 2013; 1-8.
3. Grossman's Endodontic Practice 12th edition, Wolters Kulwer,
4. Emilia karova, Snezhanka Topalova-Pirinska, Instrument life of two rotary niti single file techniques with reciprocating and continuous rotation used in curved canals after a glide path creation. *Journal of Imab – annual proceeding (scientific papers) 2014, vol. 20, issue 1; 494 -99.*
5. Mcspadden: Mastering the instrumentation;2006 Arbor books, Inc.Metzger Z, Teperovich E,
6. Zary R, et al. The Self Adjusting File (SAF). Part 1: Respecting the root canal anatomy; a new concept of endodontic file design and its implementation. *J Endod* 2010; 36: 679-690
7. Metzger Z, Teperovich E, Cohen R, et al. The Self Adjusting File (SAF). Part 3: Removal of debris and smear layer. A scanning electron microscope study. *JEndod* 2010; 36: 697-702
8. Shen Y et al. Current Challenges and Concepts of the Thermomechanical Treatment of Nickel-Titanium Instruments. *J Endod* 2013; 39:163–172.
9. Pettiette MT1, Delano EO, Trope M. Evaluation of success rate of endodontic treatment performed by students with stainless-steel K-files and nickel-titanium hand files. *J Endod.* 2001 Feb; 27(2):124-7.
10. Schafer E. Shaping ability of Hero 642 rotary nickel-titanium instruments and stainless steel hand K-Flexofiles in stimulated root canals. *Oral Surg. Oral Med. Oral Pathol. Oral Radiol. Endod.*2001; 92:215–220.
11. Cheung, G. S. and C. S. Liu (2009). "A retrospective study of endodontic treatment outcome between nickel-titanium rotary and stainless steel hand filing techniques." *J Endod* 35(7): 938-43.
12. Peter Spili, Peter Parashos, Harold H. Messer, The Impact of Instrument Fracture on Outcome of Endodontic Treatment. *Journal of Endodontics* 31(12):845-50 • December 2005

with controversial issues like this it would be wiser from our side to be aware about the current developments in the same, then take decisions for each patient logically using personal expertise, specialist opinion and expert cardiac advice if found necessary.

► **References**

1. Thornhill MH, Lockhart PB, Prendergast B, Chambers JB, Shanson D. NICE and antibiotic prophylaxis to prevent endocarditis. Br Dent J 218(11): 619-621. doi:10.1038/sj.bdj.2015.392
2. Dayer MJ, Jones S, Prendergast B, Baddour LM, Lockhart PB, Thornhill MH (2015) Incidence of infective endocarditis in England, 2000-13: a secular trend, interrupted time-series analysis. Lancet 385: 1219-1228. doi: 10.1016/S0140-6736(14)62007-9
3. Journal of Irish Dental association; practice management; Infective endocarditis prophylaxis, summary information for dentists; Vol 55(2);April/may 2009; 102
4. D. Wray et al, Prophylaxis against infective endocarditis for dental procedures – summary of the NICE guidelines; BDJ Volume 204, No 10 May 24 2008; 555-557
5. Sarah McKernon; Antibiotic prophylaxis to prevent endocarditis; dental Nursing, Augustvol 11; No 8; 2015 482-483

6. FulviaCostantinides, et al; Antibiotic prophylaxis of infective endocarditis in dentistry; clinical approach and controversies, Oral health and preventive dentistry vol 12, no 4, 2014; 305-311
7. DayTer M J, Chambers J B, Prendergast B, Sandoe J A, hornhill M H. NICE guidance on antibiotic prophylaxis to prevent infective endocarditis: a survey of clinicians) attitudes. CUM 2013; 106: 237-243.
8. Lockhart PB, Brennan MT, Sasser HC, Fox PC, Paster BJ, Bahrani-Mougeot FK (2008) Bacteremia associated with toothbrushing and dental extraction. Circulation 117: 3118-3125. 10.1161/CIRCULATIONAHA.107.758524
9. Bor DH, Woolhandler s, Nardin R, Bruschi J, Himmelstein DU. Infective endocarditis in the U.S., 1998-2009: a nationwide study. PLoS One 2013;8(3): e60033.
10. National Institute for Health and Care Excellence (2008) Prophylaxis Against Infective Endocarditis: Antimicrobial Prophylaxis Against Infective Endocarditis in Adults and Children Undergoing Interventional Procedures. www.nice.org.uk/ guidance/cg64 (accessed July 13 2015)
11. Lewis T, Grant R. Observations relating to subacute infective endocarditis. Heart 1923; 10: 21-77.
12. Roberts GJ, Radford P, Holt R. Prophylaxis of dental bacteraemia with oral amoxycillin in children. Br Dent J 1987;162:179-182

The Largest Dental Portal of Kerala

Log on [www.idakerala.com](http://www.idakerala.com)

for IDA Activities, Reports, Publication etc...



## ‘ഡോക്ടറേ ഒരു സംശയം’

(ഒരു ദന്ത ഡോക്ടറുടെ ചികിത്സാനുഭവങ്ങൾ)

ഒരർമ്മയിൽ നിറഞ്ഞ അനുഭവങ്ങൾ കൗതുകമുള്ള കഥകളായപ്പോൾ വായനക്കാർക്ക് സംശയം തീർക്കുന്ന നല്ല പാഠങ്ങൾ ആവുകയാണ് ‘ഡോക്ടറേ ഒരു സംശയം’ എന്ന പുസ്തകത്തിലൂടെ. സ്വന്തം ദന്ത ചികിത്സാലയത്തിലെ സൂക്ഷ്മ നിരീക്ഷണങ്ങൾ ഡോ. പി.ബി സനോജ് കുറിച്ചിട്ടപ്പോൾ അതു പുസ്തക രൂപത്തിലിറക്കാൻ ഡി. സി ബുക്സ് തയ്യാറായതും വിഷയത്തിന്റെ പ്രസക്തിയും വായനാസുഖവും മനസ്സിലാക്കി കൊണ്ടുതന്നെ.

അങ്ങനെ 21 കഥകളിലൂടെ ദന്തരോഗ സംബന്ധമായ ഒരുപാട് ചോദ്യങ്ങൾക്ക് ലളിതമായ ഭാഷയിലുള്ള മറുപടിയായി പുസ്തകം എത്തുകയാണ്. ഈ പുസ്തകത്തിന്റെ പ്രകാശനം 2015 ഫെബ്രുവരിയിൽ പ്രശസ്ത സാഹിത്യകാരൻ ശ്രീ ബെന്യാമിൻ (ആടു ജീവിതം) നിർവ്വഹിച്ചു. സ്വന്തമായി ദന്ത ചികിത്സ ആരംഭിച്ച കാലത്തെ മണ്ടത്തരങ്ങളും ആധികളും തുറന്നു പറഞ്ഞുകൊണ്ടാണ് ‘ഇൻജക്ഷനും പുലിവാലും’ എന്ന ആദ്യ കഥ പുസ്തകത്തിൽ ഉൾപ്പെടുത്തിയിട്ടുള്ളത്. ആദ്യമായി സ്കൂളിൽ പോകുന്ന കൊച്ചു കുട്ടിയുടെ മാനസികാവസ്ഥയാണ് ആദ്യ ദന്ത പ്രാക്ടീസ് എന്നു ഡോക്ടർ പറഞ്ഞുവെക്കുമ്പോൾ പുസ്തകമെഴുത്തിൽ അത്തരം വ്യാകുലതകൾ ഇല്ലെന്നു ഓരോ അധ്യായവും നമുക്ക് കാണിച്ചു തരികയും ചെയ്യുന്നു.

യഥാർഥ അനുഭവങ്ങളുടെ രസച്ചരമു പൊട്ടി വീഴുന്നവയാണ്. എന്നാൽ ഒരു കഥയും വെറുതെ പറഞ്ഞു തീരുന്നില്ല. പല്ലിന്റെ ആരോഗ്യത്തെ കുറിച്ച് പൊതുവെ പ്രചരിക്കുന്ന തെറ്റിദ്ധാരണകളും സംശയങ്ങളും അകറ്റാനും നർമ്മത്തിൽ ചാലിച്ച ഈ പുസ്തകം പ്രയോജനപ്പെടും.

ഒരു വർഷം കൊണ്ടു തന്നെ ഈ പുസ്തകത്തിന്റെ ആദ്യ പതിപ്പ് വിറ്റഴിഞ്ഞു. പുസ്തകത്തിന്റെ രണ്ടാം പതിപ്പ് പ്രശസ്ത സാഹിത്യകാരനും നിരൂപകനുമായ പ്രൊഫസർ എം കെ സാനു മാഷ് 2016 ആഗസ്റ്റ് 7ന് കൊച്ചിയിൽ നടന്ന ഡി സി ഇന്റർനാഷണൽ ബുക്ക് ഫെസ്റ്റിവലിൽ വെച്ച് ഇന്ത്യൻ ഡെന്റൽ അസോസിയേഷൻ ദേശീയ പ്രസിഡന്റ് ഡോ. ഏലിയാസ് തോമസിനു നൽകിക്കൊണ്ട് പ്രകാശനം ചെയ്തു. ചടങ്ങിൽ ഡോ. ബാലു സോമൻ, ഡോ. സെബി വർഗ്ഗീസ്, ഡോ. കുനാൽ വിശ്വം തുടങ്ങിയവർ പ്രസംഗിച്ചു.

പ്രശസ്ത എഴുത്തുകാരൻ ശ്രീ ബെന്യാമിൻപുസ്തകം വായിച്ചിട്ട് കുറിച്ചു വരികൾ.

“ഈ പുസ്തകത്തിന്റെ വായന ഒരു നവ്യമായ അനുഭവമായിരുന്നു. നല്ല പാരായണ ക്ഷമതയുള്ള പുസ്തകം. ജീവിത സന്ദർഭങ്ങളെ കഥകളാക്കി മാറ്റിയ മനോഹര അനുഭവക്കുറിപ്പുകളാണ് ഈ പുസ്തകത്തിലുള്ളത്.”

ശ്രീ ബെന്യാമിൻ




212 KDJ – Vol. 39 • No. 3 • July 2016

► **Treatment procedure**

**1. Scaling of abutment teeth were done.**

**2. Denture fabrication**

Primary impression was made with irreversible hydrocolloid (Algitek, DPI, India) and custom tray was fabricated using cold cure acrylic resin. Border moulding was done using green stick (DPI, India). Secondary impression was made with light body elastomeric impression material (fig 2). Jaw relation and denture try in was done in the conventional manner and the denture processed.

**3. Abutment preparation and post placement**

Tooth was reduced to about 1mm above gingival margin. The attachment planned for placement is Access post overdenture system kit (Essential dental system {EDS} USA).

Gutta percha was removed with Peeso reamer to a specified length of the post according to manufacturers instruction. Primary reamer present in the kit is used to prepare full length of post after removal of gutta percha from the canal. Counter sink drills are used to create the flange and second tier around the neck of the tooth (fig 3).

After one canal is prepared, place a drill in the canal and start preparing the other canal. This is done to obtain the parallelism of the two attachments. The access posts were placed in the post space of both the mandibular canines to check the initial fit and then verified by taking a radiograph.

The canal was etched, irrigated with saline and dried with paper point. The canal and post is coated with resin cement and the cementation of post is done (fig 4).

**4. Attachment of of Nylon caps to denture**

The intaglio surface of the lower denture where it touches the attachment is marked and is relieved. Rubber band present in the kit were placed to cover the height of contour of the ball of post. Petroleum jelly is applied over the attachment post. Female part of the attachment, ie; nylon caps is placed over the attachment (fig 5). Cold cure acrylic resin is mixed and is loaded on to the relieved region and the denture is placed in the patients mouth. Patient is asked to close in centric relation position till the material sets. After the material sets, the denture is removed with nylon cap attached to intaglio surface of the denture. Rubber bands are removed. The flash is removed and finishing and polishing is done. The marginal gingival area can be slightly relieved to prevent irritation (fig 6).

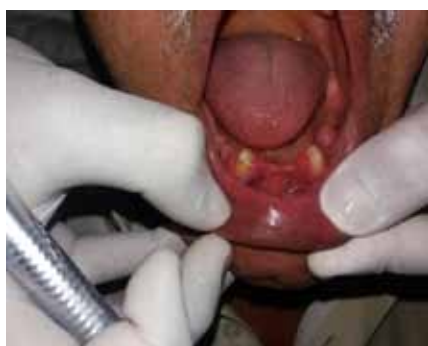

Fig. 1 Pre op photograph

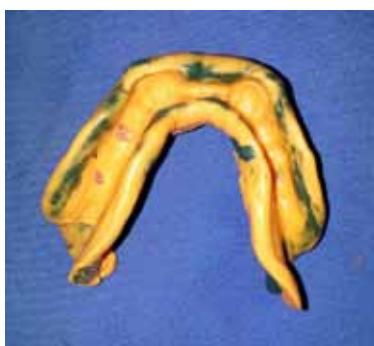

Fig. 2 Secondary impression

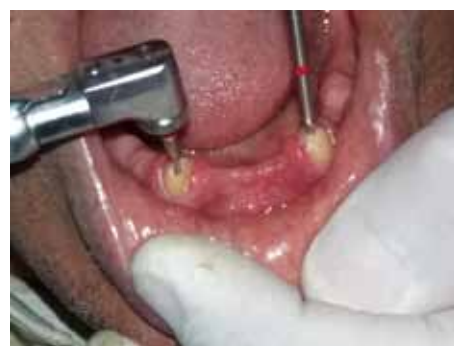

Fig. 3 Post space preparation

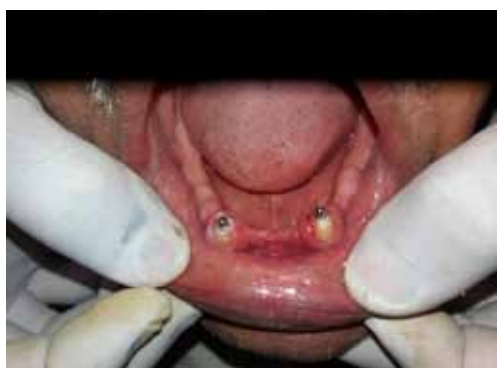

Fig. 4 Post cemented

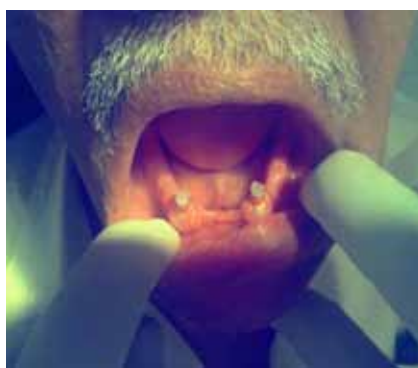

Fig. 5 Nylon cap placed

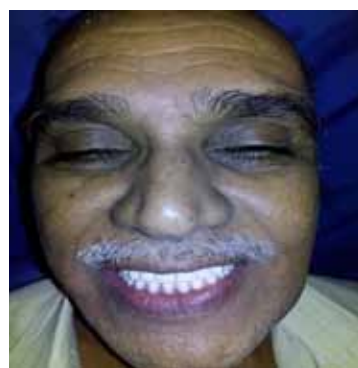

Fig. 6 Post op photograph

### ► Discussion

Preventive prosthodontics emphasizes the importance of any procedure that can delay or eliminate future problems. The basic concept of an overdenture is the preservation of hard and soft tissues in the oral cavity<sup>4</sup>. Tallgren (1972) conducted a study and reported that anterior mandible height resorbed four times faster than maxillary ridge with conventional dentures<sup>5</sup>. Crum and Runey in 1975 conducted a 5 year study on alveolar bone loss in overdentures and concluded that retention of mandibular canines for overdentures led to preservation of alveolar bone<sup>6</sup>. The success of the overdenture therapy depends upon the proper attachment selection for the particular case. Attachment selection is based on available buccolingual and inter arch space, amount of bone support, opposing dentition, personal preferences, clinical experience, maintenance problems and cost. Access posts are simplest type of stud attachments that work well with overdentures. The ball and socket attachment is patient friendly and easily placed into the denture without laboratory assistance. They occupy a small vertical space in denture. The small head of male attachment limits the amount of material that has to be removed from the denture. The ball and socket attachment of Access post allows rotation of the denture attachment. The nylon cap provides 3-5 pounds of retention<sup>3</sup>. The technical work required is minimal and can be carried out at chairside, thus making it cost effective. Access post overdenture is superior to any other passive overdenture because flange

and second tier dissipate functional stresses and prevents “bottoming out” eliminating the high apical stresses under function common to other passive posts.

### ► Conclusion

The concept of overdentures, though not a complete answer, provides a positive means of delaying the process of resorption of denture foundation. Although it is a feasible alternative, it is not often used to its full potential. Careful case selection and abutment preparation as well as periodic recall are the key to successful overdenture rehabilitation.

### ► Reference

1. Mahajan N, Thakur RJ. Overdenture locator attachments for atrophic mandible. *Contem Clin Dent*. 2013(4);4:509-511.
2. Cohen BI, Musikant BL, Deutsch AS. Clinical use of access post system. *Dent Today* 1998;17:120-121.
3. Jain DC, Hegde V, Aparna I, Dhanasekar B. Overdenture with accesspost system: A clinical report. *Ind J Dent Res* 2011;22(2):359-361.
4. Winler.S. Essentials of complete denture Prosthodontics, 2nd ed. 2000:384-02.
5. Tallgren A. The continuing reduction of the residual alveolar ridges in complete denture wearers: a mixed-longitudinal study covering 25 years. *The Journal of prosthetic dentistry*. 1972;27(2):120. 13.
6. Crum RJ, Rooney Jr GE. Alveolar bone loss in overdentures: a 5-year study. *The Journal of prosthetic dentistry*. 1978;40(6):610-3.
7. Burns DR. The mandibular complete overdenture. *Dental Clinics of North America*. 2004;48(3):603.

# HOMO SAPIENS DIVINE

Life's quest for perfection: From a strand of protein to exalted human and beyond

By Dr. Varghese Mani



**Video trailer**

<https://youtu.be/dVtAUiUb7Fk>

**To purchase**

<https://notionpress.com/read/homo-sapiens-divine>

### Description

Explicit evidence exists for the progression of life-over a period of three-and-a-half billion years-from a strand of protein to an intelligent human, through trial, rejection and selection. The process continues and, if not hindered, a higher destiny awaits us in the distant future.

Is life a property of matter? Is evolution a passive process? Or, does it have an aim or purpose? What is the role of beauty, intelligence and awareness in this evolutionary saga? Is eugenics going to hinder the natural process? Are we on our way to self-inflicted extinction?

This book ponders on these questions and attempts to trace life's quest for perfection-where beauty, vitality and wisdom meet.

# Restoration of severely worn dentition - a multidisciplinary approach

\* A V Sreekumar, \*\* Mohammed Sajeer, \*\*\*Levin Chengappa

## Abstract

Severe caries, attrition and developmental anomalies of anterior teeth lead to loss of anterior guidance. This in turn causes attrition of posterior teeth and loss of occlusal vertical dimension of occlusion. To gain the space for esthetic rehabilitation in these cases is challenging task. The required space can be achieved by crown lengthening and increasing the vertical dimension of occlusion within physiologic limits. We, hereby have presented a case report showing the treatment procedure of a patient with severely worn dentition in a simple and systematic multidisciplinary approach to improve the function as well as aesthetics, that also remains in harmony with the entire gnathostomatic system.

**Key words:** Decreased vertical dimension, Attrition, Esthetics, Full mouth rehabilitation, amelogenesis imperfecta

KDJ 2016 | Vol. 39 | No. 3 | Pg 221-223

## ► Introduction

Severely worn dentition cases are one of the most difficult cases to manage in dental practice. This is because such cases involve not only replacement of the lost tooth structure but also restoring the lost vertical dimensions. Full mouth reconstruction is basically a set of procedures that are aimed at restoring chipped or worn out teeth and correcting an improper bite position. Improper jaw position is implicated in various neuro-muscular problems. Correcting

the jaw position not only restores proper function, but also helps in enhancing the appearance of the patient.

Full mouth fixed rehabilitation is one of the greatest challenges in the field of prosthodontics. Apprehensions involved in the reconstruction of debilitated dentitions are increased by widely divergent views concerning the appropriate procedures for successful treatment.

The existing vertical dimension of occlusion (VDO) has to be assessed extra orally and intraorally before considering increasing the VDO. Sometimes the vertical dimension has to be restored or increased. The contributing factors for excessive wear of teeth are evaluated and should be removed or reduced if possible. These assessments reveal the merits of changing the VDO and permit the dentist to evaluate suitable treatment options. It is critical to verify loss of VDO before the reconstruction of an increased VDO. The different techniques that can be used are use of phonetics method, evaluation of interocclusal distance and the evaluation of soft tissue contours.

This article discusses a multidisciplinary approach in a severely worn dentition by restoring esthetics and function

## ► Case report

A 60 year old male patient was referred to the department of prosthodontics, Kannur Dental College, Anjarakandy. with a chief complaint of inability to chew, and poor dental

esthetics. The general medical condition was satisfactory, intraoral examination revealed generalized attrition in all mandibular teeth, maxillary posterior teeth and chipping of enamel in maxillary anterior teeth. Teeth numbers 26,27,37,46,47 were missing, joined crown was noticed on 15,16,17,18. and tooth number 21 was prepared for crown. (Fig. 1)

On the basis of clinical and radiographic examination, diagnosis was made as amelogenesis imperfecta with reduced vertical dimension of occlusion. Full mouth rehabilitation of the mouth was planned to restore the function, aesthetics, speech and comfort of the patient. The patient was informed of the diagnosis, the treatment planning and his consent was taken before start of the procedure.

Reduction in vertical dimension were confirmed using different methods like: use of phonetics, the use of interocclusal distance, use of facial measurements and the evaluation of soft tissue contours.

Due to the presence of decreased VD (fig, 1), an increase in VD was first considered. By giving occlusal splint. But because of severely attrited mandibular teeth with inadequate clinical crown and pulp exposure it is difficult to place a occlusal splint on mandibular arch,

From clinical and radiological examination endodontic treatment of teeth 35,34,32,31,41,42,43,44 were planned and performed (fig;2). Extraction of 36 done because of unrestorable condition.

\* Professor & HOD, \*\* PG student, \*\*\* Reader, Department of Prosthodontics and Crown and Bridge, Kannur Dental College, Kannur • Corresponding Author: Dr. Mohammed Sajeer PC, E-mail: sajeerpc.sajeer@gmail.com

Then the crown lengthening procedure of mandibular teeth were done to increase the clinical crown height. Fig;3

Restoration of lost vertical dimension 6mm planned. First Vertical dimension was increased by 2mm using an occlusal splint which was fabricated using self cure clear acrylic resin at centric relation, which was cemented to mandibular teeth for a period of 6 wks. After 6 wks height of splint was raised

to 4mm placed back to patient mouth. At the end of 6th week no abnormal findings were noted and as the patient was comfortable, 2mm increase in the VDO as planned earlier was performed.

After establishing the vertical dimension prosthetic rehabilitation started. Since there were no pulp exposure maxillary teeth were restored with fixed partial denture. Post

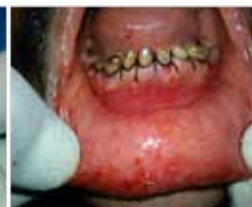
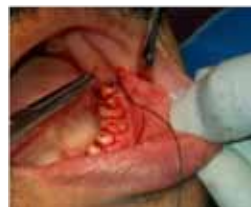
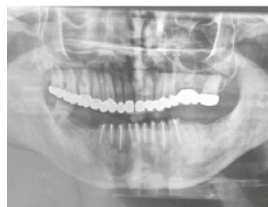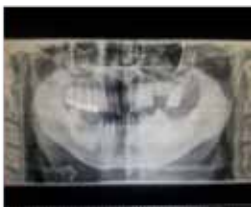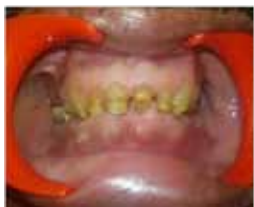Fig. 1

Fig. 2

Fig. 3

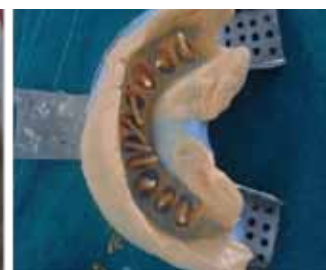
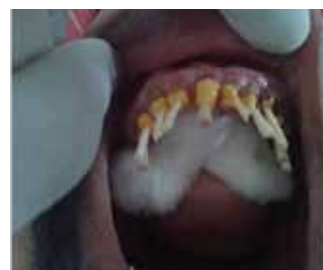
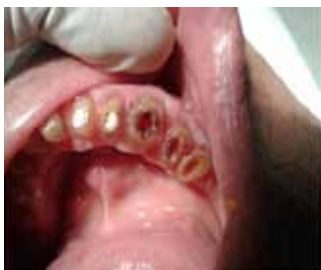Fig. 4

Fig. 5

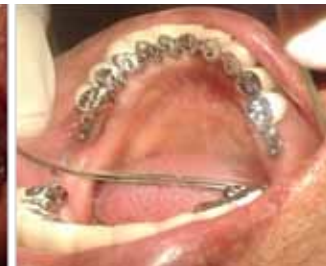
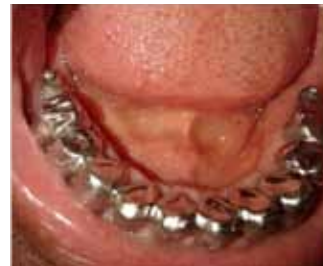
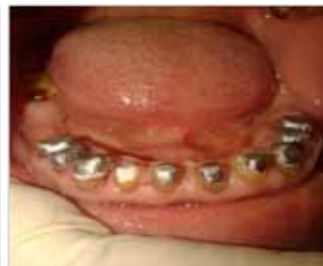Fig. 6

Fig. 7

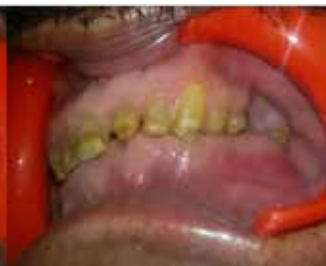
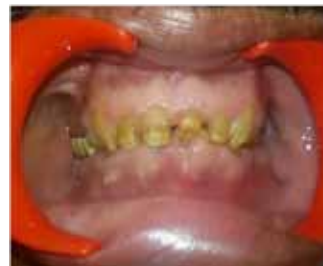
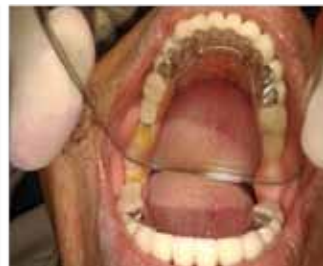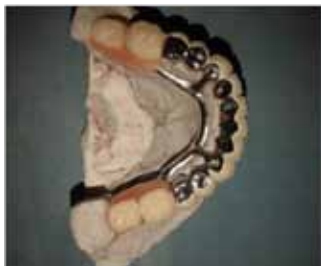Fig. 8

Fig. 9

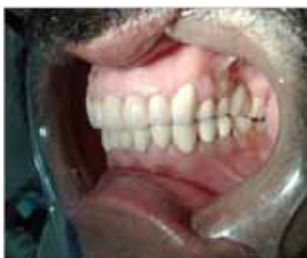
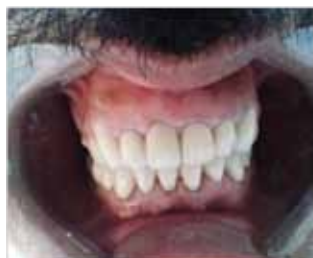
Fig. 10



core were done on mandibular teeth 35,34,32,31,41,42,43,45,46 to attain favorable clinical crown for FPD (fig; 4,5,6). Patient was very much concerned about esthetics replacement of lower posterior with cast partial denture with out visible clasp assembly was made (fig; 7,8,9,10)

### ► Discussion

Reconstruction of severely attrited dentition is a challenge to a dentist's skill and capabilities. It demands rehabilitation and reconstruction within the physiological and functional harmony of the stomatognathic system. For occlusal rehabilitation two occlusal philosophies are present. One advocates simultaneous reconstruction of both arches and the other advocates complete restoration of one segment in a programmed sequence before proceeding to the next. The concept of complete mouth rehabilitation is basically depends upon three proved and accepted principles. These are; the existence of a physiological rest position of the mandible which is constant, the recognition of a variable vertical dimension of occlusion (VDO) and the acceptance of a dynamic, functional centric occlusion. Thus the aim of rehabilitation includes the health of the periodontium, vertical dimension, interocclusal distance, functional balanced occlusion and esthetics. The presence of caries, restoration, attrition or a combination of these conditions can cause teeth to have little intact coronal tooth structure remaining, resulting in loss of vertical dimension of occlusion. Many clinical studies indicate that, vertical dimension of occlusion is maintained even with rapid wear. As the occlusal surface wears, compensatory alveolar process elongates by progressive remodeling of the alveolar bone. As a result there is no loss of vertical dimension unless tooth loss occurs. However, occlusal wear may occur more rapidly than continuous eruption depending on the etiology of the wear. Therefore, it is critical to verify loss of occlusal vertical dimension prior to restoration at an increased vertical dimension. So combination of methods like phonetics, facial appearance and measuring the interocclusal distance are used to verify the lost vertical dimension. Occlusal splint is used as a means to raise the vertical dimension of occlusion for 6 weeks. Basic function of a splint is referred to as muscle deprogrammer and it helps the condyle in returning to their centric relation position.

In our case the patient was presented with a couple of other treatment options. One of the options was to remove all the teeth and prepare a full denture for lower arch FPD for upper arch. Another treatment option was saving all the anterior and premolars teeth in lower arch and extracting all the other teeth and making a normal cast partial denture after increasing vertical dimension by crowns. Third option was extraction of some teeth followed by over denture. Fourth

option was to restore the entire dentition with porcelain fuse to metal crown by increasing the vertical dimension and lower posterior with clasp less RPD. Fifth option was restoration of missing teeth with implant prosthesis. The patient refused to get his teeth extracted. He was interested on saving all the teeth which are possible and was prepared to undergo any amount of extensive treatment to achieve the end result. And he was apprehensive about implants and he want to avoid metal display of RPD. So the patient was planned to restore the entire dentition with porcelain fuse to metal crown by increasing the vertical dimension of occlusion by 6mm. with clasplless RPD.

### ► References

1. D'Incau E, Couture C, Maureille B. Human tooth wear in the past and the present: Tribological mechanisms, scoring systems, dental and skeletal compensations. *Arch Oral Biol* 2012;5(3):214-29.
2. Turner KA, Missirlan DM. Restoration of the extremely worn dentition. *J Prosthet Dent* 1984;52(4):467-74.
3. Goldman I. The Goal of Full Mouth Rehabilitation. *J Prosthet Dent* 1952;2(2):246-51.
4. Krishna MG, Rao KS, Goyal K. Prosthodontic management of severely worn dentition: including review of literature related to physiology and pathology of increased vertical dimension of occlusion. *J Ind Prosthodontic Society* 2005;5(2):89-93.
5. Abduo J. Increasing occlusal vertical dimension. *Dental Abstracts*. 2013;58(2):81-3. *Malaysian Dental Journal* (2014) 36(1) 23-29
6. Sato S, Hotta TH, Pedrazzi V. Removable occlusal overlay splint in the management of tooth wear: A clinical report. *J Prosthet Dent*. 2000;83(4):392-5.
7. Koksall T, Dikbas I, Kazaoglu E. Alternative Restorative Approach for Treatment of Patient with Extremely Worn Dentition. *N Y State Dent J*. 2009;75(5):52-5.
8. Kleeberger BG. Restoring the worn dentition for function and aesthetics. *J Cosmet Sci*. 2007;23(2):82-92.
9. Binkley TK, Binkley CJ. A practical approach to full mouth rehabilitation. *J Prosthet Dent*. 1987;5(3):261-6.
10. Stewart B. Restoration of the Severely Worn Dentition Using a Systematized Approach for a Predictable Prognosis. *Int J Periodontics Restorative Dent* 1998;18(1): 46-57.
11. Hunt KH. Full mouth multidisciplinary restoration using the biological approach: a case report. *Pract Proced Aesthet Dent*. 2001;13(5):399-406.
12. Hegde C, Krishna DP, Jacob SJ, Shetty M. Full mouth rehabilitation of a severely worn out dentition to functional harmony. *J Indian Prosthodont Soc*. 2009;9:164-6.
13. Johansson A, Johansson AK, Omar R, Carlsson GE. Rehabilitation of the worn dentition. *J Oral Rehabil*. 2008;35(7):548-66.
14. Song MY, Park JM, Park EJ. Full mouth rehabilitation of the patient with severely worn dentition: a case report. *J Adv Prosthodont*. 2010;2(3):106-10.
15. Rugh JD, Drago CJ. Vertical dimensions: a study of clinical rest position and jaw muscle activity. *J Prosthet Dent*. 1981;45(6):670-5.
16. Hellsing G. Functional adaptation to change in vertical dimension. *J Prosthet Dent* 1984;52(6):867-70.

# Ridge mapping- ‘a map to success’

\*Vivek B. Chandran, \*P. Rajkumar, \*\*T. Sreelal, \*\*\*Aparna Mohan, \*\*\*\*Giri Chandramohan

## Abstract

Implants are the new era of treatment for edentulism which not only provides aesthetics but also improves the function and speech ability of the individual. For placement of implant assessment of underlying alveolar bone is at most important. The assessment of alveolar bone should be done in a multi-dimensional way to ensure the longevity and function of the implant. There are direct as well as radiographic methods for assessment of the alveolar bone. In this review, various methods to evaluate the parameters of alveolar bone required for proper implant placement is explained in brief.

KDJ 2016 | Vol. 39 | No. 3 | Pg 224-227

## ► Introduction

Implants are today a common and most widely accepted treatment for edentulism. The quality and quantity of the bone available at the implant site is of primary importance. Precise measurement of alveolar bone and adjacent anatomic structures are of utmost importance in implantology. Proper pre-surgical assessment requires accurate radiographic visualization of anatomic structures and pathologic conditions.

## Available bone:

A multidimensional assessment of the available bone in the edentulous region is the most important factor

necessary for a sound treatment planning ensuring longevity and functionality of the implant<sup>1</sup>.

Determinants of available bone are:- 1.height 2.width 3.length 4.angle 5.crown/implant ratio

The minimum implant length in an ideal bone density situation for predictable success is 10mm, allowing a safe distance of 2mm from vital landmarks like inferior alveolar canal. Available width is defined as the distance between the buccal and lingual plates, measured at the crest. Each 1mm increase in diameter increases the surface area by 20-30%, thus implant diameter is much more critical than its length. Implant length, on the other hand only improves initial stability<sup>2</sup>.

## ► Ridge mapping

Ridge mapping is the evaluation of bucco-lingual dimension of the alveolar ridge which is an important pre requisite in implant dentistry. The various methods of ridge mapping can be considered as Invasive and Non-Invasive (Table-1)

## Invasive methods

They can be either using ridge mapping calipers or with the help of various stents.

## A. Ridge mapping calipers.

They are forceps like devices having gradations at one end & the other end has pointed beaks which come in

contact with the alveolar bone piercing the mucosa (Fig. 1 and Fig. 2). It is an invasive method and therefore it must be performed only after administration of local anaesthetic agents. It is considered as the most economic and simplest in-office method of evaluation of the dimensions of alveolar ridge.

## B.Stents

Stents fabricated using self-cure acrylic and also vacuum adapted thermoplastic sheets can be used for this purpose. They can be used for immediate implant placement as well as conventional two stage implants.

## Conventional implant placement

For conventional two stage implants, self-cure acrylic stents are fabricated which covers the implant site. A series of calibrated holes every 2 mm are made on the labial and palatal region of the stent covering the implant site. Following administration of local anesthetic, the stent was placed in the patient's mouth and calibration is done with endodontic files to measure the thickness of the mucosa covering the bone. Transfer the ridge mapping readings recorded to the sectioned cast (Fig. 3)

## Immediate implant placement

For immediate implant placement, prior to extraction of the tooth, during the first appointment an impression is made and a diagnostic cast is made. A stent is prepared using a vacuum-adapted thermoplastic sheet<sup>3</sup>. A series of

\*P.G Students, \*\*Professor and Head of the Department, \*\*\*Senior Lecturer, \*\*\*\*Reader, Dept of Prosthodontics, Sree Mookambika Institute of Dental Science, Kulasekharan, Kanyakumari, Tamilnadu  
• Corresponding Author: Dr. Vivek B. Chandran

calibrated holes every 2 mm are made on the labial and palatal region of the stent covering the tooth to be extracted and after administration of local anaesthetic, the stent is placed in the patient's mouth and calibration is done with endodontic files to measure the thickness of the mucosa covering the bone. Now an accurate impression of the arch is made using an elastomeric impression material of putty consistency following that atraumatic tooth extraction is done under local anesthesia without fracturing the tooth. The tooth which is extracted is then placed in the putty impression and a cast is poured (Fig. 4)<sup>3</sup>. The cast thus obtained is sectioned along the long axis of the tooth and the stent with the readings are transferred onto it (Fig. 5)<sup>3</sup>.

**2. Non-invasive Methods**

The discovery of X-rays by Roentgen in 1895 revolutionized dentistry<sup>4,5</sup>. Various two dimensional and three dimensional imaging modalities are now available.

**A. Peri-apical radiographs, occlusal radiographs & OPG's**

These are two dimensional imaging modalities which can be used for preliminary diagnosis which gives an idea of the available bone, underlying lesions, granulomas, demineralised areas and calcifications. They cannot be considered as accurate as they are flat projection of a curved structure. With the help of peri-apical radiographs the available bone height can be roughly calculated (Fig. 6) so that implants with adequate lengths can be selected and with the help of occlusal radiographs an approximate width of the osseous ridge can be measured (Fig. 7) so that implant with maximum diameter can be selected.

**B. Computed tomography imaging**

Ever since its introduction in 1972 by Godfrey Hounsfield it has become an important tool in the field of imaging, they are found to be 100 times more sensitive than conventional



Fig. 1

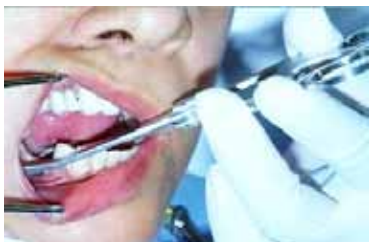

Fig. 2 Caliper in contact with the alveolar bone

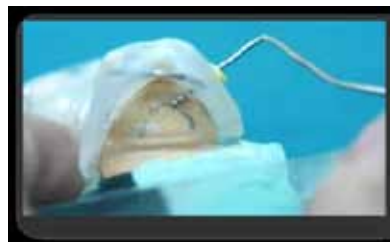

Fig. 3

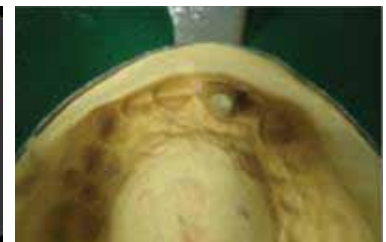


Fig. 4

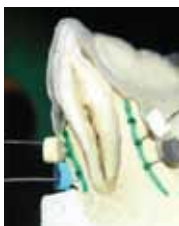


Fig. 5

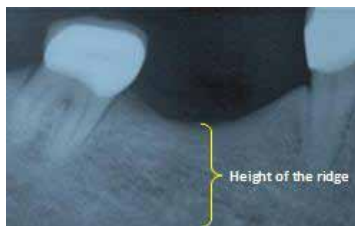

Fig. 6

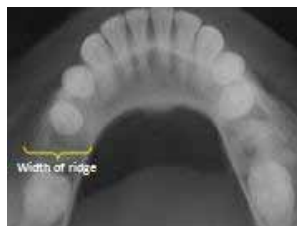

Fig. 7

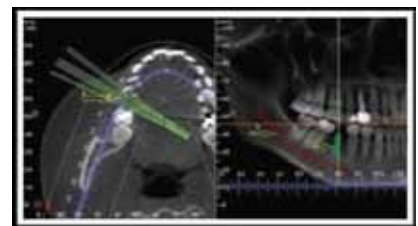


Fig. 8

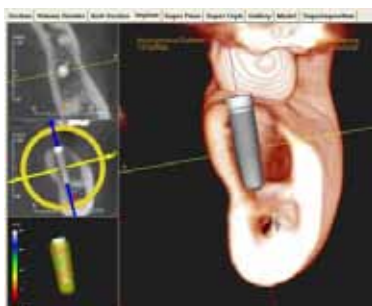

Fig. 9

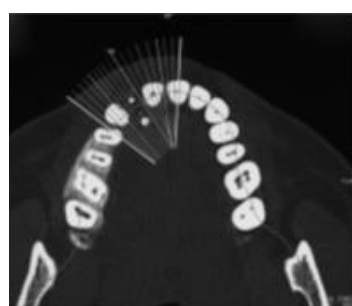


Fig. 10 Slicing region of interest<sup>7</sup>

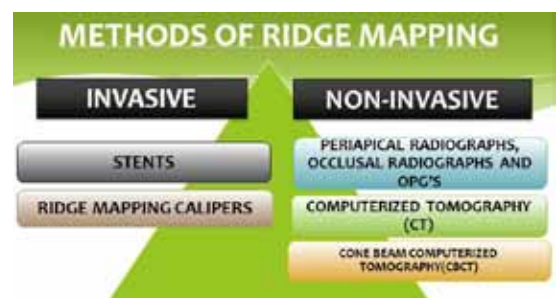


Table I

radiographs<sup>6</sup>. CT images are digital images reconstructed by computer, which mathematically manipulates the transmission data obtained from multiple projections<sup>7,8</sup>. According to the results obtained from a study conducted by Chugh et al, there is no significant difference in CT and direct surgical exposure measurements, which supports the use of CT method for the evaluation of alveolar ridge width measurements in areas where the ridges are resorbed, there are maxillary anterior ridge concavities, high lingual frenum areas, and vestibular depth is less<sup>9</sup>.

### C. Cone beam computed tomography (CBCT)

CBCT has become increasingly important in treatment planning and diagnosis in implant dentistry<sup>10</sup>. The American Academy of Oral and Maxillofacial Radiology (AAOMR) also suggests cone-beam CT as the preferred method for pre-surgical assessment of dental implant sites. During dental imaging, the CBCT scanner rotates around the patient's head, obtaining up to nearly 600 distinct images. The angulation of placement of the implant, dimensions of the implant, the bone width and height and the location of the anatomical landmarks can be easily found accurately with the help of CBCT imaging. It even enables slicing of the region of interest into multiple slices<sup>7</sup>.

### ► Conclusion

The most frequently used imaging modalities in implant dentistry are proposed based on the clinical need and biologic risks associated with the patient. CBCT and OPG are two common imaging modalities used in implant dentistry<sup>7</sup>. Direct mapping using calipers and stents are also a reliable method for measuring the width of the bone available for implantation. It is always recommended to use three dimensional imaging

modalities like CT and CBCT in conditions where the alveolar ridges are resorbed, incidence of maxillary anterior ridge concavities, there are high lingual frenum areas and also in situations where vestibular depth is inadequate<sup>5,7</sup>.

### ► References

1. Goyal S and Iyer S. Bone Manipulation Techniques; International Journal of Clinical Implant Dentistry. Jan-April 2009; 1(1):22-31.
2. Misch Carl E. Contemporary Implant Dentistry. 2nd ed. Pittsburg: Mosby; 1999.
3. Chandraker NK, Chowdhary R, Verma A. Technique to assess the alveolar bone width for immediate implant placement in fresh extraction sockets. Indian J Dent Res. 2013; 24:784-6.
4. Chen ST, Wilson TG Jr., Hammerle CH. Immediate or early placement of implants following tooth extraction: Review of biologic basis, clinical procedures, and outcomes. Int J Oral Maxillofac Implants 2004; 19(1): 12-25.
5. Belsler, U., Buser, D. & Higginbottom, F. (2004) Consensus statements and recommended clinical procedures regarding esthetics in implant dentistry. International Journal of Oral and Maxillofacial Implants 19 (1.): 73-74.
6. Halazonetis J. Demetrios. From 2-dimensional cephalograms to 3-dimensional computed tomography scans. American J. 2005; 127(5): 627-637
7. Amarnath GK, Kumar U, Hilal M, Muddugangadhar BC, Anshuraj K, Shruthi CS. Comparison of Cone Beam Computed Tomography, Orthopantomography with Direct Ridge Mapping for Pre-Surgical Planning to Place Implants in Cadaveric Mandibles: An Ex-Vivo Study. J Int Oral Health 2015; 7(7):1-5
8. Ito K, Gomi Y, Sato S, Arai Y, Shinoda K. Clinical application of a new compact CT system to assess 3-D images for the preoperative treatment planning of implants in the posterior mandible. A case report. Clin Oral Implants Res. 2001; 12:539-542
9. Chugh A, Bhisnoi P, Kalra D, Maggu S, Singh V. Comparative evaluation of three different methods for evaluating alveolar ridge dimension prior to implant placement: An in vivo study. J Dent Implant. 2013; 3:101-10,
10. Hatcher DC, Dial C, Mayorga C. Cone beam CT for pre-surgical assessment of implant sites. J Calif Dent Assoc. 2003;31(11):825-3



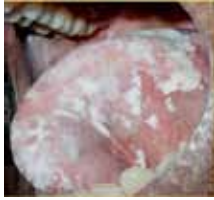## OBITUARY

Dr R N Shenoy was born in Kochi as the son of a business man. Graduated from Nair Dental College, Mumbai and started his own practice at Kochi in 1967. He was instrumental to start IDA in Kerala and was a charter member of the Kerala State. As a Kochi branch member he involved in various activities and his own clinic was a venue for several Executive meetings of IDA in earlier days. He was the past president of IDA Kochi branch, past treasurer of IDA Kerala

State during 84-87 and President of IDA Kerala State during 1992-93. He was involved in various state and national conferences as committee chairman. Married to Smt. Thamkamma and only son is an engineer in the ship. His spontaneous jokes and satire always attracts others and infact a soft spoken gentleman passionate and valued friendship. His death created a vacuum among whole of the IDA branches and we all pray for the departed soul.

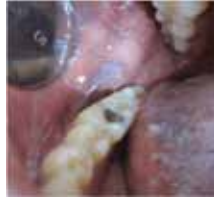\* Jayanthi, \*\* Varun B.R.

1. A 60 year old male patient reported with the complaint of white patches on the tongue. On examination, scrapable, curdy white patches were seen on the dorsum of the tongue. History revealed that the patient had uncontrolled diabetes. Topical application of clotrimoxazole resulted in resolution of the lesion. The probable diagnosis is:



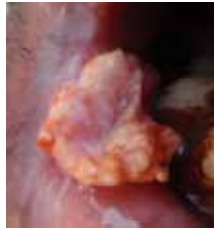- a. Leukoplakia,                      b. White spongy nevus  
c. Pseudomembranous candidiasis      d. Leukedema

2. A 45 year old female patient reported with mild burning sensation of right buccal mucosa. History revealed that the patient developed the symptoms following the placement of amalgam restoration in lower right molar tooth. On examination, white radiating striae were noted on the right buccal mucosa adjacent to 46 region. Which of the following is the appropriate clinical diagnosis?



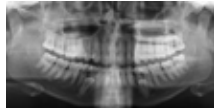
- a. Reticular lichen planus,      b. Erosive lichen planus  
c. Atrophic lichen planus      d. Lichenoid mucositis

3. A 62 year old male patient reported with the complaint of growth on the lower lip for the past 6 months. Clinical examination revealed proliferative growth on the right lateral aspect of lower lip, showing finger like projections. The patient had given a history of chewing tobacco for the past 20 years. Histopathology revealed parakeratin plugging and broad bulbous rete ridges. The diagnosis is:



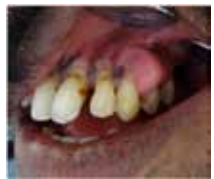- a. Verrucous carcinoma              b. Verruca vulgaris  
c. Keratoacanthoma                  d. Condyloma accuminatum

4. A 30 year old male patient visited the dental hospital with the complaint of pain in the right side mandibular third molar region. OPG revealed partially impacted 48 and 38. Impacted supernumerary teeth were also noted bilaterally in the mandibular premolar region. Multiple impacted supernumerary teeth are noticed in which of the following syndromes?



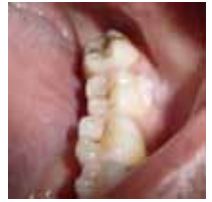- a. Cleido-cranial dysplasia      b. Gardner's syndrome  
c. Peutz-Jegher syndrome      d. Both a and b

5. Intra oral examination of a 40 year old male patient revealed a firm, non tender swelling of the gingiva between 23 and 24 regions. His oral hygiene was poor and radiograph did not reveal any bone changes. Excisional biopsy was performed and histopathological examination showed dense fibrous connective tissue with focal areas of bone formation. The diagnosis is:



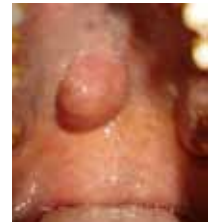- a. Peripheral giant cell granuloma,      b. Central giant cell granuloma  
c. Peripheral ossifying fibroma      d. Central ossifying fibroma

6. A 50 year old female patient presented with an exophytic growth on the buccal marginal gingiva in relation to 37 region. The surface of the lesion had finger like projections. The lesion was sessile, white in color and non tender. Histopathology revealed hyperplastic stratified squamous epithelium thrown into finger like projections with thin connective tissue core. The diagnosis is



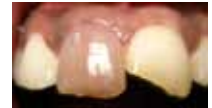- a. Squamous papilloma,      b. Verrucous hyperplasia  
c. Verrucous carcinoma,      d. Keratoacanthoma

7. A 45 year old female patient reported with a slow growing swelling of the hard palate since 8 months. On examination, a swelling was noticed on the posterior region of the hard palate towards the mid line. The swelling had a smooth surface and was firm in consistency and non tender on palpation. Histopathology showed proliferation of ductal and myoepithelial cells along with a chondromyxoid stroma. Which of the following is the appropriate diagnosis?



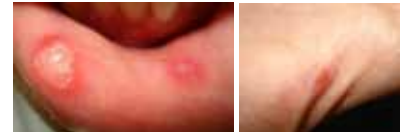- a. Pleomorphic adenoma,      b. Myoepithelioma  
c. Oncocytoma,                      d. Basal cell adenoma

8. A 15 year old boy reported with a discolored upper anterior tooth. History revealed that he had a fall from the bicycle 5 years back, following his left maxillary central incisor was fractured. On examination, his right maxillary central incisor was pink in color. Which of the following conditions best describes this clinical condition?



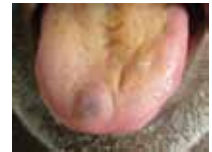- a. Acute reversible pulpitis,      b. Chronic irreversible pulpitis  
c. Internal resorption,              d. External resorption

9. A 22 year old male patient reported with a history of vesicles and ulcers of mouth since one week. On examination, ulcers were noticed on the lower lip, buccal mucosa and palate. The patient also had lesions on the hand which appeared as concentric layers of erythematous rash. General physical examination revealed conjunctivitis and urethritis. Patient gave a history of antibiotic intake one week back following which the lesions appeared. The diagnosis is



- a. Steven - Johnson syndrome,      b. Ehler - Danlos syndrome  
c. Gorlin - Goltz syndrome      d. Goltz-Gorlin syndrome

10. A 52 year old male patient reported with a small swelling on the tongue since 7 months. Intra oral examination showed a swelling on the dorsum of the tongue in the anterior 2/3rd, measuring around 1x1.5cm in size. The surface of the lesion was smooth and had a bluish discoloration. The swelling was soft in consistency and non tender. Histopathology showed proliferation of sheets of polygonal cells with numerous cytoplasmic granules. The diagnosis is



- a. Hemangioma                      b. Lymphangioma  
c. Granular cell tumor              d. Neurofibroma

Answers: 1. c, 2. d, 3. a, 4. d, 5. c, 6. a, 7. a, 8. c, 9. a, 10. c

\* Professor, Dept. of Oral & Maxillofacial Pathology, Azeezia Dental College, Kollam; \*\*Reader, Dept of Oral & Maxillofacial Pathology, PMS Dental College, Trivandrum  
E-mail: drjayanthip@gmail.com

# About IDA

The Indian Dental Association (IDA) is an authoritative, independent and recognized voice of dental professionals in India, and is committed to public oral health, ethics, science and advancement of dental professionals through its initiatives in advocacy, education, research and development of standards.

IDA membership opens a -- gateway to make a difference in your practice and your profession. Your collective support gives strength to our voice, the profession, educate the public and advocate for health care that works.

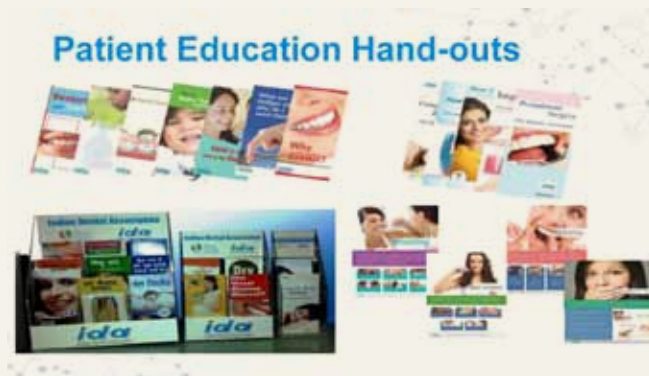## Membership participation programme Health Initiatives – TII, OCF, CDC, EDC



**National Oral Health Programme an initiative of the Indian Dental Association (IDA) affirms that oral health is essential to general health and well-being**

## IDA catalogue

IDA catalogue offers a wide range of patient education material for dental professionals to educate their patients in an innovative way in their clinic while they wait at the reception. The resource is developed for members to develop IDA's brand in patients. IDA catalogue offers patient education leaflets, wall posters, post-operative instruction card of various treatments which are helpful to enhance their communication while they consult their patients. Membership plaque, acrylic stands enhances the brand reputation.



**IDA Publications** allow dental professionals and IDA members to stay ahead and updated about the latest technology, practice management and clinical procedures by supplementing their clinical knowledge and experience. These publications provide in depth information on different aspects of dentistry offering a vast amount of data and knowledge useful for dental professionals. IDA publishes seven publications like IDA times, Dental Events, JIDA, Product Profile, Oral Health, and Clinical Dentistry and Student Digest at most affordable price for its members.



## Financial benefits

Besides the regular membership benefits, IDA has recently launched its Membership Advantage Program to provide financial benefits to its member.

Under this program IDA has partnered with reputed brands and companies to provide exclusive discounts, bonuses, and coupons to IDA members.

IDA has partnered with Kotak Bank to help dental professionals and students with educational loan, gold loan, car loan, personal loans and many more banking products. With IDA Pro Plan members can get access to the best medical care and treatment while being financially protected. These insurance products designed to meet specific requirements of dentist members, such as individual health insurance, family health insurance, motor insurance, travel insurance, professional indemnity insurance. Clarks group of hotels is providing up to 30% discount stay across their locations in India. The hotel group also offers exclusive discounts on banquets. Dining Plus card along with IDA membership offers members the privilege to choose from a wide range of dining and accommodation benefits at discounted rates. It also includes numerous lifestyle benefits, health and fitness offers. With the dining plus card the subscriber can avail discounts at 2,500 outlets in India, 300 in Far East and 350 in U.A.E, A 3D2N free stay from any of the specified 63 holiday destinations in India, free movie tickets, free Health check up voucher, reward points and more.

# IDA - Faculty List

## 1) DR ABDUL LATHEEF

EMAIL: varpil@gmail.com mob; 9447268913

- A) SMART PRACTICE (PRACTICE MANAGEMENT MODULE FOR DENTAL SURGEONS)
- B) THE CHEMISTRY OF RELATIONSHIPS (FAMILY EMPOWERMENT PROGRAMME)

## 2) DR AJI KUMAR

EMAIL: acesmile123@gmail.com mob; 9847243553

- A) SIMPLIFIED SHADE SELECTION
- B) "CERAMICS": CLINICAL AND LABORATORY ASPECTS FOR PRECISION WORK

## 3) DR AJI MATHEW THOMAS

EMAIL: drajimatthew@gmail.com mob; 8281606260

- A) OBSTACLES IN ENDODONTICS
- B) ROLE OF ROTARY TAPERS IN ENDODONTIS

## 4) DR. ANAND P.K

EMAIL: drpkanandida@gmail.com mob; 9895080522

- A) "PLANNING RETENTION AND MINIMIZING RELAPSE AFTER ORTHODONTIC TOOTH MOVEMENT"
- B) APPLIANCE SELECTION AND PATIENT MOTIVATION ASPECTS IN FIXED ORTHODONTIC CASES"

## 5) DR. ANJANA G

EMAIL: dranganag72@gmail.com mob; 9447115816

- A) THE PROBLEM KID: TIPS AND TRICKS
- B) DENTAL TRAUMA: CONCEPTS AND MISCONCEPTIONS

## 6) DR. ANNEY GEORGE

EMAIL: georgeanney2000@yahoo.com mob;9747004055

- A) HEPATITIS & DENTISTRY
- B) OCCUPATIONAL HAZARDS IN DENTISTRY

## 7) DR ANU GEORGE

EMAIL: anusaara@gmail.com mob; 9446562968

- A) SMILE DESIGNING
- B) STERILIZATION AND DISINFECTION

## 8) DR. ANURADHA R MALLYA

EMAIL: anumallya@gmail.com mob; 9645078807

- A) QUALITY MANAGEMENT IN DENTAL CLINICS
- B) PERIODONTICS SIMPLIFIED FOR GENERAL PRACTITIONERS

## 9) DR ARUN SADASIVAN

EMAIL: sadasivan\_arun@hotmail.com mob; 9847246961

- A) DIAGNOSIS AND MANAGEMENT OF PERIODONTAL DISEASE & BONE GRAFTING IN PERIODONTAL REGENERATION
- B) INTER DISCIPLINARY DENTISTRY (-THE ORTHO PERIO..ENDO PERIO ....PROSTHO PERIO LINK) AND PERIODONTAL MEDICINE ( THE LINK BETWEEN MEDICAL CONDITIONS AND GUM DISEASES)

## 10) DR CIVY V PULAYATH

EMAIL: publicealthdentist@gmail.com mob; 9895677477

- A) CTRL+ ALT+DEL THE INSIGHT INTO PREVENTIVE DENTISTRY
- B) DENTIST NO1 TIPS AND TRICKS ON SUCCESSFUL DENTAL PRACTICE

## 11) DR ELDO KOSHY

EMAIL; eldokoshy@koshysdentalclinic mob; 9497646938

- A) INFECTION CONTROL IN DENTAL OFFICES
- B) DENTAL IMPLANT PROSTHODONTICS AND IMPLANT COMPLICATIONS

## 12) DR GEORGE JOSE

EMAIL: drgeorgejose@gmail.com mob; 9446288387

- A) EARLY AGE TREATMENT OF SKELETAL AND NON SKELETAL PROBLEMS
- B) SURGICAL AND NON SURGICAL (CAMOUFLAGE ) MANAGEMENT OF SKELETAL MALOCCLUSIONS

## 13) DR GOPU HAREENDRALAL

EMAIL: gopuhareendralal@gmail.com mob; 9562506999

- A) "TOOTH ACHE IN CHILDREN": AN ENIGMA TO PARENTS AND GENERAL DENTIST. PULP THERAPY AND POST ENDODONTIC RESTORATION IN PEDIATRIC DENTISTRY
- B) "BRACES ARE NOT WORN ONLY AFTER 12" A PRACTICE REVIEW OF PREVENTIVE AND INTERCEPTIVE ORTHODONTICS

## 14) DR JAIBIN GEORGE

EMAIL: drjaibin@gmail.com mob; 9447796026

- (B) IMPLANTOLOGY FOR BEGINNERS AND BONE AUGMENTATION TECHNIQUES IN IMPLANT DENTISTRY
- (A) IMMEDIATE LOADING IMPLANTOLOGY AND IMPLANTS IN ESTHETIC ZONE

## 15) DR. JAINI J L

EMAIL: drjainij@gmail.com mob; 9447461776

- A) "CEMENTATION OF ALL CERAMIC RESTORATIONS"
- B) "PORCELAIN LAMINATE VENEERS: A DOOR WAY TO ESTHETIC SMILE"

## 16) DR JOHN C.P.

EMAIL: drcpjohnvm@gmail.com mob; 9745224522

- A) MARKETING YOUR PRACTICE WITHOUT ADVERTISEMENTS
- B) CREATED INVISIBILITIES IN DENTISTRY

## 17) DR JOY KURIAN

EMAIL: drjoykurian@gmail.com mob; 9447054054

- A) PEDIATRIC DENTISTRY UPDATE
- B) RECENT ADVANCES IN DENTISTRY

## 18) DR JUSTIN MATHEW

EMAIL: justmatt1973@gmail.com mob; 9846053443

- A) PRINCIPLES OF SURGERY
- B) LOCAL ANESTHESIA

## 19) DR KAVITHA S IYER

EMAIL: drkavithaiyer@gmail.com mob;9962597241

- A) EARLY ORTHODONTIC TREATMENT- CATCH THEM YOUNG!!WATCH THEM GROW
- B) ORTHODONTICS – AGE NO BAR.....

**20) DR KRISHNAKUMAR**

EMAIL: krishnakumar@gmail.com mob; 9495628114

- A) "A BETTER TOMORROW"- A WALKTHROUGH PRACTICE MANAGEMENT
- B) "LASERS" - NEW TREND IN PRACTICE BUILDING

**21) DR. LAJU.S**

EMAIL: drlajus@gmail.com mob; 9961196669

- A) DESIGN CONSIDERATIONS OF CAST PARTIAL DENTURE IN DIFFERENT CLINICAL SCENARIO

**22) DR LEEBA VARGHESE**

EMAIL: drleeba@gmail.com mob; 9388144446

- A) POST ENDODONTIC RESTORATIONS
- B) RUBBER DAM IN DAILY DENTAL PRACTICE

**23) DR MAHESH NARAYANAN**

EMAIL: drmaheshn@gmail.com mob; 9847157998

- A) "LASERS FOR SUCCESS" – INNOVATIONS FOR PATIENT COMFORT

**24) DR.MATHEW JOSE**

EMAIL: matjosein@yahoo.co.uk mob; 9447525297

- A) DENTAL MANAGEMENT OF MEDICALLY COMPROMISED PATIENTS
- B) WISDOM TOOTH MANAGEMENT

**25) DR NIRMAL GEORGE SAIBU**

EMAIL: nirmal\_saibu@yahoo.com mob; 8281133300

- A) "FROM TEARS TO CHEERS"; RETENTION IN COMPROMISED EDENTULOUS RIDGES
- B) IMPLANT PROSTHESIS

**26) DR PRASANTH DHANPAL**

EMAIL: prasanthdhanpal@gmail.com mob; 9846162420

- A) POST AND CORE RESTORATIONS IN PRACTICE.
- B) ENDODONTICS FOR GENERAL PRACTITIONERS

**27) DR. PRASANTH PILLAI –**

EMAIL: drppillai@gmail.com mob; 9447051422

- A) STRATEGIC IMPLANTOLOGY: A NOVEL AND SUPERFAST APPROACH IN DENTAL IMPLANTOLOGY
- B) ADVANCED SMILE CORRECTION PROCEDURES - STRATEGIES BEYOND THE REALMS OF COSMETIC DENTISTRY

**28) DR RAHUL R**

EMAIL: rrpillai85@outlook.com mob; 8111834448

- A) "WHAT EYE SEE, MIND DOESN'T KNOW"- DIAGNOSIS YOUR DAILY RADIOGRAPHS
- B) "PRECANCEROUS OR NOT" DIAGNOSIS AND MANAGEMENT

**29) DR ROSHY GEORGE**

EMAIL: drrosHYgeorge@gmail.com mob; 9446450961

- A) COMPLETE DENTURE REVISITED- CLINICAL STEPS AND COMMON MISTAKES
- B) WHY FEAR CAST PARTIAL DENTURES?

**30) DR SABU KURIAN**

EMAIL: drsjkurian@gmail.com mob; 9446574707  
SURGICAL PERIODONTICS IN GENERAL PRACTICE: THE ECONOMIC POINT OF VIEW

**31) DR SAJU N S**

EMAIL: drsajuns@gmail.com mob;9447201441

- A) "ORAL SURGERY IN EVERYDAY PRACTICE" (WITH HANDS ON TRAINING ON SUTURES & SUTURING TECHNIQUES)
- B) "THROUGH THE LENS"APPLICATION OF PHOTOGRAPHY IN DENTISTRY (WITH LIVE DEMONSTRATION / HANDS ON TRAINING)

**32) DR SANGEETH CHERIAN**

EMAIL: sangeethmds@gmail.com mob; 9495630302

- A) TRENDS, ADVANCES AND OPINION IN REMOVABLE PROSTHODONTICS
- B) EXPERTISING CROWN AND BRIDGE

**33) DR SEBASTIAN THOMAS**

EMAIL: sebastianhere@yahoo.com mob; 9847157998

- A) CERAMIC LAMINATE VENEERS
- B) HOW TO TRIM AND INSERT THE ACRYLIC RPD: VALUABLE TIPS AND HANDS- ON

**34) DR SEBY VARGHESE**

EMAIL: drsebys@gmail.com mob; 9020202000

- A) ETHICS, LAW AND COMMERCE OF DENTISTRY
- B) PHILOSOPHY, MANAGEMENT AND PROMOTION OF DENTISTRY

**35) DR P A SHAJAHAN**

EMAIL: drshajahanpa@gmail.com mob; 9072277275

- A) LASER IN CLINICAL PROSTHODONTICS AND COSMETIC DENTISTRY
- B) ALL CERAMIC RESTORATION: A PERFECT DENTAL MASK?

**36) DR SHYAM KISHORE**

EMAIL: drshyamkishore@yahoo.com mob; 9447415584

- A) JOB SATISFACTION IN DENTISTRY
- B) DENTAL DILEMMAS – AVOID CONTROVERSY IN DENTAL TREATMENT PROCEDURES

**37) DR SIMPLE VARGHESE**

EMAIL: simplevarghese@ymail.com mob; 9447097676  
LASERS-" A RAY OF HOPE, FOR THE HOPELESS"

**38) DR SREEDEVI S**

EMAIL: sreegj@gmail.com mob; 8089087801

- A) PORCELAIN LAMINATE VENEERS
- B) POST ENDODONTIC RESTORATIONS-SELECTION TO EXECUTION

**39) DR SUNIL KA**

EMAIL: drkasunil@rediffmail.com mob; 9847165859

- A) PRACTICE MANAGEMENT AND HANDLING OF PATIENTS

**40) DR VINOD N A**

EMAIL: drmavinod@gmail.com mob; 9656045990

- A) "ACCESS TO SUCCESS" ROOT CANAL TREATMENT MADE EASY
- B) "FAST AND FURRIERS" SINGLE SITTING WITH IMMEDIATE POST AND CORE TREATMENT

**41) DR VIVEK NARAYAN**

EMAIL: drviveknaryanan@gmail.com mob; 9895319384

- A) "ADD A PINK FEATHER TO YOUR PRACTICE" TAKING PERIODONTICS TO THE GENERAL PRACTITIONERS
- B) PREVENTIVE DENTISTRY- PROPAGANDA OR PROMISE?



# Association News

## ► Quilon Branch

The fifth CDH programme of IDA, Quilon branch conducted on 24th April at Hotel Ritz from 10 am to 1.30 pm a "staff training programme" exclusive for the staff( assistants) of doctors in IDA Quilon branch.

The programme was conducted in two modules.

Module 1: Infection management and Environmental plan by Deputy DMO, Dr Sandhya R. A detailed lecture was given by Deputy DMO on the said topic with special focus on the importance of sterilization and cross infection followed by an active interactive session.

Module 2: Staff training by dentcare dental lab, Muvattupuzha: Conducted a live demonstration on the mixing of various materials viz alginate, putty, dental stone etc. He stressed upon the importance of weighing materials in a weighing balance and manner of storing material. Printed information regarding the same were distributed to the staff.

The sixth CDH programme of IDA Quilon branch was held in relevance to WORLD HEALTH DAY(7th April'16) with the theme "BEAT DIABETES" at St Peters parish hall, Moothakara from 9.30 am to 2.30 pm in association with Quilon social service society. The programme was highlighted with "free random blood testing" for sixty seven patients, "talk on diabetic diet" by a dietician and "individual counselling" for diabetic patients along with dental and medical check up camp and distribution of free medicines and metabolic care products. Announcements on radio and alerts in all leading newspapers were made before the event to reach out to the public.

World no tobacco day programmes: WNTD 1ST PROGRAMME: PUBLIC AWARENESS: Infant Jesus School: 27th June'16. Class on WNTD for nearly 300 students and teachers with power point presentation.

- Slideshow/Documentary presentations

- Essay Competition on WNTD

- Poster competition with the theme of WNTD- 'Get ready for plain packaging.

1) WNTD 2nd PROGRAMME: Press meet was conducted on 29th May at Press club Kollam.

2) WNTD 3RD PROGRAMME: PUBLIC AWARENESS: Radio Benziger FM Station- 107.8 (31ST MAY TO 4TH JUNE) An awareness talk was aired in 107.8 FM station (Radio benziger) from 31st May to 4th June'16.

3) WNTD 4TH PROGRAMME: PUBLIC AWARENESS: RP Mall: 31st MAY'16. Inaugurated by Deputy Excise commissioner Mr Anil Kumar.

Documentary presentations

- Distribution of Anti-tobacco brochures

- Pledge to quit counter

- Short film contest declaration (theme of WNTD 2016)

- Awareness talks

- Interactive sessions with the public

4) WNTD 5TH PROGRAMME: PUBLIC AWARENESS: Bike Rally: 31ST MAY'16. IDA, QLN branch in association with Meditrina Hospitals Qln, took forward the campaign against tobacco with a road show (BIKE RALLY) which commenced at 5 pm, from Meditrina hospitals, Qln via beach ending at Adventure park at 7 pm after floating lamps at Ashtamudi lake. The event was flagged off by the Eravipuram MLA- elect M.Noushad.

5) WNTD 6TH PROGRAMME: ONLINE PAGE (FB): IDA QUILON BRANCH CELEBRATES WNTD 2016": Online Page from 1st May'16.

6) WNTD 7TH PROGRAMME: CANCER SCREENING: Dental Medical Cancer Detection Camp with Routine Medical Consultations & dispensing of Medicines (RCC, Travancore Medical College & Azeezia College of Dental Sciences) in association with QSSS, Reliance Foundation and Caritas India.

CDE: 3rd CDE program on Role of general practitioners in detection of oral cancer first part by Dr Rathy R HOD Oral medicine Azeezia Dental College on 30th April at Lions Hall Kollam from 7:30 pm to 9 pm.



## ► Malanadu Branch

**CDE programmes:** Malanadu branch has conducted two cde programmes during this period, our 2nd cde on 22.05.2016 on the topic Medical emergencies in dental office. The faculty of the programme were Dr.Sankar vinod, Dr.Suraj john and Dr. Ninan Thomas. Another one our third cde, a national workshop and hands on and cde 'STOMA' on 12.06.2016 on the topic surgical advancements. The faculty were Dr.varghese Mani, Dr. Sankar vinod and Dr.Arun george.

**CDH programmes:** State anti tobacco day programme was hosted by malanadu branch in association with rotary club central perumbavoor, mar baselious dental college and with indira Gandhi college kothamangalam. at government hospital perumbavoor and conducted A road show at kothamangalam on 31.05.2016. inaugurated by MLA Adv.Eldhos kunnappally. More than two hundred and fifty people participated in the programme. IDA immediate past president (HO) Dr.Alias thomas. State President Dr.Muhammed Sameer, state vice president Dr.Ciju a paulose and state CDH chairman Dr.subhash Madhavan

were present. Oral screening was done and cancer awareness class was also taken after the meeting.

**Family Meeting:** Family meeting was organized on 22.05.2016 at hotel kabani international, muvattupuzha. In the meeting senior dentists who have completed 25 years of clinical practice were honoured. All the MLA's of ida Malanadu territory were also honoured during the programme- Anoop Jacob, Eldho Abraham.

Womens Wing inauguration was held on 22.05.2016 by muvattupuzha municipal chairperson Smt.Usha Sasidharan.

First issue of Malanadu Dental journal 2016 was released on 22.05.2016 during the family meeting.

A Cricket match was organized between mar baselious dental college team and malnadu ida team and ida malanadu came as runner up in the match. This was held on 17.04.2016.



## ▶ Attingal Branch

### BEAT THE B

Beat the B is a mega project of CDH wing of IDA Attingal. The program is to ensure Hepatitis B vaccination for the staffs and other workers of Dental clinic.

First dose of vaccination was given to the staffs and other workers on 17th Sunday 2016 at Shifa Hospital, Kaniyapuram. We can able to give free vaccination to more than 70 staffs and workers.

Two awareness classes was also given to the staffs on the same day first one was about Hepatitis B by Dr Shifi another one was about sterilization by Dr Meera.

Second booster dose was given on 15th Sunday 2016 at Shifa Hospital Kaniyapuram.

**Second branch CDE (15th May 2016):** The second branch CDE program was held at Malabar Hall, Techno Park, Trivandrum on 15th May 2016 by the faculties Dr Sudeep S, Dr Dinesh N and Dr Sherin A Khalam. The topic was The Myth and Reality of Dental Implantology. The program was a 6 hr program includes lecture and Hands on implant placement in Goat jaw. KDC awarded 6 credit points for the program. 60 participants attended the program.

**WDC: ONE DAY PICNIC (May 1):** WDC arranged one day picnic exclusively for ladies and kids to Thenmala eco-tourism, kollam district.

**MOTHER'S DAY (May 8):** WDC Attingal observed mother's day on may 8. On the occasion WDC arranged an awareness camp and oral screening done for the inmates of Al Himaya orphanage. Dr Rakhee, Dr Deepa, Dr Meera and Dr Mintu conducted the program.

**ADOPTION OF ORPHANAGE:** An awareness camp and screening camp was organized in the adopted orphanage of WDC. Members of WDC also provided study materials for the inmates of Al Himaya orphanage.

### CDH

**NO TOBACCO DAY (May 31):** CDH wing of IDA Attingal observed No Tobacco day on 31st may. Branch contacted two programs on that day.

One was an awareness class and a oral Cancer detection camp organized at PATMOS INSTITUTE, KILLI, TVM in association with IMA and Solce Mission. Dr Ramesh, Dr Afzal and Dr Alex organized the camp. More than 70 persons attended the camp.

Other was an oral cancer detection camp organized for the public at Primary Health Sub centre, Nadakal, Kollam. Dr Hari, Dr Sanu and Dr Binu conducted camp. More than 60 peoples attended the camp. The camp was a joint venture of IDA Attingal and JCI Chathannor.



## ▶ North Malabar Branch



**CDE activities:** A webinar was conducted on the topic Minor Oral Surgical Procedures at IDA hall podikundu on 6th April 2016. CDE programme on TIPS IN PEDIATRIC DENTISTRY FOR GENERAL PRACTITIONERS was conducted on 22nd april by Dr Anupam Kumar, Prof.GDC Calicut.43 members attended.

**CDH activities:** Anti tobacco day was celebrated on 31st May at Chamber of commerce hall, Kannur. Dr P P Venugopal, Dean, Kannur Medical College was the chief guest. IDA NMB members and around 250 Kudumbashree workers participated in the function.

Dr Prabath Ramakrishnan and Dr Anil Kumar P K took awareness class for public about the side effects of tobacco usage.

**Executive committee meeting:** 2nd executive committee meeting was held on 11/4/16 at IDA hall, Podikundu. An emergency executive committee meeting was held on 21/4/16 at IDA hall

## ▶ Vatakara Branch

An emergency executive meeting was held on 20-04-2016 at Excellent Dental Clinic, Nadapuram to discuss to conduct the north zone cricket match at Vatakara. Meeting was attended by Dr. Pramod, Dr. Gireesh Kumar, Dr. Abdul salam, Dr. Sushanth, Dr. Anil Kumar besides President and Secretary and decided to form an organizing committee to conduct the matches at Govt. college, Madappally. Organizing committee meeting was held on the same day just after executive meeting. Dr. Nidhin, Dr. Ashin, Dr. Sajeer, Dr. Bineesh, Dr. Dipin Tom attended along with executive members. All were made members of different sub committees, for the smooth functioning.

Proposed cricket match was postponed later as per the directive from IDA KSB due to fear of sunstroke.

The IV executive meeting was held at DENTART Vatakara on 2-5-2016 and evaluated compliment and complaints about the so far conducted programmes, attended by 11 members.

Decided to conduct a CDE programme in pedodontics and decided to admit non- IDA members with double charges.

Decided to celebrate Environment day Celebration on June 5th 2016.

**ENVIRONMENT DAY CELEBRATION** was conducted by Women's Dental Council of Vatakara branch by planting 18 tree saplings along the boundaries of play ground of one of the oldest high school in Vatakara thaluk, Kadathanad Rajas high school, Purameri.

Programme was inaugurated by Sri. K. Achuthan, President Grama Panchayath, Purameri and graced by Sri. K.C. Udaya varma Raja, Manager KRHS School. Dr. Padma Praseeda planted the first sapling and attended by Dr. Chitra Lekha, Dr. Bindu, Dr. Sreekala, Dr. Nasheedha, Dr. Shafeena, Dr. Veena, Dr. Sruthi, Dr. Pramod, Dr. Abdulsalam, Dr. Gireesh Kumar, Dr. Sushanth and Dr. Salil.

The fifth Executive meeting held on 21-06-2016 at Nadapuram, decided to conduct Iftar Meet on 27-06-2016 at Govt. guest house Nadapuram

### CDE Programmes:

1. On 10-4-2106 Lecture and hands on in rotary endonants by Dr. Nanda Kishore was done in association with Confident Dentals. 40 members attended lecture, and hands-on done by 15 doctors

2. A CDE in Pedontics by Dr. Anand Raj was done on 5-6-2016 at Hotel Sreekrishna, and was well attended by 35 participants.



## ▶ Trichur Branch

### MAY

Anti-tobacco day was observed with an anti-tobacco campaign and CDE programme at Dass Continental on 31st May 2016 with 3 credit points approved by KDC. Prof. Anthony George, MDS (Oral Pathology) took a class on "Ill effects of Tobacco-chewing and tobacco-smoking". He gave a very informative lecture on the incidence of cancers due to tobacco use. 85 members attended the program.

### JUNE

An Executive Meeting and General Body meeting were conducted as usual on June 11th and 25th 2016 respectively.



### JULY

A CDE programme was conducted on 10th July 2016. Topic was "Oral Surgical Procedures and with KDC approved 6 credit points. Prof. Dr. Manoj Bhaskar, Unit Chief, OMFS, Elite Hospital Thrissur, Dr. Joseph Lijo, Consultant OMFS, Elite Hospital Thrissur and Dr. Arjun Shenoy, MDS, doing fellowship in Maxillofacial Taruma took classes on Oral Surgical Procedures. Dr. Varghese Mani, Dr. Philip Mathew and Dr. Antony Manavalan were the chief moderators of the programme. Dr. Binoy Kurian MBBS, MD (Microbiology, Jubilee Mission Hospital) took classes about "Sterilization techniques for Dental Clinics". 91 members attended the programme.

## ▶ Mavelikkara Branch

The second executive committee meeting was held on March 22nd at hotel travancore regency. meeting decided to observe oral health day with poor needy people of the society.

Oral health day was observed on March 31 at govt hospital, mavelikkara.

Dr. Shehena Superintendent of govt hospital was the chief guest.

We have distributed wheel chairs, walking sticks, water beds, colostomy bags to the poor and needy patients of 7 panchayats of mavelikkara. total 40 patients got benefited from the programme. Dr. Ratandas, our CDE chairman, was the successful organizer for this programme.

On May 22, the Women's Dental Council organized a program in which Mr. Jayachandran (Director, Folk Life Academy, Playback Singer, etc.) did a program for kids. It was a program mainly for the kids. During this program, a sale and exhibition of home-made food products and handicrafts (prepared by our own members) was arranged. Dr. Susan Mathew and Dr. Parvathy Manoj, our president and Sec of Women's Wing, conducted the program successfully.

On 29 May, a class and hands-on training on next-gen endodontics was conducted by Dr. Aparajithan about root canal treatment in association with Kerr Company. Dr. L. L. S. (CDE Chairman) effort behind the programme was appreciable.



## ▶ Kodungallur Branch

- 1) 3rd general body held on 27/4/2016 at Rotary hall, Kodungallur.
- 2) 3rd Scientific session conducted by Dr. Kavitha Vijesh on 27/4/16 on Pedodontics
- 3) 2nd executive committee meeting held on 11/5/16 at hotel Cherakulam
- 4) Family get-together held on 28/05/2016
- 5) Inter branch CDE held on 12/06/16 by Dr. Joy Kurian on Happy smiles for children at Rotary hall, Kodungallur.
- 6) Doctors day celebrated on 6/07/2016 at hotel Relax Muziriz, Kodungallur.



## Tellicherry Branch

3rd executive committee meeting was held at parco residency on 6th of may 2016.13 members attended the meeting. Decided to conduct 2 cdes in the coming months and to conduct the general body meeting and family get together.

3rd cde programme was held at parco residency on 15th of may 2016. The topic of the cde programme was composite veneers. Faculty of the programme was Dr Jayasree Hegde. It was attended by 27 doctors. 6 credit points was allotted to this cde by KDC.



1st general body meeting and family get together was conducted on 19th of June at parco residency thalassery. We celebrated nombuthura along with family get-together on this occasion. Around 25 members with family attended the event. The meeting started at 6pm. After nombuthura there was a class by Dr Ummer Farooq ( member, child welfare committee, Kannur district ) on family relations.The class was followed by dinner.



## Wayanad Branch

1. Executive Meeting: IInd Executive Meeting on 24 - 2- 2016, at M.K. Tourist Home Panamaram.

III rd Executive Meeting on 22 - 4 -2016, at Hotel 'Manasa Saras' Manandhavadi.

IV th Executive Meeting on 4 - 6 -2016, at Hotel The Resort Sulthan Bathery. All the meeting were well attended by all the executive committee members

2. CDE Programme: I st CDE Programme 22 - 5 - 2016.

Topic: Layers of Beautification By Dr. Ratan Salecha. at Hotel Mount Avenue Ambalavayal.

IIInd CDE Programme on 19 - 6 - 2016: Topic: Advanced Rotary Endodontics By Prof. Dr. Narasimhan Bharadhvaj, at the Wynd Vally Resort, Kalpetta.

IIIrd CDE Programme on 10



- 7 - 2016.: Topic: Endodontic made Easy and Root Canal Retreatment By Dr. Ashish Medha. at Wynd Valley Resort Kalpetta.

CDH Programme: Conducted Anti Tobacco Awareness Programme at Subjail, Vythiri on 12 - 7 -2016.

Branch Tour: Conducted Family tour to Dhottapette, Ooty on 2 - 7 - 2016. 10 family participated.



## Coastal Malabar Branch

1. 15th CDH ACTIVITY- 07/04/2016; Distribution of Oral Health Kits To Students; Venue- BUDS SPECIAL SCHOOL, KOOKANAM Time - 9.30 am onwards; Powered toothbrushes, kids tooth paste, mouthwash and towels distributed to 35 students.

2. 16th CDH ACTIVITY-10/04/2016; Dental awareness class and dental checkup camp done for specially challenged children and their parents. 70 students and parents took part in the CDH activity. Vishu kit was offered to Cancer patients on the same day.

3 4th CDE PROGRAMME- 17/04/2016; Venue- Hotel JK Residency, Cheruvathur; Date - 17/04/2016 Topic- "INTEGRATED DENTISTRY" (Perio- Prosthodontic- Endo-Ortho- Interrelationship) Faculty - Dr.A.V. Sreekumar(Prosthodontist) Dr. Anil.M (Periodontist) Dr.Ranjith. Raveendran (Orthodontist), Dr. Sanjith.Simon (Endodontist), Moderator- Dr. Santhosh. Sreedhar Time - 3.30 pm to 7.30pm

4. Dr.Rahul.Nandakumar, Dr.Santhosh.Sreedhar, Dr.Ahmed Shafi, Dr.P.K. Jayakrishnan, Dr.Sreekumar.C, Dr.A.V. Sreekumar and Dr.Rajesh.E attended the State Executive Committee meeting held on 24/04/2016,Sunday at Hotel Nila Palace, Shornur.

5. Organised a family tour for two days (30/04/2016, 01/05/2016) at Club Mahindra Resort, Virajpet.

6. 17 th CDH ACTIVITY - 08/05/2016

Observation of Mothers' Day was done by WDC by conducting a Charity work at Sai Old Age Home,Thrikaripur. A dining table was donated to Old age home. Dental awareness class and dental checkup was done for 10 units of Kudumbasree at Koyankara L.P School, Thrikaripur.

7. 5th CDE PROGRAMME- 15/05/2016; Topic- STRATEGIC IMPLANTOLOGY; Venue- Hotel JUJU International, Payyannur; Faculty- Dr.Prasanth.Pillai. MDS; Time - 9.30am to 1.30pm

8. 3rd Executive Committee Meeting was held on 15.05.2016, Sunday at Hotel JUJU International, Payyannur from 2.00 pm onwards.

9. 18th CDH ACTIVITY- ANTI-TOBACCO DAY CELEBRATION- 31/05/2016; Done at Cheemeni Open Prison, Cheemeni on 31.05.2016 from 12.00pm to 4.00pm.; Awareness class and No tobacco oath was taken.

10. 6th CDE PROGRAMME - 12/06/2016; TOPIC- VENEERING; VENUE- Nalanda Resorts, Nileshwar; FACULTY- DR. Meera Gopalakrishnan; Time- 3.30pm to 6.30pm

11. Iftaar Sangamam was celebrated on 12/06/2016, Sunday at Nalanda Resorts,Nileshwar from 7.00pm to 8.00pm

12 19th CDH ACTIVITY- 26.06.2016- OBSERVATION OF ANTI-DRUG ABUSE DAY: Distribution of clothes & Dental Kits, awareness class & dental checkup was done at Childrens' Orphanage, Punchakad by WDC.



## ▶ Alappuzha Branch

### CONTINUING DENTAL EDUCATION PROGRAM

The second CDE of the branch was organized on 22.05.2016 at Hotel Arcadia, Alappuzha on the topic of "Lasers in general dentistry by Dr Mahesh Narayan from 6-8pm and the orator was Dr Mathew P C BDS MDS FCCS Oral & Maxillofacial Surgeon and the attendance was 30 members.

### Executive meeting

The third executive meeting of IDA Alappuzha branch was conducted on 06.06.2016 at Ramavarma club and the presentation of the accounts of previous CDE and CDH activities were done. The planning of third CDE was done as a one day hands on program by Dr Rupesh on pulpectomy in primary teeth and stainless steel crown. The arrangements for the CDH activity, a treatment camp

organized by IDA Alappuzha in association with the Press club of Alappuzha and the Govt Dental college Kottayam was discussed.

### CDH ACTIVITY

The second CDH activity of IDA Alappuzha was a treatment camp at YMCA Alappuzha in association with Press club Alappuzha and Govt. Dental College Kottayam on 21/ 06/ 2016 for the press club members and inmates of St. Antony Orphanage Alappuzha. Among 80 patients reported 60 of them got treatments including restorations, extractions, oral prophylaxis and topical fluoride applications. It was good collective effort by IDA Alappuzha with the presence of President Dr Joe Bojoy, Hon Sec. Dr Tijo Alex, Dr Chandy Joseph, Dr Prasanth Jacob, Dr Binu, Dr Elizabeth, Dr Geethu & Dr Vishnu.



## ▶ Eranad Branch

CDH reports-Dental screening camp was conducted at korenkode anganawadi akambadam Nilamboor on 31st March 2016. Two dental surgeons took part in camp and around 25 students were screened in this camp.

Conducted dental camp at snehalaya orphanage Nilamboor on 10/04/2016. Eight dental surgeons took part in the camp and around 50 inmates were screened in the camp. Conducted anti tobacco day may 31st 2016 by placing educational flex boards in different parts of Malapuram. We conducted the candle lite procession in Nilamboor at 6:30pm. We built a house for poor from our project 'varsham oru vedu'. Ida state president Dr Sameer, state secretary dr Suresh, National past

president dr Aalias Thomas, cdh chairman dr Subhash madhavan presented the key to Mrs soudha from edavanna. It was our prestigious project. All members actively participated in it. CDE REPORTS-'problem solving in restorative dentistry-a new innovative approach' was conducted on April 17th at hotel Hiton PERINTHALMANNA. 31 members attended. Forth Cde -' Drugs in dental practice and Sterilization and disinfection' was conducted on May 15 th at Hotel soorya regency Malapuram by Dr Bobby John. 27 members attended. We conducted our 2nd executive committee meeting on 9th April 2016 at hotel woodbine manjery at 8pm. Conducted IFTHAR party on Jun 25 at manjery. It was really a feast for belly



## ▶ Valluvanad Branch

**THIRD EXECUTIVE MEETING IDA KERALA STATE:** IDA kerala state 3rd Executive meeting was hosted by IDA VALLUVANAD BRANCH on 22nd April, 2016 at Hotel Nila residency shornur. The meeting started at 10 30 am and ended by 4 30 pm. President, secretaries, and executive members from various branches participated. About 100 members attended the meeting and we could make them very happy by conducting the meeting in an excellent manner.

**2nd cde program:** IDA VALLUVANAD 2nd CDE program was conducted in branch level on 22nd may 2016, at fun city conference hall, mega mall, ottapalam. The topic was interceptive orthodontics taken by faculty Dr. mohammed haris T.P, MDS. Senior lecturer, P.S.M Dental college, thrissur. About 12 members participated

**3rd cde program:** IDA VALLUVANAD 3rd cde program was conducted on 22nd may, 2016 at fun city conference hall, mega mall, ottapalam. The topic was periodontics for general practitioners taken by faculty Dr. hrishi T.S, MDS., PK DAS hospital, vaniyankulam. About 12 members participated

**ANTI TOBACCO DAY- MAY 31ST:** IDA VALLUVANAD has observed anti tobacco day on may 31st by exhibiting anti tobacco campaign posters on prime locations of near by towns.

**BRANCH MEETING:** IDA VALLUVANAD branch meeting was held on april 21st and may 22nd.



## ► Malabar Branch

1. CDH ACTIVITY No.5: Dental Screening and awareness camp was conducted at Karikamkullam Karaparambu Kozhikode on 03/04/2016 in association with Karikamkullam East Residents association. Dr.Harish Kumar inaugurated the camp with an awareness class.Around 150 Participants were present in the camp.
2. SECOND EXECUTIVE MEETING: The Second executive meeting of IDA Malabar Branch was held on 07/04/16 at IDA hall Ashokapuram Kozhikode. Meeting began at 7.30pm when Hon Secretary Dr.Sudheer KT Collared the President Dr.Dinesh KR followed by a silent Prayer.
3. CDH ACTIVITY No 6: Dental Screening and awareness camp was conducted at Chengotukavu Koiylandy Kozhikode on 10/04/2016 in association with Town Residents association Chengotukav at Sri Ramananda Auditorium Chengotukav. Around 100 Participants were present in the camp.
4. CDH ACTIVITY No.7: Dental Screening and awareness camp was conducted at Kolapuram Kozhikode on 017/04/2016 in association with Nava Kerala Samskaravedi Kolapuram. Around 300 Participants were present in the camp.
5. Cricket and Football Tournament.: In the Loving Memory of our past Presidents who left us early, Dr.Moidheen Sha Chamba and Dr.KP Sharafudheen, Football and Cricket tournaments were conducted in their respective names at Calicut Medical College Ground on 17/04/2016 in association with Calicut Dental College Alumini association. Four teams participated in the tournament. After the completion of all matches, valedictory function began at 6.30 pm. Dr.Manoj Michael Senior member of Malabar branch distributed the prizes for winners.
6. CDE No.3 LECTURE WITH LIVE DEMO: The third CDE of IDA Malabar branch was held on 01/05/2016 at Hotel Maharani Kozhikode. The programme started at 9.00 am and was inaugurated by Dr.Dinesh KR President IDA Malabar branch. The topic of CDE was Mastering Laminate Veneers. The Faculty was Dr.Arvind Shenoy MDS Proffesor, Dept of Endodontics Bapuji Dental College and Hospital Davangare.
7. RELEASE OF JOURNAL: The Journal of IDA Malabar was released on 01/05/2016 by Dr.Aravind Shenoy and Dr.Auwsaf Ahsan (Editor IDA Malabar branch)during the 3rd CDE proamme.
8. FOLLOW UP VISITS TO HOME OF LOVE (THE ADOPTED OLD AGE HOME): Multiple visits were made to adopted old age home and four complete denture were delivered to the inmates. Arround 70 extractions were done so far and four completed dentures are in process which reached upto jaw relations..
9. INAGURATION OF FILM CLUB AND FAMILY MEET: Inaguration of film club and family get together were conducted on IDA hall on 22/05/2016 followed by film show. The programme started at 10.00am by lightening the lamp by our senior members Dr.Jayaram (Former Principal Govt Dental College), Dr.Ramakrishnan (Former Principal Pariyaram Dental College), Dr.Balraj Senior practitioner, Dr.Bijoy from IDA Wayanad. Five Critically acclaimed Movies on the theme,"A Window to Relationships ", were screened and lunch and dinner were served to participants.
10. CDE No.4 (LECTURE WITH LIVE DEMO): The fourth CDE of IDA Malabar branch was held on 029/05/2016 at Hotel Maharani Kozhikode. The programme started at 9.00 am. The topic of CDE was "Creating a Good Impression". The Faculty was Dr.T.V.Padmanabhan MDS HOD Dept. of Prosthodontics Sri Ramachandra University.
11. ANTI TOBACCO DAY OBSERVANCE (31/05.2016): IDA Malabar branch arranged a float in a tempo traveller highlighting the adverse effects of tobacco and simultaneously announcing the adverse effects of tobacco giving awareness to the public, which ran throughout the Kozhikode City from 8.00 AM to 8.00 PM. On 31/05/16.

We arranged a Candle lit Procession as a part of Anti Tobacco Campaign in the Kozhikode beach on the same day. Flagging of the rally was done by Shri. Purushan Kadalundy MLA. Rally started from the Southern end of the Kozhikode Beach at 6.PM. Nearly 60 members and their family participated in the rally carrying placards and candles. Rally ended near the Lions Park Kozhikode., with a candle light vigil on the open stage. IDA also arranged a small documentary against the use of Tobacco which was exhibited in LCD projector in Kozhikode Beach.



## ► Kasargod Branch

1. Executive committee meeting was held on 26th January, Tuesday, at IMA hall Kasargod. Issues and programmes to be conducted in the current year were discussed.
2. Dentists day was celebrated on 6th march
3. Second CDE programme was conducted on Management of medically compromised patients in a dental clinic by Dr Avinash Kakunje on march 11th Friday, at Hotel J K residency, Kasargod, at 7 30pm. 35 members attended the meeting. Issues discussed from the state branch was presented to the members.
4. On May 8th Sunday, CDH programme, Dental Screening camp was conducted in "Ashraya" an old age home in Kasargod. Screening of 75 patients were done.
5. May 29th we had a family meeting and also felicitation ceremony to Dr. K Ganapathi Bhat for completing 50 year of dental practice in Kasargod.





**Dr. Mercy Joji**  
Chairperson

## WDC Report



**Dr. Sapna Sreekumar**  
Secretary



Women's dental council, wdc kerala state and ida quilon branch conducted mega dental and medical cancer detection camp along with routine medical consultations as the womens dental council state programme as well as the 7th cdh programme of the branch on 3rd june 2016 in relevance to world no tobacco day at San Pio retreat house, Chavara, Kollam from 9.30 am to 2.30 pm. The camp was in collaboration with regional cancer centre (rcc)trivandrum, travancore medical college (medicity), quilon, azeezia college of dental sciences, quilon, quilon social service society (qsss), caritas india and reliance foundation with onsite pharmacy and lab, attended by four hundred and seventy three patients.

The mega camp was inaugurated by the honourable Mayor of Quilon Adv.V.Rajendra Babu followed by President of the branch Dr Sundareshan, Chairperson WDC Kerala State Dr Mercy Joji, Executive director QSSS Fr. Pious Malliar, South Zone coordinator and CDH chair Dr Anney George, Project officer Caritas India Mr Amal Krishna, District coordinator Reliance Foundation Mr Praveen. Chief Co-ordinator of the programme was Dr. Annie George, WDC Kerala State South Zone Co-ordinator.

### MEGA DENTAL AND MEDICAL CANCER DETECTION CAMP, WDC KERALA STATE & IDA QUILON BRANCH



MEGA DENTAL AND MEDICAL CANCER DETECTION CAMP, WDC KERALA STATE

WDC THIRUPUNITHURA BRANCH NO TOBACCO DAY OBSERVATION

## IDA Hope Report

**Dr. Joseph C.C.**  
Hon. Secretary



### Greetings from The IDA Hope Office.

Hope you all fine. Our Health insurance policy will expire on 30th September 2016.

In order to renew our policy we have to pay the premium for the next year before 20th SEPTEMBER 2016. We had paid around 93 lakhs as premium including service tax 15% last year (2015-2016) for 1012 hope members and their family. Around 4300 persons insured in the scheme. As on date we have claimed 1 crore 62 lakhs and we still have two more months to go. And based on this claim ratio we had a negotiation for the premium to be paid for the year 2016 – 2017.

It may also be noted that nearly 70% of the claims have been MADE FOR PARENTS OF THE MEMBERS who otherwise may not have got any insurance cover due to age and pre-existing disease. Also we have negotiated for entry of parents for SLAB 3 only. (5 lacs) It may also be noted our scheme has benefited many of our members for their treatment of life threatening disease, some of whom were in dire financial difficulty.

This is the most economical insurance scheme considering the risk profile.

THE IDA HOPE HEALTH INSURANCE is being renewed on the **1st of October 2016**

The hospital admission expense and treatment charges have gone up many folds and our moderate scheme is in aimed at giving sufficient relief to Members and their immediate family members in the event of a major illness especially our parents.

The scheme is extended only for IDA HOPE Members, Spouse, Children and Parents. (Parents covers under slab 3 only).

Negotiations are going on and as soon as the insurance company gave the renewal premium, it will be displayed in our web site. Then you can pay the amount to our account.

For payment of premium we have made arrangements with The South Indian Bank Ltd.

For IDA HOPE HEALTH INSURANCE – VIRTUAL account in The South Indian Bank LTD, Thamarassery

The Details are as under.

For IDA Hope Health Insurance payments  
Bank Name :The South Indian Bank, Thamarassery

A/C Name : IDA – HOPE

Virtual Account Number: A122A11XXXX, Replace “XXXX” by your hope no

IFSC Code : SIBL0000428

For remittance from South Indian Bank Branches, Please use the following details only

Account Name: IDA HOPE

Account Number: 0428053000020940

Please remember to quote your hope number and Mobile number in remittance slip in both cases

For any Clarifications Please contact SIB Tamarassery . Phone No.0495 2222550

Email: br0428@sib.co.in

The Premium can be paid to above bank account only either by cash or cheque or transferred directly from your bank account by NEFT (National Electronic Fund Transfer).through net banking.

We request each one of you to subscribe to IDA HOPE HEALTH INSURANCE. COME LETS US ALL JOIN for our MUTUAL BENEFIT.

Completed application form and payment details are to reach the Hope office on or before the 15th Sep.2016 5.30 pm. Payment shall be made only directly to the South Indian Bank virtual account –details furnished below.

Dr. Joseph. C.C, IDA Hope Secretary

For more information and premium calculation you can contact our insurance consultant Mr. Alex. P.V..9447608146,999518805 (Retd. Senior Manager, United India insurance Co Ltd)

Director of Cosmos insurance brokers Pvt. Ltd. 39/2338, 2nd floor, Durbar hall Road Ernakulum 682016

Tel : 0484 2351432 ,09447608146, Tele fax: 0484 2351433 E mail: cosmosbrokers@rediffmail.com

## CDE Report



**Dr Nirmal George Saibu**  
Convenor CDE

Dear friends,  
Warm greeting to all.

As you all know, almost all branches have conducted the CDE programmes in a well organised manner. At the foremost, I would like to thank all branch committee members for their overall systematic approach towards the success of the programs.

This year, we are having four main targets. Two are already on track. The first programme was faculty hunt. In that event, 41 IDA members attended. The programme was carried out in IMA hall Kochi on 24-5-2016 at 9.30 am. Prof Dr Chitra Sanker, Dr Abdul Lateef, Dr Civy V Pulayath ebbed off their views which rippled among the audience. IDA State President Dr Mohammed Sameer, Secretary Dr Suresh Kumar, Incoming president Dr Sabu Kurian, Vice President Dr Fazil V Hassan, CDH chairman Dr Subash Madhavan's presence provided a perfection to the event.

Our second aim is CDE programmes. The first state level CDE programme was conducted in Malabar Palace Calicut on 26th June 2016 hosted by IDA Malabar branch. The topic was "management of ailing and failing implants" by Dr Tosun Tosun (Istanbul, Turkey), Dr Jaibin George and Mr Tarek. IDA State President Dr Mohammed Sameer, Secretary Dr Suresh Kumar, IDA Malabar branch President Dr Dinesh, Secretary Dr Sudheer K T, CDE Chairman Dr Madhavan Kuttty, Past presidents and CC members was also there. We got financial support from Adin implants, Dent care dental lab and Colgate.

The upcoming programme is "web seminar" coming soon by August.

Looking forward your sincere support for all our future endeavours. A glimpse of thanks to all dearest friends in IDA

## CDH Report



**Dr. Subhash Madhavan**  
Chairman CDH

### **INDIAN DENTAL ASSOCIATION KERALA STATE OBSERVANCE OF 'ANTI TOBACCO DAY' – HOSTED BY IDA MALANADU BRANCH- A REPORT.**

IDA Malanadu hosted the IDA KERALA STATE programme on the occasion of World No Tobacco day on May 31st 2016. The day started with Road show of about 200 students and ida members rallying through the streets

of Kothamngalam town holding placards displaying anti tobacco messages, conducted street plays and a few dressed up in Cigarette and Betel leaf costumes at around 8.30 am. The demonstration attracted the attention of the mass and was well appreciated by the local people and media.

Following that, An official meeting was organized at PERUMBAVOOR GOVERNMENT TALUK HOSPITAL considering the fact of anti tobacco message it will send across to the public. The meeting started at sharp 10.15am which was

presided over by the state IDA President Dr. Mohammed Sameer. The IDA state Anti Tobacco day meeting was inaugurated by the Perumbavoor MLA Adv. Eldhos Kunnappilly by lighting the lamp. He pin pointed the ill effects of tobacco in its various forms in his speech. That was really an eye opener to the public.

Dr. Alias Thomas immediate past president ida head office spelled out the anti tobacco oath to the the people present in the meeting. The meeting was attended by the IDA state first vice president Dr. Ciju A Paulose and state cdh chairman Dr. Subash Madhavan. The meeting was felicitated by Dr. Suma, medical superintendent government hospital. The dignitaries were welcomed by IDA Malanadu president Dr. Arun George and vote of thanks was given by Dr. Litto Manuel Hon. secretary IDA Malanadu.

After the meeting An awareness class on the topic 'Anti tobacco ill effects' was taken for the public by Dr. Skaria with audio visual aids. About 80 to 90 people attended.

Street play and anti tobacco costumes worn by IDA mebers attracted many ordinary people. Free oral screening camp also was organized in which we screened around 100 people. Pamphlets highlighting ill effects of tobacco and urging people to reduce or stop tobacco usage were distributed to all who came for the meeting and for the camp. Dental kit distribution also was arranged.

