



# KDJ

K e r a l a   D e n t a l   J o u r n a l

Vol 39 | No. 1  
January 2016

Quarterly Publication of Indian Dental Association, Kerala State Branch

- Biologic Width – Line of controller of Gingiva
- Interdisciplinary Periodontics
- Saliva: A diagnostic tool for oral cancer
- Impression techniques for ocular prosthesis
- Immediate denture – an important treatment modality
- Biological restorations in children
- Recording sublingual crescent region for improving stability and retention in mandibular dentures
- Rehabilitation of an edentulous geriatric patient with resorbed residual ridges and excessive interarch space using a maxillary hollow complete denture
- Comparison of different methods of assessing alveolar ridge dimensions prior to dental implant placement
- Predictive marker of residual ridge resorption-biochemical and radiographic evaluation
- Current concepts in eradicating enterococcus faecalis biofilm
- Digital impressions – a peak into the future
- A case report on the management of an infrabony defect with tetracycline fibres
- Sweetening the burden of diabetes
- Evaluation of the effectiveness of photodynamic therapy using toluidine blue for microbial reduction in periodontal pockets
- Management of Excessive Gingival Display
- A cross sectional survey on the utilization of scientific journals among staffs and students of Dental Colleges in Kerala

SIS Index ID 833





**EDITOR**

**Dr. K. Nandakumar**

**ASST. EDITOR**

**Dr. R. M. Baiju**

**BUSINESS MANAGER**

**Dr. Mathew Jose**

**EDITORIAL CONSULTANTS**

- Dr. Santhosh Sreedhar**
- Dr. K. Chandrasekharan Nair**
- Dr. Ipe Varghese**
- Dr. Oommen Aju Jacob**
- Dr. V.I. Paul**
- Dr. Thomas Manjooran**
- Dr. Sobha Kuriakose**
- Dr. T. Sreelal**
- Dr. Siby Xavier**
- Dr. M.K. Mangalam**

**EX-OFFICIO MEMBERS**

- Dr Mohammed Sameer PT.**
- Dr. Suresh Kumar G.**
- Dr. Thomas KC**
- Dr. Sabu Kurian**

**EDITORIAL BOARD**

- Dr. Dibyendu Mazumder**
- Dr. Ashok Dhoble**
- Dr. Jayakar Shetty**
- Dr. Radhakrishnan Nair**
- Dr. K. T. Sreelatha**
- Dr. Sunil Sunny**
- Dr. Jayaprasad K.**
- Dr. Ajay Kumar Haridas**
- Dr. Prasanthila Janam**
- Dr. George Varghese**
- Dr. Retnakumari**
- Dr. Jolly Mary Varughese**
- Dr. Romel Joseph**
- Dr. Thomas Joseph**
- Dr. Pradeep Kumar C.**
- Dr. Vinod R.B.**
- Dr. S. George P. John**
- Dr. P.G. Francis**
- Dr. M. Sadique Hussain**
- Dr. Saji P.**
- Dr. N.O. Varghese**
- Dr. Gopinathan M.**
- Dr. Aby Mathew T.**
- Dr. E. Anuradha Sunil Jagan**
- Dr. Manoj Nair**
- Dr. P.C. Sunil**
- Dr. Shamsuddin**

**EDITORIAL OFFICE**

Neelambikam, Attukal, Manacaud  
 Trivandrum, Kerala - 695 009  
 Phone: 0471-2459235  
 Mobile: 09447066100  
 e-mail: editorkdj@gmail.com  
 web: www.idakerala.com

**OFFICE BEARERS OF  
 IDA KERALA STATE**

**PRESIDENT**

Dr Mohammed Sameer P.T.

**IMM. PAST PRESIDENT**

Dr. Thomas KC

**PRESIDENT ELECT**

Dr Sabu Kurian

**VICE PRESIDENTS**

Dr. Ciju A. Poulouse  
 Dr Eugene Varghese Joseph  
 Dr Fazil V Hassan

**HON. SECRETARY**

Dr Suresh Kumar G

**JOINT SECRETARY**

Dr Binoy Stanly

**ASST. SECRETARY**

Dr. Krishna Kumar K S

**TREASURER**

Dr. Santhoshkumar P.U.

**EDITOR**

Dr. K. Nandakumar

**CDE CONVENOR**

Dr. Nirmal George Saibu

**CDH CHAIRMAN**

Dr. Subash K Madhavan



# Oral Cancer Incidence and Prevalence

## The Indian Scenario

Oral cancer is the most common cancer in India; as 4 in 10 of all cancers are oral cancers. Annually 130,000 people succumb to oral cancer in India which translates into approximately 14 deaths per hour. The reason for high prevalence of oral cancer in India is primarily because tobacco is consumed in the form of gutka, quid, snuff or misri. Rising tobacco use in India, where 40 per cent of the world's smokers live has contributed to this trend. In comparison, in US oral cancer represents approximately 13% of all cancers thereby translating into 30,000 new cases every year.

## Facts about oral cancer in India

- Recently, a trend has been observed towards increased incidence of oral cancer among young adults. This increase in incidence is only observed in patients with tongue cancer.
- In fact, in India, 60-80% of patients are present with advanced disease as compared to 40% in developed countries. Early detection would not only improve the cure rate, but it would also lower the cost and morbidity associated with treatment.
- Increasing prevalence of oral submucous fibrosis, especially in younger individuals, caused by gutka, an industrially manufactured food item has been seen.

The above facts state that, cancer cases in general, are increasing in India and it is high time that planners, social activists and government give adequate stress for prevention, early diagnosis, treatment and rehabilitation of these populations.



President's Message	10
Secretary's Report	11
Editorial	12
<b>Biologic Width – Line of controller of Gingiva</b>	13
– Agee Antony	
<b>Interdisciplinary Periodontics</b>	17
– Harikrishnan Balachandran Pillai	
<b>Saliva: A diagnostic tool for oral cancer</b>	20
– Jinisham	
<b>Impression techniques for ocular prosthesis</b>	24
– Rohit Raghavan	
<b>Immediate denture – an important treatment modality</b>	27
– Kalpana Hasti	
<b>Biological restorations in children</b>	30
– Seena John	
<b>Recording sublingual crescent region for improving stability and retention in mandibular dentures</b>	33
– Thomas Paul	
<b>Rehabilitation of an edentulous geriatric patient with resorbed residual ridges and excessive interarch space using a maxillary hollow complete denture</b>	37
– Ashwin Kumar S G.	
<b>Comparison of different methods of assessing alveolar ridge dimensions prior to dental implant placement</b>	40
– Veena T.K.	
<b>Predictive marker of residual ridge resorption-biochemical and radiographic evaluation</b>	43
– Jemcy James	
<b>Current concepts in eradicating enterococcus faecalis biofilm</b>	47
– Ruth Hepsi Bealah	
<b>Digital impressions – a peak into the future</b>	51
– Rohit Raghavan	
<b>A case report on the management of an infrabony defect with tetracycline fibres</b>	55
– Kadeeja Rushin	
<b>Sweetening the burden of diabetes</b>	58
– Navia George	
<b>Evaluation of the effectiveness of photodynamic therapy using toluidine blue for microbial reduction in periodontal pockets</b>	60
– Anjhana Narayanan	
<b>Management of Excessive Gingival Display</b>	65
– Jyotsna J.	
<b>A cross sectional survey on the utilization of scientific journals among staffs and students of dental colleges in Kerala</b>	68
– Civy V. Pulayath	
<b>Quiz</b>	70
– Jayanthi	
<b>Association News</b>	71

# President's Message

---



**Dr Mohamad Sameer P T**

Dear friends and colleagues,

It is with pride and honor that I write my first letter addressing the members of the kerala state branch of the Indian Dental Association. This wonderful organization runs on the shoulders of ordinary members like each of you and I pray that I will be able to move forward with the support of one and all.

Over the years under the able leadership of the past presidents and secretaries IDA KSB has grown in many levels.

The social commitment of its members is tremendous and I wish to highlight this during my tenure as President. It is my dream to serve the elderly underprivileged people of our homeland by making the maximum number of complete dentures possible and delivering them to the needy.

I earnestly request all members of our branch to take up this cause and volunteer to make a complete denture for the needy person in your neighbourhood.

Our association's activities encompass a wide range -social, professional and humanitarian. Together with the Honorary Secretary Dr Suresh Kumar G and our team, we wish to highlight our activities in society and please ensure that you take an active role in the CDE, CDH and cultural programs of your branch. Together we will be take IDA to greater heights and make it more visible in the public eye. At the same time, we are also striving to create a smoother arena for the functioning and for obtaining the required governmental clearances for the same by coordinating with the government and other agencies. I assure you that I will do my very best to safeguard the interests of the profession and once again seek your blessings and support

Jai Hind and Jai IDA

**Dr Mohamad Sameer P T**  
President, IDA Kerala State

# Secretary's Report

---



**Dr. Suresh Kumar G**

My “GOOD WISHES” to all members of IDA Kerala State. At the onset let me thank all members of IDA Kerala State for giving me the opportunity to correlate with you at a more personal level as Hon. Secretary of this prestigious organisation. Naturally, I’m acutely aware of the profound responsibility and trust this position carries along with it.

On behalf of IDA Kerala State I request each one of you to make a concerted effort whereby more dentists can be brought under the IDA Kerala State umbrella and thus strengthen our hands to meet the challenges that would come up in our profession. Besides this also increases the fraternity feeling among ourselves with mutual trust and brotherhood.

Our doors are open to all members at all times and we will always be available to hear your grievances and find a suitable and amicable solution to your problems within the ambit of reasonable limits. Professional issues such as the problems associated with mushrooming of Dental colleges, the private dental practice scenario, the proposed Clinical Establishment legislation, the problems associated with registrations and Licences are just some of the many key issues which threatens to undermine working conditions of private clinics in this state on which we will continually remain vigilant.

I sincerely hope that IDA is able to extend its presence to the Government sector and Private colleges as well. Efforts will be undertaken to liaise with professional dental organisations in the Government sector and it would definitely strive to uphold and protect the rights of the Private dental college faculties. Our aim would be to position IDA in its rightful place with regard to policy making and administrative positions thereby playing a vital role with regards to Dental profession.

The onus of the state office will be on effective communications with the Local Branches and its members. As we grow in strength and number we have to adapt more to embrace ourselves with the technology around us while at the same time realise that this does not create a disconnect with the members at large.

I hope during my tenure as Hon Secretary, the office would be able to carry along all members in unity and friendship and also expect that all members will extend their undivided support to implement the ideals that our predecessors have tirelessly struggled to implement over the years.

Last but not the least, I extend my appreciation to the Editorial Board of KDJ and in particular to Dr K. Nandakumar who over the years have made KDJ the best journal ever.

**Dr. Suresh Kumar G.**

Hon. Secretary, IDA Kerala State



Dr. K. Nandakumar

## Are you serious about the future of Dentistry in India?

Time has ripened to present consolidated facts related to dentistry in India. If we are not considering the facts seriously and react appropriately, dentistry as a profession will have no standing in the world especially against other countries. These are the facts to be considered:

1. First dental college was started in Calcutta by Dr. R. Ahmed in 1920
2. First private dental college was started in 1966
3. There are 310 Dental colleges in the country out of which 292 are in the private sector and 40 in the government sector
4. Approximately 118,000 dentists are working in India.
5. 5% of graduated dentists are working in the government sector.
6. More than 30000 dental graduates are added to the profession every year.
7. Dentist to population ratio is approximately 1:10270
8. Dentist population ratio for India suggested by WHO is 1:7500
9. If the present situation continues there will be a surplus of more than one lakh dentists by 2020.
10. Private clinics are not viable in rural areas because of lack of awareness of oral health amongst the rural population.
11. Dental graduates are facing serious financial constraint. Unemployed dentists are left with no choice but to leave their profession and work in areas which have no connection with the dental profession like call centers etc.
12. Yearly visit to dentist is nearly 100% in the upper socio economic status and 32.3% in the lower socio economic status
13. Graduates when they go abroad face the ridiculing question “have you bought your degree for a price”
14. Pass percentage in the professional examinations conducted by both health and deemed universities is approximately 90% and above
15. A number of dentists are now moving to places like Russia, Romania, Germany for higher education

16. Countries like USA, UK, Australia and New Zealand are popular destinations for dental graduates for higher education and employment
17. Excepting a few clinical branches like Endodontics, Orthodontics and Prosthodontics, students are reluctant to join for MDS course.
18. Private colleges do not find running MDS programme as a profitable business option and are planning to close down programmes in non clinical subjects

The Government has to take some proactive steps immediately to stall the down fall of the dental profession. Government hospitals especially primary health centres should have posts of dentists so that people of the rural areas can have access to quality dental health care. Proposals to start dental colleges should not be entertained in the next 10 years. Dentist population ratio and linked creation of new dental colleges is a fallacy. Make a statistics on the realistic picture of dental graduates to find out where do they work or where do they disappear. Both central and state governments should seriously think of the future of dental profession.

### Further reading

Chandrashekar BR, Reddy C, Manjunath BC, Suma S. Dental health awareness, attitude, oral health-related habits, and behaviors in relation to socio-economic factors among the municipal employees of Mysore city. *Ann Trop Med Public Health* 2011;4:99-106.

Hemant Jain and Aparna Agarwal, Crisis Facing Dental College Graduates in India, *Journal of Clinical and Diagnostic Research*. 2012, 6: 1-4

Vundavalli.S, Dental manpower planning in India: current scenario and future projections for the year 2020; *International Dental Journal*, 2014, 64:62-7

**Dr. K. Nandakumar**  
Editor, KDJ



# Biologic Width – Line of controller of Gingiva

\* Agee Antony, \*\*Subair K., \*\*\*Anil Melath

## Abstract

Biologic width is perceived to bestow specific numeric dimensions to a unique and dynamic biologic entity. Maintenance of biologic width is one of the key for the success or longevity of dental restorations and for the tooth. Clinicians must be aware that biologic width is indeed a reality and violation of biologic width leads to complication such as gingival inflammation and alveolar bone loss. Preserving biologic width can pave way for a longer life of restorations with healthy Periodontium. This article discusses the various methods for biologic width assessment, guidelines and various procedures for reconstruction of biologic width.

**Key words:** Biologic width, restorative margin, gingivectomy, apically repositioned flap, supracrestal fiberotomy.

KDJ 2016 | Vol. 39 | No. 1 | Pg 13-16

## ► Introduction

Natural teeth are surrounded by gingival soft tissues that provide a biologic seal between the oral cavity and the inside of the body. This unique structure is composed of epithelium and soft connective tissue that are continually bathed in gingival fluid<sup>1</sup>. This unique structure; biologic width is rather a great emphasis focused on perio-restorative interface in restorative dentistry. The biologic width is defined as “the dimension of soft tissue, which is attached to the portion of the tooth coronal to crest of alveolar bone”<sup>2</sup>.

## The concept of biologic width:

The concept of biologic width is based on histologic studies by Gargiulo et al<sup>3</sup> of the stages of passive eruption in normal cadaver Periodontium, on the dimensions and relationships of dentogingival junction in humans. The reported findings were gleaned from 30 human cadaver jaws, and 287 teeth of which 325 surfaces were examined and quantified the average as a constant 2.04mm (the epithelial attachment is 0.97 mm, and connective tissue is 1.07 mm) with sulcus depth 0.69 mm. (fig. 1). In 1977, Ingber et al described biologic width and credited D Walton Cohen for first coining the term “biologic width”<sup>4</sup> and suggested that a minimum of 3mm was required from the restorative margin to alveolar bone crest to permit adequate healing and restoration of tooth. Maynard and Wilson (1979) divided the periodontium into three dimensions; superficial physiologic, crevicular physiologic and subcrevicular physiologic.<sup>5</sup>

- Superficial physiologic- free gingival+attached gingival
- Crevicular physiologic- dimension from gingival margin to junctional epithelium
- Subcrevicular physiologic- junctional epithelium+connective tissue attachment

In 1994, Vacek et al on evaluation reported that connective tissue attachment was the most consistent measurement and interproximally the biologic width is similar to that of the facial surface but not the total dentogingival complex.<sup>6</sup>

## Evaluation:

- ❖ Clinical method
- ❖ Bone sounding
- ❖ Radiographic method

## Clinical method:

Signs of biologic width violation that are seen clinically are as follows:<sup>7</sup> (fig 2 &3)

- Chronic progressive gingival inflammation around the restoration
- Bleeding on probing
- Localized gingival hyperplasia
- Clinical attachment loss
- Alveolar bone loss

## Bone sounding

The biologic width can be assessed by probing under local anesthesia to the bone level and if this distance is less than 2mm at one or more locations, a diagnosis of biologic width violation can be confirmed (fig. 4). It can be a presumptive guide for bone level assessment.<sup>8</sup>

## Radiographic evaluation:

Radiographic interpretation can identify interproximal violations of biologic width. A new innovative parallel profile radiographic (PRR) technique is used to measure both length and thickness of dentogingival unit with accuracy.<sup>9</sup>

## Perio-restorative interrelationship:

Categories of biologic width and margin placement guidelines to prevent violation. Kois proposed three categories of biologic width based on total dimension of attachment and the sulcus depth following bone sounding measurement namely normal crest, high crest, low crest.<sup>10,11</sup>

\* Junior Resident, \*\*Reader, \*\*\*Professor & HOD, Principal, Department of Periodontics; Mahe Institute of Dental Sciences & Hospital, Mahe • Corresponding Author: Dr. Agee Antony E-mail: antonyagee@gmail.com

**Normal crest :**

In the normal crest patient, the mid-facial measurement is 3.0mm and proximal measurement is a range from 3.0 mm to 4.5 mm. (Fig 5) Normal crest occurs approximately 85% of the time. In these cases gingival tissues tends to be stable for long term.

**High crest:**

In the high crest patient, the mid-facial measurement is less than 3.0 mm and the proximal measurement is also less than 3.0 mm and the proximal measurement is less than 3.0mm. (fig. 5) This is an unusual finding in nature and occurs approximately 2% of the time. There is one area where high crest is seen more often, in a proximal surface adjacent to an edentulous site. In the high crest patient, the mid-facial measurement is less than 3 mm.

**Low crest :**

In the low crest patient group, the mid-facial measurement is greater than 3 mm and the proximal measurement is greater than 4.5 mm. (fig. 5) Low crest occurs approximately 13% of the time. Traditionally a low crest patient has been described

as more susceptible to recession secondary to the placement of an intracrevicular crown margin.

**Restorative margin:**

The restoration margins can be grouped in any of the following three categories: - supragingival, equigingival, and subgingival (fig 6).<sup>12</sup>

**Supragingival margin**

It is the least irritating to the periodontium and is easy to prepare. The final fit and finish of the margins and removal of excess cement are also the easiest to achieve. Though this type of margin has the least impact to the periodontium, it is unaesthetic and preferred only in non-esthetic areas.

**Equigingival margin**

Equigingival margin can be easily blended with the tooth and can be finished easily to provide a smooth and polished margins. But such margins are not desirable as they are thought to favor more plaque accumulation and therefore result in greater gingival inflammation.

**Subgingival margin**

Though it is esthetic, it is detrimental to periodontal health

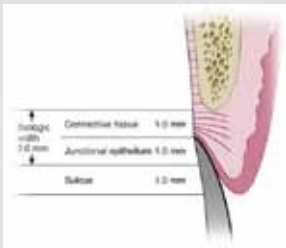


Fig. 1

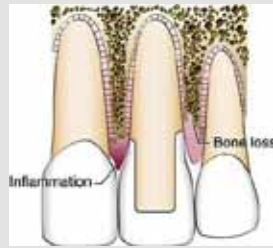


Fig. 2

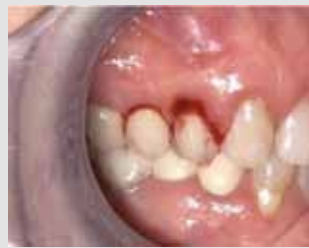

Fig. 3

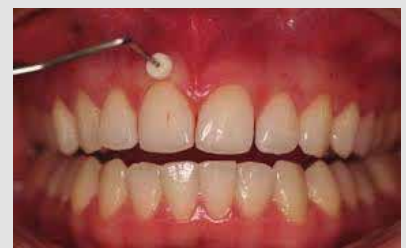

Fig. 4

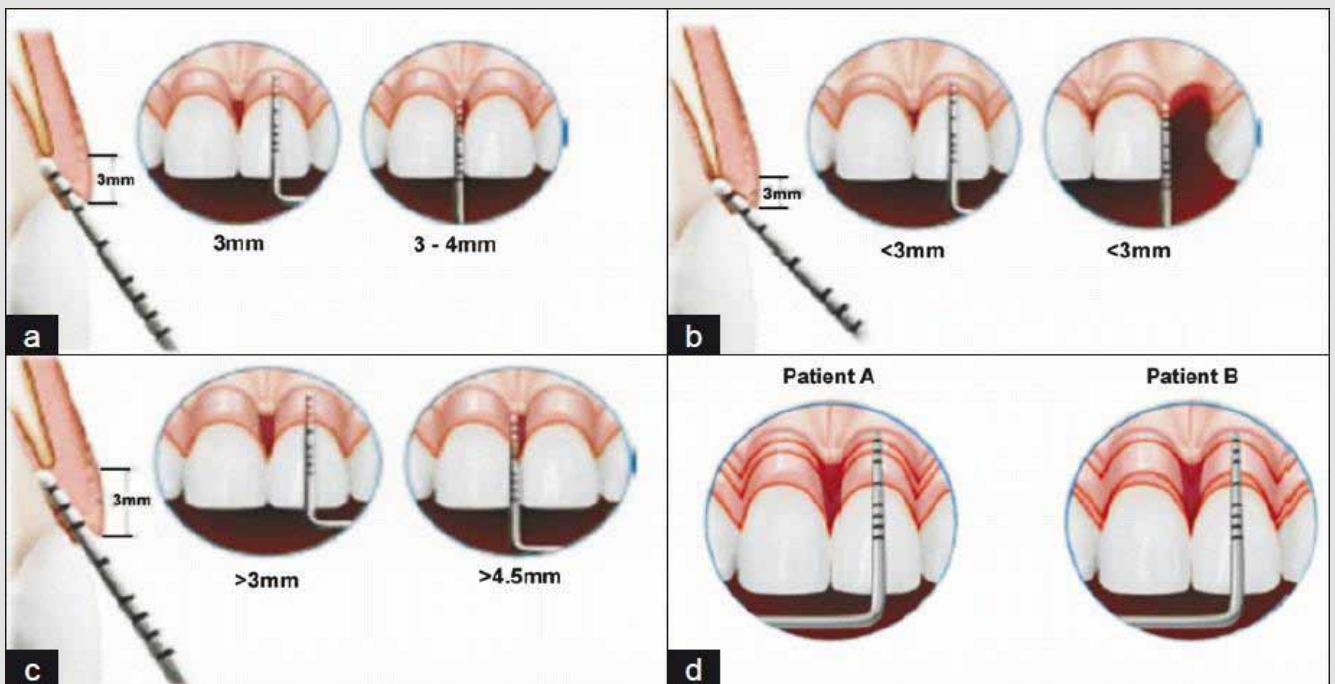


Fig. 5



as it acts as a permanent irritant to the periodontium. Many studies have demonstrated qualitative and quantitative changes in subgingival microbes, increased plaque index, gingival recession and pocket depth.<sup>5</sup> Biologic width encroachment becomes more common when planning for subgingival restorations in cases that are fractured or carious, near the alveolar crest. Also esthetics demands often require hiding of restorative margins below the gingival margins i.e., pushing them down into the sulcus, which may cause biologic width violation.

Based on the sulcus depth, the following three rules can be used to place intracrevicular margins:

1. If the sulcus probes are 1.5 mm or less, the restorative margin could be placed 0.5 mm below the gingival tissue crest
2. If the sulcus probes are more than 1.5 mm, the restorative margin can be placed in half the depth of the sulcus.
3. If the sulcus is greater than 2 mm, gingivectomy could be performed to lengthen the tooth and create a 1.5 mm sulcus. The patient can then be treated as per rule.<sup>13,14</sup>

**Correction of biologic width**

- ❖ Surgical correction
  - Gingivectomy
  - Apically repositioning flap surgery
- ❖ Orthodontic correction

**Surgical crown lengthening:**

Designed to increase the clinical crown length and Surgical correction is aimed at removing the bone away from the restorative margin.<sup>15</sup>

Indications: (1) Inadequate clinical crown for retention due to subgingival caries or tooth fracture within the cervical 1/3rd of the root in teeth with adequate periodontal attachment, (2) Placement of sub gingival restorative margins, (3) Unequal, excessive or unaesthetic gingival levels for esthetics, (4) Teeth with excessive occlusal wear or incisal wear, (5) Teeth with inadequate interocclusal space for proper restorative procedures due to supraeruption.

Contraindications: (1) Deep caries or fracture requiring excessive bone removal, (2) Post surgery creating unaesthetic outcomes, (3) Tooth with inadequate crown root ratio, (4) Non restorable teeth, (5) Tooth with increased risk of furcation involvement.

**External bevel gingivectomy:**

It can be used only in situations with hyperplasia or pseudopocketing (> 3 mm of biologic width) and presence of adequate amount of keratinized tissue. (fig 7)<sup>16</sup>

**Internal bevel gingivectomy:**

Reduction of excessive pocket depth and exposure of additional coronal tooth structure in the absence of a

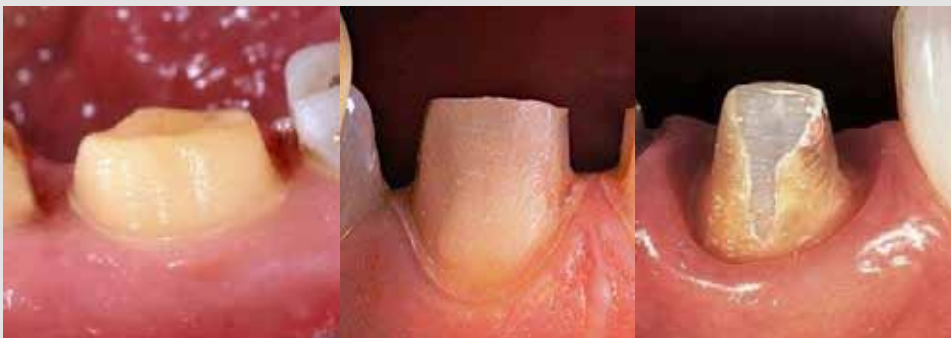

Fig. 6

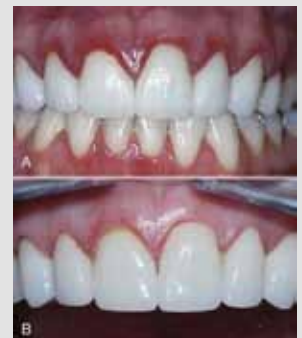

Fig. 7

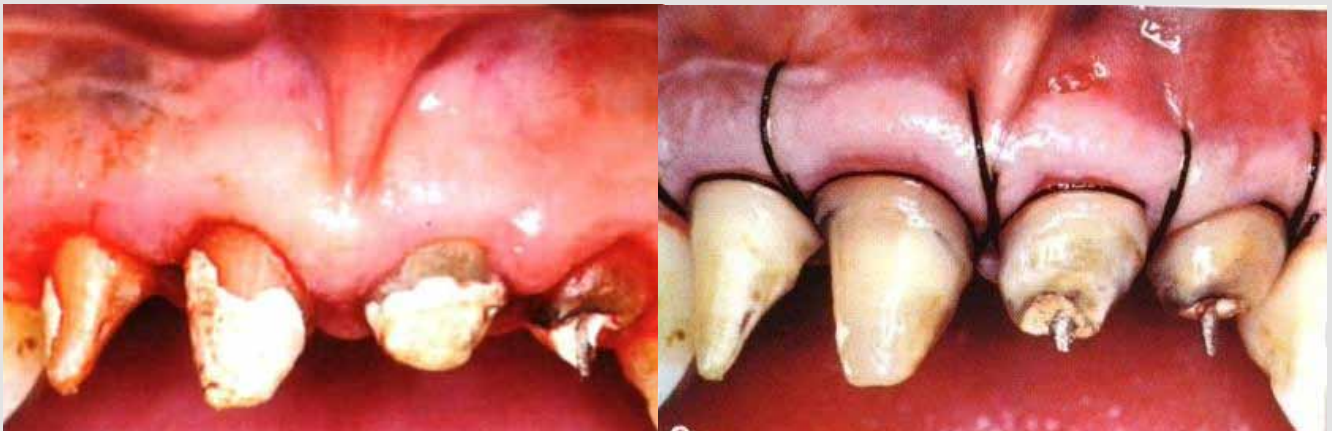

Fig. 8

sufficient zone of attached gingiva with or without the need for correction of osseous abnormalities requires internal-level gingivectomy.

**Apical repositioned flap surgery:**

This procedure is done when there is no adequate width of attached gingiva. (fig 8) Indicated for crown lengthening of multiple teeth in a quadrant or sextant of the dentition, root caries, fractures.<sup>17</sup> Contraindication during surgical crown lengthening of a single tooth in the esthetic zone.

<b>Apical repositioned flap surgery without osseous resection</b>	<b>Apical repositioned flap surgery with osseous resection</b>
when there is a biologic width of more than 3 mm on multiple teeth	when biologic width is less than 3 mm

**Orthodontic extrusion:**

It is indicated in cases when traditional surgical crown lengthening will lead to unaesthetic outcomes or which could lead a negative architecture.<sup>18,19</sup> Extrusion is performed in two ways:

- Forced eruption with minimal osseous resection
- Forced eruption combined with fiberotomy

**New advanced technique in orthodontic correction:**

Orthodontic extrusion associated with supracrestal fiberotomy and root planning (OEFRP):

It is a new flapless technique for crown lengthening after orthodontic extrusion.<sup>20</sup> The OEFRP procedure must be carried out every 2 weeks during the entire extrusive orthodontic phase.

► **Conclusion:**

Biologic width is the sum of epithelium and connective tissue attachment on the tooth surface. Therefore the biologic width can be understood as the body’s response to the special challenges at the site where a tooth emerges through oral mucosa. Periodontal health depends on appropriately designed restorations with correctly placed margins without violating the biologic width. Although individual variations exists in the soft tissue attachment around the teeth there is general agreement that a minimum of 3 mm should exist from the restorative margin to alveolar bone allowing for 2 mm of biologic width space and 1 mm for sulcus depth. All things are subject to interpretation, whichever interpretation prevails at a given time is a function of power and not truth.

► **References:**

1. Dhir.S.Significance and clinical relevance of biologic width to implant dentistry.J.Interdisciplinary dentistry.2012;2,84-91.
2. Newman MG,Takei HH,Klokkevold PR,Carranza FA. Clinical Periodontology,11th edition;Saunders-elsevier, Missouri(USA).
3. Garguilo AW,Wentz FM,Orban B.Dimensions and relations of dentogingival junction in humans.J.Periodontol 1961;32:261-7
4. Ingber JS,Rose LF,Coslet JG.'The biologic width'- a concept in periodontics and restorative dentistry. Alpha Omegan 1977;70(3):62-5
5. Maynard JG, Wilson RD.Physiologic dimensions of the periodontium, significant to the restorative dentist.J.Periodontol 1979;50(4):170-4
6. Vacek JS,Gher ME,Assad DA et al. The dimensions of human dentogingival junction.Int. J.Periodontics restorative dentistry.1994;14:154-165
7. Jorgic-Srdjak,Plancak D,Maricevic T.Dragoo MR, Bosnjak A. Periodontal & prosthetic aspect of biologic width part I:Violation of biologic width.Acta Stomatol Croat 2000;34:195-7
8. Newman MG,Takei HH,Klokkevold PR,Carranza FA. Clinical Periodontology,11th edition;Saunders-elsevier, Missouri(USA) 2006, p:1050-69.
9. Galgali SR,Gontiya G.Evaluation of an innovative radiographic technique-parallel profile radiography-to determine the dimensions of the dentogingival unit. Indian J.Dent Res2011;22:237-41.
10. Kois JC. The restorative-periodontal interface:biologic parameters. Periodontal 2000.1996; 11:29-38.
11. J.Williams Robbins.Tissue management. Functional esthetics & restorative dentistry 2007;1:40-3
12. Amit parshar,Abhishek Zingade,Sheetal Sanikop et al. Biologic width:silent zone. Int. Dental J.2015:2011-15.
13. Orkin DA,Reddy J,Bradshaw D. The relationship of the position of crown margins to gingival health. J.Prosthetic dent. 1987; 57(4):421-24.
14. Freeman K,Berbermeyer R,Moretti A, Koh S.Single tooth crown lengthening by the restorative dentistry-A case report.J.Gt.Houst. Dent Soc 2000;2:14-6.
15. Jorgic-Srdjak,Plancak D,Maricevic T.Dragoo MR, Bosnjak A. Periodontal & prosthetic aspect of biologic width part II:Reconstruction of anatomy function. Acta Stomatol Croat2000;34:441-4.
16. Smukler H,Chabi M. Periodontal and dental considerations in clinical crown extension-A rational basis for treatment. Int.J.Periodont Res. Dent 1997;17:464-77.
17. Khuller N,Sharma N.Biologic width- evaluation and correction of its violation. J.Oral health comm. Dent 2009;3:20-5.
18. Luis Antonia Felippa,Sylvio Monterio,Luis Clovis,Cardosa Vierra,Elito Araujo. Re-establishing biologic width with forced eruption. Quintessence Int, 2003;34:733-38.
19. Ingber JS : Forced eruption II- A method of treating non-restorable teeth, periodontal & restorative considerations. J.Periodontol 1995;47:203
20. Braga G,Bocchieri A. A new flapless technique for crown lengthening after orthodontic extrusion. Int. J.Periodontics res. Dent. 2012;32:81-90.

# Interdisciplinary Periodontics

\*Harikrishnan Balachandran Pillai, \*\*Devisree Naveen, \*\*Teenu Abraham, \*\*\*Padmakumar T P, \*\*\*\* Nandakumar K.

## Abstract

The interdisciplinary approach has been a trend for a comprehensive dental treatment. The inter-relationship between different specialities in dentistry is very much necessary for the successful treatment outcome. In this case we have tried to restore the lost periodontal structures for teeth to be used as an abutment for prosthetic replacement and thus improve the treatment outcome.

KDJ 2016 | Vol. 39 | No. 1 | Pg 17-19

## ► Introduction

Periodontal disease is an infectious disease which results in destruction of periodontal structures and if untreated in time, leads to loss of teeth<sup>1</sup>. Most of the time, loss of teeth without replacement results in unwanted consequences such as drifting of teeth, food impaction and occlusal disharmony. Hence, preservation of the compromised remaining teeth which can be used as abutments for the prosthetic replacement is deemed important. In these type of cases a multidisciplinary approach involving periodontics and prosthodontics ensures restoration of the lost periodontal structures so that prosthetic restoration can be successfully placed. The importance of multidisciplinary approach in the long term prognosis of periodontal treatment is thus explained.

Within modern dentistry, periodontics and prosthodontics share an intimate and inseparable relationship in multiple aspects, including treatment plan, procedures execution, outcome achievement and maintenance. By controlling inflammation and preparing sites for proper prosthetic prostheses, periodontists no doubt can provide a solid foundation for successful prosthetic outcomes<sup>5</sup>.

## ► Case report

A 48 year old female patient reported to the department of periodontics, Azeezia College of Dental Sciences and research, Kollam complaining of mobile teeth in upper left back region of the jaw. The Patient came for fixed replacement of adjacent edentulous area and was referred from department of Prosthodontics for assessing the prognosis of the teeth as a fixed abutment. She had a history of extractions 5 years back, prosthetic replacement of contralateral area 1 year back, and root canal treatment 3 weeks back. Patient is a known diabetic with FBS 113 mg% and is on oral hypoglycaemic drug for the past 1 year.

On intra oral examination of 23, 24, 25, 26, 27 area, the marginal gingiva appeared soft, oedematous and rolled out, periodontal pocket of 7mm was present in relation to mesio-buccal area of 27, missing teeth were present in relation to 24, 26. There was traumatic

occlusion on 27 from extruded 38 and grade 2 mobile 27. (Fig 1, 2)

In IOPA, there was a radiolucency in the mesial surface of 27 extending from the cemento-enamel junction till the apical third of root, suggestive of vertical bone loss. (Fig 3)

The case was diagnosed to be chronic generalised periodontitis with primary occlusal trauma in 27.

The prognosis of the tooth was poor and it was ideal to undergo extraction. But since it was planned to replace the adjacent edentulous area, regenerative periodontal access therapy was planned.

The treatment plan included initial etiologic phase inclusive of removal of plaque and calculus, extraction of 38 and oral hygiene reinforcement. Next surgical phase followed that is periodontal access therapy in 27 region. Restorative phase followed with temporisation in the edentulous area and later permanent prosthesis placement.

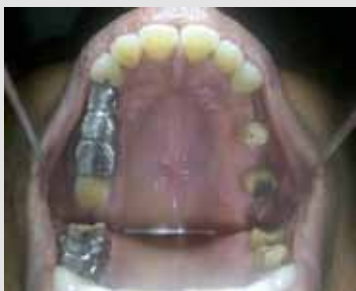## ► Periodontal access therapy

Initially 5 ml of venous blood was collected from anti-cubital fossa and was subjected to centrifugation for 3000 r.p.m for 10 minutes for PRF preparation.

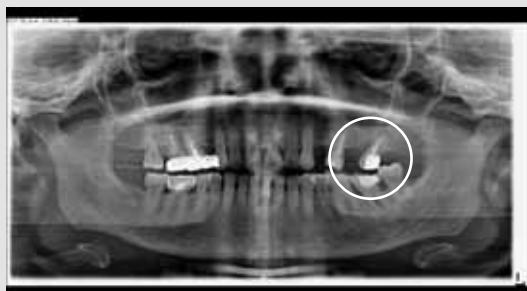
After acquiring sufficient anaesthesia, crestal incision was placed with no.15

\*PG student, \*\*Senior Lecturer, \*\*\*Professor, \*\*\*\*Professor and HOD, Department of Periodontics, Azeezia College of Dental Sciences and Research, Meeyannoor, Kollam. Corresponding Author: Dr. Harikrishnan Balachandran Pillai. E-mail: hkbp83@gmail.com.

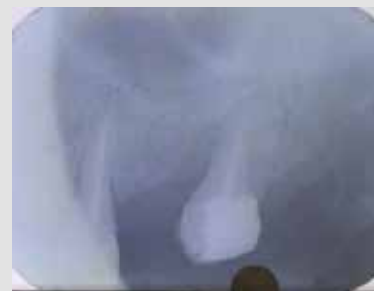



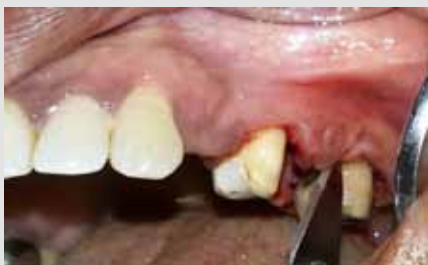**Fig 1:** Pre-operative view showing edentulous area in 2nd quadrant



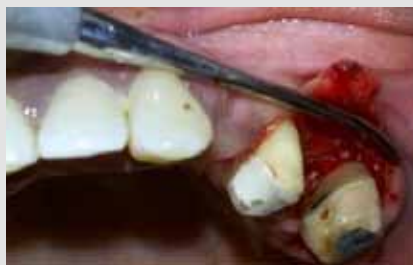**Fig 2:** Pre-operative OPG showing edentulous area in 2nd quadrant



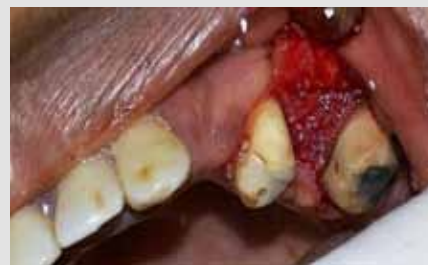**Fig 3:** Pre-operative IOPA showing intra bony defect.



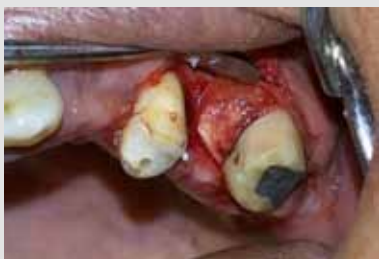**A**



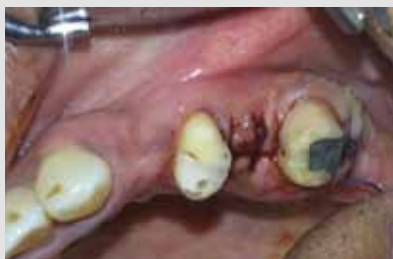**B**



**C**

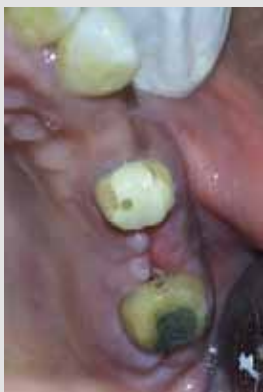

**D**

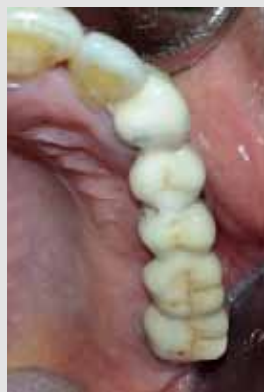

**E**

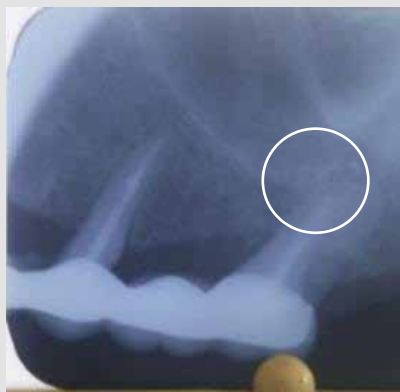**Fig 4:**  
**A** - Incision placed  
**B** - mucoperiosteal flap reflected and granulation tissue curettage done,  
**C** - hydroxyapatite bone graft mixed with PRF placed after root conditioning  
**D** - GTR membrane placed  
**E** - sutured with 3-0 resorbable suture



**Fig 5**

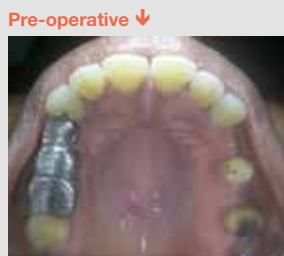

**Fig 6**

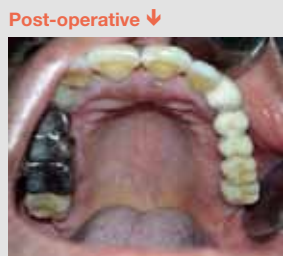

**Fig 7**

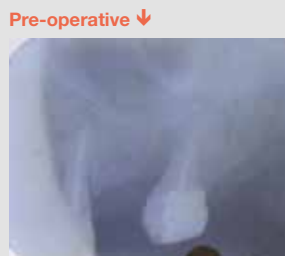
**Fig 5:** 1 week post-operative view,  
**Fig 6:** 1 year post-operative photograph after final prosthesis,  
**Fig 7:** 1 year post-operative IOPA showing bone fill



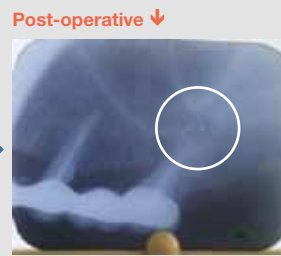**Pre-operative** ↓



**Post-operative** ↓



**Pre-operative** ↓



**Post-operative** ↓

**Fig 8:** Pre-operative and post-operative photograph and IOPA

Bard Parker blade in edentulous area of 26 and distal to 27 and sulcular incision was placed in 27 area (Fig 4A). Muco-periosteal flap reflection was done using periosteal elevator and the defect was debrided with area specific Gracey curette and evaluated for configuration of defect which was a 2-wall vertical defect (Fig 4B). Next root conditioning was done with tetracycline and the defect was packed with Hydroxyapatite mixed with PRF (Fig 4C). GTR membrane was placed and sutured with 3-0 resorbable suture (Fig 4D, E). The patient was recalled after 6 days for suture removal (Fig 5).

The patient was recalled for temporary bridge restoration in relation to 25, 26, 27 after 3 months. There was reduction in gingival inflammation, probing depth and also gain in attachment level.

Final prosthesis was delivered after 1 year follow-up after clinical and radiographic assessment (Fig 6). In IOPA bone fill was noted 1 year post-operatively (Fig 7, 8).

### ► Discussion

Prior to treatment plan, tooth prognosis should be addressed both on individual tooth and the overall dentition. Several periodontal prognostication systems have been introduced based on either periodontal stability<sup>2,3</sup> or certain parameters<sup>2,4</sup>, such as furcation involvement, tooth mobility, the severity of bony destruction, etc. By identifying the etiology and contributing factors of periodontal diseases, these systems indicate the possibility of tooth sustainability in short term and long term.<sup>5</sup>

Active periodontal diseases and contributing factors should be eliminated or controlled prior to prosthodontic constructions. The signs of active periodontal inflammation include pocket formation, the presence of bleeding on probing or suppuration, and tissue changes of gingiva. Without controlling the existing periodontal inflammation, a cascade of adverse events of periodontal destruction would take place and cause persistent inflammation, bone resorption and eventually tooth loss. In other words, function and lifespan of the prosthesis will be compromised if periodontal diseases remain uncontrolled after delivery.<sup>5</sup>

The primary goal of periodontal treatment is the maintenance of the natural dentition in health and comfortable function<sup>6</sup>. When periodontal disease has caused a loss of the attachment apparatus, optimal care seeks to regenerate the periodontium to its pre-disease state.

### ► Conclusion

Reconstructive periodontal surgical procedures provide the most dramatic improvement in the treatment of intra-bony defects of all currently available modalities.

In this case we have used regenerative periodontal therapy to save the teeth from extraction and use the same teeth as a prosthetic abutment.

Patients who had history of periodontitis, regular supportive periodontal therapy is beneficial to prevent further disease progression and failure of prosthesis. Regular periodontal maintenance is the key to reduce the incidence of tooth loss following prosthetic therapy. Due to limitation of home cares, regular professional maintenance therapy plays a key role in reduction of periodontal inflammation induced by plaque accumulation, especially in the subgingival area.

The inter-relationship between prosthodontics and periodontics is intimate and inseparable. Robust supporting periodontal tissues provide solid foundations for predictable prosthetic therapy. For regaining stable periodontal conditions establishment of proper contact types, occlusal scheme and quality prosthesis is mandatory. Frequent and efficient communications are essential between periodontists and prosthodontists to create pleasing esthetics with a harmonious stomatognathic system.<sup>5</sup>

### ► References

1. Consensus Report: Chronic Periodontitis. *Ann Periodontol* December 1999; Volume 4, Number 1.
2. Newmann, Takei, Klokkevold, Carranza, Carranza's Clinical Periodontology, 10th edition.
3. Kwok V, Caton JG. Commentary: prognosis revisited: a system for assigning periodontal prognosis. *J Periodontol* 2007; 78: 2063-71.
4. Becker W, Berg L, et al. The long term evaluation of periodontal treatment and maintenance in 95 patients. *Int J Periodontics Restorative Dent* 1984; 4: 54-71.
5. Nan-Chieh Huang, Hom-Lay Wang. Relationship between Periodontics and Prosthodontics: The Two-Way Street, *Journal of Prosthodontics and Implantology*, Volume 4, Number 1, 2015
6. Position Paper Periodontal Regeneration, *J Periodontol*, September 2005.



# Saliva: A diagnostic tool for oral cancer

\*Jinisham, \*\*Nileena R. Kumar, \*\*\*Haris P.S., \*\*\*\*Anita Balan

## Abstract

Oral cancer is a common and lethal malignancy. Oral squamous cell carcinoma, OSCC is sixth most common epithelial malignancies with significance morbidity and mortality. In spite of diagnostic and therapeutic advances over the decades, the disease still remains a challenge. Despite the fact that the oral cavity is easily accessible, most OSCCs are not diagnosed until an advanced stage, which is believed to be the major reason for the low survival rate, and points to the urgent need for clinical diagnostic aids for early detection of OSCC. Thus, there has been an ever-growing effort dedicated to the basic research of oral cancer, focusing on the identification of biological indicators for the diagnosis.

Salivary diagnostics is a dynamic and emerging field utilizing nanotechnology and molecular diagnostics to aid in the diagnosis. Using saliva for disease diagnostics and health surveillance is a promising approach as collecting saliva is relatively easy and non-invasive. Direct contact between saliva and the oral cancer lesion makes measurement of tumor markers in saliva an attractive alternative to serum testing. Thus, much research effort has been dedicated to investigating potential salivary biomarkers for OSCC.

**Keywords:** saliva; oral cancer; biomarkers

## ► Introduction

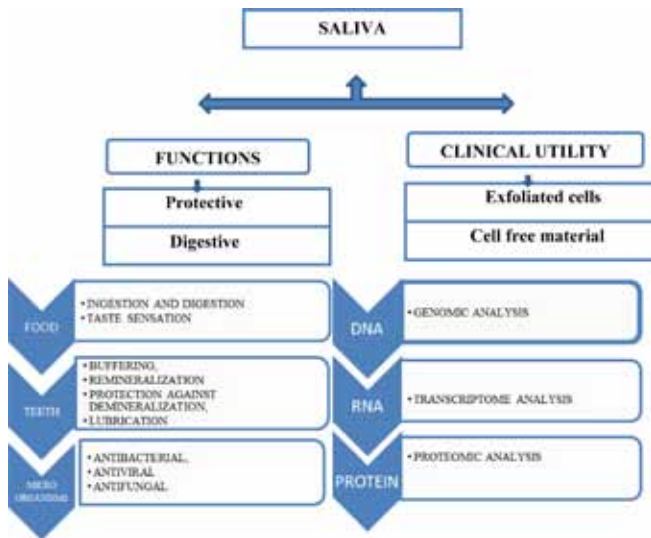
Oral cancer is a common and lethal malignancy and the outcome of the treatment and prognosis largely depends on early diagnosis. Oral squamous cell carcinoma is the most common among oral cancers. OSCC is the sixth most common human malignancy, with a 5-year mortality rate of approximately 50%<sup>1</sup> which has not changed significantly in more than 50 years, and a high rate of morbidity. The therapeutic modality currently offered to OSCC patients is based on traditional stage-predicting indices (based mostly on the TNM criteria) and on histological grading<sup>2</sup>. Unfortunately, these predictors are subjective and relatively unreliable. Thus, there has been an ever-growing effort dedicated to the basic research of oral cancer. Despite the fact that the oral cavity is easily accessible, most OSCCs are not diagnosed until an advanced stage, which is believed to be the major reason for the low survival rate, and points to the urgent need for clinical diagnostic aids for early detection of OSCC. However, very few studies have examined tumor markers in the saliva of OSCC patients, though such an examination might be of great benefit because of the direct contact between the oral cancer lesion and saliva.

Salivary testing, a non-invasive alternative to serum testing, can be an effective modality for diagnosis and prognosis predicting of oral cancer. Much research effort has been dedicated to investigating potential salivary biomarkers for OSCC. A systematic review of the current status of salivary diagnostics for detection of OSCC is presented

## ► Discussion

### Saliva and its diagnostic potential

Human saliva is a clear, slightly acidic (pH=6.0-7.0) biological fluid containing a mixture of secretions from multiple salivary glands, including the parotid, submandibular, sublingual gland other minor glands beneath the oral mucosa as well as gingival crevice fluid<sup>3</sup>. Saliva has long been proposed and used as a diagnostic medium as it is easily accessible, collection is noninvasive, not time consuming, inexpensive and can be used for mass screening purposes. A major drawback to using saliva as a diagnostic fluid has been the notion that informative analytes generally are present in lower amounts than in serum. However with new techniques of detecting small quantities of salivary components including proteins and messenger Ribonucleic acid (mRNA), almost anything that can be measured in blood can be measured in saliva.

Functions and Clinical Utility of Saliva<sup>4</sup>

### ► Salivary biomarkers for oral cancer detection

So far, more than 100 potential OSCC salivary biomarkers have been reported in the literature. The first report of

saliva as a diagnostic tool for oral cancer detection was published in 2000<sup>4</sup>. Global profiling of disease-associated molecules, such as proteins, DNA, mRNA, micro RNA, and metabolites is becoming the state-of-the-art method to provide promising disease biomarker candidates. The ability to globally profile these molecules in saliva, through transcriptomic and proteomic approaches, as well as the ability to detect specific molecules in saliva will greatly enhance the opportunities to identify reliable oral cancer biomarkers.

### Mechanism for the presence of biomarker in saliva

Though the exact mechanism for the presence of these tumor markers in saliva is not known, they may be either derived from serum or can be produced locally<sup>5</sup>. Molecular markers for the diagnosis of oral cancer can be queried in 3 levels;<sup>6</sup> changes in the cellular Deoxyribonucleic acid (DNA) which results in altered mRNA transcripts leading to altered protein levels intracellularly, on the cell surface or extracellularly. Markopoulos et al<sup>6</sup> have summarized the molecular markers for the diagnosis of OSCC

Changes in cellular DNA	Altered mRNA transcripts	Altered protein markers
Allelic loss on chromosome	Presence of IL-8	Elevated levels of Defensin 1
Mitochondrial DNA mutation	Presence of IL-1 $\beta$	Elevated CD44
P53 gene mutations	Dual specificity phosphatase 1 (DUSP 1) H3F3A (H3histone, family 3A)	Elevated IL-6, IL-8
Promoter hypermethylation of genes	Ornithine decarboxylase antizyme 1 (OAZ1)	Inhibitors of apoptosis (IAP)
Cyclin D1 gene amplification	S100 calcium binding protein P (S100P) Spermidine/spermine N1-acetyl transferase (SAT)	Squamous cell associated antigen (SCC-Ag)
Increase in ki67 markers		Carcino-embryonic antigen (CEA)
		Micro satellite alterations of DNA
		Presence of HPV and EBV virus genome
		Carcino-antigen (CA19-9), CA 128
		Serum tumor marker ( CA 125)
		Intermediate filament protein (Cyfra 21-1)
		Tissue polypeptide specific antigen (TPS)
		Reactive nitrogen species (RNS)
		8-OHdG DNA damage marker
		Lactate dehydrogenase (LDH)
		Immunoglobulin (IgG)
		s- IgA
		Insulin growth factor (IGF)
		Metalloproteinases

DNA; Deoxyribonucleic acid; mRNA; messenger ribonucleic acid; HPV; Human Papilloma Virus ;EBV; Epstein Barr Virus

### ► Alterations in host cellular DNA

DNA markers are universal i.e., there is not a single tumor cell with in the lesion which does not contain its genetic material. They originate from dead cells, are detected in the early stage of tumorigenesis and are absolutely oncospecific; showing a direct cause-and-effect relationship with tumorigenesis. However, tissue specificity of DNA markers is very low.<sup>7</sup>

Loss of heterozygosity (LOH) is defined as loss of genomic material in one of the chromosomal pair. Studies have shown that LOH in regions that contain a known human suppressor gene is an early predictor of malignant transformation of precancerous lesion<sup>8</sup>.

Rosin *et al*,<sup>9</sup> in their study found that allelic loss at 3p and 9q increase the risk of malignant transformation by 3.8 fold and the risk of further increase to 33 fold when LOH occurs at chromosomes 4q, 8p, 11q, 13q and 17p in addition to the former.

p53 gene located on chromosome 17p13.1 exhibits mutation in 50-70% of epithelial tumors 10, 11 and LOH of p53 allele has been reported in 22% of pre-cancer and 20% of oral cancer. Other genes such as p16, p27, p63, p73 related to p53 and cell cycle have been found to be altered in varying degrees in oral cancer.<sup>10</sup> Promoter methylation, an alternate form of gene silencing, which depends on the epigenetic factor has been described to be involved in OSCC<sup>10</sup>. The main genes to be methylated are CDKN2A, CDH1, MGMT, DAPK1<sup>10, 12</sup>.

Amplification and over expression of c-MYCIN-MYC has been observed in 20-40% of oral cancers. Das *et al*,<sup>13</sup> have reported amplification of 11q13, containing 1NT2, HST1 and Cyclin D oncogenes in 30-50% of patients with oral cancer. STAT 3 expression and activation was found in 82% of oral cancers related to chewing tobacco.<sup>14</sup>

Levels of Ki67 marker were increased while 8-oxoguanine DNA glycosylase, phosphorylated-Src and mammary serine protease inhibitor (Maspin) were found decreased in the saliva of patients with OSCC.<sup>2</sup> The presence of HPV and EBV virus genomic sequence has been identified as possible DNA markers in detecting OSCC and tumor progression<sup>15</sup>.

### RNA as a biomarker

RNA has been found to be an informative marker and salivary RNA signatures have been identified for oral cancer. Studies have found seven mRNA molecules; (1) IL-8<sup>16,17</sup> (2) IL1 $\beta$ <sup>16,17</sup> (interleukin 1) which take part in signal transduction, proliferation, inflammation and apoptosis, (3) DUSP1<sup>17</sup> (dual specificity phosphatase 1) with a role in protein modification,

signal transduction and oxidative stress, (4) H3F3A<sup>17</sup> (H3 histone, family 3A) having a DNA binding activity, (5) OAZ1<sup>16,17</sup> (ornithine decarboxylase antizyme 1) taking part in polyamine biosynthesis, (6) S100P<sup>17</sup> (S100 calcium binding protein P) with a role in protein binding and calcium ion binding and (7) SAT<sup>16, 17</sup> (spermidine/spermine N1-acetyltransferase) which takes part in enzyme and transferase activity, to be significantly elevated in OSCC patients rather than in healthy controls

### Protein markers

Protein markers are differentiation antigens of corresponding normal tissue and characterize a certain stage of its maturation. Salivary protein markers have shown moderate sensitivity and specificity as prognostic markers<sup>6</sup>.

A substantial increase in salivary carbonyls (246%) is seen in OSCC patients and points to the fact that there is a significant free radical attack to which the epithelial cells are exposed<sup>2</sup>. Metalloproteinases such as MMP-92, MMP-11<sup>18</sup>, MMP-2<sup>18</sup> are significantly altered in OSCC. IL-6, IL-8 are post inflammatory cytokines and are identified as important mediators of cancer development and powerful activators of not only apoptosis but also anti apoptotic signaling cascade<sup>19</sup> and hence play a role in early detection of oral pre-malignancies and OSCC. Cytokeratins are cytoskeletal intermediate filaments present in almost all normal and malignant epithelial cells.<sup>20</sup> In malignant epithelial cells, the activated protease increases degradation of cytokeatin free filaments into the blood. Increased levels of Cyfra 21-1 in saliva have been found in OSCC.<sup>21-23</sup>

Some of the other salivary biomarkers which are significantly altered in OSCC patients are inhibitors of apoptosis<sup>24</sup> (IAP), squamous cell carcinoma associated antigen<sup>23,25</sup> (SCC-Ag), carcino-embryonic antigen<sup>23,26</sup> (CEA), carcino-antigen (CA19-9)<sup>23,25</sup>, CA128<sup>25</sup>, serum tumor marker (CA125)<sup>23, 27</sup>, tissue polypeptide specific antigen (PPS)<sup>23,28</sup> reactive nitrogen species (RNS)<sup>29</sup>, lactate dehydrogenase (LDH)<sup>22</sup> and immunoglobulin G (IgG)<sup>22</sup>, s-Ig A<sup>18</sup>, insulin growth factor (IGF)<sup>18</sup> and defensin<sup>30</sup>.

Recently Oral fluid NanoSensor Test (OFNASET) technology developed by the UCLA research group, platform combines cutting-edge technologies, such as self-assembled monolayers (SAM), bionanotechnology, cyclic enzymatic amplification, and microfluidics, with several well-established techniques including microinjection molding, hybridization-based detection, and molecular purification. The intended use of the OFNASET is the multiplex detection of salivary biomarkers for oral cancer.<sup>31</sup>

### ► Conclusion

The field of salivary diagnostics is a broad, complex and crosscutting area of scientific research with enormous potential

to impact the diagnosis of various diseases including oral cancer. The significant increase in tumor markers in saliva is quite encouraging. Though at present no single tumor marker can validate the presence or prognosis of disease, a panel of biomarkers would be more helpful. Recent advances and emerging technologies such as nanotechnology, proteomic and genomics make salivary diagnostics a highly sensitive tool. The present methods are not ready for immediate direct use and much needs to be done to come up with a fast, simple, cost effective clinical diagnostic system. Saliva will possibly outperform other media in the diagnosis of not only cancer but other diseases as well.

### ► Bibliography

1. Myers JN, Elkins T, Roberts D, Byers RM. Squamous cell carcinoma of the tongue in young adults: increasing incidence and factors that predict treatment outcomes. *Otolaryngology--Head and Neck Surgery* 2000; 122(1):44-51.
2. Shpitzer T, Hamzany Y, Bahar G, et al. Salivary analysis of oral cancer biomarkers. *British journal of cancer* 2009; 101(7):1194-98.
3. Spielmann N, Wong DT. Saliva: diagnostics and therapeutic perspectives. *Oral diseases* 2011; 17(4):345-54.
4. Shah FD, Begum R, Vajaria BN, et al. A review on salivary genomics and proteomics biomarkers in oral cancer. *Indian Journal of Clinical Biochemistry* 2011; 26(4):326-34.
5. Baum BJ. Principles of saliva secretion. *Annals of the New York Academy of Sciences* 1993; 694(1):17-23.
6. Markopoulos AK, Michailidou EZ, Tzimagiorgis G. Salivary markers for oral cancer detection. *The open dentistry journal* 2010; 4:172.
7. Lichtenstein A, Potapova G. Genetic defects as tumor markers. *Molecular Biology* 2003; 37(2):159-69.
8. Zhang L, Rosin M. Loss of heterozygosity: a potential tool in management of oral premalignant lesions? *Journal of oral pathology & medicine* 2001; 30(9):513-20.
9. Rosin MP, Cheng X, Poh C, et al. Use of allelic loss to predict malignant risk for low-grade oral epithelial dysplasia. *Clinical Cancer Research* 2000; 6(2):357-62.
10. Tilakaratne WM. *the cancer handbook*. 2nd edition ed: United States: John Wiley and Sons Ltd; 2007; 2007.
11. Boyle JO, Hakim J, Koch W, et al. The incidence of p53 mutations increases with progression of head and neck cancer. *Cancer Research* 1993; 53(19):4477-80.
12. Ha PK, Califano JA. Promoter methylation and inactivation of tumour-suppressor genes in oral squamous-cell carcinoma. *The lancet oncology* 2006; 7(1):77-82.
13. Das BR, Nagpal JK. Understanding the biology of oral cancer. *Medical Science Monitor* 2002; 8(11):RA258-RA67.
14. Nagpal JK, Mishra R, Das BR. Activation of Stat-3 as one of the early events in tobacco chewing-mediated oral carcinogenesis. *Cancer* 2002; 94(9):2393-400.
15. Shimakage M, Horii K, Tempaku A, et al. Association of Epstein-Barr virus with oral cancers. *Human pathology* 2002; 33(6):608-14.
16. Wong DT. Salivary diagnostics powered by nanotechnologies, proteomics and genomics. *The Journal of the American Dental Association* 2006; 137(3):313-21.
17. Zimmermann BG, Wong DT. Salivary mRNA targets for cancer diagnostics. *Oral oncology* 2008; 44(5):425-29.
18. Shpitzer T, Bahar G, Feinmesser R, Nagler RM. A comprehensive salivary analysis for oral cancer diagnosis. *Journal of cancer research and clinical oncology* 2007; 133(9):613-17.
19. Pezelj-Ribaric S, Prso IB, Abram M, et al. Salivary levels of tumor necrosis factor- $\alpha$  in oral lichen planus. *Mediators of Inflammation* 2004; 13(2):131-33.
20. Moll R, Franke WW, Schiller DL, Geiger B, Krepler R. The catalog of human cytokeratins: patterns of expression in normal epithelia, tumors and cultured cells. *cell* 1982; 31(1):11-24.
21. Bhatavdekar J, Patel D, Vora H, Balar D. Circulating prolactin and TPS in monitoring the clinical course of male patients with metastatic tongue cancer: a preliminary study. *Anticancer research* 1992; 13(1):237-40.
22. Yen T, Lin W, Kao C, Cheng K, Wang S. A study of a new tumour marker, CYFRA 21-1, in squamous cell carcinoma of the head and neck, and comparison with squamous cell carcinoma antigen. *Clinical otolaryngology and allied sciences* 1998; 23(1):82-86.
23. Nagler R, Bahar G, Shpitzer T, Feinmesser R. Concomitant analysis of salivary tumor markers—a new diagnostic tool for oral cancer. *Clinical Cancer Research* 2006; 12(13):3979-84.
24. Kurokawa H, Tsuru S, Okada M, Nakamura T, Kajiyama M. Evaluation of tumor markers in patients with squamous cell carcinoma in the oral cavity. *International journal of oral and maxillofacial surgery* 1993; 22(1):35-38.
25. Hoffmann J, Munz A, Krimmel M, Alfter G. Intraoperative and postoperative kinetics of serum tumor markers in patients with oral carcinoma. *Journal of oral and maxillofacial surgery* 1998; 56(12):1390-93.
26. Krimmel M, Hoffmann J, Krimmel C, Cornelius CP, Schwenzler N. Relevance of SCC-Ag, CEA, CA 19.9 and CA 125 for diagnosis and follow-up in oral cancer. *Journal of Cranio-Maxillofacial Surgery* 1998; 26(4):243-48.
27. Kurokawa H, Yamashita Y, Tokudome S, Kajiyama M. Combination assay for tumor markers in oral squamous cell carcinoma. *Journal of oral and maxillofacial surgery* 1997; 55(9):964-66.
28. Bahar G, Feinmesser R, Shpitzer T, Popovtzer A, Nagler RM. Salivary analysis in oral cancer patients. *Cancer* 2007; 109(1):54-59.
29. Nagler RM, Barak M, Peled M, et al. Early diagnosis and treatment monitoring roles of tumor markers Cyfra 21-1 and TPS in oral squamous cell carcinoma. *Cancer* 1999; 85(5):1018-25.
30. Mizukawa N, Sugiyama K, Fukunaga J, et al. Defensin-1, a peptide detected in the saliva of oral squamous cell carcinoma patients. *Anticancer research* 1997; 18(6B):4645-49.
31. Gau V, Wong D. Oral Fluid Nanosensor Test (OFNASET) with Advanced Electrochemical-Based Molecular Analysis Platform. *Annals of the New York Academy of Sciences* 2007; 1098(1):401-10.



# Impression techniques for ocular prosthesis

\*Rohit Raghavan, \*\*Shajahan P. A., \*\*\*Ritha Bos, \*\*\*Geethprasad TS

## Abstract

Eyes are generally the first features of the face to be noted. The disfigurement caused by loss of an eye is often a psychologically damaging experience for the patient. Ocular prosthesis is an artificial replacement of the eye. To gain proper fit and intimate tissue adaptation of ocular prosthesis, an accurate impression technique is necessary. This article deals with various impression techniques used in the fabrication of acrylic resin custom ocular prostheses.

**Key Words:** Eye stock Prosthesis, Ocular impression

KDJ 2016 | Vol. 39 | No. 1 | Pg 24-26

## ► Introduction

A defects that compromise esthetics and function, and prevents one to lead a normal life, usually leads the individual to seek treatment that will reinstate acceptable normacy. Eyes are generally the first features to be noted<sup>1</sup>. The loss or absence of an eye may be due to many reasons like congenital defect, trauma, tumour, a painful blind eye, sympathetic ophthalmia or the need for histological confirmation of a suspected diagnosis<sup>2</sup>.

Replacement of the missing eye should be done as quick as possible to promote physical and psychological healing for the patient which would help to improve the social acceptance. A multidisciplinary management and team approach are essential for an

accurate and effective rehabilitation. Therefore, the combined efforts of the ophthalmologist, the plastic surgeon and the maxillofacial prosthodontist are essential to provide a satisfactory ocular prosthesis.<sup>3</sup>

## ► History

The first artificial eyes were made by Egyptians. The Babylonian and Sumerian civilizations had used “art-eyes” in statues and mummies, fabricated from precious stone, silver or gold<sup>4</sup>. Ambroise Pare (1510-1590) –describe the use of an artificial eyes in an eye socket (pioneer of modern artificial eyes)- fabricated eyes porcelain. In the beginning of the 19th century, France became the centre of artificial eye making. Boissoneau in 1849 was credited with coining the term “ocularist”, He produced stock glass eyes, which were popular in Europe and America. In 1853, Ludwig Muller Uri used a novel method (a unique method of colouring the iris) for making human glass eyes. Friedrich A. Muller is credited with developing the double wall glass prosthesis. By the end of the last century most of the ocular prosthesis was developed. II World war-Naval dental school (1943)-tested the fabrication of ocular prosthesis using acrylic resins.

## Indications for prosthetic devices

The various indications for fabrication of prosthetic devices are divided into two broad categories namely congenital and acquired deformities<sup>5</sup>.

- A. Congenital deformities
  - Anophthalmia
  - Microphthalmia
- B. Acquired deformities
  - Phthisis bulbi
  - Post-enucleation
  - Post-chemical injuries
  - Contracted socket following radiation
  - Post-orbital exenteration

## Method for the fabrication of ocular prosthesis<sup>5</sup> are

1. Examination by the ocularist
2. Taking an impression
3. Wax pattern for the socket
4. Centration of the prosthesis
5. Fabrication of iris and pupil to match the fellow eye
6. Moulding in acrylic
7. Tinting to match the scleral shade
8. Packing with the clear acrylic
9. Polishing
10. Patient education about hygiene and care of the prosthesis

Out of which the impression making is of greater importance, different technique of impression making is going to be discussed in detail.

1. The Direct Impression/External Impression
2. Impression with Stock Ocular Tray
3. Stock Ocular Tray Modifications
4. Impression with Custom Ocular Tray
5. Impression Using Stock Ocular Prosthesis

\* Head of Department, \*\* Professor, \*\*\*PG Student, Dept of Prosthodontics, Royal Dental College, Chalissery, Palakkad, Kerala Corresponding Author : Dr Ritha Bos E mail: drithabos@gmail.com



6. Ocular Prosthesis Modification
7. Wax Scleral Blank Technique

### 1 The Direct Impression/External Impression

In this technique impression materials like alginate is injected directly into the enucleated socket.<sup>3</sup> Patient is said to look straight in front as technique commences. The anatomy of the an ophthalmic socket and overlying tissues is obtained by using a rigid tray which is reinforced over the additional material applied to the external tissue. Stone model is made from the impression and a wax pattern is carved. This acts as a trial ocular prosthesis which is tried in the patient and adjusted accordingly to achieve proper tissue contours and fit. Bartlett and Moore<sup>3</sup> substantiated the necessity of an impression procedure to realize the full movement potential of a prosthesis supported by an ocular implant. By doing so voids in the socket are eliminated and possibility of debris collection is minimal. In addition, they emphasised that a wax try-in is necessary to evaluate proper physiologic function

### 2 Impression with Stock Ocular Tray

Most widely used impression technique. Here stock ocular tray is used to support the impression material<sup>6,7</sup>. Allen and Webster<sup>6</sup> called it the “modified impression method.” A thin mix of ophthalmic alginate is injected through the stock ocular tray which has a hollow stem fastened in the middle. Trays are perforated which aids in flow and retention of the alginate. A wax pattern is fabricated. This wax trial prosthesis is placed in the socket for around 10 minutes which allows the muscle accommodation. The fit of the trial prosthesis is evaluated and modified as needed.

### 3 Stock Ocular Tray Modifications

Variations of the “modified impression method” center on the fabrication or configuration of a stock ocular tray. Maloney<sup>8</sup>, in the superior edge of customized stock trays placed 3 channels to prevent air entrapment. In this method, a raised ring around the stem which would prevent the eyelid from blocking the channels.

### 4 Impression with Custom Ocular Tray

Miller<sup>9</sup> explained for patients with ophthalmic sockets which were highly irregular custom ocular trays were of greater advantage. He attached a solid suction tube to the existing prosthesis of the patient, conformer, or wax shell and invested it in an alginate mold. After the alginate sets, these were removed and replaced with clear acrylic resin. Perforations are made in the resulting tray, and a tunnel is cut into the stem and impression material can be injected through it. An impression is made using injected alginate.

### 5 Impression Using Stock Ocular Prosthesis

Stock ocular prosthesis were used as a tray to carry impression material. In this method an appropriate stock acrylic resin ocular prosthesis was selected and then was adjusted by trimming its peripheries which was later lined with a thin mix of ophthalmic alginate and definitive impression were obtained. Alternately, alginate can be injected directly into the socket and then reinforced by placement of the stock eye. A customized stock prosthesis were obtained from the proceeded impression. Limitations of this technique include the need of large supply of artificial eyes and the inability to match to the appropriate sizes and colors of the iris and pupil as required in the patient.

### 6 Ocular Prosthesis Modification

Chalian<sup>10</sup> suggested trimming and polishing a stock prosthesis will gain more acceptable fit. And also by using alginate or soft wax the stock trays can be modified, which then can be invested and processed.

Smith<sup>11</sup> suggested relining an existing prosthesis using an impression wax, Korecta-Wax No. 4. Here the existing prosthesis is trimmed peripherally and posteriorly, and modified with baseplate wax. When proper contours are achieved, a thin layer of Korecta-Wax No. 4 is added. The lined prosthesis is warmed, inserted which is left in place for 30 minutes and the patient is said to intermittently moves his or her eyes in all possible directions. A laboratory reline procedure is then accomplished.

### 7 Wax Scleral Blank Technique

The wax scleral blank was advocated as the starting point in several techniques.

Benson<sup>12</sup> created a wax pattern of half of the size of steel ball. The resultant pattern is smoothed, trial was done, and adjusted. The pattern is invested and processed with iris button attached. Chalian et al<sup>13</sup> also followed the same.

McKinstry<sup>14</sup> suggested “compression impression” technique in which he formed a wax pattern based on examination of the site. Wax pattern was tried in, modified as needed, and processed after addition of an iris. Advantage of this method is that it accurately records and form an inferior fornix if the patient’s or the fornix is shallow or lower lid is weak.

Le Grand and Hughes<sup>15</sup> in their “empirical/ impression” technique attached a “dummy” aluminium button to act as a handle. Then properly contoured wax pattern is used as a tray to carry alginate or support impression material. Hughes<sup>16</sup> subsequently suggested that a syringe to be attached to the completed wax pattern so that impression material can be injected directly through it.

Schneider duplicated the patient's conformer to obtain a wax conformer and modified it in sections, using a dental impression wax, Iowa Wax. Various ocular movements given by patient resulted in a functional impression of the socket.

Alternately Sykes in his technique used polyvinylsiloxane material on the tissue surface. The modified wax pattern is then used to fabricate the final ocular prosthesis.

► **Conclusion**

The rehabilitation of a patient who has suffered the psychologic trauma of an ocular loss requires a prosthesis that will provide the optimum cosmetic and functional result. Refinement in the details of custom ocular construction has produced a superior restoration delivered more readily. Impression making to facilitate the designing of an artificial eye is a common practice today. Numerous ocular impression methods exist.

► **Reference**

1. Doshi PJ, Aruna B. Prosthetic Management of patient with ocular defect. *J Ind Prosthodont Soc* 2005; 5: 37-38.
2. Raflo GT. Enucleation and evisceration. In: Tasmun W, Jaeger E eds. *Duane's Clinical ophthalmology*, Revised edn, Vol. 5. Philadelphia: Lippincott-Raven, 1995: 1-25.
3. Bartlett SO, Moore DJ. Ocular prosthesis: a physiologic system. *J Prosthet Dent* 1973; 29: 450-459

4. Martin O, Clodious L. The history of artificial eyes. *Ann Plastic Surg* 1979;3:168-70.
5. K. Raizada, D. Rani / *Contact Lens & Anterior Eye* 30 (2007) 152-162
6. Allen L, Webster HE: Modified impression method of artificial eye fitting. *Am J Ophthalmol* 1969;67:189-218
7. Allen L, Bulgarelli DM: Obtaining and understanding the alginate impressions. *J Am Soc Ocularists* 1988;19:4-13
8. Maloney BA: Development of impression fitting equipment: A new technique. *J Am Soc Ocularists* 1979;9:32-33
9. Miller BJ: Custom ocular impression trays. *J Facial Somato Prosthet* 1996;2:109-113
10. Chalian VA: Treating the patient with facial defects, in Laney WB (ed): *Maxillofacial Prosthetics*. Littleton, MA,2. PSG Publishing Co, 1979, p 286
11. Smith RM: Relining an ocular prosthesis: A case report. *J Prosthodont* 1995;4(3): 160-163
12. Benson P: The fitting and fabrication of a custom resin artificial eye. *J Prosthet Dent* 1977;38:532-538
13. Chalian VA, Drane JB, Metz HH, et al: Extraoral prosthetics, in Chalian VA, Drane JB, Standish SM (eds): *Maxillofacial Prosthetics: Multidisciplinary Practice*
14. Cerullo L, McKinstry RE: Ocular prostheses, in McKinstry RE (ed): *Fundamentals of Facial Prosthetics*. Arlington, VA, ABI Professional Publications, 1995, pp 107-109
15. Le Grand JA, Hughes MO: Empirical impression technique for artificial eye fitting. *Adv Ophthalmic Plast Reconstr Surg* 1990;8:118-125

# Immediate denture - an important treatment modality

\* Kalpana Hasti, \*\*Anurag Hasti, \*\*\*Rahul Sharma, \*\*\*\*Aprajita Mitra

## Abstract

An immediate complete denture is a restoration of the lost natural teeth and associated tissues which is inserted into the patients mouth immediately following the extraction of remaining teeth. The removal of all the remaining teeth and placement of the complete denture are important in patients' life. The transition from dentulism to edentulism should be psychologically atraumatic as far as possible.

The cases presented here are conventional (classic) immediate denture and interim (transitional or non transitional) immediate denture which offer good esthetic and functions.

**Key words:** conventional immediate denture, interim immediate denture.

KDJ 2016 | Vol. 39 | No. 1 | Pg 27-29

## ► Introduction

Patient increasing demand for natural appearance of the lost teeth has become a challenge to the dentist<sup>1</sup>. The placement of complete denture immediately following the removal of natural teeth is not new. Richardson (in the year 1860) emphasized on immediate denture service, saying that “the value of temporary sets of teeth to the patient on the other hand is questionable.

They fulfill in a tolerable degree all the requirements of artificial teeth under any circumstances, if we expect that the mastication, this function being more or less imperfectly performed with such pieces.” But late on in the year 1951 Sears said that “in cases where some of the natural teeth remain in place it is wise to consider the advisability of constructing dentures before the teeth are removed”<sup>2</sup>.

Dental professionals have recognized the patients wish and need to avoid an edentulous period which resulted in the fabrication of the denture that can be placed in the patients mouth immediately following the removal of last natural teeth. The success of the immediate denture depend on the correct indication and precise execution of clinical and laboratory procedure.

## ► Case report 1

A 55 year old male patient was referred to the department of Prosthodontics for oral rehabilitation. On intra-oral examination teeth present were 12, 14, 15, 21, 22, 23, 31, 32, 33, 34, 36, 37, 38, 42, 44, 46, 47 (Fig I)

Orthopantomography was advised (Fig 2). Upper and lower alginate impressions were made; study models were fabricated and articulated. All the facial measurements were recorded.

After the diagnosis of the cast, radiograph evaluation and clinical examination, a conventional immediate denture was planned. The patient was referred to the department of Oral and Maxillofacial surgery for extraction of 36, 37, 38 and 44, 46, 47 and was advised to report back after 6 – 8 weeks. When the patient reported after 6 weeks, the healing was found to be satisfactory. (Fig 3 and 4)

## ► Procedure

Upper and lower alginate impressions were made. A custom tray was fabricated for Camphagne's<sup>3</sup> impression technique. Border molding was done using green stick compound and final impression was made using Zinc Oxide Eugenol and dentulous area in Alginate as a pick-up impression material.

A master cast (Fig 5), record base and occlusal rims were fabricated. Jaw relation was recorded. 14 and 34 were used as a vertical stop. The records were transferred on to the articulator, Posterior Teeth arrangement was done and upper 12 and 22 were arranged to confirm esthetics, labial fullness, lower lip line, size and shape of teeth. Try –in was done. The cast modification was done by the technique given by Jerbi<sup>4</sup>. Flasking and curing was done followed by finishing and polishing. On the day of insertion all the remaining

\* Reader, Dept. of Prosthodontics, Jaipur Dental College; \*\*Reader, \*\*\* Senior Lecturer, \*\*\*\*P.G Student, Dept. of Prosthodontics, School of Dental Sciences, Sharda University; Corresponding Author: Dr. Kalpana Hasti Email- kalpanagupta78@yahoo.com

anterior teeth were extracted and denture insertion was done. (Fig 6,7,8)

Patient was advised to wear the denture overnight and for 3 consecutive days and recall was done after 24 hours. Patient complained of ulceration in the upper canine region and in the posterior mylohyoid region and the required trimming was done. Patient was advised to continue wearing denture and called for suture removal after a week. Patient was recalled after 6 months to check for the retention and stability of both the dentures and assessed for relining.

► **Case report 2**

A 29 years old female patient was referred to department of Prosthodontics for replacement of missing teeth. On examination, the teeth present were 13,14,15,16,23,25,26,34, 35,36,37,45,47,48. All the remaining teeth were found to be

periodontically involved with Grade II and Grade III mobility. (Fig 9 and 10)

Orthopantography (OPG) was advised. Upper and lower Alginate impressions were made and study models were evaluated. Patient was referred to department of Periodontics for opinion. The OPG revealed severe bone loss. Patient was diagnosed with aggressive periodontitis. After diagnosis, examination and OPG evaluation an interim immediate denture was planned. The custom tray is fabricated.

Border molding is done using low fusing impression compound and final impression was made with medium body rubber base impression material.(Fig 11) On the master cast record base was fabricated and only anterior try-in was done. The casts were articulated in the normal occlusion of the patient. Posterior arrangement was done and the cast modification was done by the technique given by Jerbi<sup>4</sup>.

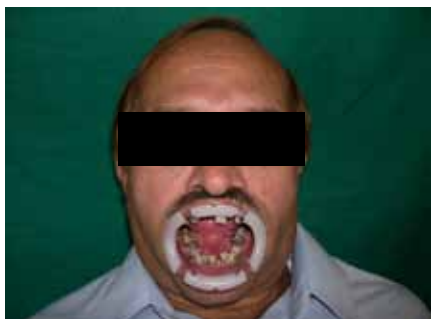


Fig. 1: Pre operative

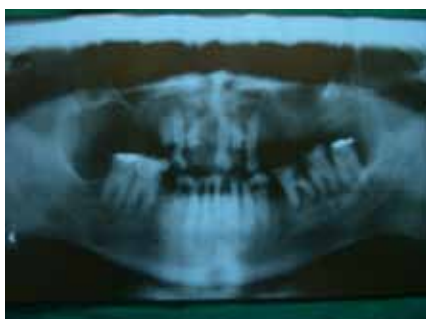


Fig. 2: Diagnostic OPG

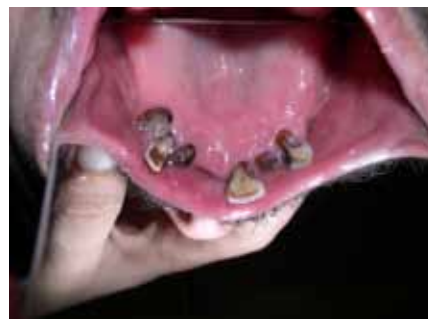

Fig. 3: Maxillary arch post extraction

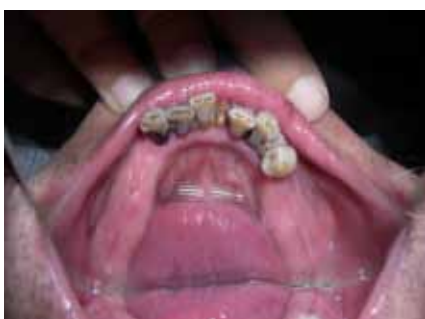

Fig. 4: Mandibular arch post extraction

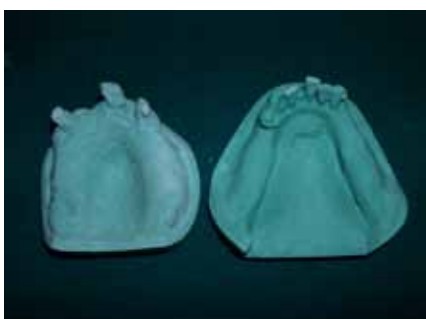

Fig. 5: Master cast

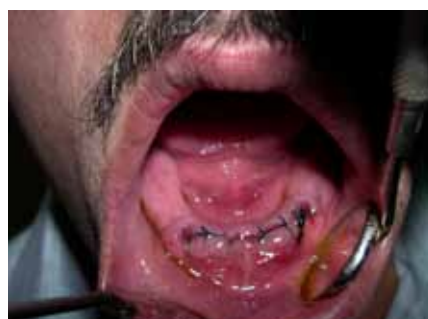

Fig. 6: Completely extracted mandibular arch

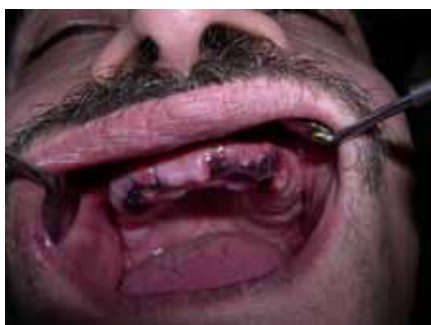

Fig. 7: Completely extracted maxillary arch




Fig. 8: Post operative

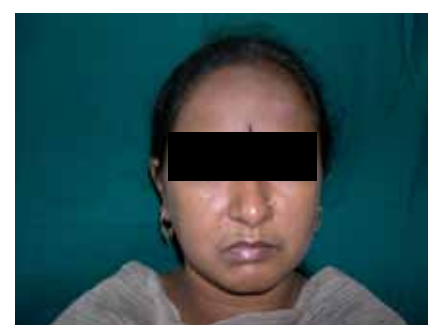

Fig. 9: Pre operative



Flasking and curing was done followed by finishing and polishing. On the day of insertion all teeth were extracted and denture insertion was done. Patient was advised to wear the denture overnight and for 3 consecutive days and recall was done after 24 hours (Fig 12,13,14,15). Patient was advised to continue wearing denture and called for suture removal after a week. Patient was recalled after 6 months to check for the retention and stability of both the dentures and assessed for relining.

► **Discussion**

When removal of teeth becomes necessary an immediate denture is an important treatment modality. There are many advantages of immediate dentures as it acts as a matrix which controls hemorrhage, prevents contamination and provide protective covering over the wounds.

It provides restoration of phonetics and masticatory functions and facilitates transition of the edentulous state<sup>5</sup> It enables the patient to continue to engage in social and business activities without an embarrassing period of staying edentulous<sup>6</sup>. As in the case of conventional immediate dentures there are many advantages of CID than IID. The use of transitional partial denture to replace posterior teeth prior to the removal of the anterior teeth is highly recommended. As discussed in interim immediate complete denture case report, successful treatment of aggressive periodontitis depends a lot

in early diagnosis of the disease. When diagnosed in late stage the treatment option is extraction. A young female patient suffering from aggressive periodontitis and loss of all her teeth has a devastating effect on functionally, and psychologically so a fabrication of IID is useful method.

► **Conclusion**

In the era of implant and immediate implant treatment, immediate complete denture treatment should still be considered as an important treatment modality. A detailed extraoral and intraoral evaluation and correct treatment planning will lead to a successful replacement of missing structures with immediate dentures which is functionally acceptable to the patient.

► **Reference**

1. Puthanakar N.Y, Pappachan B, Patil A.G. Full mouth rehabilitation by immediate denture prosthesis- A case report. *Annals and Essences of Dentistry*.2012;4(4):28-33.
2. Goswami R, Singh M. Immediate denture- a spatial modeling way. *Guident*. Sept 2012;42-44.
3. Campagna S.J. An impression technique for immediate dentures. *J Prosthet Dent*. 1968;20: 196-203. 3
4. Jerbi.F.C Trimming the cast in the construction of immediate denture *J Prosthet Dent* 16:1047-1053, 1966.
5. Wiebelt F.J. Two steps better immediate dentures. *Quitessence Int*. 1980;5:27-30.
6. Gilboa I, Cardash H.S. An alternative approach to immediate overdentures. *J Prosthodont*.2009;18;71-75.

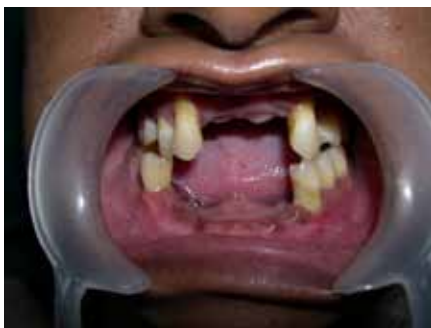

Fig. 10: Pre operative intraoral

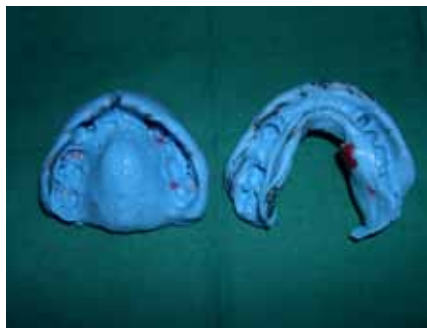


Fig. 11: Final impression

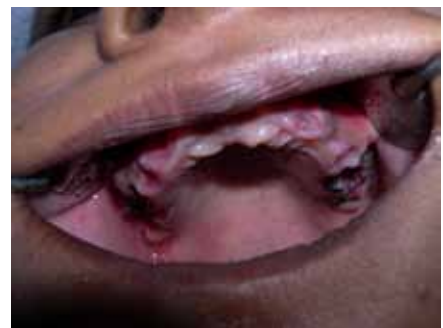

Fig. 12: Post extraction maxillary arch

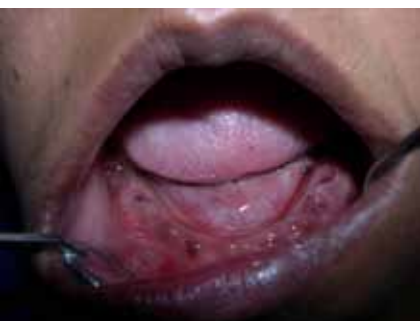

Fig. 13: Post extraction mandibular arch

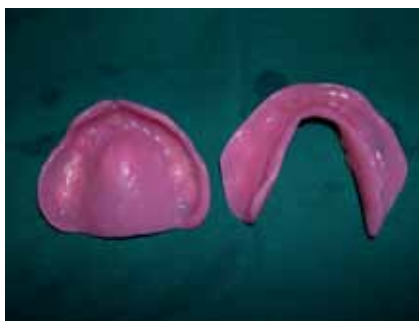

Fig. 14: Processed denture

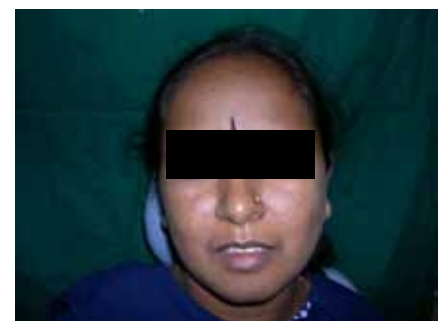

Fig. 15: Post operative



# Biological restorations in children

\* Seena John, \*\* Faizal C. Peedikayil, \*\*\* Vimal Remy

## Abstract

An increasing demand for esthetics has led to new innovations and techniques in dental restorations in anterior teeth. Tooth structure may be used as an alternative to restore fractured segments, grossly carious teeth etc. The tooth fragments can be obtained from patients own tooth or from tooth bank. The restorations using these teeth are termed as biological restoration. This article discusses the different aspects of biological restorations.

**Key words:** Biological Restorations, Tooth Fragment, Paediatric Dentistry.

KDJ 2016 | Vol. 39 | No. 1 | Pg 30-32

## ► Introduction

Fractured tooth crowns, Primary teeth with extensive carious lesions are routinely observed in clinical practice. Tooth material loss at an early age may not only lead to establishment of neuromuscular imbalance leading to decreased masticatory efficacy but also phonetic and esthetic problems, development of parafunctional, psychological problems.<sup>1</sup> To restore them is thus a challenge for the clinician. Diverse treatment options are available today like, composite restorations stainless steel crowns, cheng crowns, dura crowns, strip crowns, glastech crowns, pedo jacket crowns etc. Out of the various treatment options available to rehabilitate severely destroyed tooth crowns, conservatively and biologically, several authors have suggested the use of tooth structure as a restorative material.<sup>1,2</sup> The term biologic restoration was introduced by Santos

and Bianchi in 1991. It is defined as an “alternative technique that uses adhesive capabilities of materials in combination with strategic placement of parts of human extracted teeth”<sup>2,3</sup>.

The technique of bonding tooth fragments was first proposed to repair permanent teeth with the patient’s own fractured crown. However, it also has been performed to restore crowns severely destroyed by carious disease, using fragments from another patient. Moreover, extracted permanent teeth have also been employed in removable and fixed prostheses. Natural crowns and roots, obtained from a tooth bank, have been used for several clinical and laboratory procedures.<sup>4</sup>

Although the technique is simple, it requires the professional ability to prepare and adapt the natural crowns and intra canal posts. Parents must be informed of, accept, and consent to the use of teeth from a tooth bank. Teeth from a trustworthy tooth bank must be available.

## Fragment reattachment

Traumatic injuries most commonly affect maxillary incisors. The most common teeth effected are central incisors and lateral incisors due to their anterior position and protrusion caused by the eruptive process. Reattachment of a tooth fragment should be preferable for restoring fractured teeth. There are several advantages in this treatment such as obtaining aesthetic in a single appointment, being a more conservative

procedure, obtaining healthy periodontal attachment and maintenance of the original tooth contours and translucence. The reattachment technique was first described in 1964 by Chosak and Eidelaman. At that time, it was considered as a provisional restoration due to the low bond strength values achieved by the adhesive systems. However, the remarkable advancement of the adhesive systems and resin composites has made there attachment of tooth fragments a procedure that is no longer a provisional restoration, but rather a treatment offering favourable prognosis.(Fig. 1) This procedure found a strong argument in a conservative philosophy, since it does not require excessive wear of the healthy tooth structure and do not make unfeasible any other later possible restorative treatment 4 - 6. J. O. Andreasen<sup>7</sup> states that the tooth reattachment procedure may importantly serve as a transitional treatment alternative for pre-teens or teenage patients to postpone definitive treatment until an age where gingival margin contours are relatively stable. Patients should be appraised of the advantages and disadvantages and should make an informed decision based on the dentist’s recommended treatment

Current adhesive agents provide sufficient bonding strengths to withstand the slow loading from masticatory stresses eventhough this bonded interface is undeniably susceptible to the effects of cyclic fatigue and hydrolytic degradation over time. However, it

\*PG Student, \*\* Professor & HOD, Department of Pedodontics and Preventive Dentistry, \*\*\* Senior Lecturer, Dept of Endodontics, Kannur Dental College, Kannur, Kerala State, India Corresponding author: Dr. Faizal C. Peedikayil, Email drfaizalcp@gmail.com

appears that improvements in the luting and/or bonding systems employed and a greater knowledge of the factors influencing restoration longevity should serve to enhance the potential for success of reattachment techniques in the future.<sup>8</sup>

### Biological crowns

The use of extracted teeth as biological restoration constitutes a viable restorative alternative for teeth with extensive coronal destruction. This technique is simple, provides excellent esthetics as well as preserves natural tooth colour compared to composite resins and stainless steel crowns, allows the preservation of sound tooth structure and has low cost. The enamel of the biologically restored tooth has physiologic wear and offers superficial smoothness and cervical adaptation compatible with those of surrounding teeth. Biological restorations not only mimic the missing part of the oral structures, but are also biofunctional.<sup>5,6</sup>

The length of each appointment is reduced because natural teeth are prepared previously. Clinical chair time for fragment bonding procedures is relatively short, which is a merit especially while dealing with paediatric patients. Resin composite restorations do not present these advantages and can allow staining and plaque formation on their surfaces.<sup>2,3</sup>

Disadvantages of the biological crown restoration technique include the difficulty in obtaining teeth with the required coronal dimensions and characteristics, problems inherent to indirect restorations and matching fragment colour with tooth remnant colour. Also, having teeth from other people's teeth in their mouth is not a pleasant idea for some patients and many of them refuse to receive this treatment. However, all these factors are not contraindications of the technique.<sup>2,3,6,8</sup>

Biological restoration used teeth from the Human Tooth Bank are used as natural posts & crowns.<sup>2,7</sup> The selected tooth from the tooth bank is reshaped, roots strengthened by retro filling with flowable composites and autoclaved for 30min at 121 degree centigrade and 15 lbs pressure before cementation.<sup>9</sup>

Other factors of concern while using biologic restoration is that Universal protocol of consent, storage and sterilization

should be followed in the human tooth bank. Collected samples should be scaled, polished and freed of soft tissues and periodontal remnants. Pulpas have to be removed and complete biological preparation is to be done. Teeth are then stored at 4 degree centigrade in HBSS with donor identification till the time of its use.<sup>9,10</sup>

It is important that the parents are informed that the tooth fragments used for biological restoration are previously submitted to a rigorous sterilization process that completely eliminates any risk of contamination or disease transmission to the child receiving the fragment. Presently, secure methods of sterilization and storage are available to ensure the safety of teeth or tooth fragments coming from tooth banks. Several materials have been used for bonding dental fragments to cavities, e.g., adhesive systems, composite resins, glass ionomer cements and dual-cure resin cements. Since the Tooth fragment which was taken was large, it was concerned that optimal light-curing would not be achieved at the cavity gingival margin. Thus, dual-cure resin-based cement was used to enhance polymerization at this region in addition to filling any possible gaps existing at tooth/fragment interface with composite resin only.<sup>3,4,5</sup>

Biological restoration technique using tooth fragments has a practical clinical applicability and is a viable, cost-effective restorative procedure for primary teeth with severely damaged crowns. In the present case, the use of biological restoration with natural crown resulted in clinical success as well as recovered the proper functional anatomy of the tooth. Finally the choice of restorative technique depends upon the operator preferences, esthetic demands by the parents and child's behavior that affect the ultimate outcome of whichever restorative material chosen.

### ► Conclusion

The constant evolution of Restorative Odontology is creating a new sight. In this short review represents the functional recuperation of a tooth, through the use of a endogenous dental fragment, a technique known as Biological

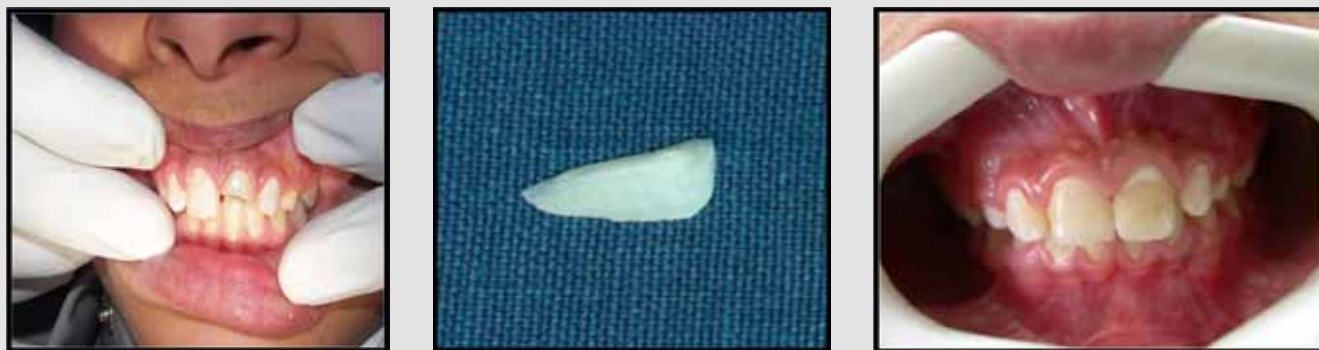

Fig. 1: Tooth fragment reattachment

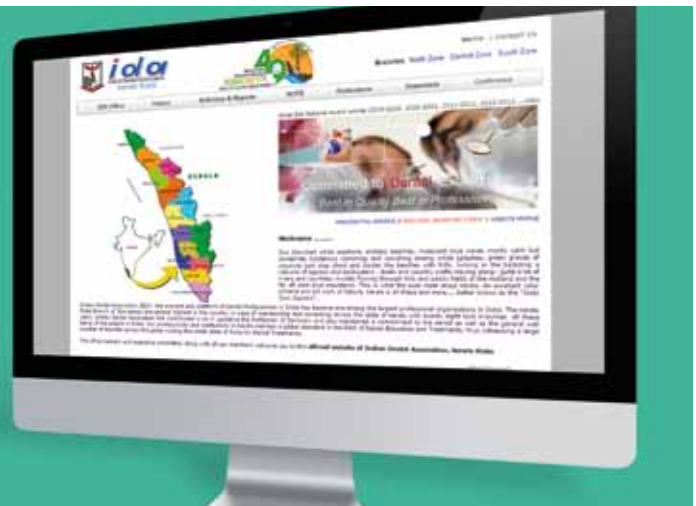restoration. With highly satisfactory results obtained in many case reports, we conclude that this technique can be considered as alternative to all others and can be carried out quickly and inexpensively.

► **References**

1. Mathur S, Rahul C, Pandit I K, Srivastava N, Gugnani N. Biological Restoration of a Grossly Decayed Deciduous Mandibular Molar. *Journal of Clinical and Diagnostic Research*. 2012 February;6(1): 139-141.
2. Sanches K, CarvalFabrício K D, FilhPaulo N,Sada A F,WanderleyGarcia De Paula E S,Alexandra, Mussolino D Q. Biological Restorations As A Treatment Optionfor Primary Molars With Extensive Coronal destruction - Report Of Two Casesbraz Dent J (2007) 18(3): 248-252.
3. Das U K, Maiti N. Nature's Own Alternative – Restoration With Biological Crowns. *International Journal Of Pediatric Dentistry*.2014april-June;3(2):144-149.
4. Saha R, Malik P. Paediatric aesthetic dentistry: a review. *European Journal of Paediatric Dentistry*.2012; vol. 13(1):6-12.
5. Am Botelho, Kta T, Correa-Faria P1, Lns M,Viana M. Esthetic–Functional Recovery Of Permanent Posterior Tooth Using Prima Autogenous Biologica Irestoration *Journal Of Indian Society Of Pedodontics And Preventive Dentistry*. 2012 Oct - Dec; 4(30):333-336.
6. Grewal N, Reeshu S. Case Report Biological restoration: An alternative Esthetic Treatment For Restoration Of Severly Multilated Primary Anterior Teeth *International Journal Of Clinical Pediatric Dentistry* 2008.;1(1):42-47.
7. Textbook and Color Atlas of Traumatic Injuries to the Teeth, 4th Edition, Jens O. Andreasen, FrancesM. Andreasen Lars Andersson, July 2007, Wiley-Blackwell
8. Attila IO, Cenk MHA, Serdar MT. Multidisciplinary approach to the rehabilitation of a crown –root fracture for immediate esthetics. *Dent traumatol*. 2006;22(1):48-52.).
9. Habiltz S, et al. Nanoindentation and storage of teeth. *J Biomech* 2002; 35(7):995 98.
10. Imparato JCP. Bank human teeth. Curitiba: Publisher May, 2003.

The Largest  
Dental Portal of Kerala

Log on  
[www.idakerala.com](http://www.idakerala.com)  
for IDA Activities, Reports,  
Publication etc...



# Recording sublingual crescent region for improving stability and retention in mandibular dentures

\* Thomas Paul, \*\* Byju Paul Kurian, \*\*\* Parvathy Raj, \*\*\* Prisly Thomas,

## Abstract

Achieving retention and stability in mandibular complete denture has always been challenging to the novice and the experienced dentists throughout the world. When it comes to treating a complete denture patient we are ought to treat the particular patient and not an average patient. Various techniques and modifications available can hence be duly chosen and customized for fabrication of satisfactory dentures in compromised conditions. One such technique includes the utilization of sublingual crescent region through a slight modification of the conventional impression technique that has been described in the current article.

KDJ 2016 | Vol. 39 | No. 1 | Pg 33-36

## ► Introduction

In complete denture prosthodontics achieving retention and stability for mandibular dentures have been an inscrutable dilemma in the bygone years. The art of impression making becomes beautiful only if it achieves the core principles underlying. Creation of such beautiful masterworks call for appropriate knowledge of the oral anatomy, knowledge of a basic and reliable technique, understanding of the materials and skill of the dentist.

Retention of a denture is the resistance to removal in a direction opposite to that of its insertion while stability is the resistance to horizontal movements. Both these factors are strongly related that without the one the other doesn't exist and is achieved by registering exact tissue details under

minimal pressure. Appropriate retention aids the denture to resist the forces of gravity, adhesiveness of foods and the forces associated with the opening of the jaws. Among the factors of retention the most important is the accomplishment of an appropriate peripheral seal which is the positive contact of the entire perimeter of the denture base to the resilient tissues that outline the basal seat. The correct position for the mandibular denture border is easily determined in the labial, buccal, and posterior regions, but the exact placement of the denture border in the anterior lingual region has always been a factor of uncertainty.

Tilton stated that "border molding ends at a point where the border tissues seat firmly, but lightly against the denture periphery when the border tissues are in extreme function"<sup>1</sup>. Accurate border molding within physiologic boundaries accomplishes the most desirable border sea<sup>1,2,3</sup>. The purpose of this article is to illustrate how the anterior lingual seal can be established during the impression making phase by utilizing the sublingual space for a retentive, stable mandibular denture.

## Definitions

The term "sublingual" pertains to the region or structures located beneath the tongue.

The "sublingual crescent extension" refers to the mandibular denture flange that covers the anterior region of the

floor of the mouth. It starts at the crest of the alveolar ridge and ends at the soft tissue displacement tissue at the base of the tongue not supported by bone.

The region covered by the sublingual flange of a mandibular denture have been given different terminologies namely lingual vestibule<sup>4</sup>, lower denture space<sup>5</sup>, anterior lingual region<sup>6</sup>, sublingual cells<sup>7</sup>, sublingual region<sup>8</sup> and sublingual space<sup>9,10</sup>.

The Glossary of Prosthodontic Terms (8th edition 2005) differentiates between the sublingual crescent area, sublingual fold and sublingual fossa<sup>11</sup>. It defines them as follows:

**Sublingual crescent:** The crescent-shaped area on the anterior floor of the mouth formed by the lingual wall of the mandible and the adjacent sublingual fold. It is the region of the anterior alveolingual sulcus.

**Sublingual fold:** The crescent-shaped area on the floor of the mouth following the inner wall of the mandible and tapering toward the molar regions. It is formed by the sublingual gland and submaxillary duct.

**Sublingual fossa:** A smooth depression on the lingual surface of the body of the mandible near the midline, and above the mylohyoid line and below the alveolus. This fossa accommodates part of the sublingual gland.

## Anatomy

The sublingual region is bordered

\* Professor, \*\* Professor and Head, \*\*\* Post Graduate Student, Department of Prosthodontics, Annoor Dental College, Muvattupuzha, Ernakulam - 686673. Corresponding Author: Dr. Parvathy Raj, E-mail: drparvathysree@gmail.com



medially by the base of the tongue and laterally by the mandible. The muscle and mucous membrane that form the floor of the mouth are separated from each other by loose connective tissue containing glandular elements.

Genioglossus is the most superiorly placed muscle in the sublingual region. It is a fan shaped muscle with its group of fibers attached anteriorly to the superior genial tubercle and runs posteriorly to be attached into and become part of the tongue<sup>6</sup>.

The anterior group of fibres are attached just below the upper surface of the tongue at the junction of its anterior third with the middle third. The posterior group of fibers protrudes the tongue by pulling on its posterior part and thus moving the entire structure forward. The fibers of the anterior group are relaxed during this process, and they, together with the surrounding tissues, are moved forward passively under the influence of pressure from the more posteriorly placed group of fibers. Contraction of the superiorly placed anterior group of fibers of the genioglossus muscle depresses that part of the surface of the tongue which is a short distance posterior to the tip. This produces a marked concavity of that surface and tends to retract the tip of the tongue, causing it to move upward and backward. This movement occurs during the formation of the bolus and in the first stage of swallowing and actively raises the floor of the mouth to its highest level. During these functions, the fibers of the anterior group are contracted strongly and, being superficially placed in the floor of the mouth, exert a strong pressure through the overlying mucosa against a denture base which might be obstructing its movement<sup>6</sup>.

The mylohyoid muscle is located inferiorly and serves as the floor of the mouth. This muscle arises from the inner surface of the mandible whereas its posterior fibres originate from the alveolus at the level of the third molar. The mylohyoid muscle deepens anteriorly, forming a sublingual cell composed of the genioglossus muscle arising from the upper genial tubercle.

### Sublingual folds

Two folds in the mucosa overlying the genioglossus muscle run obliquely forward and inward at a varying distance from the alveolar ridge and nearly meet in the midline. These are the left and right sublingual folds which carry the ducts of the corresponding submandibular salivary glands in their free borders. At the midline a strong fibrous tendon originates from the ventral surface of the tongue and extends toward the alveolingual sulcus. This is the lingual frenum. It contains two sublingual caruncles (openings) of Wharton's duct located on either side of the midline.

Some sublingual folds are quite small and others much larger. When the tip of the tongue is raised, the sublingual folds are also raised and are pulled away from the alveolar ridge. When the tongue is relaxed and its tip is allowed to rest in contact with the lingual surfaces of the lower anterior teeth, the sublingual folds also move downward and forward nearer to the alveolar ridge and the denture border.

The sublingual gland along with hypoglossal nerve, lingual nerve, lingual vein, and lingual artery are contained in the sublingual region.

Each patient requires an individual evaluation to identify the various characteristics of the floor of the mouth. It is

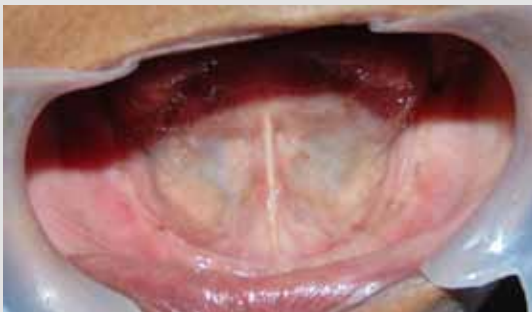

Fig. 1

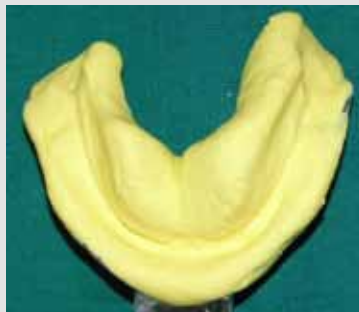

Fig. 2 & 3

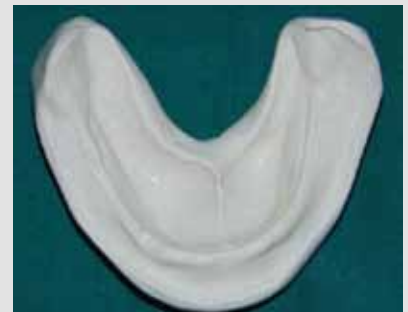

Fig. 4



Fig. 5



Fig. 6

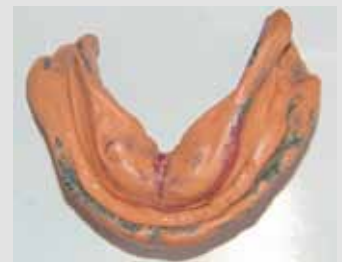

Fig. 7

hence expected that one must treat the particular patient and not the average patient.

Fournet classified the floor of the mouth into four types as follows<sup>12</sup>:

1. A high floor of the mouth with no sublingual fold or space. The acrylic resin special tray should be shortened lingually until it does not touch the sublingual gland.
2. A clearly defined space for the sublingual fold and gland. The custom tray is trimmed and shortened carefully in the sublingual region with the tongue just touching the handle of the tray without dislodging it.
3. A sublingual gland at a higher level than the level of the alveolar ridge. In this situation the tray should be trimmed short so as not to impinge on the gland or occlude the orifices.
4. A sublingual gland that is nearly at the same level of the ridge. When this occurs, the lingual flange of the tray is relieved over the genial tubercles.

#### ► Case report

A 54 year old female patient reported to the Department of Prosthodontics, Anoor Dental College with a chief complaint of ill fitting lower denture since 1 year. The intra oral examination revealed completely edentulous maxillary and mandibular arch with moderate resorption in lower anterior region (Atwood's Order V) (fig. 1). The floor of the mouth may be considered as Fournet's type 2 with clearly defined sublingual space on either side of the lingual frenum. The treatment plan was modified to give a mandibular complete denture with sublingual crescent extension opposing a conventional maxillary denture.

#### ► Procedure<sup>13</sup>

1. Preliminary impression is made with alginate in a perforated edentulous stock tray to facilitate better recording of the resorbed residual ridges. (Fig 2,3)
2. Acrylic special tray is made with spacer from the primary cast. Spacer may be avoided in severely resorbed ridge cases because adapting a wax spacer may not be feasible in such conditions.
3. The special tray borders are checked for over extensions by assessing displacement due to lip, cheek or tongue movements.
4. Border moulding with low fusing compound is first done in the mylohyoid, retromylohyoid and the distal extensions of the tray; initiated from one side followed by the other side. This improves the stability of the tray. The labial and buccal areas are then border moulded. The thickness of these borders recorded within functional limits enhance the peripheral seal. (Fig3,4)
5. Any extension of low fusing compound into the pre-mylohyoid area is then removed.

6. Sublingual crescent recording is then initiated with impression compound which is tempered using water bath at 1400 F (600 C) and luted on to the border of a custom acrylic resin tray that is trimmed 2 mm short of the floor of the mouth from pre-mylohyoid area from one side to the other, finally spanning the entire anterior lingual area of the tray with the impression compound. Mold it into a shelf extending downward and backward over the crescent region. Impression compound is softened carefully over a dry flame taking care not to burn out the material. The special tray is placed in the mouth and the patient is then instructed to gently place the tongue against the lingual side of the tray handle. (Fig 5)
7. The tray is removed from the mouth and cooled in cold water. If the extension of the sublingual crescent is inadequate, more material is added and the procedure is repeated. Properly recorded sublingual crescent bulges upward from the tray borders more than a normal border moulded border. It is approximately crescent or half spindle-shaped extending to either sides of the midline.
8. The impression compound is then relieved in the frenal notch area to expose the openings of the sublingual ducts. If this is not done, collection of saliva and pain occurs due to the obstruction of the sublingual gland duct openings.
9. The sublingual crescent border of the tray contacting the ventral side of tongue is examined and its borders are trimmed to remove any overextension beyond the posterior border of the sublingual fold. The light pink color of the sublingual fold than the darker pink ventral surface of the tongue acts as a guide.
10. The added sublingual extension now maintains contact with the sublingual fold when the tongue touches the lower lip. It also maintains contact with the floor of the mouth when the tongue is in a retracted position, thereby developing a good peripheral seal in both tongue positions.
11. The wax spacer is removed from the border moulded special tray to provide room for the final impression material.
12. The secondary impression is then made in zinc oxide eugenol impression paste with the lip and cheek movement as usual and protruded and retracted tongue positions.
13. The cast is poured to get the master cast, with the additional positive replica of the sublingual crescent.

Further alterations in methods in a sublingual recorded lower denture include the following<sup>15</sup>:

- a. Adequate quantity of heat-cure acrylic resin should be used during packing procedures to compensate for the reduced ridge height and also the additional sublingual crescent area. Excess flash during trial closure of flask should be assured.
- b. Long curing cycle is preferred for polymerization of the denture to prevent porosities in the thick areas.

### ► Discussion

Many methods of developing lingual borders have resulted in satisfactory dentures. Different designs of the lingual flange can be developed because of the anatomic and functional variation in patients.

Pendleton<sup>14</sup> has stated, “There appears to be one method and adequately this method is applied by permitting the tissues to establish their own associations by forming the impression material to their own individual functional requirements.” Other authors preferred a dynamic impression to be made of the lingual borders and found that the use of tissue-conditioning impression material had the added benefit of improving the oral mucosa. Lawson<sup>6</sup> suggested that thickening the sublingual region of the denture could result in more retention, especially when the tongue is relaxed and seal is not broken. Some authors suggested that where marked residual ridge resorption occurs, it may be desirable to use the tongue and the buccinators muscle to fix the denture in place by the appropriate designing of the width and form of the flanges. Brill et al<sup>5</sup> reported that thinning the denture flanges would increase the retentive forces by the muscle fixation if the patient has an adequate ridge. On the other hand, Lott and Levin demonstrated the clinical advantages of thicker borders.

Each patient requires an individual evaluation to identify differences in anatomy. In view of these anatomical differences definite guidelines should be formulated for each patient regarding the impression techniques and extension objectives. For example, the use of a dynamic impression material may be beneficial in the markedly resorbed ridge. Molding a thick border and wide sublingual region often helps to achieve a better seal because it aids continuity with the floor of the mouth. The border contours should be rounded, according to Slack<sup>15</sup> to minimize trauma resulting in sore spots on the mucosa. However, some authors suggested that thinner flanges enhance retention.

### ► Conclusion

The dental literature offers a variety of terms to describe the sublingual region. The “anterior lingual seal region” and “sublingual crescent region” are appropriate terms because they describe the location and function of the lingual flange of the mandibular denture. Variations in shape and anatomy dictate the use of different impression techniques and modifications in flange design to make a clinically successful mandibular denture.

Recording sublingual crescents during impression making in severely resorbed mandibular ridges, combined with setting the lower posterior teeth with flattened cusps in the center of the posterior ridge in the denture and contouring of the lingual, buccal and labial flanges of the denture base (Fisch concept) provides sufficient retention and stability for the dentures made on these ridges.

The tongue movements may be limited slightly due to the presence of sublingual crescents which the patient gets adapted, if extensions are proper. The patient can also perform functional movements of the tongue sufficiently without dislodging the denture. Overextended sublingual extensions will diminish the mandibular denture retention. Slight limitation of the tongue movement is an added benefit to maintain retention and stability in severely resorbed ridges.

### ► References

1. Tilton GE. Denture periphery. *J Prosthet Dent* 1952;2:290-306.
2. Tench RW. Impressions for dentures. *J Am Dent Assoc* 1934;21:1005-18
3. Fournet SC, Tuller CS. A revolutionary mechanical principle utilized to produce full lower dentures surpassing in stability the best modern upper dentures. *J Am Dent Assoc* 1936;23:1028-30.
4. Edwards LF, Boucher CO. Anatomy of the mouth in relation to complete dentures. *J Am Dent Assoc* 1942;29:331-45.
5. Brill N, Trycle G, Cantor R. The dynamic nature of the lower denture space. *J Prosthet Dent* 1965;15:401-18.
6. Lawson AW. Influence of the sublingual fold on retention of complete lower dentures. *J Prosthet Dent* 1961;11:1038-44.
7. Bocage M, Lehrhaupt J. Lingual flange design in complete dentures. *J Prosthet Dent* 1977;37:499-506.
8. Rouviere H. *Anatomia humana. Description and topografica.* Madrid: Bailey-Bailer, S.A., 1961.
9. Lewis ET. Repositioning of the sublingual fold for complete dentures. *J Prosthet Dent* 1958;8:22-5.
10. Lewis ET. The genial tubercle space in full lower dentures. *J Prosthet Dent* 1954;4:606-10.
11. Glossary of prosthodontic terms. 8th ed. 2005:94:1.
12. Fournet SC. Stabilization of lower dentures. *J Dent Surv* 63;35-41.
13. Gafoor MAA, Kumar VVH, Sheejith M, Swapna C. Recording ‘Sublingual Crescents’ in Lower Complete Dentures: A Technique so Effective but still Esoteric and Arcane. *J Contemp Dent Pract* 2012;13(2):222-226
14. Pendleton EC. *American textbook of prosthetic dentistry.* 7th ed. Philadelphia:Lea & Febiger Publ, 1942:121.
15. Slack FA. Positive retention in lower dentures. *Bull Phila Count Dent Soc* 1949;14:2-7.



JOIN

**IDA-HOPE (Help Offered to Professionals in Emergencies).**  
Members are requested to contact their respective IDA local branch  
HOPE representative to receive original application forms

# Rehabilitation of an edentulous geriatric patient with resorbed residual ridges and excessive interarch space using a maxillary hollow complete denture

\* Ashwin Kumar S G., \*\* R. Ravichandran, \*\* S. Lylajam, \*\*\* K. Harshakumar

## Abstract

Severely atrophic ridges cause decrease in retention, support and stability thus leading to a clinical challenge to the success of complete denture. It is the dentist's responsibility to fabricate prosthesis with good stability retention and support which ultimately provide satisfactory functional and aesthetic acceptance to the patient. In special situations such as patients with broad upper lip, severely resorbed ridge with increased inter arch distance, the weight of a maxillary denture often causes dislodgment hence, a light weight denture is preferred for better retention.

Different approaches like using a solid 3-dimensional spacer including dental stone, cellophane wrapped asbestos, silicone putty or modeling clay have been used during laboratory processing to exclude denture base material from the planned hollow cavity of the prosthesis.

KDJ 2016 | Vol. 39 | No. 1 | Pg 37-39

## ► Introduction

Fabrication of a complete denture as a treatment modality can pose a daunting clinical challenge in case of severe resorption of maxilla. This may be due to narrower and constricted residual ridge formed owing to resorption process, resulting in a large restorative space between the maxillary

residual ridge and opposing mandibular teeth. As a result, maxillary complete denture will develop a substantial increase in weight leading to decreased retention and stability of the prosthesis. Literature suggests various methods for weight reduction such as using a solid 3-dimensional spacer, including dental stone, cellophane wrapped asbestos, silicone putty, or modeling clay during laboratory processing to exclude denture base material from the planned hollow cavity of the prosthesis<sup>1-3</sup>. This article describes a technique of fabricating a hollow maxillary complete denture using silicone putty as well as a mixture of dental plaster and pumice (1:1 by weight) to develop a cavity within the denture base<sup>3-5</sup>.

## ► Case report

A 73-year-old male patient reported to the Department of Prosthodontics with the chief complaint of difficulty in chewing and broken upper denture causing loss of retention. History revealed that the patient was a denture wearer for the past 17 years. Upon preliminary intra oral examination, it was found out that maxillary ridge was severely resorbed. The upper lip was long and the inter-ridge distance was

exceedingly more than the normal limits. The patient had no relevant medical history. The final treatment plan decided was to fabricate a new set of complete denture for the patient with a hollow maxillary and a conventional mandibular denture.

## ► Technique

1. Make a definitive impression of the maxillary residual ridge and fabricate the denture to the trial denture stage in a conventional manner. (Fig 1)
2. Process the trial denture using standard technique till the wax elimination stage. (Fig 2)
3. Process a shim of indexed acrylic resin over the residual ridge. Adapt thin layer of baseplate wax to the intaglio surface of the teeth, conforming to the border extensions. (Fig 3.) Reset the original cope on the drag and verify complete closure of the flask. Use the second flask to invest the baseplate wax and pack the second drag with heat-polymerized acrylic resin and process.
4. Mix and adapt vinyl polysiloxane putty over the permanent denture

\* PG student, \*\* Professor, \*\*\* Professor and Head, Department of Prosthodontics, Govt. Dental College, Trivandrum. Corresponding Author: Dr. Ashwin Kumar S G, E- mail: ashwinsg27@gmail.com



- base and the counterpart with acrylic shim was seated over it. Wait for the vinyl polysiloxane putty to set. (Fig 4)
5. Vinyl polysiloxane putty was removed from the alveolar ridge area. (Fig 5) Dental plaster-pumice mixture was placed onto the acrylic shim area. Both the counterparts of the flask were closed and waited for the mixture to set. (Fig 6)
  6. Reopen the flask and remove the remaining putty material from the borders and cameo surface of the permanent denture base.
  7. Thin mix heat cured acrylic resin material was injected on to the sides of the acrylic shim. The counterpart with permanent base was seated over the acrylic shim portion and processed.



Fig. 1 Trial Denture.

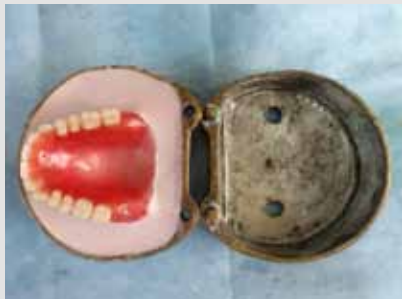

Fig. 2 Invested Maxillary Trial Denture.

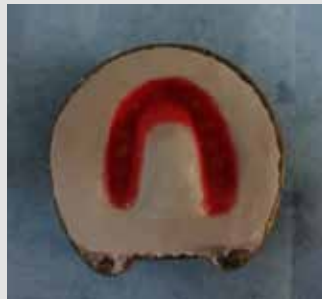

Fig. 3 Wax Shim over the dewaxed denture.

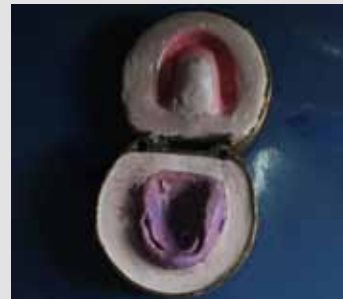

Fig. 4 Adapting putty material onto the record base.

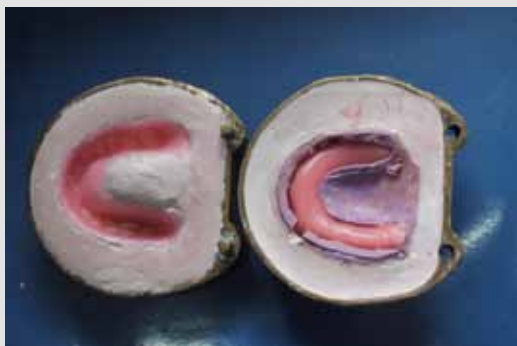

Fig. 5 Removed putty material from record base.



Fig. 6 Packing pumice plaster mixture over the wax shim.

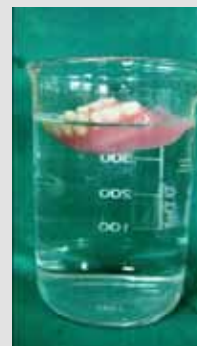

Fig. 7 Floating Hollow complete denture.

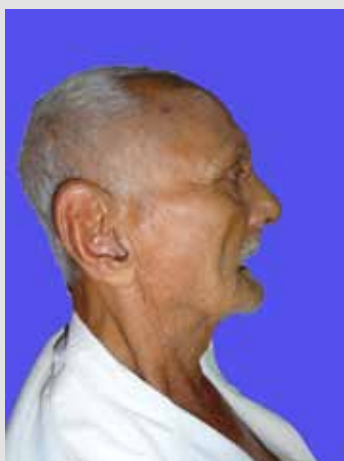

Fig. 8 Pre operative lateral view.

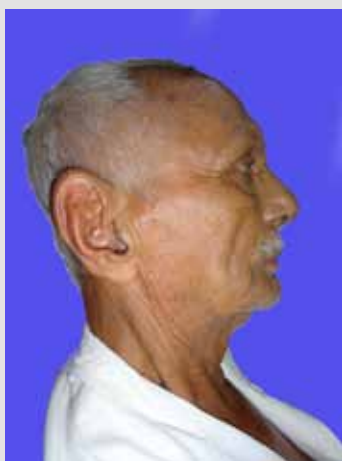

Fig. 9 Post operative lateral view.

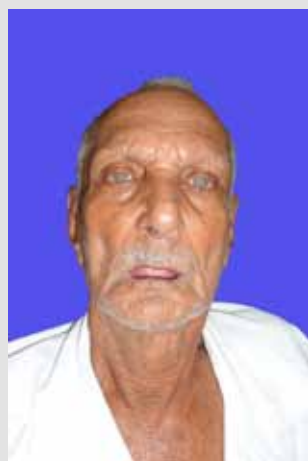

Fig. 10 Pre operative frontal view.



Fig. 11 Post operative frontal view.

8. Recover the processed denture in the usual manner. Remount the denture on an articulator and adjust the occlusion as necessary. Cut two openings with a bur into the denture base distal to the most posterior teeth. Remove the dental plaster – pumice mixture by scraping with a sharp instrument. After complete removal of the mixture the windows were sealed using autopolymerizing resin. (Fig 7)
9. Polish the denture in the usual manner. Verify that the cavity was sealed by immersing the denture in water. No bubbles were evident, indicating an adequate seal over the denture.
10. Regular recall visit for 3 months was kept during which no discomfort was reported by the patient. (Fig 8 & 9). The patient was satisfied with the function, aesthetic and comfort of the denture. (Fig 10 & 11)

### ► Discussion

Rehabilitation of the patient with severely resorbed ridges poses a significant challenge to the specialist. There are various methods for rehabilitation of such patients<sup>6,7</sup>. Treatment options like implant supported overdenture, ridge augmentation can be considered for the patients with resorbed ridges. Many times such patients will be geriatric patients with systemic illness, economic constraints and not willing for any kind of surgical procedures as well. Hence, it will be better to treat them in a conventional manner<sup>3</sup>.

O. Sullivan et al used two flasks with inter changeable halves for fabricating a hollow maxillary denture. Heat-polymerizing one portion of the denture against polymerized resin may reduce leakage at the junction of the two portions of the denture. Since both portions are heat polymerized there will be reduced leakage along the junction at the two portions of the denture<sup>8,9</sup>.

The technique used in the article requires two interchangeable flasks for the fabrication of the denture. Even though the procedure is time-consuming it will reduce the weight and which in turn will considerably enhance the

retention of the denture<sup>10</sup>. Hollow dentures are prone to fracture and care should be taken to avoid leakage along the junction of the two portions of the denture.

### ► Conclusion

The hollow maxillary denture is an ideal method of rehabilitating a patient with the severely resorbed maxillary ridge. It significantly reduces the weight of the denture which ultimately results in increased retention and stability of the prosthesis<sup>11</sup>. Moreover, this may also aid in preserving the existing residual alveolar ridge of the patient. The method described here highlights a simple but precise technique for the fabrication of maxillary hollow denture. Another advantage of the technique is that the dental plaster and pumice mixture used as the spacer which can be easily removed using a sharp instrument to make the denture hollow and weightless.

### ► References

1. Fattore LD, Fine L, Edmonds DC. The hollow denture: an alternative treatment for atrophic maxillae. *J Prosthet Dent* 1988; 59:514-6.
2. Laxman Singh Kaira, maxillary hollow denture: A case series, *Journal of Orofacial Research* April – June 2012; 2(2): 109-112.
3. N Kalavathy, M MithaShetty, Premnath, KarunaPawashe, RKV Patel, Hollow mandibular complete denture - A case report. *SRM University Journal of Dental Sciences*, Volume 1, Issue 3, October – Decembret 2010
4. SaurabhChaturvedi, A.K. Verma, Mariyam Ali, PreetiVadhvani, Hollow Maxillary Denture: A Simplified Approach. *People's Journal of Scientific Research*.,Vol. 5(2), July 2012
5. Gardner LK, Parr GR, Rahn AO. Simplified technique for the fabrication of a hollow obturator prosthesis using vinyl polysiloxane. *J Prosthet Dent* 1991;66:60-2.
6. McAndrew KS, Rothenberger S, Minsley GE. An innovative investment method for the fabrication of a closed hollow obturator prosthesis. *J Prosthet Dent* 1998;80:129-32.
7. Holt RAJr. A hollow complete lower denture. *J Prosthet Dent*1981;45:452-4.
8. Jhanji A, Stevens ST. Fabrication of one-piece hollow obturators. *J Prosthet Dent* 1991;66:136-8.
9. Elliott DJ. The hollow bulb obturator: its fabrication using one denture flask. *Quintessence Dent Technol* 1983;7:13-4.
10. DaBreo EL. A light-cured interim obturator prosthesis. A clinical report. *J Proshet Dent* 1990;63:371-3.
11. Chalian VA, Barnett MO. A new technique for constructing a one-piece hollow obturator after partial maxillectomy. *J Prosthet Dent* 1972;28: 448-53.

# Comparison of different methods of assessing alveolar ridge dimensions prior to dental implant placement

\* Veena T.K., \*\* Sudeep S, \*\*\* Dinesh

## Abstract

The science of Implantology is highly dynamic ever since its introduction into the field of dentistry by Dr. P.I Branemark, it has undergone numerous modifications and improvements. With each improvement and advancements made, implantology has proved to be a boon to the society and hence its acceptance by the general population has widely increased despite it being a relatively expensive treatment modality.

Minimally Invasive Flapless Implant surgery has gained wide acceptance among practitioners and patients alike owing to its obvious advantages such as lesser bleeding, post operative discomfort and simpler surgical procedure.

However, such flapless placement requires precise planning and astute understanding of supporting tissue such as the dimensions of the osseous ridge and bone. This paper intends to present our investigations into comparative assessments of the accuracy of various modalities both radiographic (Dentascan, occlusal radiography) and ridge mapping towards the planning of each implant surgery.

KDJ 2016 | Vol. 39 | No. 1 | Pg 40-42

## ► Introduction

The use of dental implants to support prosthodontic restorations has a high success rate. Careful diagnosis and treatment planning are critical for a favorable outcome. Evaluation of the dimensions of the available alveolar bone is an important prerequisite.

Bone evaluation limited to the use of panoramic and/or periapical radiographs may be insufficient because it only provides two-dimensional information about implant sites. Assessment of the bucco-lingual dimension of the osseous ridge also is needed for proper treatment planning. The bucco-lingual ridge width can be evaluated by Dentascan; a computed tomography (CT) software program that allows the mandible and maxilla to be imaged in three planes: axial, panoramic and cross-sectional. It has been widely used pre-operatively for implant surgery as it provides a comprehensive assessment of the bone morphology and measurement of the dental implant. It is an interactive CT imaging software that combines the power and detail of CT imaging with the convenience of interacting with the images on a desktop or notebook computer. An alternative method is ridge mapping using a caliper device under local anesthesia. The pointed tips of the instrument penetrate

buccal and lingual soft tissue layers and measure the bucco-lingual width of the underlying bone. This procedure is performed chairside and provides instant information.

The aim of this study was to compare the width of bone using Ridge mapping, Dentascan and Intra Oral Periapical Radiographs (IOPA) in Occlusal projection.

## ► Materials and methods

### Study Subjects

Six subjects (four males and two females; age range: 32 to 45 years) with 12 sites for planned implant placement were recruited. One subject provided four sites, three subjects provided two sites, and two subjects provided one site. The subjects were chosen from individuals referred to the Department of Prosthodontics, PMS College of Dental Science and Research and was granted approval for the study from the ethical committee of the Institution. The participants signed an informed consent prior to examination. The inclusion criteria were as follows: Non-pregnant, healthy subjects, presence of a partially edentulous ridge in the mandibular posterior region, presence of at least one periodontally healthy and stable tooth adjacent to the edentulous ridge to serve as an abutment for guidance stents, treatment plan with implant placement.

\* PG Student, \*\* Professor and Head, \*\*\* Professor, Department of Prosthodontics, PMS College of Dental Science and Research, Vattappara, Trivandrum - 695 028 Corresponding Author: Dr Veena T.K, Email: tkveena1@gmail.com

### Stent Fabrication to Prepare for Measurements (Fig 1)

A study model was made from an alginate impression and a clear acrylic stent was fabricated. A pair of buccal/lingual measurement points were defined at the site for implant placement and marked on the study model. The points located 7 mm from the summit of the alveolar soft tissue. It was transferred to the stent by drilling 1.0-mm diameter guide holes. In this manner, the stent provided consistent buccal and lingual locations for the assessment of ridge width. The holes in the guidance stent were filled with gutta percha for use during the preoperative scan to provide radiopaque landmarks indicating the locations for comparative radiographic ridge width measurements.

### Alveolar Ridge Dimensions Assessed by Dentascan (Fig 2)

Dentascan was performed with subjects in a supine position. The device was operated at 120 kV with an exposure time ranging from 5.4 to 9.0 seconds. The images were obtained from 1-mm CT cross sections with the software program provided by the manufacturer. The stent with gutta percha in the guide holes was placed in the mouth before the images were obtained. The measurements were performed using the software's built-in measurement tool. The largest distance between the buccal and lingual bone walls was recorded.

### Alveolar Ridge Dimensions Assessed by Intra Oral Periapical Radiographs in Occlusal projection (Fig 3)

An intra oral periapical film was placed occlusally on the occlusal stent. The occlusally projected beam was directed and radiograph was taken. The radiographs showed gutta percha markings buccally and lingually and the width of the bone was measured.

### Ridge-mapping measurements (Fig 4)

Following local anesthesia, the stent was placed in the area to be measured (the gutta percha was removed from the guide holes). The tips of the ridge-mapping instrument were inserted into the guide holes, penetrating through the soft tissues until there was contact with bone. The width of the alveolar ridge at 7mm was recorded to the nearest millimeter.

### ► Results

The mean value of RM (Ridge mapping) was  $7.01 \pm 1.508$ . The mean value of OP (Occlusal projection) was  $9.81 \pm 1.915$ . The mean value of DS (Denta scan) was  $8.18 \pm 1.535$ . Since standard deviation was high for OP, the data OP was more fluctuating in nature.

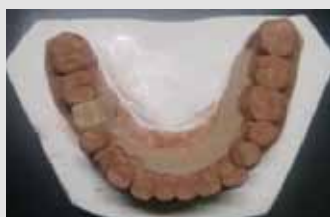Since the ANOVA value showed p value less than 0.05, there was significant difference among the mean value of RM, OP and DS; which was low for RM and high for OP. The post hoc test, showed that there was significant differences among all the mean values. (Table 1 and Chart 1)

### ► Discussion

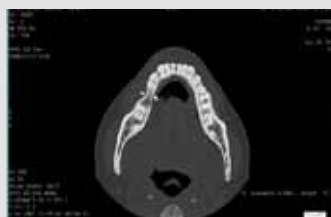In the comparative study, the width of bone was compared using Ridge mapping, Dentascan and Intra oral periapical radiographs (IOPA) in Occlusal projection. Though there were quite other techniques for assessing ridge dimension like CBCT, transtomography and direct caliper measurement following surgical exposure of the bone.

Since the ANOVA value showed p value less than 0.05, there was a significant difference among the mean values of RM, OP and DS; which was low for RM and high for OP and the post hoc test, showed that there was significant differences among all the mean values.

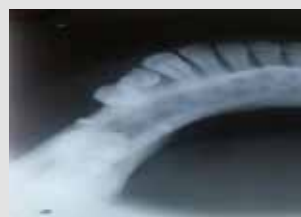This was in agreement with Lung-Cheng Chen et al<sup>2</sup>; compared ridge mapping measurement before surgical flap reflection and measurement using images from cone beam computerized tomography (CBCT) to direct caliper measurement following surgical exposure of the bone. They concluded that CBCT was less consistent compared to direct caliper measurements and did not provide any additional, significant diagnostic information. But in contrast; Shrikar et al<sup>3</sup> studied the dimensions of ridge/width of bone and deviation of center of ridge using Intra oral periapical radiographs (IOPA) in occlusal projection as a preprosthetic diagnostic method and their findings suggested that IOPA radiographs in occlusal projection could be used as a preprosthetic diagnostic method to assess the width of the alveolar bone for future flapless implant placement.



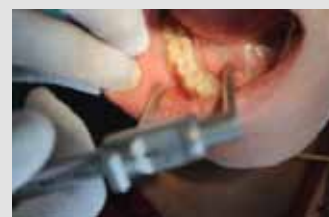**Fig 1:** Stent Fabrication to Prepare for Measurements



**Fig 2:** Alveolar Ridge Dimensions Assessed by Dentascan



**Fig 3:** Alveolar Ridge Dimensions Assessed by Intra Oral Periapical Radiographs in Occlusal projection



**Fig 4:** Ridge-mapping measurements



**Table 1:** One factor ANOVA

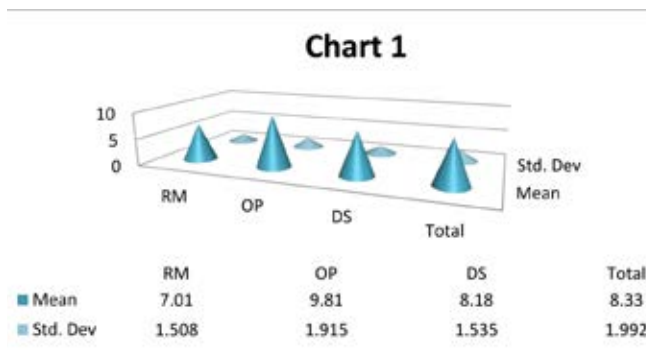
	Mean	n	Std. Dev		
	7.01	12	1.508		RM
	9.81	12	1.915		OP
	8.18	12	1.535		DS
	8.33	36	1.992		Total
ANOVA table					
Source	SS	df	MS	F	p-value
Treatment	47.623	2	23.8117	8.61	.0010
Error	91.242	33	2.7649		
Total	138.865	35			

*Post hoc analysis*

p-values for pairwise t-tests

		RM	OP	DS
		7.01	9.81	8.18
RM	7.01			
OP	9.81	.0002		
DS	8.18	.095	.0216	

Ridge mapping concept was introduced by Wilson<sup>4</sup>. Traxler et al<sup>5</sup> compared the use of two different calipers in four subjects and 11 sites marked with a water insoluble pen. The maximum deviation between the two calipers for individual pairs of measurements was 0.5 mm. Bruggenkate et al<sup>6</sup> used another ridge-mapping instrument in 60 subjects and 176 maxillary implant sites and compared preoperative measurements (ridge mapping) to measurements following mucoperiosteal flap reflection (direct caliper measurements) without the use of any device to identify the measurement locations. The mean ridge mapping measurements averaged 0.4 mm less than the direct caliper measurements. However, the frequency of deviations of different magnitudes comparing the two methods was not reported. Allen and Smith<sup>7</sup> used still another caliper comparing ridge mapping to direct caliper measurements in 11 subjects and 25 maxillary anterior sites, using stents to identify the measurement locations. Details of the magnitude of the deviations were not provided. However, statistically significant differences between the two methods were observed.



► **Conclusion**

The results of the present study favour the use of ridge mapping. Dentascan was less consistent and IOPA in occlusal projection was least consistent when compared to direct caliper measurements. However, it must be kept in mind that ridge mapping may give erroneous readings.

► **Reference**

1. Siddhartha chandel, Amiya agrawal, Nishi singh, Ankita singhal. Dentascan: a diagnostic boon. Journal of dental sciences and research vol. 4(1): 13 - 17
2. Lung-Cheng Chen, Tord Lundgren, Hadar Hallstrom, and Fabrice Cherel, ' Comparison of Different Methods of Assessing Alveolar Ridge Dimensions Prior to Dental Implant Placement. J Periodontol 2008;79:401-5.
3. Shrikar R. Desai, I. Karthikeyan, Singh Rika, 'An in-office, cost effective technique for measuring width of bone using intra-oral periapical radiographs in occlusal projection'; Journal of indian society of periodontology, 2013 Jan;17(1):82-6.
4. Wilson DJ. Ridge mapping for determination of alveolar ridge width. Int J Oral Maxillofac Implants 1989;4:41-43.
5. Traxler M, Ulm C, Solar P, Lill W. Sonographic measurement versus mapping for determination of residual ridge width. J Prosthet Dent 1992;67:358-361.
6. Ten Bruggenkate CM, de Rijke TB, Kraaijenhagen HA, Oosterbeek HS. Ridge mapping. Implant Dent 1994;3:179-182.
7. Allen F, Smith DG. An assessment of the accuracy of ridge-mapping in planning implant therapy for the anterior maxilla. Clin Oral Implants Res 2000;11:34-38.

# Predictive marker of residual ridge resorption- biochemical and radiographic evaluation

\* Jemcy James, \*\* Sudeep S., \*\*\* Dinesh

## Abstract

Residual ridge resorption (RRR) a term used to describe the changes which affect alveolar ridge following tooth extractions, continues well after healing of the extraction socket and a vexing problem faced by a prosthodontist owing to its unpredictable nature. Studies on RRR have often focused on the aetiology and to the retrospective assessment of the extent of supporting tissue destruction. Predictive assessments that point towards prospective loss of denture bearing area have been few in the literature. This paper is an attempt aimed at shedding light on the use of biological predictive markers such as urinary calcium creatinine ratio and radiological parameters such as resorption index and panoramic mandibular index in edentulous patients in a effort to assess RRR

**Keywords:** Residual Ridge Resorption, Resorption Index, Panoramic Mandibular Index, Calcium Creatinine Ratio

KDJ 2016 | Vol. 39 | No. 1 | Pg 43-46

## ► Introduction

Residual ridge is a term used to describe the shape of the clinical alveolar ridge after healing of bone and soft tissues after tooth extractions. It consists of the denture-bearing mucosa, submucosa and periosteum, and the underlying residual alveolar

bone. Residual ridge resorption describes the changes which affect alveolar ridge immediately following tooth extractions and continues well after healing of the extraction socket and is a vexing problem faced by a prosthodontist owing to its unpredictable nature. The size of the residual ridge is reduced most rapidly in the first 6 months, but the bone resorption activity continues throughout life at a slower rate.<sup>1</sup> In a prosthetic sense, bone is considered to be the base which provides support for dentures. In the physiological sense, it is an area where forces created while biting and chewing foods are transmitted. In young and healthy individuals the process involves a relative balance between bone resorption and absorption, with the result that premature bone loss is not observed. In older people the life span and proliferation of osteoclasts is significantly decreased, which results in domination of the resorptive process over osteogenesis.<sup>2</sup> As the success of removable prosthesis relies greatly on the quantity and architecture of the jaw RRR appears to be a crucial factor that affects the retention and stability of removable prosthesis, and consequently, masticatory function. Even when mandibular atrophy does not interfere with the potential for implant placement, a residual ridge with reasonable dimensions can be a significant advantage for the success

of an implant-supported removable or fixed prosthesis.<sup>3</sup>

It has been established in the past that the process of residual ridge resorption is multifactorial in nature and this multifactorial etiology makes it difficult to predict the rate and amount of the residual ridge resorption. Studies on RRR have often focused on the aetiology and to the retrospective assessment of the extent of supporting tissue destruction. Predictive assessments that point towards prospective loss of denture bearing area have been few in the literature. With the introduction of resorption markers it is possible to understand the rate of resorption. These markers measure the levels of biochemical markers of bone resorption in the form of free and urine deoxypyridinoline (DPD), N-telopeptides (NTx) and C-telopeptides (CTx).<sup>4</sup> However, the resorption markers serve as a relatively expensive technique and require constant monitoring. Hence there is a need for a simpler and cost effective technique to predict the resorption of bone. This study is an attempt aimed at shedding light on the use of biological predictive markers such as 24hr urinary calcium creatinine ratio along with radiographic evaluation in edentulous patients in an effort to assess RRR.

\* PG Student, \*\* Professor and Head, \*\*\* Professor, Department of Prosthodontics, PMS College of Dental Science and Research, Vattappara, Trivandrum - 695 028 Corresponding author: Dr Jemcy James, Email: jemmu2485@gmail.com

► **Materials and methods**

Ten completely edentulous male patients of age group 55 to 75 (mean age 65) who visited the department of prosthodontics of PMS College of Dental Science and Research Trivandrum Kerala were selected for the study. The inclusion criteria for the study were completely edentulous male patients who had never worn any removable dental prosthesis before with no relevant medical history and who were willing to participate in the study. Female patients were not included to the study due to the postmenopausal osteoporotic changes frequently diagnosed in them. The study group of patients was not selected on the basis of any radiographic or medical criteria that would define an individual as ‘normal’ or ‘osteoporotic’. Study was approved by the institutional ethical committee and informed consent was obtained from the patient.

Standardized OPG were taken. Linear measurements were made on selected panoramic radiographs using the Sidexis XG software by including a correction of 20% magnification to better simulate the clinical condition. Two observers (one oral radiologist and one prosthodontist) independently assessed the Mean Cortical Width at the mental foramen region. Resorption index and Panoramic mandibular index was measured from the radiographs. Panoramic mandibular Index (PMI), is measured as the ratio of the thickness of mandibular cortex to the distance between the mental foramen and the inferior mandibular cortex. Resorption Index (RI) which is described as the ratio of the mandibular total bone height to basal bone height at the mental foramen region

**Table 01** Results of RI, PMI and Ca Cr Ratio

SN	Age	Resorption index	PMI	Ca Creatinine ratio
1	71	1.76	0.08	0.36
2	57	2.25	0.03	0.39
3	61	1.72	0.18	0.34
4	65	1.97	0.03	0.38
5	74	1.42	0.28	0.3
6	70	2.36	0.02	0.42
7	59	1.85	0.08	0.37
8	71	2.66	0.028	0.58
9	62	1.86	0.06	0.38
10	57	1.69	0.22	0.33

Random urine sample was taken from the patient. Patient was asked not to collect first urine sample but collect all subsequent samples for next 24 hrs. Samples were tested for 24-hrs Calcium Creatinine ratio

► **Results**

The results obtained from 24 hr urinary calcium creatinine ratio and resorption index and panoramic mandibular index are shown in the table 1. Karl Pearson coefficient of correlation was used to assess the correlation between age, Resorption index Panoramic mandibular index and 24hr Calcium creatinine ratio. Correlation matrix was obtained as in Table 2. It was found that Age has no correlation with Resorption index, PMI and Calcium creatinine ratio. Resorption index and Calcium Creatinine ratio have negative high correlation. Resorption Index and PMI have high positive correlation. PMI and Calcium Creatinine ratio have moderately positive correlation. The values are statistically significant  $p < 0.05$

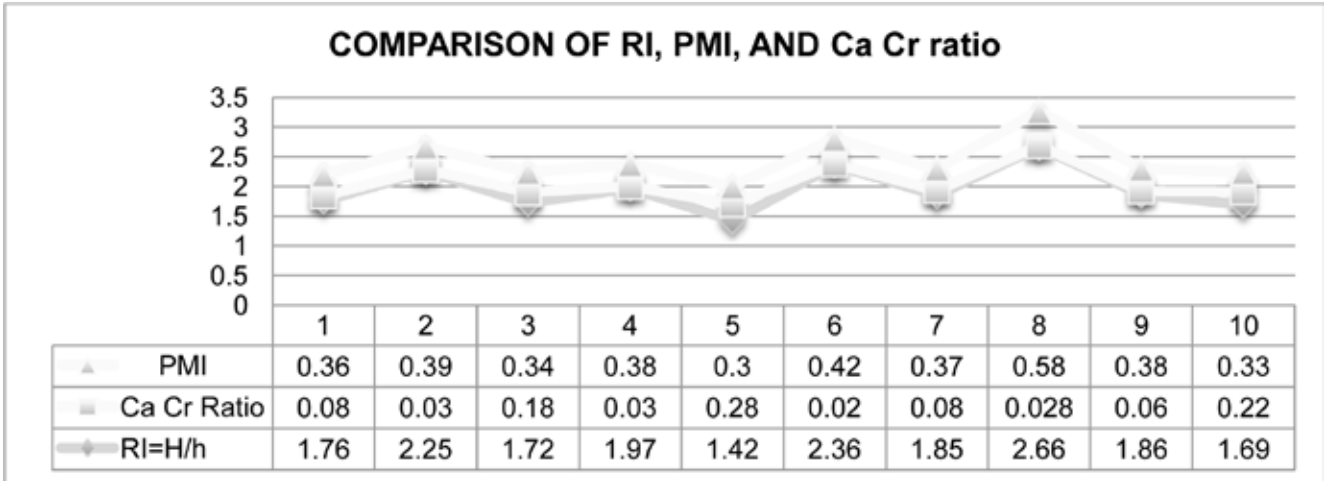
► **Discussion**

Residual ridge resorption (RRR) following the loss of teeth is well recognized as a major oral disease. 1 As the success of removable prostheses relies greatly on the quantity and architecture of the jaw bones, residual ridge resorption (RRR) appears to be a crucial factor that affects the retention and stability of removable prostheses, and consequently, masticatory function. Severe pathological resorption of the inferior alveolar process and basal bone may lead to weakening of the jaw, which in turn results in an unstable removable prosthesis, and marked reductions in the facial and vertical dimensions.<sup>3</sup>

The rate of RRR varies, from one individual to another; at different phases of life and even at different sites in the same person. The clinical significance of such remodelling is that the functionality of removable prostheses, which rely greatly on the quantity and architecture of the residual ridge, may be adversely affected. Residual ridge resorption is often clinically evident yet the actual physiological changes that follow tooth extraction are not well-understood. Atwood first

**Table 02** - Correlation Matrix

	Age	RI=H/h	Ca Cr Ratio	PMI
Age	1			
RI=H/h	0.089	1		
Ca Cr Ratio	0.036	-0.79	1	
PMI	0.254	0.912	-0.651	1



postulated the four main factors namely anatomic, prosthetic, metabolic, and functional factors that are responsible for the loss of alveolar bone. (Atwood, 1957, 1962)<sup>5</sup>

Every clinician is aware that the proportions of the residual ridge are critical to denture success. Irrespective of the etiology, the management of cases of residual ridge resorption is more or less the same. Most of the studies in literature has focussed on the retrospective assessment of resorption. Little evidence is there on the prospective aspects of residual ridge resorption. The use of resorption markers has given us a technique to understand the resorption of bone. These markers study the breakdown products of the bone matrix in the form of urine or serum by-products. However these markers are very technique sensitive and are relatively expensive. The urinary resorption markers are Urinary

hydroxyproline Urinary total pyridinoline (PYD)Urinary free deoxypyridinoline (DPD)Urinary collagen type 1 cross-linked N-telopeptide (NTX)Urinary or serum collagen type 1 cross-linked C-telopeptide (CTX)Bone sialoprotein (BSP) Tartrate-resistant acid phosphatase 5b.<sup>4</sup> The purpose of this study was to find out a simple biochemical and radiological measurement to predict residual ridge resorption.

Calcium is a vital element for the physiological functioning of the body. It is a fundamental element necessary to form electrical gradients across membranes and the main constituent in bone. Under normal physiologic conditions, the concentration of calcium in serum and in cells is tightly controlled. The excess of calcium is excreted through urine or faeces. Asplin found a correlation in urinary calcium excretion and resorption of bone.<sup>7</sup> Nordin proposed the use of the ratio

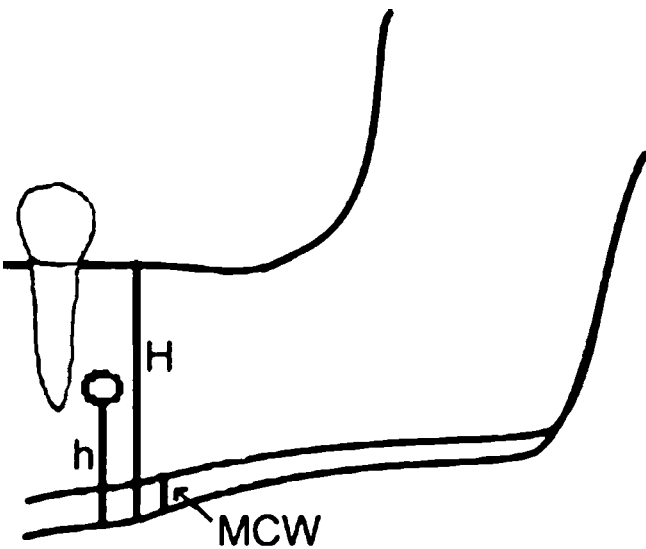


Fig 1 Measured regions of interest

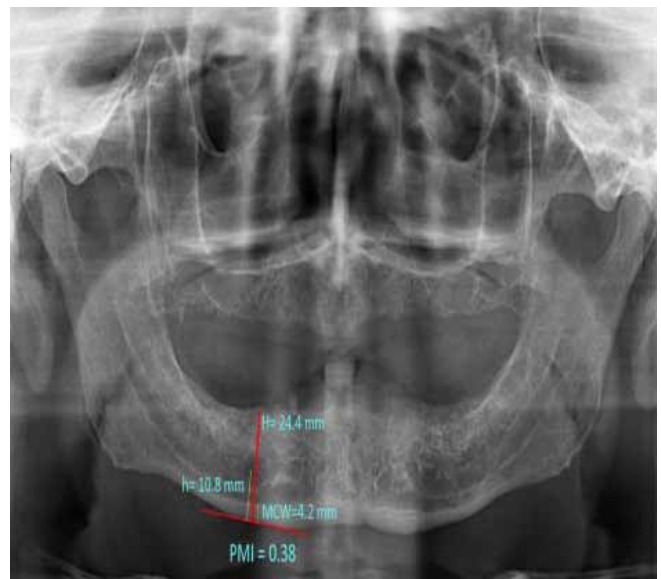

Fig 2 Tracing on Orthopantomographs



of the calcium to creatinine concentration in random urine specimens as a convenient index of urinary calcium excretion. In this ratio creatinine serves as a reference standard by virtue of its relatively constant excretion rate throughout the 24 hours. Hence a 24 urinary calcium- creatinine ratio was evaluated.<sup>8</sup>

Despite the possibility of a resorptive process above the mental foramen, the distance from the foramen to the inferior border of the mandible remains relatively constant throughout life. In this region, the distance below the foramen in a non-resorbed mandible is approximately one third the total height of the mandible which may have strong diagnostic value.<sup>9</sup> Some investigators report that a greater RRR of the mandible may be associated with lower skeletal bone mineral density or osteoporosis.

In this study Panoramic Mandibular Index (PMI) and Resorption index (MR). PMI was calculated according to the method of Benson et al. as a ratio IC/h. MR, serving as the indicator of residual ridge resorption (RRR), was calculated as a ratio H/h according to the method of Ortman et al which is adaption of a technique described by Wical and Swoope.<sup>10</sup> A correlation was obtained between 24hr Calcium Creatinine ratio Resorption index and panoramic index to residual ridge resorption. Hence these can be used as a simple radiographic and biologic screening test to predict residual ridge resorption.

However this study has included only male patients because of the post-menopausal osteoporotic changes diagnosed in female patients. Also the dietary intake of calcium has not been taken into account which can alter the urinary excretion of calcium. This is just a preliminary study and more extensive research have to be conducted before final conclusions could be made regarding the reliability of using these for predicting residual ridge resorption

## ► Conclusion

Within the limitations of the study it could be concluded that

- There was a significant correlation between calcium creatinine ratio, resorption index and panoramic index
- These can be used as screening tests for predicting residual ridge resorption

## ► References

1. D'souza.D, Residual ridge resorption revisited, Oral Health Care – Prosthodontics, Periodontology, Biology, Research and Systemic Conditions
2. E. Zmysłowska, S. Ledzion, K. Jędrzejewski, Factors affecting mandibular residual ridge resorption in edentulous patients:a preliminary reportFolia Morphol., 2007, Vol. 66, No. 4
3. Imirzalioglu.P, Yuzugullu.B and Gulsahi.A, Correlation between residual ridge resorption and radiomorphometric indices, Gerodontolgy 2012; 29: 536–542
4. Kheur, et al.: Prediction of residual ridge resorption Journal of Orofacial Sciences 2012 32 Vol. 4 Issue 1
5. Atwood DA, Coy WA. Clinical, cephalometric, and densitometric study of reduction of residual ridges. J Prosthet Dent 1971;26:280-95.
6. Atwood DA. Post extraction changes in the adult mandible as illustrated by microradiographs of midsagittal sections and serial cephalometric roentgenograms. J Prosthet Dent 1963;13:810-24.
7. Asplin JR, Donahue S, Kinder J, Coe FL. Urine calcium excretion predicts bone loss in idiopathic hypercalciuria. Kidney Int 2006;70:1463-7.
8. Wills MR. The urinary calcium/creatinine ratio as a measure of urinary calcium excretion. J Clin Pathol 1969;22:287-90.
9. Wical KE, Swoope CC. Study of residual ridgeresorption. Part I. Use of panoramic radiographs for evaluation and classification of mandibular resorption.J Prosthet Dent 1974; 32: 7–12.
10. B Drozdowska, W Pluskiewicz, B Tarnawska, Panoramic-based mandibular indices in relation to mandibular bone mineral density and skeletal status assessed by dual energyX-ray absorptiometry and quantitative ultrasound, Dentomaxillofacial Radiology (2002) 31, 361 ± 367
11. Parlani.S, Nair.P, Agrawal.S, etal Role of Panoramic Radiographs in the Detection of Osteoporosis Oral Hyg Health 2014, 2:1

# Current concepts in eradicating enterococcus faecalis biofilm

\* Ruth Hepsi Bealah, \*\* Jonathan E Sam, \*\*\* Jacob Raja,  
\*\*\*\* Bejoy J Thomas, \*\*\*\*\* Paulaian Benin, \*\*\*\*\* Gen Morgan

## Abstract

The ultimate goal of endodontic treatment is to eliminate bacterial infection from the root canal system and obliterate the canal system with three dimensional obturation and allow healing of periapical pathology. The survival of microorganisms inside the root canal system has been proven as one of the major cause of endodontic failure. Enterococcus faecalis (*E.faecalis*) constitutes the most resistant endodontic biofilm which the abilities to survive through harsh environmental conditions like nutritional deprivation and insult from medications used in endodontic treatment. There have been a lot of advances in the field of dentistry to eradicate endodontic biofilm completely from the root canal system. This literature review article briefly describes the various available materials and technologies to completely eradicate endodontic biofilm.

KDJ 2016 | Vol. 39 | No. 1 | Pg 47-50

## ► Introduction

The objective of endodontic therapy is to remove diseased pulpal tissue, eliminate the endodontic pathogens and provide a hermetic seal to prevent post endodontic recontamination promoting a favorable environment for periapical healing. Endodontic micro-organisms has the ability to organize themselves to

form a resistant endodontic biofilm and its eradication is difficult. This may lead to endodontic failure. Biofilms formed by Enterococcus faecalis (*E.faecalis*) are most commonly associated with post endodontic diseases. This biofilm enables the bacteria to become one thousand times more resistant to phagocytosis, antibodies and antimicrobials when compared non-biofilm producing bacteria<sup>1</sup>.

A challenge is put forth before the endodontist to implement methods to effectively eliminate this *E.faecalis* biofilm during and after root canal treatment. Successful endodontic treatment outcomes require new strategies for the complete eradication of *E.faecalis* biofilms from the root canal system.

The eradication of *E.faecalis* biofilm has gone through a long journey with various advancements in irrigants, medicaments and various other technologies to define a better future for the endodontic speciality.

## Current Concepts in elimination Of *E.faecalis* Irrigants

Irrigants are chemicals used to aid in the removal of micro-organism, debris and acts as a lubricant. Sodium

hypochlorite (NaOCl) is an effective irrigant is used to destroy all forms of *E.faecalis* including its biofilm form<sup>2</sup>. Clegg et al in his study reported that 6% NaOCl is the only agent capable of removing *E faecalis* biofilm and killing bacteria<sup>3</sup>. The action of NaOCl is a dose depended. At higher concentration there is better removal of the biofilm. The anti-biofilm effects of NaOCl is by removal of organic tissue, thus eliminating the bacterial attachment to dentin and other organisms.

A two minute rinse of 2% chlorhexidine (CHX) in liquid form is effective to eliminate *E.faecalis* from the superficial layers of dentinal tubules up to 100 micrometer<sup>4</sup>. EDTA has minimal effect on the biofilm but its ability to remove inorganic portion of the smear layer, facilitates other irrigants to penetrate better into the dentine<sup>5</sup>.

Qmix (EDTA, CHX and a detergent) is as effective as 5.25% NaOCl in eradicating the *E.faecalis* biofilm<sup>6</sup>. MTAD (mixture of tetracycline isomer, acetic acid and tween 80) was found to completely eliminate the growth of *E.faecalis* biofilm by its anticollagenase activity, low pH and its ability to be released over time. On comparing the anti bacterial efficacy of MTAD and

\* Postgraduate student, \*\* Professor and Head, \*\*\*Professor, \*\*\*\*Reader, \*\*\*\*\*Senior Lecturer, Department of Conservative Dentistry and Endodontics, \*\*\*\*\*Senior Lecturer, Department of Oral and Maxillofacial Surgery, Rajas Dental College, Kavalkinaru, Thirunelveli District, Tamil nadu Corresponding contributor: Dr. Ruth Hepsi Bealah, E-mail: dr ruthmorganjenitta@gmail.com

Tetraclean against *E. faecalis* biofilm, it found that tetraclean has better activity against biofilm than MTAD<sup>7</sup>. 3.8% of Silverdiamine fluoride used for intracanal irrigation has been shown to eradicate *E. faecalis* biofilm<sup>8</sup>.

Natural and herbal products are also used as irrigants to bring about eradication of *E. faecalis* biofilm. Curcuma longa (Turmeric) has significant anti bacterial activity against *E. faecalis*<sup>9</sup>. Azadirachta indica (Neem) is anti viral, anti fungal and anti bacterial makes it a potential agent for root canal irrigation and has significant anti microbial activity against *E. faecalis*<sup>10</sup>. Triphala's fruit is rich in citric acid which helps in removing the smear layer and green tea polyphenols have significant anti cariogenic, anti inflammatory and anti microbial properties, Triphala and Green tea polyphenols were found to have significant anti microbial activity against two weeks old *E. faecalis* biofilm<sup>11</sup>. Since herbs lack microbial resistance and are able to eradicate the biofilm better than NaOCl and CHX their use as irrigant should be encouraged.

Conventional irrigation with syringes was advocated as an efficient method of irrigant delivery before the advent of passive ultrasonic activation. One-minute use of passive ultrasonically activated irrigation, followed by root canal cleaning and shaping has been shown to improve canal and isthmus cleanliness in terms of necrotic debris and *E. faecalis* biofilm removal<sup>12</sup>. Huang et al reported that manual-dynamic irrigation was significantly more effective in removal of debris and biofilm than an automated-dynamic irrigation system and static irrigation<sup>13</sup>. Ruddle brushes are rotary attached micro brushes which facilitate better removal of debris coronally and disruption of the biofilm. Endovac system which provides more debris removal and ultimately more biofilm removal. Endoactivator improved the synergistic action of 1.3% NaOCl and MTAD in the degradation of *E. faecalis* biofilms and was found to be safe and efficient irrigation regimen<sup>14</sup>. Laser-activated irrigation using photon induced photo acoustic streaming (PIPS) protocol and NaOCl significantly enhanced the antimicrobial effect by eliminating *E. faecalis* biofilm<sup>15</sup>.

#### **Intracanal medicaments:**

2% Chlorhexidine gel is effective in complete removal of the biofilm and its effective for 15 days due to its substantivity property<sup>16</sup>. Triple antibiotic paste (TAP) is a mixture of metronidazole, ciprofloxacin and minocycline has been used as an intracanal medicament for disinfecting the root canal during regenerative procedures. TAP is found to be effective against *E. faecalis* biofilm mainly by the action of minocycline<sup>17</sup>. Ledermix paste which is a commercially available intracanal medicament containing an antibiotic (demeclocycline calcium) and a steroid (triamcinolone acetonide). Athanssiadis et al

found that 50:50 combination of Ledermix and Pulpdent pastes gave a moderate reduction in *E. faecalis* biofilm<sup>18</sup>.

Nisin, a newer intracanal medicament which is a naturally occurring antimicrobial peptide is found to be as effective as NaOCl against the *E. faecalis* biofilm<sup>19</sup>. Nisin is produced by *Lactococcus lactis* and which is a class I bacteriocin. Linezolid is an oxazolidinone agent that acts by inhibiting initiation of bacterial protein synthesis used as an intracanal medicament was found to be more effective than CaOH with iodoform (vitapex) against *E. faecalis* biofilm<sup>20</sup>.

A novel intra canal medicament human  $\beta$  defensin-3 is a cationic antimicrobial peptide with strong antibacterial and immuno-regulatory activity against *E. faecalis*. In a study human  $\beta$  defensin-3 peptide was found to exhibit more antibacterial effect than 2% CHX against the *E. faecalis* biofilm<sup>21</sup>.

N-acetyl cysteine is a potent thiol containing anti-oxidant possessing strong antibacterial property. It was found to be effective in reducing extracellular polysaccharide production, disrupting mature biofilm, and reducing adhesion of bacteria on surfaces. It was found to inhibit and eradicate *E. faecalis* biofilm<sup>22</sup>.

Calcium hydroxide (CaOH) commonly used as an intracanal medicament is ineffective against *E. faecalis* biofilm<sup>23</sup> but when CaOH is mixed with CHX, it was found to be effective against the biofilm<sup>24</sup>.

#### **Other aids to remove endodontic biofilm**

##### **1. Ozone:**

Ozone is a very powerful bactericide that can kill microorganisms effectively. It is an unstable gas, capable of oxidizing any biological entity. It was reported that ozone at low concentration, 0.1 ppm, is sufficient to inactivate bacterial cells including their spores. It is present naturally in air and can be easily produced by ozone generator. When introduced in water, ozone dissolves rapidly and dissociates rather quickly and forms the ozonated water

Ozonated water used as an irrigant is a potent antibacterial agent against *E. faecalis* biofilm<sup>25</sup>. High concentrated gaseous and aqueous ozone is strain, dose and time dependently effective against *E. faecalis* in suspension and biofilm test model<sup>26</sup>.

##### **2. Plasma dental probe:**

Plasma dental probe is effective for tooth disinfection. A room temperature plasma dental probe was developed to generate a 3 cm long, 1-2 mm diameter plasma plume for root canal disinfection. The reactive plasma species (e.g., reactive

oxygen species and charged species) can be introduced by the plasma plume and capable of penetrating everywhere in the root canal, including through dentinal tubules, and disinfect surfaces by bactericidal processes. Antibacterial efficacy of plasma and 5.25% NaOCl for 5 min resulted in 93.1% and 90.0% against *E. faecalis* biofilm respectively. The demonstrated bactericidal effect of the cold plasma with direct surface contact may be due to the enhanced oxidation by the locally produced reactive plasma species<sup>27</sup>.

### 3. Laser:

Lasers such as CO<sub>2</sub> (wavelength of 10600 nm), Nd:YAG (neodymium-doped yttrium aluminium garnet) (1064nm), Er:YAG (erbium-doped yttrium aluminium garnet) (2940nm) and diode (810 or 980 nm) have been tested for disinfection of root canals. The effect of Nd:YAG on *E. faecalis* biofilm is less than that of 1% NaOCl solution. A combination of laser and NaOCl results in complete elimination of *E. faecalis* biofilms<sup>28</sup>.

### 4. Photo dynamic therapy:

Photodynamic therapy is a recent method used to remove endodontic biofilm. It involves the killing of microorganisms when a photo sensitizer selectively accumulated in the target is activated by a visible light of appropriate wavelength. George and Kishen showed that when methylene blue used as a photo sensitizer in photodynamic therapy was irradiated for 20 minutes with a 30-mW laser, it resulted in 97% reduction of *E. faecalis*<sup>29</sup>. A specific microbial efflux pump inhibitor added to methylene blue was able to increase the efficacy of photodynamic therapy in eliminating biofilms formed by *E. faecalis*<sup>30</sup>.

### 5. Nanoparticles:

Nanoparticles (<100 nm) plays an important role in the antimicrobial activity as well as the macro-particles into the endodontic fillers. It has been found that antibacterial nanoparticles have higher activity because of the higher surface area that enable to achieve a greater degree of interaction with the negatively charged surface of bacterial cells. 0.1% silver nanoparticle solution has a strong bactericidal effect against *E. faecalis* biofilm formed on dentin after 24 hours of exposure<sup>31</sup>. Chitosan nanoparticles and Zinc oxide nanoparticles possess a potential antibiofilm capability. The antibacterial property of these nanoparticles were retained even after aging for 90 days<sup>30</sup>.

### 6. Matrix metalloproteinase inhibitors:

Matrix metalloproteinase (MMPs) are essential enzymes in microbial cell growth and homeostasis, and they require transition metal ion cofactors to function. Phendione a MMP inhibitor effectively eradicated *E. faecalis* biofilms and

significantly inhibited human MMP-2 through its ability to chelate metal ions. The antibacterial property of Phendione was preserved in the presence of dentin<sup>32</sup>. Phendione can potentially be applied in endodontic treatment as both an antimicrobial agent and MMP inhibitor.

### 7. Phage therapy:

Phage therapy has been proven to be more effective, against multidrug-resistant biofilm infections. The difficulty in *E. faecalis* treatment has been attributed to the lack of anti-infective strategies to eradicate its biofilm and to the frequent emergence of multidrug-resistant strains. An anti-*E. faecalis* phage, termed EFDG1, was isolated from sewage effluents and it might be efficacious to prevent *E. faecalis* biofilm after root canal treatment<sup>33</sup>. This would be the future of eradicating the *E. faecalis* biofilm.

### ► Conclusion

Eradication of *E. faecalis* biofilm from the root canal remains a challenge even after the use of good aseptic technique, increased apical preparation sizes, and inclusion of full strength NaOCl as irrigant and 2% CHX gel as intra canal medicament Hence recent materials and technologies has helped us more to eradicate the *E. faecalis* biofilm but is still a enigma to endodontist.

### ► References

1. Distel JW, Hatton JF, Gillespie MJ. Biofilm formation in medicated root canals. *J Endod* 2002; 28:689-93
2. Siqueira J, Machado A, Siliveria R, Lopes H DeUzeda M. Evaluation of the effectiveness of sodium hypochloride used three irrigation methods in the elimination of enterococcus faecalis from the root canal in vitro. *Int Endod J*.1997;30:279-82
3. Clegg MS, Vertucci FJ, Walker C, Belanger M, Britto LR. The effect of exposure to irrigant solutions on apical dentin biofilms in vitro. *J Endod* 2006; 32:434-37
4. Vahdaty A, Pitt Ford TR, Wilson RF. Efficacy of chlorxidine in disinfecting dentinal tubules in vitro. *Endod Dent Traumatol* 1993;9:243-8
5. Bystrom A, Sundqvist G. The antibacterial action of sodium hypochloride and EDTA in 60 cases of endodontic therapy. *Int Endod J* 1985;29:243-8
6. Ma J, Wang Z, Shen Y, Hapssalo M, A non invasive model to study the effectiveness of dentin disinfection by using confocal laser scanning microscopy. *J Endod* 2011;37:1380-85
7. Giardino L, Ambu E, Savolde E, Rimodini R, Cassenali C, Debba E A. Comparative evaluation of antimicrobial efficacy of sodium hypochloride, MTAD and Teraclean against *Enterococcus faecalis* biofilm. *J Endod* 2007;33:852-5.
8. Hiraishi N, Yiu CK, King NM, Tagami J, Tay FR. Antimicrobial efficacy of 3.8% silver diamine fluoride and its effect on root dentin. *J Endod*. 2010;36:1026-9.
9. Prasanna neelakantan, chandana subbarao, chandragiri venkata subbarao, analysis of antibacterial activity of curcumin against enterococcus faecalis, *Int J cur res*.2011; 9:1-6.
10. Hannah Rosaline, Kandaswamy D, Gogulnath D, Rubin MI, Influence of various herbal irrigants as a final rinse on the adherence of



- Enterococcus faecalis by fluorescence confocal laser scanning microscope, *J Conserv dent.*2013;16;352-55
11. Madhu Pujar, Chetan Patil and Ajay Kadam, Comparison of antimicrobial efficacy of Triphala, (GTP) Green tea polyphenols and 3% of sodium hypochlorite on Enterococcus faecalis biofilms formed on tooth substrate: in vitro, *J Int Oral Health.*2011;3: 23-30
  12. Bhuvu B, Patel S, Wilson R, Niazi S, Beighton D, Mannocci F. The effectiveness of passive ultrasonic irrigation on intraradicular Enterococcus faecalis biofilms in extracted single-rooted human teeth. *Int Endod J.* 2010;43:241-50
  13. Huang TY, Gulabivala K, Ng Y-L. A bio-molecular film ex-vivo model to evaluate the influence of canal dimensions and irrigation variables on the efficacy of irrigation. *Int Endod J* 2008;41:60-71.
  14. Lei Lei, Hongyan Liu, Yanling Cai, Xi Wei. MTAD combined with endosonic irrigation as a new approach for the disinfection of Enterococcus faecalis biofilm. *J Dent Sci.*2015; 10, 437-43
  15. Mohammed Al Shahrani, Enrico DiVito, Christopher V. Hughes, Dan Nathanso, and George T.-J. Huang. Enhanced Removal of Enterococcus faecalis Biofilm in the Root Canal Using Sodium Hypochlorite Plus Photon-Induced Photoacoustic Streaming: An In Vitro Study. *Photomed Laser Surg.*2014: 32;260-66
  16. Ferraz CC, Gomes BP, Zaia AA, Teixeira FB, Souza-Filho FJ. Comparative study of the antimicrobial efficacy of chlorhexidine gel, chlorhexidine solution and sodium hypochlorite as endodontic irrigants. *Braz Dent J.* 2007;18:294-98
  17. Alireza Adl1, Nooshin Sadat Shojaee1, Mohamad Motamedifar A Comparison between the Antimicrobial Effects of Triple Antibiotic Paste and Calcium Hydroxide Against Entrococcus Faecalis. *IEJ:* 2012;7:149-55.
  18. Athanassiadis B, Abbott PV, George N, Walsh LJ. An in vitro study of the antimicrobial activity of some endodontic medicaments against Enterococcus faecalis biofilms. *Aust Dent J.* 2010; 55:150-5.
  19. Turner SR, Love RM, Lyons KM. An invitro investigation of the antibacterial effect of nisin in root canals and canal wall radicular dentine. *Int Endod J* 2004;37:664-71
  20. Rajdeep Pavaskar et al. An in vitro study comparing the intracanal effectiveness of calcium hydroxide – and linezoöld – based medicaments against Enterococcus faecalis. *J endod :* 2012;38:95-100.
  21. Jin Kyung Lee et al. Antibacterial efficacy of a human  $\beta$  defesins -3 peptide on multispecies biofilm. *J Endod.*2013;39;1625-29
  22. Samantha Yiling Quab, Siwen Wu, Jeen Nee Lui, Chee Peng Sum, Kai Soo Tan. N-acetylcysteine inhibits growth and eradicates biofilm of enterococcus faecalis. *J Endod* 2012;38;81-85.
  23. Estrela C, Pimenta FC, Ito IY, Bammann LL. Antimicrobial evaluation of calcium hydroxide in infected dentinal tubules. *J Endod* 1999;25:416-8.
  24. Mohammadi Z, Abbott PV. The properties and applications of chlorhexidine in endodontics. *Int Endod J* 2009;42:288-302
  25. R. S. Hems, K. Gulabivala, Y.-L. Ng, D. Ready & D. A. Spratt. An in vitro evaluation of the ability of ozone to kill a strain of Enterococcus faecalis. *Int Endod J:*2005: 38;22-2
  26. Jiang C, Schaudinn C, Jaramillo DE, Webster P, Costerton JW. In vitro antimicrobial effect of a cold plasma jet against Enterococcus faecalis biofilms. *ISRN dentistry.* 2012 24:2-6
  27. Rahimi S, Shahi S, Gholizadeh S, Shakouie S, Rikhtegaran S, Soroush Barhaghi MH, Ghojzadeh M, Froughreyhani M, Abdolrahimi M. Bactericidal effects of Nd:YAG laser irradiation and sodium hypochlorite solution on Enterococcus faecalis biofilm. *Photomed Laser Surg.* 2012;30:637-41
  28. George S, Kishen A. Augmenting the antibiofilm efficacy of advance noninvasive light activated disinfection with emulsified oxidizer and oxygen carrier. *J Endod* 2008;34:1119-23.
  29. Kishen A, Upadya M, Tegos GP, Hamblin MR. Efflux pump inhibitor potentiates antimicrobial photodynamic inactivation of Enterococcus faecalis biofilm. *Photochem Photobiol ASA*2010;86:1343-9
  30. Zhuang P, Gao Y, Ling J, et al. Bactericidal effect of nano-silver against E.faecalis biofilm on dentin. *Chin J Stomatol Res Electronic Edition* 2011;5:463-9
  31. Kishen, A., Shi, Z., Shrestha, A. & Gee, K. An Investigation on the Antibacterial and Antibiofilm Efficacy of Cationic Nanoparticulates for Root Canal Disinfection". *J Endod:*2008: 34;1515-20
  32. Tay CX, Quah SY, Lui JN, Yu VS, Tan KS. Matrix Metalloproteinase Inhibitor as an Antimicrobial Agent to Eradicate Enterococcus faecalis Biofilm. *J Endod.* 2015; 41:858-63
  33. Khalifa L, Brosh Y, Gelman D, Coppenhagen-Glazer S, Beyth S, Poradosu-Cohen R, Que YA, Beyth N, Hazan R. Targeting Enterococcus faecalis biofilms with phage therapy. *Appl Environ Microbiol.*2015;81:2696-705.

# Digital impressions – a peak into the future

\*Rohit Raghavan, \*\*Ranjith Kumar P, \*\*\*Nadeem Abdul Rahman

## Abstract

The use of Digital technology for impression making procedures has increased recently. Digital impression has been introduced, potentially eliminating the need for taking conventional impressions for crowns and fixed prostheses. Although majority of clinicians still prefer conventional impression techniques due to number of reasons. The overall goal of this article is to provide the clinician with information on digital impression in dentistry and the clinical application of the technology and also the merits and demerits and compares both the digital impressions and conventional impressions

**Key words:** Digital technology, Digital impression, Digital scanner, Conventional impressions, Camera, Software, Dentin bonding agents.

KDJ 2016 | Vol. 39 | No. 1 | Pg 51-54

## ► Introduction

Today, digital technology controls almost every aspect of our life, and dentistry is no exception to it. Millions of impressions are taken every year for the production of crowns, bridges, and partial dentures. Making impressions with elastomeric impression material is an everyday procedure in almost every general dental practice. A new way to dispense trays and impression materials is now available that create digital impressions of a patient's teeth. The digital impression concept is emerging rapidly on the horizon and it is believed that digital impressions will solve the challenges and difficulties of the conventional impressions.

“Impression” has different meaning in life but in dentistry, impression is negative form of teeth or other tissues of the oral cavity. Impression has its importance in various aspects of dentistry especially in prosthodontic dentistry, to perform various procedure like inlays, onlays, crowns, veneers impression has to be made using different materials and techniques. Earlier impression plaster was used to make impressions, but with time it was replaced by reversible and irreversible hydrocolloid and then elastomeric impression materials. Still, there is lack of some accuracy in making impressions. So, to overcome the inaccuracy digital impression were introduced using scanner and prosthesis are fabricated using software and milling machine.

The first digital scanner was introduced in 1980s for dental impressions since then, development engineers at a number of companies have enhanced the technologies and created in office scanners that are increasingly user friendly and producing precisely fitting dental restorations. These systems are capable of capturing three-dimensional (3D) virtual images of tooth preparations from which restorations may be directly fabricated (CAD/CAM systems) or can be used to create accurate master models for the restorations in a dental laboratory (dedicated impression scanning systems). The use of these products presents a paradigm shift

in the way the dental impressions are made.<sup>1</sup> The advent of highly innovative and accurate impression systems are poised to revolutionize the way in which dental professionals already are and will continue making impressions for indirect restorative dentistry.

The first system for the dental office was CEREC 1 in 1986. The system was developed by Prof. Dr. Werner Moermann in Switzerland and was eventually licensed to what today is Sirona Dental Systems.<sup>2</sup> The Cerec 2 and subsequent Cerec 3 as well as the eventual the Cerec 3D system replaced the original technology in 1994, 2000 and 2003 respectively.<sup>2,3</sup> The Lava™ Chairside Oral Scanner (C.O.S.) was created at Brontes Technologies in Lexington, Massachusetts, and was acquired by 3M ESPE (St. Paul, MN) in October 2006. The product was officially launched in February 2008. iTero In early 2007, the Cadent iTero (Cadent, Carlstadt, NJ) digital impression system came into the market. The E4D Dentist system, introduced by D4D Technologies LLC (Richardson, TX) in early 2008.<sup>1</sup> CEREC AC was introduced in January 2009. Each evolution in the imaging technology led to more indications that the unit could fabricate, as well as a decreased learning curve as the software evolved.<sup>2</sup> Several of the leading 3D dental digital scanning systems are presented and discussed in this article.

\* Head of Department, \*\* Professor, \*\*\* PG Student, Dept of Prosthodontics, Royal Dental College, Chalissery, Palakkad, Kerala Corresponding author : Dr Nadeem Abdul Rahman; Email: nadhee4u4ever@gmail.com

## ► **Back-ground of Current Impression Materials**

The history of today's traditional impression materials began in the mid-1930's with the introduction of reversible hydrocolloids. This was the first material that made the impression of undercuts possible. By the 1955 polysulphides were introduced and for the first time an elastomeric impression material was used.<sup>1</sup> There was a great improvement in reproducing the characteristics of prepared teeth, but still there were inherent problems like shrinkage of material.

## ► **Evolution of Digital Impressions**

It began in 1980's with the introduction of CAD/CAM in the field of dentistry, pioneered by Procera and Cerec.

The current digital impression devices available are the recently introduced Cadent iTero (Carlstadt, N.J.) and the 3M ESPE Lava Chair-side Oral Scanner C.O.S. (St. Paul, Minn.).<sup>2,3,7</sup>

## ► **Comparison between Conventional Impression and Digital Impression Technique –**

### 1. **Complexity and Cost of Purchase**

The initial cost of digital equipment is very expensive when compared to the conventional impressions. Also digital equipment's are complex and trained operator is required to operate and maintain the device. Whereas conventional impressions technique, promises cost effectiveness and also no major equipment's are required.

### 2. **Improper Tray Selection**

Tray selection is a very important step in impression making. Rigid Stock trays are used for impression making, but sometimes if the tray is not so rigid or is distorted, or improperly selected tray leads to inadequate to inadequate impression. If the stock tray and the impression material inside it are not adequately rigid, the impression's accuracy will be compromised because of the flexibility of the tray and the material.<sup>2,3,4</sup> The digital impressions do not involve impression trays, thus eliminating the problems related to improper tray selection and potentially improving the quality of impressions.

### 3. **Distortion of Impression While Removing from the Impression Tray**

Polyether and vinyl polysiloxane impression materials require adhesive agents to attach the impression material to the impression tray.<sup>1,3</sup> Perforated trays further enhance attachment of the impression material to the tray. Improper separation usually results in distortion of the impression. Impression trays are not required for digital impressions. Therefore, digital impressions eliminate this frequently seen problem.

## 4. **Storage of Impressions**

Storing impressions for some time and not pouring impressions immediately is a common procedure. While Alginate impression has to be poured immediately<sup>1</sup>, Polyether and vinyl polysiloxane impression materials are stable for a reasonable period of time after the impression is made, but they can get distorted by inadequate storage.<sup>5,6,8</sup> Digital impressions do not involve impression trays or impression materials thereby eliminating the associated problems.

## 5. **Pouring of Casts/Dies**

Sometimes, an impression is poured improperly. The stone used for pouring may be too thick or too thin, or the stone might not have set before it is retrieved.<sup>1</sup> The result of each of these problems is a need to remake the impression which causes inconvenience to the patient, increases the cost of treatment and also takes more chair side time. In case of digital impression, the digital information is stored as it is taken, so in case the problem while pouring of impression or setting of cast or placement of dies arises, the digital information stored on computer can be reused as many number of times, thus saving precious time of clinician and the patient and also the cost of treatment.

## 6. **Disinfection**

The disinfection of conventional impressions is an expensive and cumbersome procedure which is often overlooked by dentists and laboratory technicians. The digital impressions eliminate the use of stock trays and impression materials, thus, eliminating the need for disinfection.

## 7. **Patient Discomfort and Mess**

The discomfort that arises to patient with the use of stock trays and impression material is eliminated to some extent with digital impressions. Gagging and limited mouth opening further complicate the procedure with conventional impression technique. Digital impression technique involves the placement of small intraoral camera in the patient's mouth, which is usually well accepted by the patients. Digital impressions greatly reduce patient discomfort. Digital impression does not involve impression trays and mixing of impression materials as in conventional technique, thereby, do not cause any discomfort.

## ► **Various systems available in market**

1. Cerec systems
2. E4D denist system(D4D Technologies)
3. iTero system
4. The Lava™ Chairside Oral Scanner (C.O.S.)

## ► **Pre-requisite of digital imaging**

1. Digital camera.
2. Software to create image using CAD/CAM system.

3. Connection to export the image
4. Milling unit to fabricate the prosthesis (in house or in lab).

### ► Steps in digital impression

#### Types of light sources:

Dental laser technology is based on specific wavelengths that determine the tissues (eg, hard or soft) on which a particular device can be used. Diode lasers, which produce invisible near infrared wavelengths ranging from 805 nm to 1,064 nm, are for soft tissues only.

Different system uses a different method to acquire the images. The earlier versions of Cerec® employed an acquisition camera that depended on an infrared laser light source, advancements in the performance of blue light-emitting diodes (LEDs) in parameters that are relevant for 3D acquisition cameras have now surpassed the quality of the longer wavelength infrared light source. The shorter wavelength intense blue light projected by the blue LEDs allows for greater precision of the resultant optical image. The camera projects a changing pattern of blue light onto the object and then reads it back at a slightly different angle, referred to as “active triangulation technique.”

It uses a telecentric beam, which permits the capture of essential information from all of the prepared tooth’s surfaces in a single view. The entire area being impressed needs to be coated completely with a layer of biocompatible titanium dioxide powder to enable the camera to register all of the tissues. The powder is easily removed afterwards with air and water.<sup>9</sup>

The E4D (D4D TECHNOLOGIES), a complete powder free chair side CAD/CAM system, takes several images using a red light laser to reflect off of the tooth structure. The iTero system uses parallel confocal imaging to quickly capture the digital impression.

Parallel confocal imaging uses laser and optical scanning to digitally capture the surface and contours of the tooth and gum structure. The Cadent iTero scanner captures 100,000 points of red laser light and has perfect focus images of more than 300 focal depths of the tooth structure. All of these focal depth images are spaced approximately 50 µm apart. This system does not require the use of powder.<sup>9</sup>

The LAVA Chairside Oral Scanner (LAVA COS, 3M ESPE) takes a completely different approach using a continuous blue light LED video stream of the teeth. It consists of a mobile cart containing a CPU, a touch screen display, and a scanning wand, which has a 13.2-mm wide tip and weighs 14 ounces. The camera at the tip of the wand contains 192 blue

LED cells and complex optical system comprised of multiple lens. Thus, this system is able to capture approximately 20 3D data sets per second, or close to 2,400 data sets per arch, for an accurate and high-speed scan.<sup>13</sup> CEREC and LAVA currently require the use of powder for the cameras to register the topography. Each system uses a systemspecific handheld device to scan the site.

The cerec 1 was an integrated acquisition and milling unit that was moved from operator to operator. The teeth were powdered with an opaquing medium and images were taken with the camera<sup>10</sup>. One study found that the average camera angulation error by clinicians was just under two degrees. The impression process necessitates achieving adequate visualization of the margins of the tooth preparation by proper tissue retraction or troughing and hemostasis.<sup>9,14</sup> Bluecam uses blue-light light emitting diodes (LEDs) to create highly detailed digital impressions using shorter wavelengths of light than earlier systems.

### ► Software

Following image acquisition, the final image is either stored in the system and used for chairside fabrication or digitally transmitted to a laboratory for use. Cerec and E4D system is a complete system that allows the restoration to be made chairside.<sup>3</sup> CEREC Connect is used to export the final digital image directly to a Laboratory.<sup>11</sup>

The LAVA system enables transmission of the data directly to the LAVA lab machine for a coping that can then be placed on the acrylic model for the porcelain or other material to be added; LAVA can be used to print via stereolithography (SLT) physical models.

During the scan, a pulsating blue light emanates from the wand head as an on-screen image of the teeth appears instantaneously. The dentist guides the wand over the occlusal surfaces, rotates the wand so that the buccal surfaces are scanned, then rotates again to capture the lingual surfaces. The “stripe scanning” is completed once the dentist returns to scanning the occlusal of the starting tooth.<sup>9,11,13</sup> The E4D dentist system consists of a cart containing the design center (computer and monitor) and laser scanner, a separate milling unit, and a job server and router for communication.

The scanner, termed the Intra Oral Digitizer, has a shorter vertical profile than that of the cerec, so the patient is not required to open as wide for posterior scans. Therefore, once proper retraction and hemostasis have been obtained, scanning begins by simply placing the Intra Oral Digitizer directly above the prepared tooth. The scanner must be held a specific distance from the surface being scanned—this is



achieved with the help of rubber-tipped “boots” that extend from the head of the scanner. Placing these rests on adjacent teeth steadies the scanner at this optimal distance. The user holds down the foot pedal while centering the image. Once the desired area is centered on the on-screen bulls eye, the pedal is released and the image is captured

The IC Everything feature of the E4D takes actual pictures of the teeth and gingiva. A diagram on the monitor shows the user how to orient the scanner to obtain the next image. As successive pictures are taken, they are wrapped around the 3D model to create the IC Everything model. This 3D ICE view makes margin detection simpler to achieve. The touch screen monitor enables the dentist to view the preparation from various angles to ensure its accuracy.<sup>1</sup>

### ► In house milling machine

The most current version of the Cerec system is the new Cerec AC, a modular unit that contains an acquisition unit and was introduced in January 2009. A separate milling unit has evolved to allow it to fabricate virtually any type of individual restoration with ease and precision unmatched by its predecessors. The main feature of the new system is the camera, which is referred to as the “Bluecam” or “Omnica” uses blue-light light emitting diodes (LEDs) to create highly detailed impressions. Unlike previous generations of scanners, which took one image at a time, the Bluecam is a “continuously on” camera that once you turn it on with a click of the mouse, it stays on, snapping images automatically as soon as the camera is held still over a patient’s tooth. This allows the clinician to take a quadrant of images in as little as a few seconds.

### ► Benefits of digital impression<sup>11,16,17</sup>

- A. Accuracy of impressions
- B. Opportunity to view, adjust and rescan impressions
- C. No physical impression for patient
- D. Saves time and one visit for in-office systems
- E. Opportunity to view occlusion
- F. Accurate restorations created on digital models
- G. Potential for cost-sharing of machines
- H. Accurate, wear- and chip-resistant physical CAD/CAM derived models
- I. No layering/baking errors
- J. No casting/soldering errors
- K. Cost-effective
- L. Cross-infection control
- M. Patient is comfortable

### ► Conclusion

We compared the merits and demerits of conventional and digital impression making in routine dental practice. Digital

impressions emerge as practical and precise but the need for further research is required.<sup>2,3</sup> Digital impressions eliminate some of the common problems which occur in conventional impression procedures as in case of elastomeric impressions, but proper soft tissue management following fundamentals of tooth preparation and a good laboratory support is required for success. In future, the Digital technology in dentistry will continue to develop and flourish. With the numerous advantages of digital impressions over traditional impressions and the ability to benefit from digital impression making and/or CAD/CAM, more and more dentists are purchasing digital impression systems. It will likely be a routine procedure in most dental offices in the near future, as dentists, laboratory technicians, and patients all reap the benefits.

### ► References

1. Nathan S. Birnbaum; Heidi B. Aaronson; Chris Stevens; Bob Cohen. 3D Digital Scanners: A High-Tech Approach to More Accurate Dental Impressions; *Inside Dentistry*; April 2009; 5, (4).
2. Puri S. Maximizing and simplifying CAD/CAM dentistry; [www.ineedce.com](http://www.ineedce.com)
3. Feuerstein P. An overview of CAD/CAM and digital impressions; [www.ineedce.com](http://www.ineedce.com)
4. Allison M. DiMatteo, and Terri Rafferty. Dental Lasers; *Inside Dentistry*; November 2012; 8( 11).
5. Gregg A. Helvey The Current State of Digital Impressions. *Inside Dentistry*; October 2009; 5(9).
6. Stover J. Successfully Integrating Digital Impressions into the Practice; *Inside Dental Assisting* Nov/Dec 2011; 7(6).
7. Rekow D. computer aided design and manufacturing in dentistry: A review of the state of the art. *J prosthet dent* 1987;58:512-6.
8. Radz G M. making an impression while taking an impression. *catalyst magazine* 2009;(2):39-40.
9. Radz GM. Clinical impression of digital impression. *Dental economics* 2009;99(3).
10. Jason Olitsky Digital Impressioning Making Its Way into Dentistry's Mainstream. *Compendium*; October 2012; 33(9).
11. Anusavice JK in ed. Phillip's Science of Dental Materials. 11th ed. New Delhi:Elsevier;2004.205-254
12. Christensen GJ. Will digital impressions eliminate the current problems with conventional impressions? *J Am Dent Assoc* 2008;139(6):761-763.
13. Christensen GJ. Impressions are changing. *J Am Dent Assoc* 2009; 140:1301-1304.
14. Christensen GJ. The challenge to conventional impressions. *J Am Dent Assoc* 2008;139:347-34
15. Shetty P, Rodrigues S. Accuracy of elastomeric impression materials on repeated pours. *J Indian Prosthodont Soc* 2006;6(2):68-71.
16. Endo T, Finger WJ. Dimensional accuracy of a new polyether impression material. *Quintessence Int* 2006;37(1):47-51.
17. Edward A McLaren. Communicating digitally with the laboratory; Design, impressions, Shade, and the digital laboratory slip. *Inside Dentistry* 2009;4:63-67
18. Christensen GJ. The state of fixed prosthodontic impressions: room for improvement. *J Am Dent Assoc* 2005; 136(3):343-346.

# A case report on the management of an infrabony defect with tetracycline fibres

\* Kadeeja Rushin, \*\* Harish Kumar V.V, \*\*\* Santhosh V.C, \*\*\*\* Sreekanth. P

## Abstract

As a sequelae to periodontitis there occurs different patterns of bone destruction, either horizontal or angular. Angular defects are the ideal candidates for regenerative procedures. Regenerative therapy represents a proven method to improve clinical parameters, periodontal prognosis, and tooth retention. Tetracycline as an adjunct to regenerative procedures has shown to enhance bone fill. Adequate stabilization is inevitable with regard to proper healing.

This case report discusses the management of an intrabony defect with locally delivered tetracycline fibres and splinting on a root canal treated tooth.

KDJ 2016 | Vol. 39 | No. 1 | Pg 55-57

## ► Introduction

Periodontal diseases encompasses a multi-factorial disease process leading to inflammation in the periodontium and alveolar bone loss. The primary etiology of chronic periodontitis is dental plaque<sup>1</sup>. The clinical features include bleeding on probing (BOP), inflammation, pocket formation, and bone loss in advanced cases. The various nonsurgical and surgical therapy aims at removing the etiology, resolution of inflammation and regeneration of lost tissues. Even though the gold standard in periodontal therapy is scaling and root planning (SRP)<sup>2</sup>, it may not result in complete elimination of etiologic factors especially in areas of deep pockets and

furcations. To overcome this, systemic and local delivery of antimicrobials was initiated to enhance SRP<sup>3</sup>.

Regenerative procedures have shown to increase the bone level around a tooth which has a microbial free environment and is also stabilized. Tetracycline as an adjunct to regenerative procedures has shown to enhance bone fill<sup>4</sup>.

This case report describes the regenerative procedure in an infrabony defect with locally delivered tetracycline fibres after an intentional root canal treatment.

## ► Case Report

A 42 year old male patient reported to the out-patient Department of Periodontology, KMCT Dental College, Calicut, with a chief complaint of downward movement of his upper right front tooth and associated mobility since one year. He had noticed an increase in the mobility since 6 months. However there was no associated pain or pus discharge in relation to this tooth. There was spontaneous bleeding from the gums. There was no history of any periodontal abscess. Patient was systemically healthy and had no other associated habits.

After a comprehensive periodontal examination, 11 was the tooth associated with the chief complaint. The Probing Pocket Depth (PPD) and Clinical Attachment Loss (CAL) on the distal

aspect of 11 buccally was 9 mm and 10 mm respectively and on the palatal aspect was 8mm and 10 mm respectively. There was associated grade 2 mobility. PPD and CAL on the mesial aspect of 12 was 8mm buccally and 9 mm palatally. Fremitus test was negative and his general periodontal status was good. A diagnosis of Chronic Localized Periodontitis in relation to 11 and 12 was given. (Fig. 1)

Phase 1 therapy included supra and sub gingival scaling. An intentional RCT was completed in relation to 11 and the patient was re-evaluated after 6 weeks. The clinical parameters namely, PPD, CAL and mobility around 11 remained the same. In phase II a regenerative surgery was planned. The technique of papilla preservation flap, was used where in, the in-corporation of the papilla on the facial flap was achieved through crevicular incisions made around each tooth without splitting the inter-dental papilla, and a semilunar incision made across the palatal aspect of the flap 5mm from the papillary crest. This technique has the advantage of better access both in the palatal and labial region, and overcomes post-operative labial scar formation in the aesthetic zone<sup>5</sup>. (Fig. 2)

Periodontal Plus AB (Advanced Biotech Products, Chennai, India) that is tetracycline impregnated fibrillar collagen that contains 25mg pure fibrillar Type-1 collagen containing 2 mg of evenly

\* Post-graduate student, \*\* Professor & Head, \*\*\* Professor, \*\*\*\* Reader, Department of Periodontology, KMCT Dental College, Manassery, Mukkam  
Corresponding author: Dr. Kadeeja Rushin, Email: rushinkadeeja1@gmail.com

impregnated tetracycline hydrochloride were used. It is available as a strip containing four individually packed sterile packs. Fibers were placed in the defect such that the material fills the depths and curves.

Palatal flap was sutured using an internal horizontal mattress suture, which has the advantage of providing a tension-free flap and a stable support for the area. A non-eugenol periodontal dressing (COE-PAK) was placed.

The patient was put on antibiotics for a period of 5 days and anti-inflammatory drugs for a period of 3 days. Strict oral hygiene instructions were given. The sutures were removed after 10 days. Provisional splinting was done on the palatal aspect of 12, 11 and 21 using ligature wire and light cure composite resin. (Fig. 3)

Tooth mobility has been described as an important clinical parameter for predicting the prognosis of periodontally compromised teeth. The main objective of splinting is to promote healing and increase the patients comfort and function. The main attraction of splinting is its low cost, the possibility of extending life and function of failing teeth. In cases with mobility that cannot be eliminated by selective coronoplasty alone, splinting should be considered as an adjunct to provide additional tooth stability during the surgical and healing phases of regenerative procedures.<sup>6</sup>

Oral hygiene instructions were reinforced and patient was recalled after 3 months 6 months and 9 months. There was a reduction in PPD from 9mm to 4mm along the distal aspect of 11. IOPA shows an improvement in bone fill by 6 months and 9 months. (Fig. 4)

► **Discussion**

The ultimate goal of any periodontal therapy is the control of active inflammation, the arrest of disease progression and the reconstitution of the lost periodontal structures. It has been proven that conventional periodontal therapy did not succeed in predictable tissue regeneration<sup>7</sup>.

As an adjunct to scaling and root planning in management of periodontitis, systemic administration of tetracycline is routinely practiced. Tetracycline is bacteriostatic, it concentrates in periodontal pockets, and its antibacterial efficacy may be prolonged through its ability to bind to both enamel and dentin surfaces. In addition, tetracyclines have recently been shown to suppress collagenase activity in crevicular fluid and inflammatory cells and to inhibit osteoclast mediated bone resorption in vitro<sup>8</sup>.

Systemic administration of tetracycline has adverse effects such as acquired bacterial resistance, drug interaction and drug toxicity which limits its use of systemically. To overcome these shortcomings the concept of controlled release local drug delivery system was developed.

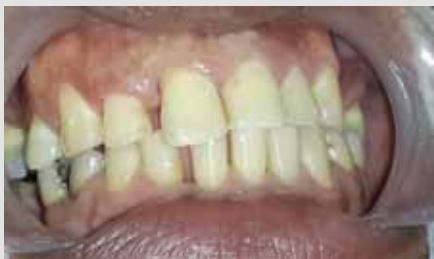

Fig. 1 Pre-op

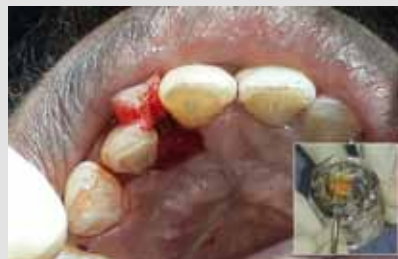

Fig. 2 Papilla preservation flap

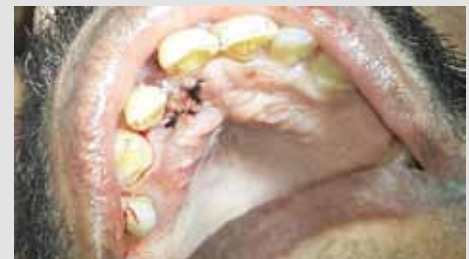

Fig. 3 suturing

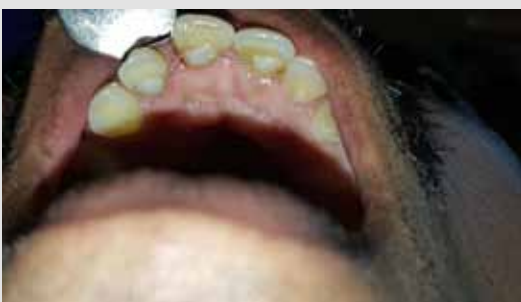

Fig. 4 Palatal composite splint

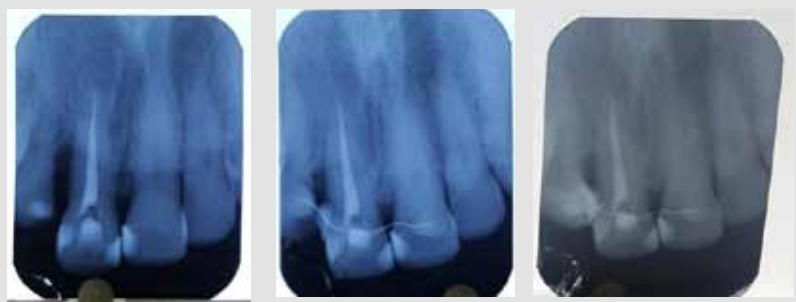

Fig. 5 IOPA at a) baseline b) 6 months c) 9 months

Tetracycline fibres are commonly used as an adjunct to scaling and root planing to decrease inflammation, reduce the pocket depth and bleeding on probing

Novak MJ and Polson<sup>9</sup> compared the effect of tetracycline therapy in combination with periodontal surgical therapy, and showed significant decrease in clinical and radiographic measurements. The probing depth decreased by  $\geq 2$  mm and there was increased height and area of coronal alveolar bone after a three month period.

Local administration of tetracycline finds its usefulness in the regenerative therapy by the support in the findings of Yaffe et al<sup>10</sup> who reported that using tetracycline and bisphosphonate together as root conditioners decreases alveolar bone resorption in rats.

Several studies have proven that open flap debridement alone or along with marrow penetration can increase the alveolar bone height in regions with bone defects. In this case we managed an intrabony defect with open flap debridement combined with packing tetracycline fibres into the defect, keeping in account of the regenerative capacity of tetracycline. Along with the surgical procedures, stabilization of the tooth with splinting further enhanced the bone fill.

### ► Conclusion

The outcome of this case highlights a cost effective regenerative technique, without using bone grafts and GTR

membranes, and also the importance of stabilization of a tooth during its healing phase post surgically for increasing its prognosis.

### ► References

1. Socranksy SS, Haffajee AD. The bacterial etiology of destructive periodontal diseases: Current concepts. *J Periodontol.* 1992; 63: 322-31
2. Cobb C M: Clinical significance of non-surgical periodontal therapy: an evidence-based perspective of scaling and root planing. *J Clin Periodontol* 2002; 29 (Suppl 2): 6-16.
3. Kalsi R, Vandana KL, Prakash S. Effect of local drug delivery in chronic periodontitis patients: A meta-analysis. *J Indian Soc Periodontol.* 2011;15:304-9.
4. John Novak, Alan M. Polson and Steven M. Adair: Tetracycline therapy in patients with early juvenile periodontitis
5. Takei HH, Han TJ, Carranza FA, Jr, Kenney EB, Lekovic V. Flap technique for periodontal bone implants. Papilla preservation technique. *J Periodontol.* 1985;56:204-10.
6. Tarnow DP, Fletcher P. Splinting of periodontally involved teeth: indications and contraindications. *New York State Dental Journal* 1986; 52(5):24-27.
7. Bosshardt D.D, Sculean A. Does periodontal tissue regeneration really work? *Periodontology* 2000. 2009;51: 208-219.
8. Kapoor A, Malhotra R, Grover V, Grover D. Systemic antibiotic therapy in periodontics. *Dent Res J (Isfahan)* 2012;9:505-515.
9. Novak MJ, Polson AM, Adair SM. Tetracycline therapy in patients with early juvenile periodontitis. *J Periodontol* 1988;59:366-372.
10. Yaffe A, Herman A, Bahar H, Binderman I. Combined Local Application of Tetracycline and Bisphosphonate Reduces Alveolar Bone Resorption in Rats. *Journal of Periodontology.* 2003; 74 1038-1042



# Sweetening the burden of diabetes

\* Navia George, \*\*Harish Kumar V.V, \*\*\* Santhosh V.C. \*\*\*\* Sreekanth P,  
\*\*\*\*\* Sameera G Nath, \*\*\*\*\* Shabeer Muhammed

## Abstract

**Introduction:** Diabetes Mellitus is one of the most frequent metabolic disorders. Periodontitis is considered as the sixth complication of diabetes. There is a two way relationship between periodontal disease and diabetes mellitus. Hence, it is necessary to estimate the blood glucose level of periodontitis patients prior to treatment.

**Objective:** To evaluate the correlation between capillary blood glucose levels (CBGLs) and sulcular blood glucose levels (SBGLs) in diabetic patients with chronic generalized periodontitis.

**Methodology:** Diabetic patients with moderate to severe periodontitis were included in the study and subjected to routine clinical periodontal examinations. For estimating random blood sugar level (RBS), blood was collected from gingival sulcus following periodontal pocket probing to a test strip of a glucose self-monitoring device. As a control, capillary blood was taken with a finger-stick. Statistical analysis was performed using Pearson's correlation coefficient and a t-test.

**Result:** It was found that, random blood glucose level were the same in both sulcular blood as well as capillary blood.

**Conclusion:** The result of this study suggests sulcular blood from a routine periodontal examination may be used for diabetes mellitus screening.

**Key-words:** Field cancerization, Squamous cell carcinoma, Second primary tumors

## ► Introduction:

Diabetes mellitus is one of the most frequent metabolic disorders with an estimated global prevalence of 9% among adult aged more than 18 years [WHO 2014], of which nearly half the cases do undiagnosed. Patients with undiagnosed diabetes mellitus are at increased risk for coronary heart disease, stroke and peripheral vascular disease. In addition, recent data indicate that the incidence of the most common type of diabetes i.e., type 2 may be increasing upto 6% per years.<sup>1</sup>

Diabetes mellitus is associated with a wide range of complications such as retinopathy, nephropathy, neuropathy, micro-macro vascular disease, altered wound healing & periodontitis.<sup>2</sup>

Moreover, diabetes and periodontitis seems to interact in a bidirectional manner.<sup>3</sup>

Currently there are strong evidences to suggest that incidence and severity of periodontitis is influenced in part by diabetes mellitus and the level of blood glucose control (Nishimara et al 1998). Hence, periodontal therapy might exert beneficial effects on diabetes control.<sup>4</sup>

## ► Aims & Objectives:

To evaluate the correlation between capillary blood glucose levels (CBGLs) and sulcular blood glucose levels (SBGLs) in diabetic patients with chronic generalized periodontitis.

## ► Materials and methods:

*Inclusion criteria:*

- Patients with chronic generalized periodontitis

- Age between 35-45 years
- Non smokers
- Those consenting to participate in the study

*Exclusion criteria:*

- Patients with systemic illness other than diabetes mellitus
- Pregnancy and lactation

A total of twenty diabetic patients (type 2) having gingival inflammation were taken for the study. Upper anterior teeth irrespective of their probing depths were chosen for glucose measurement as they are ideal for collecting gingival crevicular blood. For each measurement only one site with bleeding on probing was selected. Sites with suppuration were excluded from the study while contamination with saliva was prevented by using gauze and air drying. Blood oozing from the gingival crevicular fluid was used for glucose assessment. In addition, regular finger prick capillary blood was collected and both samples, 3 µl each, were analysed using a glucose self-monitoring device.

The paired t test was used to compare mean scores of two groups and no significant difference in the mean diabetic blood sugar in gingival crevicular and capillary blood was found.

## ► Results:

In this study, it was found that in all the 20 diabetic patients tested, random blood glucose levels were the same in both gingival crevicular blood collected through bleeding on probing as well as capillary blood collected through finger prick. Hence this study indicates

### Paired Samples Statistics

	Mean	N	Std. Deviation	Std. Error Mean	t	p	Remark
SBGL	214.70	20	68.803	15.385	1.35	0.09	Not significant
CBGL	217.00	20	69.526	15.547			

that gingival crevicular blood collected during diagnostic periodontal examination may be an excellent source of blood for glucometric analysis.

#### ► Discussion:

American diabetes association recommends that screening for diabetes should start at the age of 45 years and be repeated every three years in persons without risk factors, and earlier and more often in those with risk factors for diabetes. Moreover, testing at young age or more frequently should be carried out in individuals who are,

- Obese
- Have a first degree relative with diabetes
- Members of a high risk ethnic group
- Hypertensive patients
- Delivered a baby weighing more than 4.05 kg or have been diagnosed with gestational diabetes mellitus
- Had on previous testing an impaired glucose tolerance or an impaired fasting glucose.

Epidemiological data regarding diabetes mellitus coupled with the possible interrelationship between diabetes mellitus and periodontitis suggests that all dentists will encounter patients with diabetes mellitus and clinicians who perform periodontal therapy must be aware and knowledgeable regarding this disease. Since periodontal inflammation with/without the complicating factor of diabetes mellitus is known to produce sample extravasate of blood during diagnostic periodontal

examination, no extra procedure, e.g.: finger puncture with a lancet is necessary to obtain blood for glucometric analysis.<sup>5</sup>

Even in the case of very low gingival crevicular bleeding, a glucose measurement is possible with the used self-monitoring device, due to the low amount of blood (3µl) necessary to perform the analysis. Moreover, technique described is more familiar and less traumatic to the patient than a finger puncture.

#### ► Summary:

The results of the present study indicate that gingival crevicular blood collected during diagnostic periodontal examination may be an excellent source of blood for glucometric analysis. In addition, the technique described is safe, easy to perform, and comfortable for the patient and might therefore help to increase the frequency of diabetes screening in dental offices.

#### ► References:

- 1) Rees TD. Periodontal management of the patient with diabetes mellitus. *Periodontol* 2000 2000; 23: 63-72.
- 2) Kuczek BT, Flemming TF. In-dental-office screening for diabetes mellitus using gingival crevicular blood. *J Clin Periodontol* 2002; 29: 216-18.
- 3) Grossi SG, Jenco RJ. Periodontal disease as a complication of diabetes mellitus. *Ann Periodontol* 1998; 3: 20-9.
- 4) AAP Parameter on systemic conditions affected by periodontal disease. *J Periodontol* 2000; 71: 880-83.
- 5) Parker RC, Isley W. Gingival crevicular blood for assessment of blood glucose in diabetic patients. *J Periodontol* 1993; 64: 666-72.

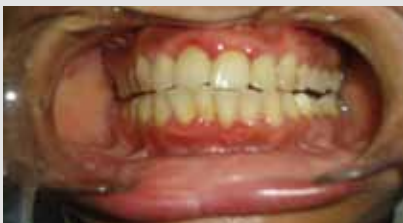

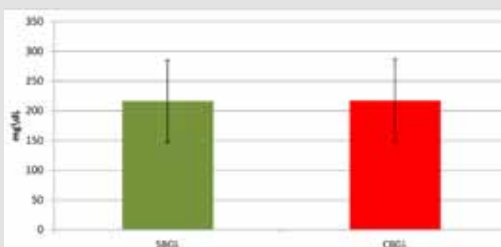
Fig. 1 Chronic periodontitis Patient

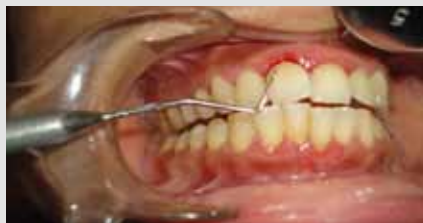

Fig. 2 Bleeding induced on probing

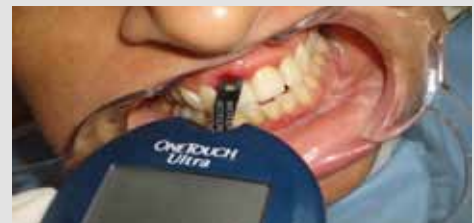

Fig. 3 Glucometric analysis of SBGLs



Graph

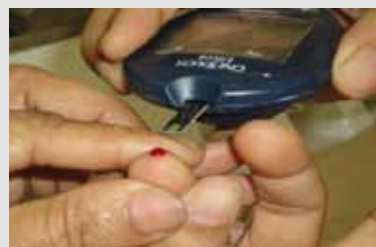

Fig. 4 Glucometric analysis of CBGLs



Fig. 5 Digital readout on Glucometer

# Evaluation of the effectiveness of photodynamic therapy using toluidine blue for microbial reduction in periodontal pockets

\* Anjhana Narayanan, \*\* Harish Kumar V.V., \*\*\* Santhosh V.C., \*\*\*\* Sreekanth P.,  
\*\*\*\* Sameera G Nath, \*\*\*\*\*Shabeer Muhammed

## Abstract

**Background:** Recent preclinical and clinical data have suggested a potential benefit of photodynamic therapy (PDT) in the treatment of periodontitis. However, there are very limited data from controlled clinical trials evaluating the effect of PDT in the treatment of periodontitis. The aim of this study was to evaluate microbiologic effects of the adjunctive use of PDT to non-surgical periodontal treatment.

**Methods:** Twenty patients with chronic periodontitis were randomly treated with scaling and root planing followed by a single episode of PDT (test) or scaling and root planing alone (control). Full-mouth plaque score (FMPS), full-mouth bleeding score (FMBS), probing depth (PD), gingival recession, and clinical attachment level (CAL) were measured at baseline. Microbiological analysis was based on semiquantitative assessment of the colony forming units on blood agar.

**Results:** At baseline the intergroup comparison of the demographic parameters were statistically insignificant. Intergroup comparison of the bacterial growth before and after intervention was statistically significant with a p value < 0.05.

**Conclusion:** With a significant reduction in the subgingival microbiota, this study suggests that aPDT can be successfully used as an adjunct to scaling and root planing.

## ► Introduction:

The etiology of periodontitis is multifactorial, which results in therapeutic difficulties. Bacteria (periodontopathogens), considered to be one of the main etiological agents, grow in biofilms, and are beyond the reach of antimicrobial chemical agents. The anatomical complexity of tooth roots provides niches for bacterial deposits, making eradication of periodontopathogens more difficult both mechanically and chemically. Also some periodontopathogens (e.g. *Aggregatibacter actinomycetemcomitans*) can penetrate into and persist in epithelial cells of the periodontal pockets and outer gingiva thus avoiding host immunity and conventional antimicrobial drugs<sup>1</sup>. Moreover, there is also a problem of increasing bacterial resistance developing to systemic antibiotics. Conventional treatment such as scaling and root planing (SRP) does not completely eliminate periodontal pathogens, especially in deep periodontal pockets; moreover, it does not prevent this microorganism from penetrating into periodontal tissue. Finally, this predisposes the periodontal pockets to re-colonization, disease relapses and maintains the chronic nature of the disease<sup>2</sup>.

These above-mentioned issues justify the need for alternative antibacterial therapeutic strategies. One of them is photodynamic therapy against microorganisms called antimicrobial photodynamic therapy.

Photodynamic therapy (PDT), also called photoradiation therapy, phototherapy, or photochemotherapy, was introduced in medical therapy in 1904 as the light-induced inactivation of cells, microorganisms, or molecules<sup>3</sup>. PDT involves the combination of visible light, usually with a diode laser and a photosensitizer. The photosensitizer is a compound that is capable of absorbing light of a specific wavelength and transforming it into useful energy<sup>4</sup>.

The action mechanism of PDT can be briefly described as: upon illumination, the photosensitizer is excited and converted from the ground state to the triplet state. The triplet state enables the interaction of the excited photosensitizer with the surrounding molecules. The cytotoxic product, usually singlet oxygen, has a short lifetime in biological systems (<0.04µs) and, also have a short radius of action (0.02 µm). Because of the limited migration of the

single oxygen from the site of its formation, sites of initial cell damage from PDT are closely related to the localization of the sensitizer, thus making it ideal for local application of PDT, without endangering distant molecules, cells or organs.

Toluidine blue O(TBO) is cell membrane active photosensitizer, which can absorb red laser light and is bactericidal for many oral bacteria. It is also shown in previous studies that light dose required to kill bacteria treated with TBO is far lower than that causing toxicity to cultured keratinocytes and fibroblasts.

The efficacy of any antibacterial substance can be evaluated by the qualitative and quantitative reduction in the bacteria to which the agent is subjected. Even though many methods of assessing the bacteria flora exists the gold standard still remains to be bacterial culture.

Thus based on these facts, this study aims to evaluate the effectiveness of photodynamic therapy using toluidine blue for microbial reduction in periodontal pockets

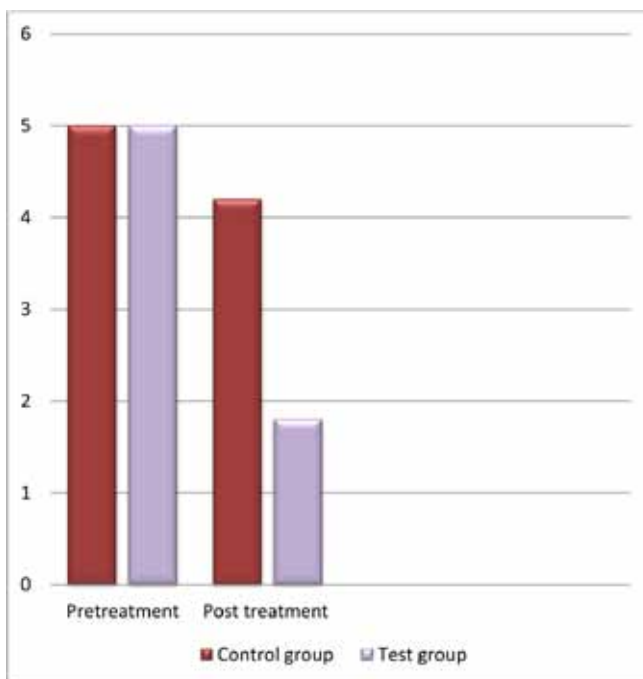
**Materials and Methods:**

**Subject Selection:** Study was conducted on patients diagnosed with chronic periodontitis, attending the Out Patient Division of Department of Periodontology, KMCT Dental College, Calicut. Twenty subjects with at least two sites with probing pocket depth of 5-7mm were selected for the study and the sites were randomly divided into two groups which were either treated with SRP using hand instruments and sonic instrumentation followed by a single episode of PDT(test group) or SRP using hand instruments and sonic instrumentation alone(control group). All patients were recruited according to the following criteria: (1) Age 30 -55 years, (2) Systemically healthy, (3) Remaining teeth ≥20, (4) at least three sites with periodontal pocket depth (PPD) of 4-7 mm in 3 or more quadrants (5) Signed inform consent form. The exclusion criteria consisted of: (1) Smoking or alcoholism, (2) Pregnancy or lactating, (3) Consuming antimicrobial drugs (ie, antibiotics) in the last 3 weeks, and (4) History of periodontal surgery in past 6 months(5) patients not allergic to toluidine blue.

The following clinical parameters were assessed Probing depth (PD), Gingival Recession (GR) & Clinical attachment level (CAL) full-mouth plaque score (FMPS), full-mouth bleeding score (FMBS). All clinical measurements were made at four sites per tooth: mesio-facial, mid-facial, disto-facial, palatal/lingual by the same examiner. The cement-enamel junction (CEJ) was used as the reference point.

Parameter	Test Group (SRP+PDT) (n = 10)	Control Group (SRP) (n = 10)	P Value
Age (years; mean – SD)	43.7 – 7.3	47.3 – 8.8	0.289
CAL (mm; mean – SD)	4.1 – 0.5	4.5 – 1.0	0.219
PD (mm; mean – SD)	3.7 – 0.5	3.6 – 0.6	0.577
REC (mm; mean – SD)	0.5 – 0.4	1.0 – 0.8	0.051
FMPS (%; mean – SD)	58 – 24	62 – 14	0.631
FMBS (%; mean – SD)	54 – 16	59 – 21	0.501
Sites with PD 4 to 7 mm (n; mean – SD)	47 – 14	49 – 25	0.812
Sites with PD ≥7 mm (n; mean – SD)	9 – 9	8 – 7	0.740

**Table 1:** The baseline characteristics of the 20 participants



**Graph 1:** Graph comparing the pre and post treatment results in microbial flora of test and control group.



**Study Design:** The study performed was a split mouth study. Treatment allocation was performed by a lottery method. Culture samples were collected from both test and control site using paper points and transferred to anaerobic transport medium. Following this supragingival calculus was removed with sonic instrumentation, and subgingival instrumentation for test and control groups was performed until the operator believed that the root surfaces were adequately debrided and planed. Randomization was performed immediately following the completion of instrumentation

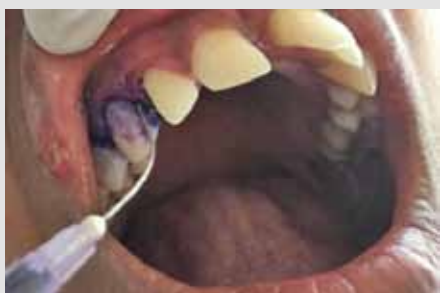**Laser Therapy/Photodynamic Therapy:** In the test group, the photosensitizer liquid that is 1% toluidine blue dye was applied with a blunt needle to the instrumented sites, starting from the apical end of the pocket and moving coronally to avoid entrapment of air bubbles (Fig. 1). One minute later, all pockets were thoroughly rinsed with sterile saline to remove the excess photosensitizer. Immediately after rinsing, the diode laser, with 810 nm wavelength and 0.8 W of power output, equipped with a probe tip, was placed at the depth of the pocket and moved circumferentially around the tooth for 30 seconds, according to the manufacturer’s instructions (Fig. 2). Post operatively oral hygiene instructions were reinforced and patients were not administered antibiotics.

**Samples for Microbiological analysis:** The procedure was performed with a sterile paper point which was inserted in the bottom of the pocket for 30 seconds (Fig. 3), after isolating the selected sites using cotton rolls. The paper points from the test and control site was streaked on a sheep blood agar plate such that one half of the plate received samples from the test site and the other half from the control site (Fig. 4). Pre and post treatment samples were collected from both sites on the same day.

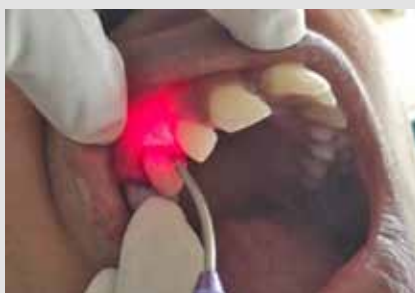Microbiological investigation was done in the Dept. of Microbiology, Aster Malabar Institute of Medical Sciences, Calicut. The samples were incubated for 48 hours and further subcultured to semi quantitatively assess the microbial colonies. Assessment was based by counting the number of colony forming units of microbial colonies(cfu)<sup>5</sup>.

Bacterial levels were expressed semi quantitatively as (no growth = 0; scanty = 1; moderately scanty = 2; moderate = 3; moderately heavy 4; heavy =5).

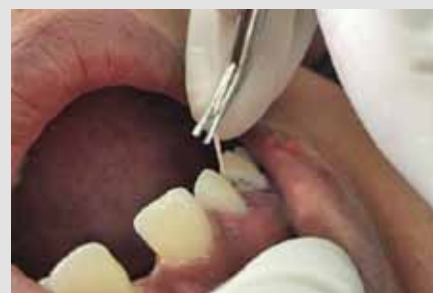**Statistical Analysis** The statistical analysis was performed using SPSS software. A subject-level analysis was performed for each of the parameters were analyzed with the Mann-Whitney U test. Differences were considered statistically significant when the P value was <0.05.



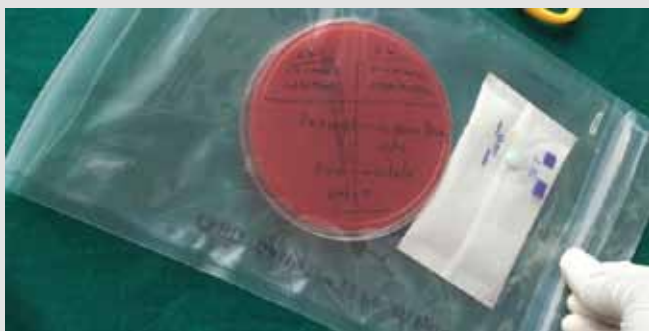**Fig. 1:** 1% toluidine blue dye was applied with a blunt needle to the instrumented sites,



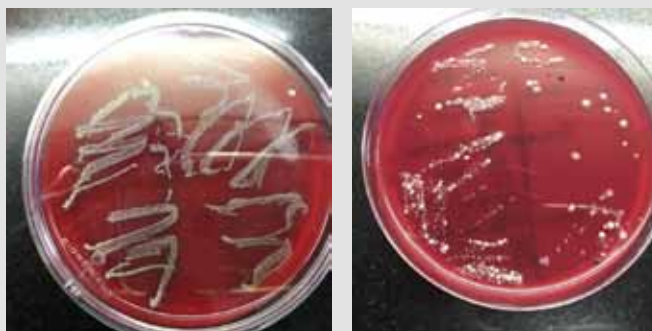**Fig. 2:** Diode laser, with 810 nm wavelength and 0.8 W of power output placed at the depth of the pocket



**Fig. 3:** Sterile paper point which was inserted in the bottom of the pocket to obtain microbial samples



**Fig 4:** Samples streaked on blood agar plates



**Fig. 5** Comparison between the blood agar plates of pre and post treatment samples from the test and control site.

### ► Results :

All patients enrolled completed the study. No adverse effects, such as discomfort, burning sensation, or pain related to the laser irradiation, were reported by any of the subjects. The baseline characteristics of the 20 participants are displayed in Table 1. The mean age was 43.7 – 7.3 years for the test group and 47.3 – 8.8 years for the control group. None of these demographic parameters showed a statistically significant difference between the groups. After incubation of the subcultures for 48 hours in anaerobic conditions, values of the CFUs on the plates were determined by the semiquantitative method used for determining bacteriuria<sup>6</sup>. The CFUs from the test and control sites of both pre and post treatment samples were compared (Graph 1), (Fig. 5 & 6) and from the results it was inferred that, in all the cases

- there was slight reduction in the bacterial count at the control site ie CFUs were recorded heavy in pretreatment samples and moderate- heavy in post treatment samples.
- there was significant reduction in the bacterial count at the experimental site, ie CFUs were recorded heavy in pretreatment samples and moderate- scanty in post treatment samples. Results of the study was statistically significant with a p value <0.05.

Thus from the results of the study we can conclude that photodynamic therapy can be used an effective adjunct to scaling and root planing in reducing the microbial load in periodontal pockets.

### ► Discussion :

Photodynamic therapy is a novel therapeutic approach for eradicating pathogenic bacteria in periodontal disease. Inactivation of microorganisms using photodynamic therapy has been defined as either antimicrobial photodynamic therapy (aPDT), photodynamic antimicrobial chemotherapy (PACT) or photodynamic disinfection. A number of studies have shown that TBO is phototoxic to several planktonic gram-positive and gram-negative bacteria<sup>7</sup>. The photodynamic efficacy of TBO

has also been demonstrated in several oral biofilm models<sup>8</sup>. Photodynamic therapy eliminated approximately 63% of bacteria in the planktonic phase, whereas only 32% of bacteria in biofilms, which derived from the same plaque samples<sup>9</sup>. However, bacterial eradication from dental plaque-derived biofilms is still at a lower level compared to the planktonic condition. The study by Fontana et al<sup>10</sup> confirmed this fact. In this study we have investigated the antimicrobial efficacy of photodynamic therapy in reducing microbial load as an adjunct to scaling and root planing in patients with chronic periodontitis.

The results of this study has shown that it is possible to kill subgingival microflora in the gingival crevice using topically applied toluidine blue and red light from a diode laser without causing any detectable damage to the adjacent tissues. There was considerable reduction in density of the black pigmented colonies in the culture plates of sites treated with aPDT.

Wakayama, Y et al showed TB to be an effective photosensitizer which is capable of damaging cell membranes during aPDT, thus leading to the eradication of bacterial cells<sup>11</sup>. Zanin et al<sup>12</sup> used TB and irradiation of 85.7 J cm<sup>22</sup> to kill in vitro-generated single-species biofilm of *S. mutans* and other oral streptococci. The elimination rates of the bacteria were found to vary between 95 and 99.9 %. Bhatti et al. found that 100% killing of *P. gingivalis* organisms could be achieved with 25 µg of toluidine blue per ml and 4.4 J of red light.

Recently, Novaes et al. investigated changes occurring in the subgingival microbiological composition of subjects with aggressive periodontitis treated with antimicrobial photodynamic therapy in a single episode or SRP. This trial indicated that aPDT is more efficient in reducing the presence of *Aggregatibacter actinomycetemcomitans* than SRP<sup>13</sup>. On the other hand, SRP limited the number of periodontal pathogens of the Red Complex more effectively than aPDT. Because of the fact that aPDT and SRP affect different species, it is suggested that both methods be combined to gain better results in non-surgical treatment of aggressive periodontitis<sup>9</sup>.

Regarding the mechanism of aPDT, a recent proteomic approach by Dosselli et al.<sup>14</sup> revealed that aPDT delays the growth of bacteria, and reduces the capacity of bacteria for glucose consumption. Combined, the bacterial killing effect and the retardation of bacterial growth with aPDT could reduce plaque deposition on teeth. Nonetheless, the negative aspects of the clinical use of aPDT should be considered. Some reports have noted tooth staining with TBO<sup>15</sup> however, residual staining of teeth and gingival tissue with TBO after the aPDT procedure was not visible, and did not present a problem in this clinical trial.

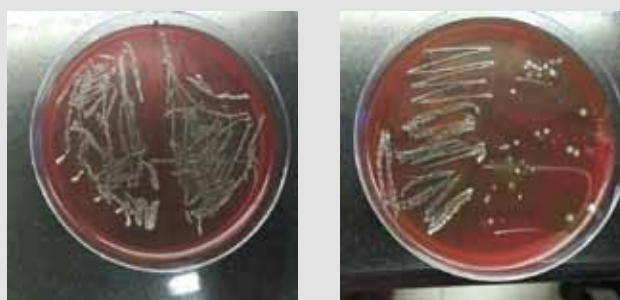

Fig. 6: Comparison between the blood agar plates of pre and post treatment samples from the test and control site.

► **Conclusion**

From this study we can conclude that using PDT is less traumatic & quicker in the treatment of inflammatory periodontal diseases. PDT offers numerous advantages, particularly in avoiding emergence of antibiotic resistance species, requiring less technical skills & reducing operating time in comparison to manual scaling and root planing.

► **References :**

1. Lamont R.J., Yilmaz O. In or out: the invasiveness of oral bacteria. *Periodontol.* 2000, 2002; 30: 61-69
2. Ardila C.M., Granada M.I., Guzmán I.C.: Antibiotic resistance of subgingival species in chronic periodontitis patients. *J. Periodontal Res.*, 2010; 45: 557-563
3. Von Tappeiner H, Jodlbauer A. On the effect of photodynamic (fluorescent) substances on protozoa and enzymes (in German). *Deutsch Arch Klin Medizin* 1904;39:427-87
4. Sharman WM, Allen CM, van Lier JE. Photodynamic therapeutics: Basic principles and clinical applications. *Drug Discov Today* 1999;4:507-517.
5. Bowler P, Duerden B, Armstrong D. Wound microbiology and associated approaches to wound management. *Clin Microbiol Rev.* 2001;14(2):244-69.
6. Ruth M Myers and Grace Koshi, *Diagnostic Procedures in Medical Microbiology and Immunology/Serology*, pg 61, 62; 1982, CMC Vellore.
7. Tang, H. M., M. R. Hamblin, and C. M. Yow. 2007. A comparative in vitro photoinactivation study of clinical isolates of multidrug-resistant pathogens. *J. Infect. Chemother.* 13:87-91.
8. Zanin, I. C.M. M. Lobo, L. K. Rodrigues, L. A. Pimenta, J. F. Höfling, and R. B. Gonçalves. 2006. Photosensitization of in vitro biofilms by toluidine blue O combined with light-emitting diode. *Eur. J. Oral Sci.* 114:64-69.
9. Soukos N.S., Ximenez-Fyvie L.A., Hamblin M.R., Socransky S.S., Hasan T. Targeted antimicrobial photochemotherapy. *Antimicrob. Agents Chemother.*, 1998; 42: 2595-2601
10. Fontana C.R., Abernethy A.D., Som S., Ruggiero K., Doucette S., Marcantonio R.C., Boussios C.I., Kent R., Goodson J.M., Tanner A.C., Soukos N.S. The antibacterial effect of photodynamic therapy in dental plaque-derived biofilms. *J. Periodont. Res.*, 2009; 44: 751-759
11. Wakayama, Y., Takagi, M. & Yano, K. (). Photosensitized inactivation of E. coli cells in toluidine blue-light system. *Photochem Photobiol* 1980;32: 601-605
12. Zanin, I. C., Lobo, M. M., Rodrigues, L. K., Pimenta, L. A., Höfling, J. F. & Gonçalves, R. B. (). Photosensitization of in vitro biofilms by toluidine blue O combined with a light-emitting diode. *Eur J Oral Sci* 2006;114: 64-69
13. Novaes A.B.Jr., Schwartz-Filho H.O., de Oliveira R.R., Feres M., Sato S., Figueiredo L.C.: Antimicrobial photodynamic therapy in the non-surgical treatment of aggressive periodontitis: microbiological profile. *Lasers Med. Sci.*, 2012; 27: 389-395
14. Dosselli R, Millioni R, Puricelli L, Tessari P, Arrigoni G, Franchin C, Segalla A, Teardo E, Reddi E: Molecular targets of antimicrobial photodynamic therapy identified by a proteomic approach. *J Proteomics* 2012, 77:329-343.
15. Williams JA, Pearson GJ, Colles MJ, Wilson M: The photo-activated antibacterial action of toluidine blue O in a collagen matrix and in carious dentine. *Caries Res* 2004,38(6):530-536.

## OBITUARY



Thrissur IDA mourns the sad demise of Dr. Manoj Davis Akkara aged 46 years (D.O.B.:19.12.1969) following brief period of hospitalization at Aster Medicity Ernakulam. He is survived by his wife Mrs. Melissa Manoj and daughter Merlin Manoj. Dr. Manoj graduated from Rajas Dental College, Vadakankulam, Thirunelveli Dist., Tamil Nadu in the year 1994 December. He set up practice at

Olarikkara, Thrissur. He was a regular and active member of IDA and had held various executive posts in committee in the past. A very well loved by all, jovial and good natured, he will be missed sorely. May his soul rest in peace. All of the Thrissur IDA members and nearby branches turned up at the funeral to express the deep grief and pay homage.



# Management of Excessive Gingival Display

\*Jyotsna J., \*\*Devisree Naveen, \*\*Teenu Abraham, \*\*\*Padmakumar T P, \*\*\*\*Nandakumar K.

## Abstract

**Introduction:** Gummy smile due to excessive gingival display always makes a normal person conscious while smiling. The treatment of choice in this type of cases with excess can be corrected by orthognathic surgery along with orthodontic treatment. It can otherwise be treated by a lip – repositioning procedure; a less invasive approach.

**Case Presentation:** This is a case report of a female patient who was unsatisfied with her smile and states that it is compromising her self – esteem due to excessive gingival display and not willing for orthognathic surgery; which is corrected by lip repositioning.

**Conclusion:** In patients with a gummy smile who are apprehensive of undergoing orthognathic surgery, lip repositioning can be a reassuring treatment option.

**Key words:** Smile, Gummy smile, smile line, lip repositioning, orthognathic surgery, gingivectomy.

KDJ 2016 | Vol. 39 | No. 1 | Pg 65-67

## ► Introduction

“Beauty lies in the eyes of the beholder” keeping this old saying in mind, smile corrections can be done in patients with esthetics concerns. Excessive gingival display, commonly referred to as ‘gummy smile’ is a major hurdle in overall personality of an individual. What constitutes a pleasant smile varies from person to person, but usually depends on the

extent of gingival exposure. Recently the dental literature has focused into various treatment modalities in the correction of gummy smile. When a person smiles, the entire crowns of maxillary central incisors and 1 mm of pink attached is visible.

Gummy smile due to excessive gingival display always makes a normal person conscious while smiling, especially when the problem is related with female patients who are more esthetically conscious than males (Geron & Atalia 2005). “Excessive gingival display”, also called gummy smile is one of the several developmental or acquired deformity that manifest in the periodontium (Armitage 1999). Gummy smile is seen due to improper relation between gingival tissue and the tooth, with gingival tissue in excess and tooth portion in a small amount, with a prevalence of 7% in young adults males & 14% of young adult females (Tjan et al 1984; Diamond O, Journ. esthet dent 1996). It can be a source of embarrassment for some patients. Gummy smile is governed by various etiological factors, for example jaw deformities, which cause excessive gingival display and require a orthognathic surgery. This occurs due to excessive increased vertical height of maxillary arch. Orthognathic surgery is usually required to treat vertical maxillary excess. A wedge of maxilla is removed and maxilla is positioned in a

pre determined level. In some cases, only mandibular osteotomy will be enough to obtain a stable occlusal relationship. The orthognathic surgery is a complicated procedure and requires team work with hospitalization and general anesthesia and entails significant discomfort, while lip repositioning is innovative and effective, less time consuming and is performed under local anesthesia. Short or hyper active upper lip, altered passive eruption, vertical maxillary excess, dento alveolar extrusion etc affects the gummy smile. Causes like delayed eruption and tooth malpositioning can be predictably treated with resective surgery and orthodontics<sup>1</sup>. When the gingiva demonstrates a healthy appearance and a reduced crown length of the anteriors; which cannot be completely explained by incisal edge wear, a differential diagnosis of altered passive eruption is made and one of the treatment modality is the crown lengthening<sup>2</sup>.

In dento alveolar extrusion, mainly due to the over eruption of maxillary anterior teeth and can be corrected by moving the over-erupted teeth into the original position. This can be accomplished either by orthodontics or with a segmental osteotomy followed by long term retention.

## Esthetic Periodontal Surgery

If the osseous level is appropriate, if there is more than 3 mm of tissue

\*PG Student, \*\*Senior Lecturer, \*\*\*Professor, \*\*\*\*Professor and HOD, Department of Periodontics, Azeezia College of Dental Sciences and Research, Meeyannoor, Kollam. Corresponding Author: Dr. Jyotsna. J. E-mail: jyotsna.j255@gmail.com



from bone to gingival crest and if it is determined that an adequate zone of attached gingiva will remain after surgery, a gingivectomy is indicated. If the diagnostic procedures reveal osseous levels approximating the CEJ, a gingival flap with osteotomy is indicated. If the gingival heights of the anterior teeth are asymmetric, the initial incision should be a gingivectomy-type incision so that the final tissue contour will be symmetric. If the preoperative tissue contours are symmetric, a sulcular incision can be used and the flap apically repositioned. The inferential incision should always be a sulcular incision, leaving the papilla totally intact interproximally<sup>3</sup>.

► **Case report**

A 23-year-old female patient with a complaint of unaesthetic smile with localized gingivitis, and maxillary gingival excess resulting in a gummy smile reported to our department of periodontics (Figs. 1 & 2). The patient has been undergoing orthodontic treatment since 3 years for bimaxillary protrusion but she felt that smile was not acceptable aesthetically. On clinical examination, extraorally face was found to be bilaterally symmetrical with incompetent lips (Fig. 3). Intraorally, a

moderate gingival display was seen during smiling, which extends from maxillary right second premolar to maxillary left second premolar. She approached in an outside clinic and was advised for orthognathic surgery.

On clinical examination, she was found to have a vertical maxillary excess & a diagnosis of moderate vertical maxillary excess with hypermobility of upper lip was made. A treatment plan involving surgical crown lengthening and lip repositioning was drawn up and presented to the patient. After obtaining approval of the treatment plan and informed consent, phase 1 periodontal therapy was performed to prepare the tissues for surgery. One week later, the patient was recalled for surgery. Bone sounding was done under anesthesia, before starting the excision, to clearly establish the position of the bone. Extra oral and intra oral antiseptics was performed with 2% chlorhexidine solution.

After acquiring sufficient anaesthesia and asepsis, Inverse bevel gingivectomy (Fig. 4) was done, and the flap rose for debridement and curettage. Hemostasis was performed using

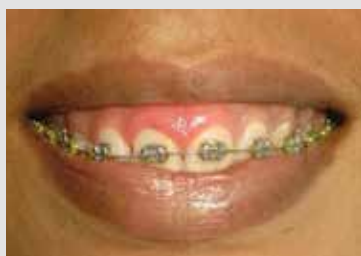

Fig 1: Pre OP

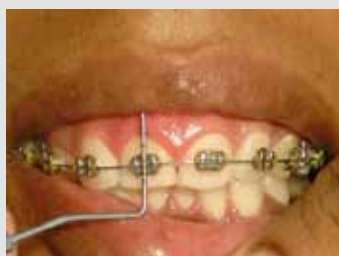

Fig 2: Distance from the lower lipline to the gingival margin

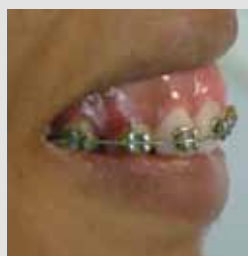

Fig 3: Lateral view

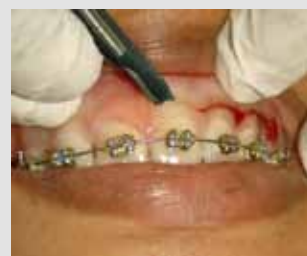

Fig 4: Gingivectomy

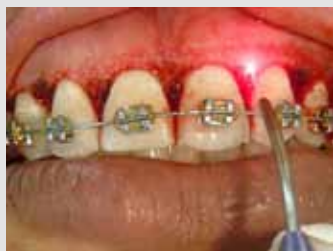

Fig 5: Hemostasis using laser therapy

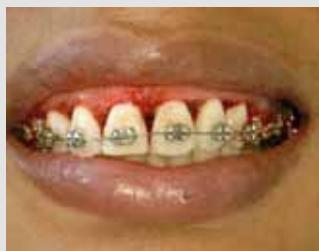

Fig 6: After gingivectomy

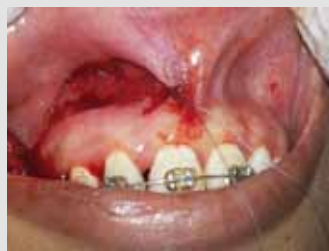

Fig 7: Lip repositioning

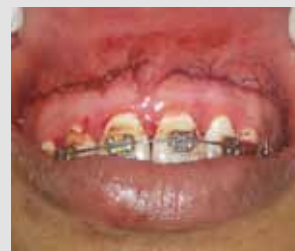

Fig 8: Continuous interlocking suture

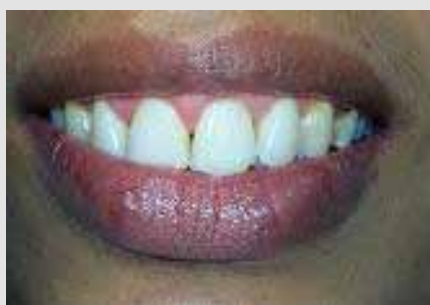

Fig 9a: Post OP one month

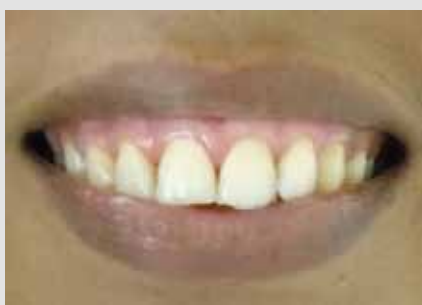

Fig 9b: Post OP third month

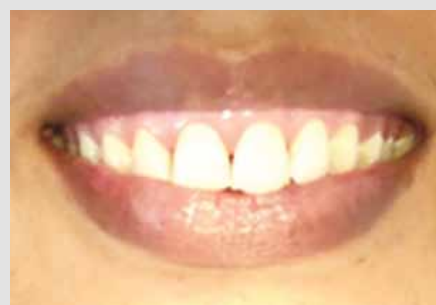

Fig 9c: Post OP sixth month

laser therapy (Fig. 5 and 6). Another appointment after 7 days was given to perform the lip repositioning surgery. Here, we performed a modification of the original Rubinstein and Kostianovsky technique, where the midline maxillary labial frenum was not excised. This modification was put forward in order to facilitate maintaining the position of the labial midline, keeping it intact and to reduce the morbidity associated with the procedure.

The surgical area was demarcated and the partial thickness horizontal incision was started at the mucogingival junction, beside the labial frenum; extending from right first pre molar to the central incisor on both sides. A second parallel incision was made at the facial mucosa at approximately 13-15 mm distance from the first incision. The two incisions were connected to create an elliptical outline. The epithelium was excised leaving the underlying connective tissue exposed (Fig. 7).

The parallel incision lines were approximated with interrupted stabilization sutures at the midline and other location along the borders of the incision to ensure proper alignment of the lip midline with the midline of the teeth and then a continuous interlocking suture was used to approximate both flaps. Sutures were resorbable in nature (Fig. 8). Postoperative instructions included placing ice packs over the upper lip for several hours, to consume soft foods, limited facial movements for one week, no brushing around the surgical site for 14 days. The patient was advised to rinse gently with 0.12% chlorhexidine gluconate twice daily for two weeks. Postoperative pain was managed with analgesics.

### ► Discussion

The procedure restricts the muscle pull of the elevator lip muscles by shortening the vestibule, thus reducing the gingival display when smiling. In our experience this procedure is safe, predictable with minimal risk or side effects, and is an alternative treatment modality in esthetic treatment. One objective of restorative dentistry is to create ideal esthetics for the patient's smile., when the patient smiles, if the upper lip moves in an apical direction and exposes the dentition and excessive gingiva, then surgical lip repositioning may be utilized to reduce the labial retraction of the elevator smile muscle and minimize the gingival display. This procedure was first described in the plastic surgery literature in 1973.

A diagnosis of delayed eruption, tooth malpositioning, and excessive skeletal deformities might best be treated by crown lengthening, orthodontics, and/or orthognathic surgery. Lip repositioning is suggested as an additional treatment modality for patients with lip hypermobility exposing undesired gingivae in a smile. In this case the patient preferred a less invasive procedure to address her chief complaint. The site

healed uneventfully and loose sutures were removed over a period of four weeks. The remaining sutures were left to be resorbed. The patient was pleased with the esthetic outcome and informed consent for a lip repositioning procedure was obtained.

Some authors advocated performing myoectomies to detach the smile muscle attachment. Variation in the technique was also reported. Lip repositioning was most commonly used as a plastic surgical procedure and is rarely used as a dental procedure. Another method to prevent reattachment of the smile muscles is to use an alloplastic or autogenous separator (Ellenbogen 1984). This spacer is placed with nasal approach between the elevator muscles of the lip and the anterior nasal spine, and thus prevents the superior displacement of the repositioned lip. Lip repositioning has also been performed in conjugation with rhinoplasty (Cachey-Velasquez, 1992). Lip repositioning procedure is contraindicated in the cases of vertical maxillary excess, inadequate attached gingiva, short lips etc. complications like paraesthesia, mucocele, transient paralysis were also been reported<sup>4</sup>.

Rubenstein and Kostianovsky first described a technique known as 'Lipstat' in 1973. The largest study to evaluate the results of lip repositioning technique was conducted by Silva et al. Later Jacobs and Jacobs conducted a study by offering the patients a reversal trial before the surgical procedure and they sutured the labial mucosa to the mucogingival junction. A supportive treatment about 6 months to 1 year is needed to evaluate the long-term outcome. In the above reported clinical case, includes the photograph of 6 months and the results appear stable. The patient is still under the maintenance phase<sup>5</sup>.

### ► Conclusion

With correct diagnosis and appropriate therapy for excessive gingival display, dental esthetics can be improved, as demonstrated by the case reported here. The disciplines of oral surgery, orthodontics, periodontics and restorative dentistry all play a role in the treatment of excessive gingival display.

### ► References

1. Ezquerria F, Berrazueta MJ, Ruiz-Capillas A, Arregui JS. New approach to the gummy smile. *PlastReconstrSurg* 104:1143-1150;
2. Dayakar MM, Gupta S, Shivananda H. Lip repositioning: An alternative cosmetic treatment for gummy smile. *J Indian SocPeriodontol* 2014;18:520-3.
3. Vig RG, Brundo GC. The kinetics of anterior tooth display. *J Prosthet Dent* 39: 502- 504, 1978.
4. Ari Rosenblatt Lip repositioning for reduction of gingival display: *QuintessenceVol*: 26, no 5,2006.
5. Monish Bhola *Quintessence*, volume 5,no.4, 2015.

# A cross sectional survey on the utilization of scientific journals among staffs and students of Dental Colleges in Kerala

\* Civy V. Pulayath, \*\* Rasmi George

## Abstract

**Aim:** To describe a hybrid technique Dental journals are the most efficient tool to bring about scientific research data, findings of clinical studies and interesting case reports to both the professionals and dental students. This study aims to measure the awareness and utilization of such journals by the students and professionals.

KDJ 2016 | Vol. 39 | No. 1 | Pg 68-69

### Introduction

Dental journals bring scientific research, interesting case reports, newer techniques and opinions to a wide audience of dental professionals around the globe in order to improve the clinical outcome of dental treatment. A query was done using a cross sectional questionnaire survey to assess the utilisation of this scientific literature in dental educational institutions.

### Aim

1. To evaluate the level of utilization of dental journals among students and staffs of dental colleges in Kerala.

### Objectives

1. To know whether avenues for utilization of journals were created in dental institutions.
2. To know whether language act as a barrier in understanding the concepts explained in the journals.

### Methodology

The investigation was conducted using a cross sectional questionnaire survey among staffs and students of dental colleges in Kerala. A quota sampling methodology was used to collect data from 500 subjects (250 Interns and 250 Staffs). Separate questionnaires with 20 closed ended questions were used for the two groups.

### Results

75.2% (188) of the students confessed that they were not interested in reading journals, while 83.6% of the teaching staff remarked that they don't use dental journals as intense as they did it during their study period. Majority of them agreed that reading journals

necessary for dental professionals mainly to get updated (493 out of 500).

Lack of adequate time prevents 44% of students and 60% of professionals from reading journals. Majority of students prefer to read Indian journals while staffs make use of international journals. In case of students, library is the main source for reading journals but lack of adequate journals in library is the main problem. At the same time staffs also access subscriptions and internet.

Journal presentation exercise for interns was found to be less prevalent in very few institutions. 92% (230) of teachers substantiated that many ideas from journals influenced their studies

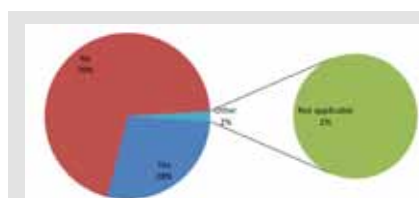


Fig.1: Difficulty in understanding statistical concepts in articles




Fig 2: Frequency of reading journals

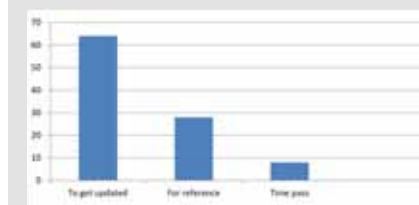


Fig 3: Purpose of reading journals




Fig 4: Academic practice of dental staffs

\* Reader, \*\* Intern, Dept of Public Health Dentistry, Al Azhar Dental College, Thodupuzha. Corresponding Author: Dr Civy V.Pulayath, Email: publicealthdentist@gmail.com

as well as career, while 60% of students were opponent to it. Most (85.2%) of them mentioned that the innovative concepts explained in the journals seem to be difficult to understand. 12% of them responded that plagiarism is the major issue affecting quality of scientific publications. 28% of dental professionals made an opinion that sometimes statistics is a barrier in understanding the concepts explained in the journals. It was shocking to find that only 12% of dental professionals had published their PG dissertation in journals. Most of them (88%) commended that they came across new dental products through Journals. 64 % dental professionals used to quote finding of studies from journals for their colleagues and patients. Very few (9 among 250) of them had their own international publications. When asked about impact factor, ISSN No;, P value, power 73.56% of them were unaware about these technical terms in journals.

#### ► **Recommendations**

1. Article publication credit points must be made mandatory for staff promotion.
2. Journal presentation should be made a compulsory activity for interns.

3. In order to draw more students into reading journals the college libraries should be well fledged with a variety of journals.
4. Concepts and statistical analysis explained in the journals should be simplified to make it easy for every one.

#### ► **Conclusion**

The effective utilization of dental journals among students and staffs of dental colleges in Kerala were found to be minimal. Lack of time, inadequate access to journals, difficulty in understanding the concepts explained in the journals were the common reasons found. Role of scientific journals in academic curriculam should be made more significant. It is the responsibility of the teaching staffs to make the students aware of the necessity of reading journals.

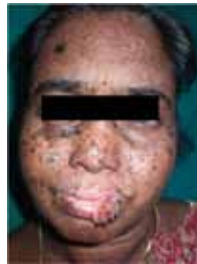#### ► **References**

1. Leyla Tercanlioglu (2004), Post graduate students use of Reading strategies in L1 and ESL contexts.
2. Pei –Hsuan Hsieh. The instructional effect of online reading strategies and learning styles on student academic achievement.
3. Reisine S.Litt.M. Scholary articles for use of dental journal, social and psychological theories and their use for dental practice.



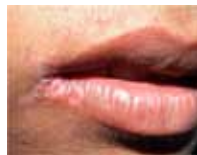\* Jayanthi, \*\* Varun B.R.

1. A 40 year old female reported with a growth on the lower lip. On examination, proliferative growth was noted on left side of lower lip along with pigmentation of skin, especially in the sun exposed areas. History revealed that the pigmentation of skin started during childhood and the lip lesion was present for the past 6 months. Histopathological examination of the lip lesion revealed squamous cell carcinoma. Which of the following genodermatosis does the patient have?



- a. Dyskeratosis congenita
- b. Pachnychia congenita
- c. Xeroderma pigmentosum
- d. Peutz-Jegher syndrome

2. An 18 year old female patient complained of painful ulcers on the lower lip. On examination, multiple small ulcers were noted on the right side of lower lip with areas of brown crustation. History revealed that the ulcers were preceded with vesicle formation. The features are suggestive of



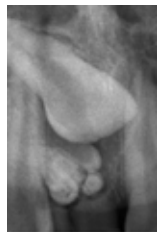- a. Herpetic ulcer;
- b. Major aphthous ulcer
- c. Minor aphthous ulcer;
- d. Traumatic ulcer

3. A 35 year old HIV positive female patient reported with white patches on the tongue. Intra oral examination showed vertical white streaks on both sides lateral surface of the tongue. The lesion is most likely to be



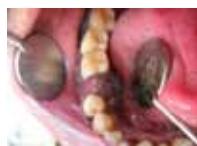- a. Hairy tongue;
- b. Oral hairy leukoplakia
- c. Verrucous leukoplakia;
- d. Speckled leukoplakia

4. A 10 year old boy reported with the complaint of retained deciduous upper central incisor. Intra oral periapical radiograph of upper anterior region showed an unerupted permanent maxillary central incisor. Identify the lesion which is preventing the eruption of permanent tooth.



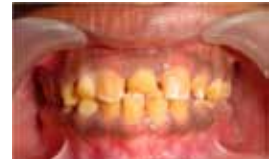- a. Complex odontome
- b. Compound odontome
- c. Ameloblastoma
- d. Odontoameloblastoma

5. A 45 year old male patient reported with a rapidly growing mass from the extraction socket. Clinical examination showed a reddish black nodular growth in the extraction socket of 45 region. Biopsy revealed epithelioid and spindle shaped cells containing brown-black pigments proliferating in the connective tissue. The clinical and histopathological features are suggestive of



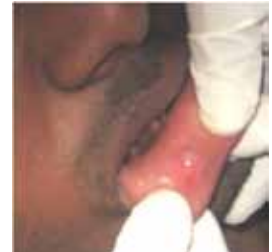- a. Melanoacanthoma
- b. Melasma
- c. Melanocytic nevi
- d. Melanoma

6. A 12 year old boy reported with yellowish brown discoloration of teeth. History revealed that both the primary and permanent dentition exhibited discoloration and his father also had a similar condition. The most probable diagnosis is



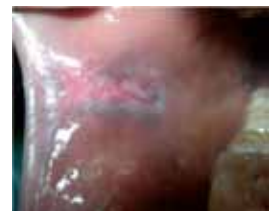- a. Amelogenesis imperfecta
- b. Turner's hypoplasia
- c. Mottled enamel;
- d. Tetracycline stain

7. A 21 year old male patient complained of a swelling on the lower lip for the past 3 months. On examination, a translucent swelling was noted on the lower lip which was soft in consistency and non tender. History revealed that patient has the habit of lip biting. The features are suggestive of



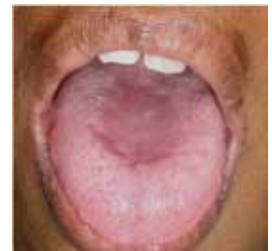- a. Cheilitis granulomatosa
- b. Cheilitis glandularis
- c. Mucocele;
- d. Salivary gland tumor

8. A 52 year old male patient reported with a red patch on the buccal mucosa. On examination, a non scrapable white patch was noted on the right buccal mucosa, which was intermixed with red areas. The patient had a habit of chewing tobacco for the past 20 years. The clinical diagnosis is



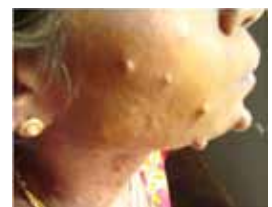- a. Speckled leukoplakia
- b. Verrucous leukoplakia
- c. Mild epithelial dysplasia
- d. Moderate epithelial dysplasia

9. A 45-year old male patient with uncontrolled diabetes had an erythematous area of depapillation in dorsal surface of the tongue. Patient also exhibited an erythematous patch on the hard palate and complained of burning sensation of the tongue. Topical application of clotrimoxazole resulted in resolution of the lesions. The diagnosis is



- a. Erythroplakia
- b. Erythematous candidiasis
- c. Erythema migrans
- d. Anemic glossitis

10. A 45 year old female patient reported to the OPD for cleaning her teeth. On clinical examination, multiple nodular growths were noticed on the face, hands and legs. History revealed that these lesions started developing during childhood and the number of lesions has increased gradually. Patient's mother also had similar lesions. Patient also had multiple brown macules on the skin. The probable diagnosis is



- a. Neurofibromatosis;
- b. Cowden's syndrome
- c. Coston syndrome;
- d. Albright syndrome

Answers: 1. c; 2. a; 3. b; 4. b; 5. d; 6. a; 7. c; 8. a; 9. b; 10. a

\* Reader, Dept. of Oral &Maxillofacial Pathology, Azeezia Dental College, Kollam; \*\*Reader, Dept of Oral & Maxillofacial Pathology, PMS Dental College, Trivandrum  
E-mail: drjayanthip@gmail.com

# Association News

## ▶ Tripunittura Branch

**INSTALLATION OF NEW OFFICE BEARERS:** At a glittering ceremony on 23RD JANUARY, presided by president Dr Jayan b AT Hotel Hill palace,Irumpanam, Tripunithura, the installation of IDA Tripunithura new president Dr Biju C Nedumburam and his new team was conducted. State Vice President Dr Eugene Varghese joseph was chief guest and State CDH Chairman as guest of honor. The founder president collared new president Dr Biju C Nedumburam, Dr Kunal viswam and Dr Saji K (Hon Treasurer) and all the office bearers took charge in the presence of CDH Chairman Dr Subash K Madhavan and senior members and office bearers of neighboring branches.

Grand smile, The Geriatric oral care project, the new campaign initiated by IDA Tripunithura was inaugurated by Dr Subash Madhavan. This program aims in spreading awareness among senior citizens on the importance of oral

hygiene and preserving their teeth. Old age homes and elders villages have been identified for this campaign.

**BRANCH ACTIVITIES:** On 30/12/2016 IDA Tripunithura conducted our first CDH Program along with chathari residence association at Plakkuzhiyil towers Chathari, Tripunithura. Around 100 people attended the camp and were screened. Dr Kunal Viswam, Dr Avneet Kunal and Dr Sabu K R conducted the camp.

On 24/01/2016 IDA Tripunithura along with SNDP Youth movement conducted our CDH program at SNDP Hall, Ambadimala,Chottanikkara for children up to the age of 15. The program was inaugurated by Smt Omana shashi (Chottanikkara grama panchayath president). Awareness class was conducted by Dr Kunal viswam (hon secretary), vote of thanks by Dr James Thomas (CDH Chairman).



## ▶ Trichur Branch

**AGM & INSTALLATION MEETING WAS** conducted on 5th January 2016 at Das Continental. Meeting was started with silent prayer. Dr. Suresh Kumar J welcome the members. House paid homage to Lt. Col. Niranjan got killed in Pattancotte terrorist attack whose wife is an IDA member. Secretary Dr. Abhilash T K presented the annual report of 2014-2015 and passed. Treasurer Dr. Sunil Fahad presented the account statement for the year 01-12-2014 to 30-11-2015 and passed. Installation of new President Dr. Jayakar V S and new executive committee was done. Dr.Varghese Mani gave oath of office to new executive committee. Dr. Jayakar V S give acceptance speech. As a part of new year celebration cake was cut by senior IDA members, Dr.Antony Manavalan, Dr.Varghese Mani and Dr. Janardhanan. Membership fee was collected on the same day.

Hon. Secretary Dr. Benil P give vote of thanks. Meeting was attended by 51 members of IDA Thrissur. Meeting adjourned for further activities.

An emergency executive meeting was called to order as a condolence to the death of Dr. Manoj Davis Akkara on 02/02/2016. The meeting was conducted at Mothi Mahal at 8.00 p.m. on 03/02/2016 that was on the funeral day.



## ▶ Pathanamthitta Branch

Installation of IDA Pathanamthitta branch for the year 2016 was held on 24th January 2016 at Hotel Hills Park, Pathanamthitta. Chief guest of the programme was Dr Aliyas Thomas, National President, IDA. President Elect of IDA Kerala state, Dr. Sabu Kurian was the guest of honour and IDA Kerala state Vice President Dr. Eugene Varghese Joseph was the Special guest.

Dr. Aliyas Thomas inaugurated the programme and activities for the year 2016. President Dr Giju Zachariah installed the newly elected President Dr Manoj M Kumar and his team of office bearers. The Motto and the Logo for the year,QUALITY ASSURED,was released by Dr Sabu Kurian. Annual edition of the journal "EXTRACT" was released by State Vice President Dr Eugene Varghese Joseph by handing over the journal to Dr. Aliyas Thomas. 104 peoples attended the programme including the branch members, their families, neighbouring branch members and special invitees from various clubs like Rotary and JCI. IDA members from neighbouring branches like Central Kerala, Kottayam, Thiruvalla, Mavelikara and Kottarakkara made their presence to make the event a grand success.

The meeting was followed by dinner, fellowship and various cultural programmes by members and their families.





## ► Chalakkudy Branch

Installation ceremony of the new office bearers for the year 2016 was on 17th January 2016 at Hotel Athirappilly Residency. Our senior member and charter president Dr George Sebastian Pullan was the installation officer. Dr

Seby K Bastin took charge as the president Dr Sijo Manavalan as Secretary and Dr Sanil Paul as treasurer

We conducted our first CDH programme at SN Vidyabhavan Aloor.



## ► Trivandrum Branch

Activities of IDA Trivandrum for the year 2016-17 kick started with installation ceremony of Dr Mathew Jose as our new president for this year. Installation was celebrated in a grand manner on 7th February 2016 at Sreemoolam club Trivandrum. On his acceptance speech Dr Mathew Jose shared his ideas for the current year and revealed his motto for this year SMILE LEARN & CARE. Chief Guest of the day was Dr MKC Nair Vice Chancellor Kerala University of Health Sciences. The Chief Guest steered audience's attention with a mesmerizing speech. Guest of Honor IDA state president Dr Sameer PT promised the crowd

that he will take IDA more popular to the public with more public awareness programs. State secretary Dr Suresh poured his gratitude and love to his home branch for giving a convincing win during the state elections held at Alleppey. Dr Achuthan the outgoing president thanked his office bearers and his members for the smooth running of the activities during his term. Dr Arun Ramachandran secretary Trivandrum thanked the gathering. The installation ceremony was followed by musical night and lip-smacking food.



## ► Eranad Branch

The 3rd installation of IDA Ernad under president-ship of Dr Ram Mohan Reddy was held at hotel HITON, Perinthelmenna on 17/1/2016 at 7:00pm. The installation ceremony was held in presence of Dr Sijo Paulose 1st Vice President of IDA Kerala state, Dr Subhash Madhavan CDH convener IDA Kerala state, Dr Jayakrishnan IMA state president, Mr Tini Tom (cine fame), Mr Kalabhavan Sinaj (cine fame). The new office of IDA Ernad comprised of Dr Ram Mohan Reddy (president), Dr Sabhish Sivasdas (hon secretary), Dr Muhsin (hon treasurer), Dr Mithun Balakrishnan (CDE Convener), Sanal Babu (CDH convener). Variety of entertainment programs was held under Mr Tini tom and Kalabhavan Sinaj and was followed by appetising feast. The inauguration was well covered and supported by the media and social forums.

IDA Eranad branch celebrates republic day, dental screening camp, and distribution of dental kit on 6 centres in Malappuram

1. MMMLP School, Kalkulam, Karapuram P.O
2. NSSUP School, Uppada
3. UMALP School, Chathangotupuram
4. GMLP School, Mukkatta, Nilamboor
5. GLP School, Kizhakethala, Karuvarakkund
6. GWUP School, Thrikkulam, Chemmad



## ► Kodungallur Branch

The installation of new office bearers of IDA Kodungallur for the year 2016 was conducted in a glittering ceremony on 2/01/2016 at IMA Hall, Kodungallur.

Dr.Nazeer.P.M. took over the reigns from Dr.Mahesh Narayanan as President of the branch while Dr.Shaji.P.H. continued as the Secretary.

The chief guest for the function was Dr.K.C. Thomas, President, IDA Kerala state who installed the new president and other office bearers. Past state president Dr.G.Premkumar felicitated the gathering and the function was adjourned for fellowship and dinner at 9.30 P.M.



## ► Valluvanad Branch

IDA VALLUVANAD BRANCH installation of office bearers was conducted on 16th January at Nila residency, Shornur. Dr. Ciju Paulose, the 1st vice president of kerala state consented to be the chief guest and installation officer. The program commenced at 7 pm with collaring of the president Dr. Sreekanth .S and followed by prayer song by Asha Lakshmi, daughter of IDA state CDH chairman Dr. Subash Madhavan. Chief guest introduction was given by Dr Haris and the incoming president introduction by Dr. Vishak. The event was honoured with the presence of two guest of honor, Dr. Subash Madhavan, IDA state CDH chairman and Dr. Mercy Joji, the women's dental council president. A detailed secretary report was read by Dr. Rajarajan. Then the new president, Dr. Vishal Korah was installed by taking oath administered by the installation

officer Dr. Ciju Paulose. After that office bearers team is been installed by Dr. Vishal Korah, newly elected president of IDA Valluvanad.

The new president was felicitated by Dr. Joji George, the president of IDA Kunnankulam branch and Mrs. Geetha, the president of rotary club of Shornur. Vote of thanks was given by Dr. Shoukath, the elected secretary and meeting adjourned for dinner and entertainment after national anthem.

About 120 members including family members attended the function. Everyone enjoyed the evening under the master of ceremony Dr.Balasubramaniam.



## ► Quilon Branch

Installation ceremony & Family meet: The 24th installation ceremony and family meet of IDA Quilon branch was held on 20th December 2015 at The Quilon Beach Hotel Kollam. Dr B S Sundaresan as the president and other office bearers were installed. The chief guest, worshipful mayor Adv V Rajendra Babu inaugurated the meeting and The past national president Dr K G Nair was honoured for his outstanding contributions to IDA. 12 new members were inducted. Ist Executive committee meeting: The first executive committee meeting held on 6th January 2016 at Hotel Shah International.

Our members attended the 48th state conference ALOHA at Alappuzha from 9-10th January

CDH program.: Conducted a dental and medical camp at Believers Church Mathma central School Eravipuram on 24th January 2016.

First Monthly meeting: The first monthly meeting & CDE program was held on 30th January 2016 at Lions Hall Kollam. 56 members attended.

First CDE Programme: Conducted a lecture on "Management of cardiac patients in dental clinic" by Dr N Pratap Kumar DM, Intervention cardiologist. President Dr Sundaresan chaired the meeting, CDE representative Dr Sudheesh Manoharan introduced the speaker. 56 members of branch attended.





## ▶ Malabar Branch

### INSTALLATION OF NEW OFFICE BEARERS & FAMILY MEET

Installation of the office bearers of IDA Malabar Branch 2015 -16 was held on 24th January 2016 at Hotel Malabar Palace Kozhikode at 6.30pm. Dr.Dinesh KR was installed as the new president of IDA Malabar Branch by Dr.Mohammed Sameer (Hon President IDA Kerala State) was the Guest of honour and installation officer. Outgoing President Dr.Saju NS handed over the President's Collar to newly installed President. Followed by the installation of other office bearers. Shri.V.K.C Mammad Koya (Hon Mayor Kozhikode) was the Chief Guest of the occasion. Felicitations were given by Dr.Nizaro Siyo Past President IDA Kerala state and Dr.Antony Thomas Past President IDA Kerala State. Many important Dignitaries witnessed the occasion including members from other neighbouring branches like Malappuram and Vadakara. Vote of Thanks were delivered by Dr.Sudheer K.T Secretary IDA Malabar branch followed by many colourfull cultural programmes by members and their families.

### CDH ACTIVITY No.1

Dental Screening and awareness camp was conducted at Kunjali Marakar Higher secondary School Kottakal Vadakara, Kozhikode on 20/12/2015 in association with Dept. Of Education Govt. of Kerala. Around 100 Participants were present in the camp. On behalf of IDA Dr.Rubeena Thahir and Dr.Muhsina Participated the camp.

### CDH No.2

Dental check up and awareness camp was conducted at Devaseva Sangham Kaithapadam Pottamal Kozhikode on 31/01/2016 in association with Lions Club Daffodils. Around 100 Participants were present in the camp. On behalf of IDA Dr.Dinesh KR, Dr.Prathap, Dr.Sudheer K.T,Dr.Haris,Dr.Susha,Dr. Sandeep Rajagopal, Dr.Pravish and Dr.Hussain Participated the camp.



## ▶ Central Kerala - Kottayam Branch

DECEMBER 2015

AGM was held on 12th Dec 2015, at Kottayam club. The annual report of branch was presented by Hon. Secretary Dr. Renju Titus. Treasurer Dr. Lijo Thomas presented the audited accounts. New President Dr. Bobby John Varghese and new team of office bearers took charge.

CDH ACTIVITY: A dental checkup camp WAS conducted by Dr. Bobby John Varghese on 6th Jan 2016 at Govt. LP School Panayara. About 300 students attended the camp.

Dental awareness camps were conducted by Dr. Robin T and Dr. Ittyvirah Babu on 16th Jan 2016 at Maria Sadanam orphanage and Town Boys Orphanage. About 600 inmates from both orphanages received the benefits. Oral Health Packs were distributed to inmates.

Dr. Nidhish and Dr. Anukesh conducted checkup camp on 22nd Jan 2016 at Excelsior school, Illickal. 100 students benefitted and Oral Health Packs were distributed.

A dental check up camp was conducted by Dr. Anukesh on 28th Jan 2016 at ACM nursery school Thiruvathilikal, 25 kids benefitted.

EXECUTIVE COMMITTEE MEETING: The first Executive meeting of IDA CKK was held on 14th Jan 2016, at Kottayam club.

INSTALLATION CEREMONY: Installation ceremony of Dr. Bobby John Varghese and his team was held on 30th Jan 2016 at Citizens club, Kottayam. IDA Kerala state President Dr. Mohammed Sameer was the chief guest of the day and he installed the new president Dr. Bobby John. Dr. Divya Iyer IAS (Asst. Collector, Kottayam) inaugurated the CDE programme and Dr. B Ekbal (former VC, University of Kerala) inaugurated the CDH programme. IDA National President, Dr. Alias Thomas inaugurated the co-operative society of CKK. Dr. Suresh Kumar (Hon. Sec, IDA Kerala State) and Dr. Sabu Kurien (President Elect, IDA Kerala State) addressed the gathering. 220 members attended the ceremony.

FAMILY GET TOGETHER: The first family get together was conducted on 30th Jan 2016, at citizens club. 220 members participated.



## ► Nedumbassery Branch

IDA Nedumbassery Branch has new leadership under the first lady president of our branch. President Dr (Mrs) Rajeena Sajee Vinod, Secretary Dr Seby Varghese, Treasurer Dr Teny Mathew.

Dr KC Thomas-the past president of IDA Kerala, installed the New Office Bearers on 2nd January 2016.

Our Theme for this year is

- 1- Welfare of our members.
- 2- Social responsibility and Social Imaging for profession and IDA
- 3- Promoting collaborative approach among the health care professionals.

Out first Executive committee meeting held on January 15th 2016.



## ► Palakkad Branch



The installation ceremony of the office bearers of the year 2016 was held on 03-01-2016 at hotel Gazala, Palakkad. Chief guest of the function was municipal chairperson Prameela Sasidharan and Dr. Joseph C C (State Sectry IDA hope) was the installation officer. Other guests like Dr. Suresh and Dr Anil felicitated the gathering. A few other members of nearby branches also attended the function.

Dr T. Raghunath Nambiar took charge as President of IDA and Dr. Sivarama Krishnan as Secretary, and the new team of

IDA executive members also took their respective positions. After installation ceremony we had entertainment programmes and dinner. All together the installation ceremony was a great treat to everyone including the participated family members.

Our members Dr Saji Thomas, Dr. Suresh and Dr.Veena Suresh conducted a dental camp on 20-01-2016 at M.A.L.P School Mundekarad, Mannarkkad with the support of our CDH co-ordinator Dr. Anoop Rajan. By this camp the activities of this year is kick started with a great bang.

## ► Mavelikkara Branch



Annual general body and annual elections of our branch were held at hotel Travancore regency on 22nd December 2015. AGM elected Dr. Seethibegam as president, Dr.Baiju Hariharan as secretary and Dr.Samith as treasurer for the year 2016.

Combined executive of IDA Mavelikkara branch was held on 18th January 2016 at hotel Travancore regency. Meeting discussed about the installation of the new office bearers of the branch and decided the date of installation.

The installation ceremony of Dr Seethi Begam and her team was held on 24th January 2016 at Wyte Portico Adoor at 5.pm. The chief guest of the day was Dr Suresh Kumar Hon. Sec IDA Kerala state and the guest of honour was Prof M S Sunil (social activist).Around 150 members of our branch attended the function. There was a variety of entertainment programs by our family members and a music entertainment by MOKSHA THE MUSIC PEOPLE....



## ▶ Attingal Branch

REPORT- JANUARY 2016

### INSTALLATION CEREMONY & FAMILY GET TOGETHER

The installation ceremony and Family Get together of IDA Attingal was held at IMA Headquarters, Trivandrum on December 27th Sunday at 5PM. On this auspicious occasion Dr Hari Kumar R installed as the 16th President of IDA Attingal by the outgoing president Dr Arun Roy. Chief Guest of the meeting was Mrs. Kala N L (Registrar TCMC & KDC). KDC Vice president Dr Anish.P welcomed the gathering. On her inaugural address KDC Registrar congratulated the IDA Attingal for conducting KDC accredited CDEs in good manner and she urged the need of conducting the CDEs on the topic on code of ethics. On his acceptance speech newly installed president Dr Hari kumar thanked the members for electing him as the president. After that the president installed the new office bearers of IDA Attingal 2016. Dr Samuel K Ninan (Past President

IDA Kerala state) was the guest of honour. He welcomed the new members to IDA and inducted new members to IDA. Vote of thanks was delivered by the Secretary Dr Alex Philip. The meeting was followed by gala banquet and entertainment programs. 200 members and their family attended the function.

### 1st BRANCH EXECUTIVE COMMITTEE MEETING

The 1st branch executive was held at PWD Rest House; Attingal on January 19 Tuesday at 7pm. President Dr Hari Kumar welcomed the members and expressed his gratitude for electing him as the new president. He also thanked all members for conducting the installation meeting in such a grand manner. Later the meeting discussed about the proposed year plan 2016. The meeting decided to conduct a CDE program on 21st February on the topic sterilization and a CDH program in association with IMA on World Cancer day.



## ▶ Coastal Malabar Branch

1. ANNUAL GENERAL BODY MEETING: Held on 20.12.2015 at Hotel J.K. Residency, Cheruvathur from 06.30 pm onwards. President Elect Dr.Suja Vinod took over the office along with her office bearers. 42 members attended the AGM

2. 1st EXECUTIVE COMMITTEE MEETING: Held on 01.01.2016 at Hotel Bekal Club, Kanhangad from 7.00pm onwards. Various subcommittees were formed. 6 CDH activities and 1 CDE activity was finalised to be conducted on the month of January. Installation of WDC and family get together finalised to be conducted on 17.01.2016.

3. 1st CDH Activity: Held on 5/1/2016 at Palavayal St. Jones L.P School from 12.00pm onwards. Dental check up done for 105 students. Dr. Sajjan Joseph and Dr.Sijo Sebastian took part in this CDH activity.

4. 2nd CDH Activity: Held on 10/1/2016 at Durga High School, Kanhangad from 10.00pm onwards. Dental checkup done for 75 patients. Dr.Jyothi, Dr.Sharmila, Dr.Vinaya,Dr.Dishana took part in this CDH activity

5. INSTALLATION OF WDC,NEW YEAR CELEBRATION AND 1st FAMILY GET TOGETHER-2016: Held on 17.01.2016 at hotel K.K.Residency from 6.00pm onwards. Installation of the Chairperson Dr.Sapna Sreekumar was done by the Past Chairperson Dr.Suja Vinod. Dr.Merci Joji, Chairperson, Womens' Dental Council,IDA Kerala State was the Chief guest and Dr.Jayashree, Head of Department,Community Medicine, Pariyaram Medical College was the

Guest of Honour. Recognizing and distribution of certificates to new members of IDA Coastal Malabar Branch was done at this function.

6. 3rd CDH Activity: Held on 23.01.2016 at Malabar Rehabilitation Centre For Handicapped, Payyannur from 10.00am onwards. Parents's training programme was done by conducting a dental awareness class for the parents by Dr.Ahamed Shafi.

7. 4th CDH Activity: Held on 26.01.2016 at Old age home, Tabore from 09.00am onwards. Treatment done for the residents of old age home. Dr.Sajjan Joseph and Dr.Merin Thomas took part in the treatment camp.

8. 5th CDH Activity: Held on 26.01.2016 at Anganvady, Thayinery, Payyannur from 09.30am onwards. Dental Check up done for 45 students,30 parents and 5 teachers. Dr.Suja Vinod, Dr.Cynjila, Dr.Sreedevi, Dr.Deepika took part in this CDH activity

9. 6th CDH Activity: Held on 28/01/2016 at Anganvady, Cherupzha. Done in association with Lioness Club Cherupuzha. Dental Check up done for 35 students,20 parents and 5 teachers.

10. 1st CDE Programme: Held on 31.01.2016 at Hotel J.K.Residency, Cheruvathur from 04.00pm to 09.00pm Topic- Problems solving in Dentistry. Faculty- Prof. Dr. Moksha. Nayak, Principal, K.V.G. Dental College, Sullia. Attendance- 55 Nos. Inauguration of CDE done by our Charter President, Dr.K.T.Suresh.



## ► Malappuram Branch

**AGM :** The Annual general body meeting of MIDA held on 30/12/15 at Rydges Inn Kottakkal. More than 24 members participated in the meeting.

**EXECUTIVE COMMITTEE MEETINGS:** First Executive committee meeting held on 05/01/16 from 8pm onwards at Cosmopolitan club Manjery. 15 members were attended.

**INSTALLATION -16:** MIDA conducted the Installation ceremony on Sunday 17/ 1/ 16 at Hotel Woodbine Manjery. Our Chief Guest was Dr Muhamed Sameer PT, President IDA Kerala, Our guest of honor was Dr Suresh kumar G, Honourable Secretary, IDA Kerala. Many important personalities from various organizations were graced the occasion. The entertainments programmes were performed by renowned artists from music world. Followed by Gala dinner culminated with mouth watering cuisines.

**“PUTHUPUNJIRI”:** The inauguration of our Mega project” PUTHUPUNJIRI”, The 100 Free dentures for poor and needy peoples done in the installation venue in the presence of many leaders and invited guests.

**MIDA LOTUS NEW YEAR CELEBRATION:** The new year celebration and inauguration of MIDA LOTUS”16 (Womens Wing) done by cutting the cake at the installation venue on 17/1/16 by the MIDA LOTUS members and the leaders.

**PAIN AND PALLIATIVE DAY OBSERVATION:** The CDH team visited the Pain and Palliative care centre at Puthanathani on pain and palliative care day. We had discussion with the office bearers of Pain and Palliative unit of Puthanathani regarding conducting an Oral awareness camp for palliative care unit volunteers in district level by their request.

**CDH REPORT:** First CDH camp of MIDA held at BHSS Mavandiyoor on 28/1/16. More than 70 students were benefitted. This dental screening camp lead by Dr Deebeu J Mathew, Dr Hisham, Dr Mahesh, and Dr Muhamed Shereef.

**LEGAL CELL ACTIVITIES:** The executive committee appointed the Legal cell committee including Dr Sadiq Ali as Legal cell chairman, President, Immediate past president, President Elect, Hon Secretary, Treasurer are the members. The executive decided to start the legal cell bank account separately for the accountability of the collecting amount towards the legal cell. The executive committee appointed the Legal advisor and cases have been reached in the High court already.

**CDE REPORT:** Our first CDE on Basic Life Support (BLS) will be held at Aster MIMS, Kottakkal on 14/2/16 on 9 am onwards. This Full day programme will be leading by Department of Emergency Medicine, MIMS Hospital.



## ► Malanadu Branch

25th installation of IDA Malanadu branch was held on 23rd January 2016, Saturday at Hotel Kabani International Muvattupuzha.

Meeting was started at 8:00 p.m. presided by Dr. Jayan Jacob Mathew. Meeting was started with the collaring of the President by Secretary Dr. Joby J. Parappuram. Dr. Byju Paul Kurian welcomed the gathering.

Dr. Sankar Vinod past president introduced the new President of Malanadu branch Dr. Arun George. The Immediate past president Dr. Jayan Jacob Mathew installed the new President, and oath was spelled by Dr. Suresh Kumar, secretary IDA kerala state, followed by the Installation of new office bearers by Dr. Arun George.

Chief guest for the day Mrs. Asha Sanil, President, Ernakulam District Panchayath who got introduced by Dr. Siju V Jose, inaugurated the IDA activities of our branch for the year 2016.

Guest of honour Dr. Alias Thomas president IDA Head office, distributed Dr Paul G Vadathu Memorial Merit Awards to the students who came first in BDS Exams from each of the five dental colleges which come under IDA Malanadu branch.

Guest of honour Dr. Sabu Kurian, President elect Kerala state Inaugurated – continuing Dental Health Welfare Activities for the Neglected Individuals by unveiling its logo “Sathkrithi”

Guest of honour Dr. Ciju A Paulose, First vice President, IDA kerala State inaugurated the Continuing Dental education programmes by unveiling its logo ‘Sparsh’ for the year 2016.

Guest of honour Dr. Suresh Kumar, secretary IDA kerala state, released The Malanadu Dental journal

Charter Day was celebrated with a “Cake Cutting Ceremony” by Our Charter President Dr. Abraham Varghese.

Pleasantries were given to the guests by Dr. Arun George. Dr. Litto Manuel, Hon. Secretary gave vote of thanks. Meeting was adjourned for dinner and entertainment programme by 10:15pm.

Report prepared by Dr. Litto Manuel, Hon. Secretary, IDA Malanadu on 24th January, 2016.





## Vatakara Branch

Inauguration of IDA VATAKARA was done by Sri.C.K.Nanu,MLA(Vatakara) by lighting the lamp at an auspicious function held at Dazzle Conference Hall,in the presence of various prominent figures and state leaders of IDA. Dr.K.C.Thomas(pres.IDA Kerala State) presided. State wide Inauguration of HOPE-MEDI,the group insurance scheme&Clinical Standardisation Programme also got inaugurated at the same venue.

Installation of branch president Dr.Abdul Gafoor was done by Dr.K.C.Thomas. Branch president installed his team of office bearers. Dr.Sanal.O.V (Secretary IDA Kerala State ) handed over the constitution to new selected secretary. Felicitations followed.

Presently the branch has 87 members in which 55 are new to IDA. The membership campaign is in full swing to add all dentists in this region to IDA.

Within the short period branch conducted two full day CDE programmes. 1:

First Response Provider Course by Angel's International Foundation, 51 members attended. 2:Problem Solving in Restorative Dentistry by Dr.Joy Kurian.MDS which had 37 participants.

Branch could conduct two free dental camps also.(1)at Kannoorka,Vatakara on 25/10/2015. It was attended by Dr.Abdul Gafoor,Dr.Thulasi Das, Dr.Salil Chakravarthi, Dr.Susanth Krishna, Dr.Sanal.P, Dr. Athul.G.S and Dr. Sajitha. (2) at Town Hall, Vatakara on 03/01/2016. Dr.Salil Chakravarthi and Dr. Susanth Krishna attended.

Immediate future programmes are(1).Free Dental Check Up Camp On 07/02/2016 @Abhayagiri tribal colony in association with JANAMAITRI POLICE.(2)a CDE programme on management of medically compromised patients(3)Cluster meeting of practicing dentists at different regions of Vatakara to create good will.(4)a family get together on 28/02/2016.



## Wayanad Branch

Installation Ceremony: The activities of IDA Wayanad branch started with the installation ceremony held at Hotel Pepper Groove, Sulthan Bathery on 16th January 2016. The chief guest of the event was Advt. T.M Rashid convenor Wayanad - Nilgiri's (NH) Railway action committee.

Dr.Mohammed Sameer president IDA kerala state was the guest of honour and keynote speaker for the function.

Dr. Suresh Kumar G, secretary IDA kerala state installed Dr. Thomas Mathew as the new president of IDA Wayanad and Dr. Sanoj P.B as the secretary. The function was well attended by the IDA members with their family and other distinguished guests.

Executive Meeting: The first executive meeting of IDA Wayanad branch was held at Hotel Resort, Sulthan Bathery on January 21st 2016. It was decided to provide Water Beds and Air Beds for the needy patients of pain and palliative care units in the district.

President Dr. Thomas Mathew brought an innovative idea ie to conduct smiling competition at schools and college levels to promote oral hygiene and to create awareness about the new trends in dentistry among the public.

CDH Programme: Balamughulam: IDA Wayanad branch in association with Bharathiya Chikhilsa Vakuppu with their Balamughulam project conducted Dental Health Check Up Camps and Dental Awareness Programme at 5 Schools in different parts of Wayanad.



## Kochi Branch

IDA Kochi Branch had its installation For the year 2016 on 20th December 2015 at Hotel Mercy Estate,Kochi. Kochi Mayor Saumini Jain was the chief guest for the Ceremony,IDA National President Dr.Alias Thomas was the Guest of Honour,IDA Kerala State President Elect Dr. Sameer P.T Guest.

The CDE program organized by Indian Dental Association, Kochi branch, and Colgate was held on 30th January,2016 at IMA House Kochi. This was the first CDE program of this year. The CDE started at 7.30 pm with a silent prayer followed by welcome address by Dr.Jayakumar.S, President of IDA Kochi. The

faculty was Dr.Vinod Thomas, DM. He is the chief cardiologist of Renai Medicity Kochi, an accomplished speaker and has presented several papers on national and international conferences and has won many accolades. The Program was followed by lecture. The lecture was assisted by audiovisual aids. He delivered a very informative lecture on Cardiology in relevance to dental practice. There were 55 participants for this program. Dr.Balu Soman Secretary IDA Kochi thanked the speaker and Colgate for supporting IDA Kochi with this program. As a token and affection memento was given to the speaker. As soon as the lecture came to close the participants were served dinner.



## ► Tellicherry Branch

Installation of office bearers of 2016 was held at lions hall Tellicherry on 14th February 2016. IDA state president Dr Muhammad Sameer was the chief guest. IDA state secretary Dr Suresh Kumar G was the guest of honour. Dr Suresh kumar installed Dr Firoze K. M. as the president. The president installed his team of office bearers. The meeting was attended by around 50 members with family. Members from nearby branches also attended the meeting. Felicitations were given by Dr Prathap Pavithran and Dr Retnakaran. The president in his

acceptance speech thanked all the senior members and State president Dr Muhammad Sameer, State secretary Dr Suresh Kumar, State IPP Dr Thomas K C, State past Secretary Dr O V Sanal, past legal cell chairman Dr Shaji K Joseph for their efforts in resolving the issues between IDA Tellicherry branch and deract. Dr Aneesh Sebastian and Dr Sujatha gave mementos to Chief guest and guest of honour respectively. Installation was followed by entertainment programmes and dinner.



## ► North Malabar Branch



The installation ceremony of office bearers of IDA North Malabar Branch for the year 2016-17 was held on February 14th at Hotel Malabar Residency, Kannur. The chief guest for the day was Dr M.K.Abdul Khader, Vice Chancellor, Kannur University and Dr Sreekumar Vasudevan, Past IMA State President was Guest of Honor. During the day Dr. Jayashree K.T. the incoming President, IDA North Malabar branch and her team of office bearers were sworn in. The ceremony was followed by variety entertainment and dinner.

## ► Kasargod Branch



First General body meeting was held on 18th January, Monday, at hotel Highway castle, Kasargod, at 7.30 pm. 30 members attended the meeting. Dr.

Rekha Maiya was elected as President, Dr. Ashwin Devasya as secretary, Dr. Uma Maheshwari as treasurer, for the year 2016.

A continuing dental education programme on “Phytopharmaceuticals in dentistry” was presented by Dr. Waheed Pasha M.D in Ayurveda from Bangalore.

Executive committee meeting was held on 26th January, Tuesday, at IMA hall Kasargod. Issues and programmes to be conducted in the current year were discussed.

## ► Kottarakkara Branch



The annual general body meeting of the branch was held on 16th January 2016. The annual report and the accounts of the branch was presented and passed.

The installation of Dr. Paul K and team was conducted on the 31st of January 2016 Smt. Aysha Potti MLA was the Chief Guest and Dr. Suresh Kumar, Hon. Sec. IDA Kerala State was the Chief Guest. The meeting was well attended by members and guests.

## ► Karunagappally Branch

The Installation ceremony of IDA Karunagappally branch 2016 was conducted on 30/01/2016 at Grand e Muscat hotel, Karunagappally. Dr Eugene Varghese



Joseph, vice president IDA Kerala state was the chief guest and installed Dr Bijoy K Sudhakar as the president of IDA Karunagappally branch. Lighting of lamp and keynote address was given by the chief guest. Dr Jayakrishnan welcomed the gathering and Dr A Q Azad proposed vote of thanks. Felicitations were given by Dr Geetha Joy, Dr Jinu Mathew Vidyan, Dr Varghese, Dr Amritha, Dr Nazeer and Dr Laiji Thomas Tharakan. The meeting was well attended followed by Cultural programmes conducted by the family members and dinner.



## ▶ Thiruvalla Branch

The INSTALLATION of IDA THIRUVALLA was held on 29th November 2015 at GREEN VALLEY, water theme park-Adoor. Dr.Samuel K Ninan Past President-IDA Kerala was the installing officer and called for facing challenges unitedly. Dr.Rajeev Simon K took oath as the president, Dr.Sunil Roy Koshy as the Hon.Secretary and Dr.Simon George as the treasurer. The President Elect is Dr.Saji Kurien, Dr Mathew P.C. is CDE representative and Dr.Reji Thomas is CDH representative. Past President Dr.Sumod P Mathew congratulated his team

for the fantastic performance and thanked the members for the wholehearted co-operation. Dr.Rajeev Simon K outlined his vision for 2016 and sought the support of members in this endeavour. He emphasised membership development and lauded the office bearers that the number stands at 89 as of today. The meeting was proceeded by Members and their family enjoying the swimming pool as well as roller coaster rides and ended with Dinner.



## ▶ Kottayam Branch



Installation Ceremony of IDA Kottayam Branch – 31st Jan 2016 at Hotel AIDA.

We had our Installation ceremony held on 31st Jan 2016 with Dr.Jojoe Joseph Surgical Oncologist, Caritas Hospital as our Chief guest and Dr. Alias Thomas,

IDA National President, and Dr.Sabu Kurian IDA Kerala State President Elect as Guests of Honour.

Dr.Jijoe Jacob welcomed the gathering.

The Secretary, Dr.Sunil T.Vergheese gave a detailed annual report of all the activities.

Dr.Thomas C.Kappen, narrated his experience being the President of our Branch and appreciated and acknowledged the good support he received from our members. Later, he installed Dr.Binumon Mani as our new President for the year 2016-17. Dr.Binumon Mani outlined his plan of activities for the coming year.

Dr.Sabu Kurian was honoured with a Ponnada by our National IDA President Dr.Alias Thomas followed by felicitations by both of them. Around fifty eight heads were present at this function. Dr.Sebastian, proposed the vote of thanks followed by the National anthem.



President Secretaries Seminar



Executive Committee Meeting



**Dr. Mercy Joji**

Chairperson

Mob : 9495416452

E-mail : mercymathewm@gmail.com

## WDC Report



**Dr. Sapna Sreekumar**

Secretary

Mob : 9496237720

E-mail : sapnamds@yahoo.co.in



### INSTALLATION CEREMONY OF WDC KERALA STATE 2016

New office bearers of WDC, Kerala State 2016 had been installed on 10th Jan 2016 at EMS stadium Alappuzha in connection with 48th Kerala State Dental Conference, ALOHA 2016 hosted by IDA Alappuzha branch. WDC, Kerala State Chairperson Dr. Mercy Joji was installed by IDA Kerala State President Dr. Mohammed Sameer. The office bearers of WDC Kerala State 2016 are

Dr. Marilyn Alias, Dr. Vimala Suresh, Dr. Thaj S. Prasad, Dr. Shoma Anil (Advisors), Dr. Anjana G. (Immediate Past Chairperson), Dr. Hema Rajesh, Dr. Susha C.N., Dr. Seethi Beegum (Vice-Chairpersons), Dr. Sudha Santhosh (Chairperson Elect), Dr. Sapna Sreekumar (Secretary), Dr. Aruna Subash (Treasurer), Dr. Jayasree Anil (Joint Secretary), Dr. Ciju. K. Eapen (Asst. Secretary), Dr. Rathy (Editor of IJWDC), Dr. Swetha Suraj, Dr. Saleena Sameer, Dr. Preetha Rajeev (North Zone Exe. Members), Dr. Avneeth Kunal, Dr. Bindu Rachel, Dr. Meera (Central Zone Exe. Members), Dr. Rakhee Rakesh, Dr. Tina Antony and Dr. Annie George (South Zone Exe. Members).

**Forthcoming Events - 1. Cancer Detection Programme :** WDC Kerala State in association with IDA Quilon branch, Palliative Care & RCC Trivandrum will be conducting a cancer detection programme at St. Johns School, Eravipuram, Kollam.

**2. Tropical Health Foundation of India (THFI) - Charity Project :** WDC Kerala State in association with IDA Kunnankulam branch and THFI will be conducting a charity project for orthotic & neuro rehabilitation commonly called Jaipur foot at Kunnankulam.

Land of Letters, Latex & Lakes beckons you all for

# 49<sup>TH</sup> IDA KERALA STATE DENTAL CONFERENCE

Venue: Hotel Windsor Castle, Kottayam

Host: IDA CENTRAL KERALA KOTTAYAM BRANCH

www.49ksdc.com | info@49ksdc.com | Helpline: +91 7025148333

Organizing Chairman  
**Dr. Mathew Joseph Vayalil**  
+91 7025148000

Organizing Secretary  
**Dr. Eapen Thomas**  
+91 7025148111

Registration  
**Dr. Sherry M Joseph**  
+91 7025148222



REGISTRATION CATEGORY		Up to January 10 <sup>th</sup> 2016	Up to December 1 <sup>st</sup> 2016	From December 2 <sup>nd</sup> 2016
Reception Committee member*	IDA Member	Rs. 3500	Rs. 4000	Rs. 4500
	Non Member	Rs. 5500	Rs. 6000	Rs. 6500
Delegate**	IDA Member	Rs. 800	Rs. 1000	Rs. 1300
	Non Member	Rs. 2000	Rs. 2300	Rs. 2500
UG Student/ Intern **	IDA Member	Rs. 300	Rs. 400	Rs. 500
	Non Member	Rs. 500	Rs. 600	Rs. 700
Accompanying Person***	Non Dentist	Rs. 2500	Rs. 3000	Rs. 3500
Children	6yrs-10yrs	Rs. 1000	Rs. 1500	Rs. 2000
	above 10 yrs	Rs. 2500	Rs. 3000	Rs. 3000

Includes: \* Registration kit, Inaugural dinner, Gala banquet dinner, Two Lunches, Gift, Entry to Scientific sessions & Trade Exhibition.  
\*\* Registration kit, Entry to Scientific sessions & Trade Exhibition.  
\*\*\* Similar to RC. But No certificate of participation.





**IDA HOPE**  
Help Offered to Professionals in Emergencies - Indian Dental Association, Kerala State)  
Reg. Under IDA KSB Charitable Society, Reg. No. TVM/TC/651/2013 Website : www.hope.idakerala.com



## **REPORT IDA-HOPE 2015 -16**

- ◆ IDA HOPE is a members welfare scheme of IDA Kerala state.
- ◆ It was formed by merging the PPS& SSS of IDA Kerala state in 2007-08
- ◆ It has 2434 active members.

### **Objectives of the Scheme**

- ◆ Indemnity insurance and legal aid to the members.
- ◆ Financial compensation to the families of the Deceased member or Total Permanent disability.
- ◆ Medico-legal awareness/education.
- ◆ Encourage promote and popularize ethical treatment amongst Dentists.

### **Membership**

- ◆ Members of IDA Kerala State with a valid DCI registration
- ◆ Membership is co terminus with the membership of IDA Kerala State.
- ◆ Membership has to be renewed annually (along after renewing IDA membership).

### **Admission Formalities- New members**

- ◆ Copies of Birth Certificate or passport or SSLC for proof of age and residence.
- ◆ Copy of professional degree certificate and post graduate certificate if any.
- ◆ Copy of dental council registration certificate and latest renewal receipt
- ◆ Two passport size photographs (1.In Application form, 2 For the Certificate)
- ◆ Application Form (To be endorsed by the branch representative or the secretary for proof of branch membership)
- ◆ DD for admission fees drawn in favor of IDA Hope Payable at Thamarassery.

### **Membership Contributions - Fraternity contribution**

- ◆ Payment of fraternity contribution @ of Rs. 500/- is mandatory along with the next year's renewal in the event of death of any member.

### **Membership Renewal**

- ▶ The membership renewal period is between 1st –April to 31 May every year for availing all the benefits of the scheme. A grace period with fine of Rs. 500 is permitted for renewal from June 1 st to 30 th September. But during this period only professional protection is covered and Death Claim (social Security) is not covered.
- ▶ The membership will be terminated if not renewed before 30 th September.
- ▶ Receipts will be issued by local branch Representative

### **Membership Rights and Obligations**

- ▶ In the event of death of a member of at least 12 months membership the nominee/legal heirs will be paid an amount 1000000 (10 lakhs)
- ▶ In case of death due to accidents a benevolent contribution is paid as soon as member ship is realized from the scheme office.
- ▶ The Professional indemnity coverage of the member will commence one month after the acceptance of membership.
- ▶ The maximum liability that will be borne by the scheme shall be Rs. 200000/— (2lakhs only)
- ▶ Continuous membership is obtained on timely renewal.
- ▶ The members shall maintain proper records and adopt standard protocols and safe dental practices as recommended by the scheme from time to time.

### **HOPE MEDI**

"The purpose of human life is to serve and to show compassion and the will to help others."

HOPE is moving one step ahead with our new health insurance scheme HOPE MEDI. Conflating our members and the insurance corporation, we successfully implemented this new health insurance plan. We are glad to inform that, 1018 members joined the scheme. This includes spouse, kids and parents. Total of 4500 family members are the covered under HOPE MEDI umbrella. Our TAILOR MADE GROUP POLICY NO.: 1009042815P108336608, PERIOD OF INSURANCE FROM 01/10/2015 To Midnight on 30/09/2016

We have paid 93 lakhs as premium. Till last month we have had 31 claims and around 25 lakhs we conferred as claims.,

IDA hope expresses sincere thanks to The United India Insurance Co, Mr. P.V. Alex and team of Cosmos insurance brokers for their timely efforts for HOPE MEDI.

Our Hope Medi Insurance which is a tailor made policy covering Ida HOPE members and their immediate family members, This unique policy covers pre existing diseases and also offers insurance sharing , at a very nominal premium. This policy can be claimed from any accredited hospital all over India. An additional feature of this policy is it gives cashless or reimbursement settlement.

IDA HOPE members who have availed this unique very beneficial insurance policy covering all immediate family members including those having pre existing diseases would have received IDA HOPE MEDI Health card by separate post from VIDAL Health TPA Pvt Ltd.

We the office bearers of HOPE have put in best possible effort for getting in maximum possible benefit for our members, **it is up to all the members of HOPE and subscribers of HOPE MEDI to keep the momentum going and make only valid claims. Members are requested to inform all the claims requirements to your Hope rep. of your branch immediately**  
**HOPE MEDI Claims**

#### **Claim Management Guidelines- Reimbursement**

For reimbursement of claims, claim form, discharge summary, discharge bill (summary and detailed) from the hospital, medical certificate, investigation reports etc., should be submitted to TPA through M/s Cosmos Insurance Brokers Pvt. Ltd. within 15 days of discharge from hospital.

#### **Claim Management Guidelines- Cashless**

VIDAL HEALTH is the Third Party Administrator (TPA) for United India Insurance. Claim has to be intimated immediately to the TPA, whether it is cashless or reimbursement basis. Insurance desk of hospital should be contacted for cashless facility showing identity cards and see that relevant treatment details as provided to TPA. It is advisable to report the claim to M/s Cosmos Insurance Brokers also when the same is initially intimated to the TPA.

#### **Contact Details:**

TPA (M/s Vidal Health TPA)	: Ph:0484-2358683	
Assigned Contact Person	: Ms. Priya	
	: Ph :0484-2359191	email: priya.sinu@vidalhealthtpa.com
M/s Cosmos Insurance Brokers	: Ph:0484-2351432	
Assigned contact person	: Mr. Darwin Gomez.	
	: Mob: 9746048805	
	: Mr. P.V Alex.	
	: Mob: 9447608146	email: cosmosbrokers@gmail.com

#### **Membership**

The active membership strength of IDA HOPE as on date is 2434. In the last financial year, 161 new members joined IDA HOPE. Thanks to all the members, representatives and branches for this great achievement. In the top list Malabar branch with 25 new members & IDA Central kerala, Kochi and Tripputhura contributed more members to IDA HOPE in the last financial year.

#### **Additional Riders**

. The premium was reduced to Rs.347347/- following negotiations with company and payment was made on 03/11/2015 to United India Insurance Co. This covers IDA HOPE any additional burden in case of multiple deaths / permanent disability in the unfortunate event of mass causality / deaths Rs. Five lakhs per deaths can be claimed by IDA HOPE in such instances to avoid depletion of the corpus fund.

#### **Meetings**

In the last financial year one Extra ordinary General Body Meeting and three Managing committee meetings were conducted. Meetings were also held with officers of United India Insurance, Chartered Accountants, Legal Advisors etc.

#### **Local Branch Representatives**

We have 31 local branch representatives. They are the pillars of IDA HOPE and the real contributors. Last year we could increase their allowances according to the membership strength of their respective branches. Thanks to all of them for their support and for keeping good relations with IDA HOPE office.

#### **Accounting & Auditing**

Our Internal Auditor Dr.Nizaro Siyo is giving all guidance for internal internal auditing. Thanks to Dr. Nizaro Siyo. Our external auditing team is Gopakumar & Co, Chartered Accountants, Calicut. The whole team has been very meticulous in verifying all our details, membership subscriptions, Bank entries, Fixed deposits and all the transactions. This year they took over two weeks to evaluate our details and we could give sufficient explanations to their queries. Thanks to Chartered accountant Gopakumar and Team.

#### **IDA HOPE office**

IDA HOPE office is maintaining all the records of our members. For transparency IDA HOPE intends to encourage fund transfer for Membership fees, renewal fees through net banking only and minimize cash transactions as far as possible. Irregularities in Applications, DDs and payments are notified to the concerned representatives and letters were forwarded to the members. We have updated the communication address of most of the members, the applications without nominees were intimated and updated as far as possible, mobile number updating under process. We could prepare a date of birth list and gender list for the purpose of United Insurance company. We also prepared a digital copy of all our applications and other records as a part of digitalizing IDA HOPE office.

#### **Fixed Deposits & SB Accounts**

All our fixed deposits are maintained in the same branches where it was started. They are at various banks at Kozhikodu, Kunnamangalam, Puthiyara, Thamarassery and Pathanamthitta. The certificates to be updated and Interest & TDS certificates to be obtained by 31<sup>st</sup> March 2015.. In this financial year four fixed deposits of Rs. 10 lakhs and two fixed deposits of 5 lakhs each were started .One FD closed for Dr Tennison Thazhath. .  
 Our Savings bank accounts are maintained at South Indian Bank Tamarassery and State Bank of Travancore, Tamarassery. .

### **SSS**

Last year four of our members expired and 40 lakhs handed over to bereaved families. Out of this, the payment to the beneficiary of Dr. Tennison Thazhath (Hope No. 1799) of Central Kerala Br. was withheld under court directives due to family issues. Now as per the judgment of Family court of Muvattupuzha, the money was handed over in a proportion to his wife and son. Our National President Dr. Elias Thomas handed over the cheque to Steve Tennison and Bilsy Tennison. Thanks to Dr. Biju Kumar S.D., SSS Chairman for the timely help to hope

### **LEGAL ISSUES**

In recent past, there IDA HOPE has seen a spurt in legal claims. This may be due to increased awareness due to easy availability of information from various sources like internet. However a point we should never forget is that, it is our duty to provide best possible dental care with proper procedures being followed to avoid and minimize the claims.

A few new cases have been reported this year. Adv. Shyam Padman & Adv. Sudheer Bose are managing our cases. And all the existing cases are running smoothly. We are getting favorable judgments in most of our cases. Thanks to Legal Cell Chairman Dr. Samuel K. Ninan Dr. V. Viswanath Dr. Manoj Joseph Michel, Dr. Saju N S and Dr. Shameem for their help and support to IDA HOPE.

All the IDA HOPE members are advised to renew their membership on time and also strictly ensure their specialist consultants and junior dental surgeons working with them are member of IDA HOPE this is to ensure better defence of indemnity cases.

At present there are 21 cases pending in the different consumer redressal forums.

#### **Indemnity Notices have been issued to our members for the following reasons.**

- ▶ Post Extraction Pain / Dry Socket.
  - ▶ Post Extraction Bleeding
  - ▶ Post Extraction Infection / Trismus
  - ▶ Removal of Lower third Molar Causing Fracture of Mandible
  - ▶ Wrong tooth extraction
  - ▶ Post filling pain
  - ▶ RCT Failure.
  - ▶ Full Denture...not Satisfactory
  - ▶ Wrong orthodontic Extraction
  - ▶ Orthodontic result ...not Satisfactory
  - ▶ Orthodontic Brackets Breakage / Multiple Non Attending Appointments.
  - ▶ Complication in Orthognathic surgery / Death of the Patient.
  - ▶ Death of Patient during Management of Fracture under GA
  - ▶ Mobility and bone loss after Orthodontic Treatment
  - ▶ Broken instrument during Endodontic Treatment
  - ▶ Roots in Maxillary Antrum
  - ▶ Bridge not satisfactory
- Counter replies are being filed and produced in court of law by our legal consultant for the indemnity notices received.

#### **Before starting any procedure on a patient, the member is advised to :**

1. Follow proper procedures to avoid and minimize the claims.
2. Maintain proper case history, Write details of clinical findings, Diagnosis,
3. Advice pre and post operative instructions properly.
4. Explain the treatment options, advantages, disadvantages and complications of each.
5. Medical / Dental / Allergy History (even if no relevant history – note that) in the case sheet
6. Avoid unnecessary assurances and words like Guarantee, life long, permanent etc
7. Inform patient and relative or bystander about treatment complications.
8. Pre operative IOPA is essential for RCT especially in case in history of anterior trauma
9. Give a short brief about medicines prescribed
10. Renew your clinic registration, dental council registration, IDA & HOPE Membership on time. Ensure that your consultants and assistants maintain the same. - Keep copies of their renewed certificates in the clinic
11. Advice proper Investigations prior to surgery. Do not undertake any surgical procedure without proper pre operative investigations.
12. Get a signed consent from patient or bystander, Also note bystanders name and relation with the patient.
13. Get radiographs, other investigations, consents from relevant medical specialist in writing whenever necessary.
14. Be attentive to the treatment while doing procedures - Avoid phone calls during procedure
15. Do not hesitate to refer cases for a second opinion or a specialist advice.
16. Do not render wrong or inappropriate treatment. Our philosophy should be DO NO HARM,
17. Behave calmly with patient and relative and never provoke the patient or tell them to go for case if they are aggrieved.
18. Listen to the patients complaints carefully and try to redress the complaint and convince the patient and bystander.

Proper records and case history will help us to defend effectively in majority of the indemnity cases..

All dentists are advised to maintain IDA HOPE prescribed format for maintaining case records or computerize the clinical records and give printed prescriptions to the patients.

**In an event of medico legal case :**

- ▶ Never panic or succumb to any pressure.
- ▶ Explain to the patient / relatives in polite manner that the procedure done is for the best interest of them. Complications rarely occur and are part of the life, which we never wish to happen.
- ▶ Be firm, be calm but don't agitate them.
- ▶ False justification will lead to trouble. Now day's patients are well aware of the treatment procedures.
- ▶ Inform the issue immediately to Legal Cell Chairman, IDA HOPE representative of your branch & IDA HOPE secretary.
- ▶ Prepare three set of copies of the following and send one set to the Legal Cell Chairman and two sets to the secretary immediately on receipt of a legal notice.
- ◇ Your Name, IDA Hope No:
- ◇ Copy of Legal notice received
- ◇ Copy of the case sheet and any other document which you feel important like consent letter, referral letter, X rays, Lab report etc
- ◇ A complete profile of the Doctor / Doctors served with the notice
- ◇ Copy of Degree Certificate and updated dental council registration
- ◇ Copy of Clinic Registration
- ◇ Detailed version of the doctor about the incident with your explanation in your letter head and signed.
- ◇ Letter from branch Secretary stating membership status

Do not send any reply on your own or through any advocate with out the permission of the scheme office. All cases are well managed by our team with the help of our advocates especially Adv. Shyam Padman.

REMEMBER IDA HOPE IS ALWAYS THERE TO RENDER ALL POSSIBLE HELP TO ITS MEMBERS,

**Administration and office bearers**

Office bearers are

1. Chairman Dr. Thomas K.C. Kannur, (President, IDA Kerala State)
2. Chairman, Legal Cell & First Vice Chairman Dr. Samuel K. Ninan, Pathanamthitta, Mob: 9447440004
3. Chairman SSS & Second Vice Chairman Dr. Biju Kumar S.D., Kollam, Mob: 9447077147
4. Hon. Secretary – Dr. Joseph C.C., Thamarassery Mob: 9447252873
5. Hon. Joint Secretary – Dr. Manoj Joseph Michel
6. Treasurer – Dr. B. Madhavankutty
7. Internal Auditor – Dr. Nizaro Siyo

President, President Elect, IPP, Hon. Secretary & Treasurer of IDA Kerala State are ex officio members. Two members from each local Branch – One representative & President or Secretary of the local branch whoever is representing the state executive committee are also members of IDA HOPE Managing Committee.

All the office bearers and managing committee members are working sincerely for the benefit of the members. Thanks for their support.

We are trying our level best to be sincere and compassionate to each and every member and to the profession in total. Our team had to face a lot of challenges like implementing our HOPE MEDI last year, still we could maintain good membership growth and attain the confidence our members.


Let me thank all our team of office bearers for being responsible to their duties. Thanks to all the office bearers of IDA HOPE and IDA Kerala State, President Elect Dr. Mohammed Sameer, IPP Dr. Nizaro Siyo, Hon. Secretary Dr. Sanal O.V., all the executive committee, members, representatives of IDA HOPE, Managing committee members, office bearers of Local Branches, Dr. Manoj Joseph Micheal, Dr. Madhavankutty, Dr. Dinesh K.R. and Dr. Antony Thomas, Dr. V. Viswanath and Dr. Sureshkumar.G and also IDA HOPE office staff for their continuous support and guidance.

The Office and Address of the Scheme shall be that of the Secretary of the scheme.

You are always welcome to contact me at the address below for any query / details etc.



Dr. K.C. THOMAS  
Chairman – IDA HOPE,  
Mob : 9447703224



Dr. JOSEPH CC,  
Hon. Secretary – IDA HOPE,  
Dental Specialty Clinic, Thamarassery, Calicut (Dt)  
KERALA Pin - 673573.  
Phone: Mobile 9447252873 s  
0495 2222904 (clinic), 0495 2372971 (Resi)  
E mail: secretaryidahope@gmail.com or josephjyothi@yahoo.com





# Reminiscence of Aloha '16

Dr. Binu Mathew  
Editor. Aloha '16

## An Event Scripted in golden letters

The annual dental conference is the premier event of all state dental associations. Kerala being the largest association in India with maximum number of branches, the event has greater importance and have participants and followers from all over the country. Dental Science has been assuming increasing importance in the modern world of changing lifestyles and poses a challenge to the dental professionals. The annual dental conferences are supposed to provide every dental surgeon a good platform for exchange of experience and sharing of skills and thereby updating and upgrading his professional skills.



When such an important event was allotted to such a small branch of 76 members, with a handful of active members, a lot of people raised their eyebrows. But the State President Dr. K.C. Thomas and Hon. Secretary

Dr. O.V. Sanal had full faith in the potential of IDA Alappuzha branch and a COC was formed under the guidance of Dr. Antony Thomas choosing Dr. Chandy Joseph as Organising Chairman and Dr. Joe Bijoy as Organising Secretary and the rest is History.

Everything about the conference was meticulously planned giving full priority to our guests. Alleppey being the top most tourist destination, a special travel desk was formed for advance booking the accommodation at a bargain rate and travel arrangements were made in such a way that Alappuzha is enjoyed with Family. All Key note Speakers and subjects were carefully selected and Pre-conference courses were chosen for the first time after getting inputs from a large number of dental surgeons around the state. It is also the very first time a dynamic website was launched with a payment gateway and people could register for the



conference, submit scientific papers and or join any preconference courses of their choice from the comfort of their homes. It was also the first time an exclusive android mobile application was launched and people could do all conference related activities like registrations, know timings of events, navigation to venues and it even created a virtual badge for entry and we are happy to know that a number of people could use only their mobile phone for entry in to multiple conference venues. The use of electronic media has made the conference activities a lot easier for the participants.

There were exclusive arrangements were made for free transportation from railway stations and



from the place of accommodation to conference venue and to banquet venue and vice versa. The fully air-conditioned and spacious traders pavilion was attracted and enjoyed by a large number of visitors and was well appreciated by

traders. We got allotted 6 credit points for the pre conference courses which is another first time achievement.

The exclusive mega banquet for the registered delegates was one of the main attractions of the conference with entertainments provided by Indian and international artists followed by large variety of mouthwatering delicacies. No wonder the then IDA President Dr. K. C. Thomas has rated it as one of the best organised conference he has ever seen.

More than everything it is the large participation of each and every one of you made it a large success and it is a big salute from all the members IDA Alappuzha branch for taking the 48th Kerala Dental Conference by their heart. ■

## CDE Report



**Dr Nirmal George Saibu**  
Convenor CDE

Dear Colleagues,

I am privileged to be in this esteemed circle as the Kerala State CDE Chairman. Thanks for extending your wholehearted co-operation during all my past tenures in various positions of IDA. I hope the same would continue now as well. Let the history repeat itself, but, of course with more programmes.

As always, we would endeavor for more programmes, rich and varied in content and innovative in structure. we would like to bring in the best of international, national and regional faculties for imparting education to the members of IDA Kerala State. This year we are planning to implement four programs 1) Platform for regional faculties 2) State level CDE programs for 3 zones 3) Certified courses for Dentists 4) Webinar – Friday club.

For all this, we definitely need your complete support and co-operation. With the hope that we would receive it, we invite you all to look forward to an exciting and knowledge packed CDE term.

Thank you

With warm regards

Dr Nirmal George Saibu

Details of the program.....

- 1) Platform for regional faculties  
Criteria for become a regional faculty
  - a) minimum 5 yrs in IDA
  - b) must be BDS/ MDS
  - c) good standing member of IDA Kerala State
  - d) submission of application only through their local branch.
  - e) submit any two topics as per the wish by the faculty and also the outline.
  - f) photo of faculty
  - g) submit before March 15th
- 2) State level CDE programs for 3 zones  
Four international faculties four different topics
- 3) Certified courses for Dentists  
Dental Implants and Dental Laser
- 4) Webinar – Friday club  
Monthly once – preferably Friday  
Eminent faculty  
45 Min to 1 hour time

## CDH Report



**Dr. Subhash Madhavan**  
Chairman CDH

### CHILDRENS DAY - NOV 14 2015

IDA Kerala state observed Children's Day on Nov 14th 2015 at

Mar Dionysius Seminary Higher secondary School at Kottayam. CDH State Chairman Dr.Subash Madhavan presided the function.

Chief guest was Mr. G Ashok Kumar, AC- Armed Reserved Police. And felicitation done by Sree.Venugopal ADNO Student Police Cadet Kottayam.

256 Police student cadets selected from all over Kerala attended the function and the awareness class. Dental awareness class taken by Dr. Anukesh Prasannan.

### WORLD AIDS DAY - DECEMBER 1

A Seminar was conducted on World Aids Day by IDA Kerala State and hosted by IDA Malabar Branch on 01/12/15 at 7.00pm. The programme was inaugurated by Dr.Subash Madhavan, CDH Chairman, IDA Kerala State in the Presence of Dr.N.S.Saju, President IDA Malabar branch and Dr.Shyam Kishore CDH Chairman, IDA Malabar branch. Dr.Neeraj MD Gen Medicine Asst. Professor Government Medical College explained about the Clinical Precautions and emergency measures in case of accidental exposure (needle prick) in the clinics. Mr.Saadik Coordinator AIDS'S Cell Kozhikode explained about the present scenario. A HIV patient for 13 years, was also present and he explained about his dark days of life for the last 13 years. Dr.Shyam Kishore delivered the vote of thanks followed by the dinner.



## New Office Bearers for Kerala Dental Council



**Dr. Anish P**  
President



**Dr. Johnykutty Jacob**  
Vice-President

Kerala Dental Council meeting held on 20th February 2016 elected Dr. Anish P. as President, Dr. Johnykutty Jacob as Vice President. Dr. Shaji K. Joseph, Dr. Prakash P., Dr. Prasanthila Janam, Director of health services were elected as Executive Committee Members. Dr. Shaji K. Joseph is the ethics committee chairman and Dr. Prakash P. is the continuing education committee chairman.

### Continuing Education Committee

**Chairman:** Dr. Prakash Prabhakaran;

**Members:** Dr. Prasanthila Janam, Dr. Biju A. Nair, Dr. Prasanth S.

### Scrutiny Committee:

Dr. Biju A Nair; Dr. Prasanth S.

### Ethics Committee:

**Chairman:** Dr. Shaji K. Joseph;

**Members:** Dr. George Varghese, Dr. K. Mohanan, Dr. Biju A Nair, Dr. Prakash Prabhakaran