

## ORAL PATHOLOGY

### PYOGENIC GRANULOMA: REPORT OF 3 CASES.



#### CORRESPONDING AUTHOR:

Dr.MADHUSUDAN.A.S.,

Associate Professor,

Department of Oral and Maxillofacial Pathology,

Pacific Dental College and Hospital,

Debari, Udaipur- 313003,

Rajasthan state.

Mobile: +91-9413026974.

E Mail id: madhu.tanu@gmail.com

- AUTHORS :** Dr. Madhusudan.A.S. 1. Associate professor,  
 Dr. Priyanka sharma 2. Post graduate student,  
 Dr. Sanjaya nayak 3. Senior lecturer,  
 Dr. Phalguni Dakwala 4. Professor and head,  
 Department of oral and maxillofacial, pathology,  
 Pacific dental college and hospital,  
 Udaipur, Rajasthan State.

Dr. Madhusudhan. A. S. has a brilliant career as oral and Maxillofacial Pathologist in Udaipur Rajasthan. He is a postgraduate associate professor in pacific dental college, Udaipur Rajasthan.

He has presented various Scientific papers in national, CDE & State level programmes. Immuno histochemistry, Dental Photography Modern dental materials, Cytogenetics, Computerized Histomorphometry etc; are his special interests.

## ABSTRACT

Analysis of the clinical features, histopathology and pathogenesis of pyogenic granuloma based on biopsy and surgical specimens of 3 cases submitted to the department of oral and maxillofacial pathology. All these granulomas occurred on the gingiva, with the maxillary gingiva involved more frequently than mandibular ones. Female: male ratio was 3: 2. No correlation was found between the size and duration of the lesion. Histopathology revealed proliferating retepegs with underlying loose fibro vascular connective tissue stroma composed of numerous small and large vascular spaces and scattered inflammatory cells. Conservative local excision was the preferred treatment.

**Key words:** Reactive lesions, pyogenic granuloma, Pregnancy tumors, Sclerosing Pyogenic Granuloma, Lobular Capillary Hemangioma, Epulis GSravidarum.

## INTRODUCTION

Focal reactive lesions are progressive proliferations in response to injury. Every act of injury incites a process of repair, in which various types of cells play a role. The proliferative activity of the various tissue elements normally occurs in a definite physiologic proportion to injury, producing just the right amount of tissue to eliminate the defect. In some processes of repair there is an over zealous proliferation of one of the tissue elements, resulting in an exuberant process and development of tumor-like configurations. However, these lesions are neither autonomous nor capable of unlimited growth and cannot be considered as neoplasm<sup>1</sup>. These reactive lesions can be classified into Focal fibrous hyperplasia, Peripheral ossifying fibroma, pyogenic granuloma and Peripheral giant cell granuloma<sup>2</sup>.

Pyogenic granuloma represents an exuberant connective tissue proliferation to a known stimulus or injury modified by hormones and drugs. It is composed of proliferating capillaries and endothelial cells that are sometimes seen in a lobular pattern and typically accompanied by a mixed inflammatory cell infiltrate. Majority of these lesions represent exuberant granulation tissue, but some of these lesions undergo sclerosis and lose much of their vascularity resembling fibroma<sup>1,3</sup>.

## CASE REPORT – 1

A 35 years old female patient reported to the department of oral medicine and radiology, with the chief complaint of swelling in upper right back region of jaw since 20 days. Intraoral examination revealed a swelling of 1 x 1 cm in relation to 15 & 16 (fig.1). The swelling was sessile, soft in consistency, reddish in color and would bleed spontaneously. Radiographs revealed no significant findings concerning the lesion. Excisional biopsy was performed and tissue was sent for histopathological examination.

**MACROSCOPY:** Gross soft tissue specimen was grayish in color, measuring about 1 x 1 cm with irregular in shape. The whole soft tissue specimen was taken for processing, sectioning was done and subjected to hematoxylin and eosin stains.

### **CASE REPORT - 2**

A 58 years old male patient reported to the department of oral medicine and radiology, with the chief complaint of swelling in upper front region of the jaw since 4 months. On intraoral examination, swelling measuring approximately 5 x 10 mm in relation to 23 was observed (fig.2) which extended till the palatal aspect causing the pathological migration of 22 (fig 3). Swelling was sessile, soft to firm in consistency, non tender and reddish in color. Oral hygiene of the patient was very poor with stains+++ and calculus+ . Radiograph did not reveal any significant finding in relation to lesion. Tentative diagnosis of pyogenic granuloma or focal fibrous hyperplasia was made. Excisional biopsy was performed and excised tissue was sent for histopathological examination.

**MACROSCOPY:** On gross examination, excised tissue specimen appeared grayish white in color, measuring 0.5 x 1.5 cms with soft to firm in consistency. Processing and sectioning was done and the tissue was stained by hematoxylin and eosin stains.

### **CASE REPORT - 3**

A 60yrs old female patient was reported with swelling in upper front region of the jaw since 6months. Extra examination did not reveal any gross asymmetry (fig 4). Intraoral examination revealed a soft pedunculated swelling measuring 1.5 x 2 cms, in relation to left maxillary anterior region as the patient was edentulous (fig 5). Swelling was non tender, soft in consistency, reddish in color and not associated with bleeding. Radiographic findings were not significant. Tentative diagnosis of pyogenic granuloma was made. Excisional biopsy was performed and tissue was sent for histopathological examination.

**MACROSCOPY:** On gross examination the soft tissue specimen measuring 6 x 8 mm, whitish in color with irregular margin and soft in consistency. The grossed soft tissue specimen was subjected to processing and stained with hematoxylin and eosin stain.

**MICROSCOPY:** Histopathologic features of all the three cases were similar. Low power view revealed a stratified squamous parakeratinised hyperplastic epithelium with focal acanthosis and underlying loose vasculo-cellular connective tissue stroma. High power showed the presence of plump and vesicular fibroblasts, hyalinised collagen fibers and proliferation of numerous large and small vascular spaces with extravassated RBC's. Dense mixed inflammatory cells like neutrophils, lymphocytes, plasma cells and macrophages were evident (fig.6, 7 & 8). The Final diagnosis of Pyogenic granuloma was confirmed.

## DISCUSSION:-

Pyogenic granuloma is a common inflammatory lesion composed of proliferating capillaries and endothelial cells that are sometimes seen in a lobular pattern typically accompanied by a mixed inflammatory cell infiltrate. Although majority of these lesions essentially represent exuberant granulation tissue, some lesions will undergo sclerosis and lose much of their vascularity<sup>4</sup>.

The etiology of this lesion remains unknown. Several investigators hypothesized that it is a hyper proliferative vascular response to infective organisms of low virulence. The entity was first described in 1897 by Poncet and Dor, who believed that the etiological organisms were fungi. In the early nineteenth century, Crocker (1903) and Hartzell (1904) applied the term granuloma pyogenicum, believing the lesion to be a localized bacterial infection, frequently presenting superficial fibrin quoted ulcers resembling pus. In spite of its name, it is not a true granuloma<sup>3</sup>.

A viral etiology has also been suggested but never been documented in case reports. Some authors suggest that granuloma arises from trauma to the skin or mucous membrane and healing abnormally with excessive formation of granulation tissue<sup>5</sup>. However in more recent study by Yunn K (2000) who carried out an immunohistochemical analysis and suggested that the etiology may be due to the imbalance between angiogenic enhancers and inhibitors and whether and how the angiogenesis associated factors are regulated by female steroid hormones remains to be answered<sup>6</sup>.

The term "pregnancy tumor" or pregnancy granuloma or epulis gravidarum or granuloma gravidarum has been used for many years to describe a lesion histopathologically indistinguishable from a pyogenic granuloma, but occurring on the gingival mucosa of a pregnant women<sup>7,8</sup>. Lee<sup>9</sup> (1968) and others suggested that an endocrine imbalance probably played a role in the development of these lesions. However Mair and Orban (1949) studied gingivitis in pregnancy and concluded that although pregnancy can be considered a conditioning factor, which influences the character of the inflammatory reaction in the gingiva, it is not the primary etiologic factor in the development of gingival or periodontal disease<sup>4</sup>. Ojanatko-Harri (1985) and Ojanatko-Harri et al. (1991) proposed that the high levels of progesterone in pregnancy, which can cause immune suppression combined with the inhibited function of inflammatory cells, alters the reaction of the tissue to dental plaque and produce a more fulminant gingivitis<sup>4</sup>. More recently Daley et al. (1991) concluded from the examination of 42 cases that the pregnancy tumor is a distinctly different entity from pyogenic granuloma with a differing behavior, but only with a histologic similarity<sup>2</sup>.

The study by Nichols et al. (1992) attempted to implicate the presence of estrogen and progesterone receptors by immunohistochemical staining in the pathogenesis of lobular capillary hemangioma and the results showed a uniformly negative expression<sup>10</sup>. On contrary, Whitaker et al. (1994) concluded that the quantity of estrogen or progesterone receptors in pyogenic granuloma is not the determining factor in the pathogenesis of this lesion. Rather, attributed to the increased serum levels of these hormones in pregnancy could exert a greater influence on the endothelium of vessels, giving rise to pyogenic granuloma<sup>4</sup>.

Angelo M. (1999) reviewed dental plaque induced gingival diseases and noted that pregnancy associated pyogenic granuloma is not a tumor but an exaggerated inflammatory response, during pregnancy to an irritation resulting in a solitary polypoid capillary hemangioma. This has been reported to occur in 0.5% to 5.0% of pregnant women. It may develop as early as the first trimester<sup>12,13,14</sup> with some amount of recurrence during pregnancy<sup>15</sup> and paradoxically, partial or complete regression of the lesion commonly after child birth<sup>12</sup>.

It is generally now agreed that Pyogenic granuloma arises as a result of some minor trauma to the tissues, which provides a pathway for the invasion of non specific type of microorganisms and tissue respond by overzealous proliferation of a vascular type of connective tissue<sup>16</sup>.

Clinically, pyogenic granuloma is an elevated, exophytic mass which is pedunculated or sessile with a smooth, lobulated or even mushroom-like, warty surface, which commonly ulcerate and tends to bleed spontaneously or upon slight trauma and usually appears fiery red in color<sup>2,17,18</sup>.

Pyogenic granuloma occurs in all age groups but mainly in youngsters. Females are more frequently affected than males and there is no marked difference between the involvement in the mandible and the maxilla. It commonly occurs not only on maxillary anterior gingiva<sup>5,12,19</sup> but in the other intraoral sites such as lips, tongue, palate, occasionally on the buccal mucosa and on the skin also<sup>7,8,19,20,21</sup>.

Histologically the lesion is composed of a vast number of small and large endothelium lined vascular spaces with a mixed inflammatory infiltrate of lymphocytes, plasma cells and frequently polymorphonuclear neutrophils. It is covered by a thin, often ulcerated layer of stratified squamous epithelium<sup>2,17,18</sup>. The amount of collagen is usually sparse, and may tend to become more fibrous if left intact for a longer time<sup>2,5</sup>. However few authors<sup>2</sup> suggested that three persistent pregnancy tumor became focal fibrous hyperplasia, indicating the loss of vascular proliferative effect by undergoing resolution and organization. While some considered this highly unlikely<sup>21</sup>. Brown, Darlington and Kupfer (1956) has shown angiofibromatous epulides on the alveolar border produce bone in 6 cases and 50% of which is seen in maxillary anterior

region<sup>22</sup>. Anderson B.G. (1939) states that the vascular supplies in these lesions seem to be adequate only for nutrition, but high vascularity may stimulate true hemangioma<sup>23</sup>.

Eversole and Rovin (1972) noted a direct correlation between age, sex and site distribution for both Pyogenic granuloma and peripheral giant cell granuloma and suggested a varied response to similar irritational factors irrespective of dental tissue. It is therefore postulated that the peripheral giant cell granuloma is a response of periosteum to more intense irritation than that associated with the formation of the pyogenic granuloma<sup>19</sup>.

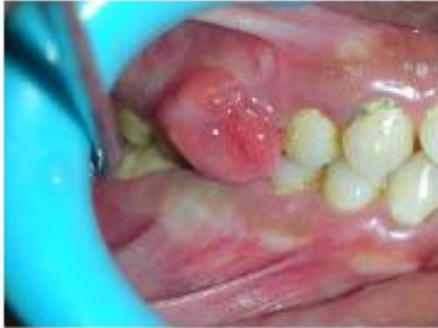Conservative local excision is the preferred treatment. According to some authors it is variable, depending upon the hormonal state of the affected individuals and multiple recurrences was also possible<sup>2,9&22</sup>.

If the lesion is not surgically excised, there is gradual obliteration of many capillaries and it assumes a more fibrous appearance. This maturation of connective tissue element is constructed as evidence of healing of the lesion. Both clinically and microscopically an old lesion may resemble a fibroepithelial polyp or even a typical fibroma and it is likely that many fibromas are healed Pyogenic Granulomas<sup>16</sup>.

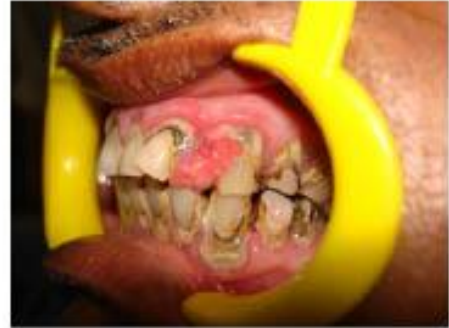In the above reported cases, lesion was seen in 2 female patients out of three cases, confirming the female predilection. In all the cases, gingiva was the site of lesion and swelling was pedunculated in one of the cases and sessile in rest two cases. The surface of lesion was smooth and reddish in color. Microscopically, all the reported cases showed similar morphology.

Because the lesion frequently is misinterpreted clinically and histologically and since the lesions of mucous membrane have not been appreciated fully in the field of dentistry, the literature was reviewed.

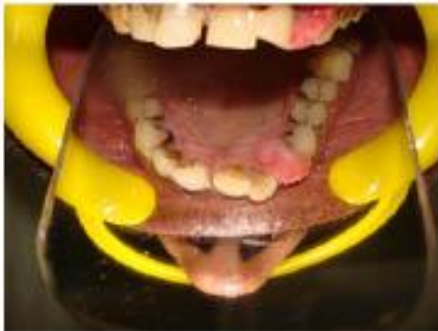



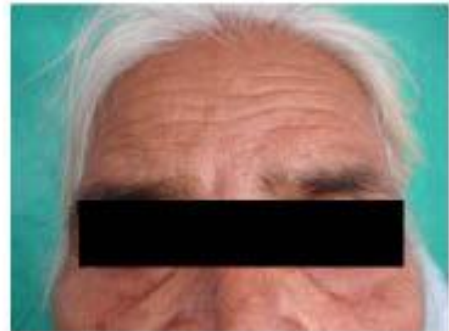**Figure 1**



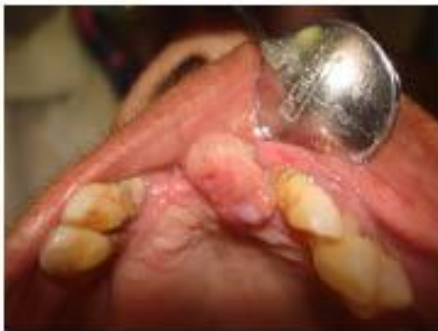**Figure 2**



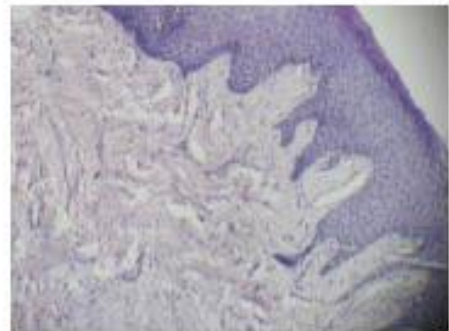
**Figure 3**



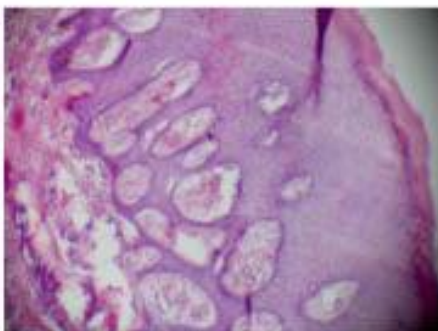
**Figure 4**



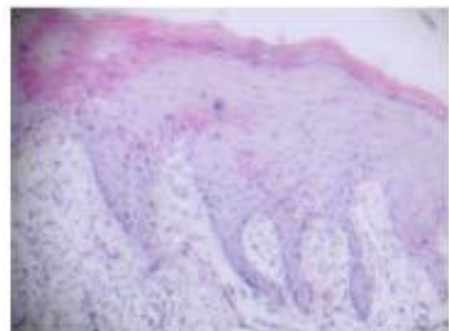
**Figure 5**



**Figure 6**



**Figure 7**



**Figure 8**

**FIGURE LEGENDS:**

Figure 1: Intraoral picture of lesion on buccal aspect of gingiva measuring approximately 1x1cm in relation to 15&16 corresponding to case 1.

Figure 2: Intraoral photograph of lesion showing swelling measuring approximately 5x10mm on gingival aspect of 23 representing case 2.

Figure 3: Intraoral Occlusal view of case 2 showing extension of lesion upto palatal aspect and pathological migration of 22.

Figure 4: Extraoral image of case 3 patient showing no gross asymmetry of face pertaining to lesion.

Figure 5: Intraoral photograph of swelling measuring about 1.5 x 2 cms on left anterior edentulous region corresponding to case 3.

Figure 6: Microscopic picture of case 1 lesion showing proliferating hyperplastic epithelium with underlying fibro-vascular connective tissue composed of numerous small and large vascular spaces and scattered inflammatory cells.

Figure 7: Histopathologic picture of case 2 showing stratified squamous parakeratinised epithelium with connective tissue comprising proliferating vascular spaces with extravassated RBC's

Figure 8: Histopathological picture showing straitified squamous parakeratinised hyperplastic epithelium with fibrovascular connective tissue, plump fibroblasts, hyalinised collagen fibers and dispersed inflammatory cells corresponding to case 3.



## REFERENCES

1. Kerr DA and Ash MM. Oral Pathology. 5th ed. Philadelphia, Lea and Febiger, 1986.
2. Daley TD, Nartey NO and Wysocki GP. Pregnancy tumor: An analysis. Oral Surg Oral Med Oral Pathol 1991;72:196-199.
3. Neville BW, Damm DD, Allen MC & Bouquet JE . Oral and maxillofacial pathology. 1st ed. Philadelphia, W.B.Saunders Company, 1995: 362-376.
4. Whitaker SB et al. Identification and semi quantification of estrogen and progesterone receptors in pyogenic granulomas of pregnancy. Oral Surg Oral Med Oral Pathol 1994: 78:755-760.
5. Kerr DA. Granuloma Pyogenicum. Oral Surg 1951: 4 : 158-176.
6. Yuan K, Jin Y and Lin M T. The detection and comparison of angiogenesis associated factors in pyogenic granuloma by immunohistochemistry. J. Periodontol 2000 : 71:701-709.
7. Allen NE. Pregnancy tumor superimposed upon a nevus. Oral Surg Oral Med Oral pathol 1960:13:657-662.
8. Fabe SS . Pregnancy tumor. Oral Surg Oral Med Oral Pathol 1954 : 7:714-719
9. Lee KW. The fibrous epulis and related lesions, Granuloma Pyogenicum, pregnancy tumor, fibroepithelial polyp and calcifying fibroblastic granuloma. A clinico-pathological study. Periodontics 1968 : 6:277.
10. Nichols GE et al. Lobular capillary hemangioma - An immunohistochemical study including steroid hormone receptor status . Am J Clin. Peridontol 1992:97:770-775.
11. Angelo M. Dental plaque –Induced gingival diseases. Ann Peridontol 1999
12. Shafer WG, Hine MK and Levy BM. A Textbook of Oral Pathology.4th ed. Philadelphia, WB Saunders Company. 1983:141-208.
13. Macleod RJ and Soames JV. Epulides:A clinico-pathological study of a series of 200 consecutive lesions. Br Dent 1987 : 163:51-53.
14. Traiger J. Pregnancy tumor - Report of a case. Oral Surg Oral Med Oral Pathol 1961:14:1264-1268.
15. Eversole LR. Clinical outline of oral pathology : Diagnosis and treatment. 2nd ed Philadelphia, Lea & Febiger.1984:101.
16. R Rajendran, B Sivapathasundharam: Shafer's textbook of oral pathology 6th ed.
17. Kfir Y, Buchner A and Hansen. Reactive lesions of gingiva. A clinico-pathological study of 741 cases. J Peridontol.1980 :51:655-661.
18. BuchnerA, Calderton S and Ramon Y. Localized hyperplastic lesions of the gingiva –A clinico-pathological study of 302 lesions. J. Peridontol.1977: 48(2): 101-104.
19. Eversole LR and Rovin S. Reactive lesions of the gingiva. J Oral Pathol 1972:1:30-38.
20. Patrice SJ, Wiss K and Mulliken JB. Pyogenic granuloma- A clinico-pathological study of 178 cases. Pedi Dermatol 1991:8(4):267-276.
21. Bhasker SN and Jacoway JR. Pyogenic granuloma- Clinical features, incidence, histology and result of treatment: Report of 242 cases. J Oral Surg 1966: 24: 391-398.
22. Brown GN, Darlington CG and Kupfer SR. A clinico-pathologic study of alveolar border epulis with special emphasis on benign giant cell tumor. Oral Surg 1956-9:765-775, 888-901.
23. Anderson BG. Epulis -A series of cases. Arch Surg 1939 : 38: 1030-1039.